

[ORIGINAL ARTICLE]

Vertical and Circumferential Localization of Esophageal Mucosal Breaks in Patients with Mild Reflux Esophagitis

Kyoichi Adachi¹, Takumi Notsu¹, Tomoko Mishiro¹, Mayumi Okada²,
Eiko Okimoto² and Yoshikazu Kinoshita²

Abstract:

Objective Esophageal mucosal breaks are considered to occur circumferentially in locations with high exposure to acid. In the present study, we investigated the circumferential localization of esophageal mucosal breaks based on their distance from the esophagogastric junction.

Methods The vertical and circumferential localization of 625 esophageal longitudinal mucosal breaks was examined in 398 patients with mild reflux esophagitis.

Results The number of mucosal breaks in which the distal end was located 0-1 cm from the esophagogastric junction was 454, while those in which the distal end was located 1-2, 2-3, and >3 cm from the junction were 125, 28, and 18, respectively. There was a marked difference in the circumferential distribution among the groups defined by distance from that junction. Esophageal mucosal breaks whose distal end were located 0-1 cm from the esophagogastric junction were mainly found on the right anterior wall of the esophagus, while those located 1-2 cm from the junction were mainly found on the right wall, and those located 2-3 and >3 cm from the junction were mainly found on the posterior wall.

Conclusion Esophageal mucosal breaks occurring relatively near the esophagogastric junction mainly exist on the right anterior wall, whereas those farther from that junction tend to exist on the posterior wall of the esophagus. The circumferential location of esophageal mucosa highly exposed to refluxed gastric contents changes based on the distance from the esophagogastric junction.

Key words: circumferential localization, vertical localization, esophageal mucosal breaks, reflux esophagitis

(Intern Med 58: 15-20, 2019)

(DOI: 10.2169/internalmedicine.1356-18)

Introduction

The main location of esophageal mucosal breaks in patients with low-grade reflux esophagitis [A and B in the Los Angeles (LA) classification] has been shown to be the right anterior wall, while that in high-grade patients (grades C and D) is generally the posterior wall of the distal esophagus (1, 2). This difference in the localization of such mucosal breaks between low- and high-grade esophagitis is considered to be related to the area exposed to refluxed acidic gastric contents. Indeed, an intra-esophageal pH monitoring study showed that nocturnal gastroesophageal reflux is predominant in patients with high-grade esophagitis,

and the posterior wall of the esophagus may be exposed to refluxed acid while in a supine position (3). In addition, a study that utilized a catheter equipped with eight pH sensors radially arrayed at the same level revealed that the location of esophageal mucosal breaks fits with the area mainly exposed to acid in patients with low-grade esophagitis (4). Therefore, esophageal mucosal breaks in all types of esophagitis are considered to occur in locations with high exposure to gastric acid.

We noticed that esophageal mucosal breaks sometimes exist in areas relatively far from the esophagogastric junction. The site of esophageal mucosal break is theoretically identical to the locations with high exposure to refluxed gastric contents, even though the mucosal break exists apart from

¹Health Center, Shimane Environment and Health Public Corporation, Japan and ²Second Department of Internal Medicine, Shimane University Faculty of Medicine, Japan

Received: April 9, 2018; Accepted: May 24, 2018; Advance Publication by J-STAGE: August 10, 2018

Correspondence to Dr. Kyoichi Adachi, adachi@kanhokou.or.jp

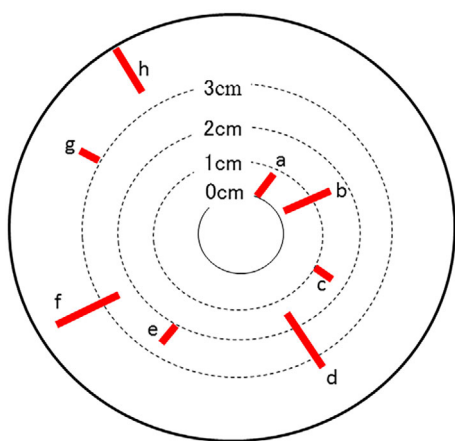


Figure 1. Determination of the vertical and circumferential localization of esophageal mucosal breaks. The vertical localization was determined based on distance from the distal end of the esophageal mucosal break to the esophagogastric junction (a, b: 0-1 cm; c, d: 1-2 cm; e, f: 2-3 cm; g, h: >3 cm). The circumferential localization was determined according to the numbers on a clock face (a: 1, b: 2, c: 4, d: 5, e: 7, f: 8, g: 10, h: 11 o'clock).

the esophagogastric junction. However, the relationship between the vertical and circumferential localization of esophageal mucosal breaks has not been examined.

The purpose of the present study was to investigate the circumferential localization of esophageal mucosal breaks that exist relatively far from the esophagogastric junction.

Materials and Methods

The study subjects were individuals who visited the Health Center of Shimane Environment and Health Public Corporation for an annual detailed medical checkup between April 2015 and March 2016. All underwent upper endoscopic examinations. Those with a history of gastric surgery were not included in this study, whereas subjects who had taken medications, such as proton pump inhibitors or H₂ receptor antagonists, were not excluded.

All upper endoscopic examinations were performed by licensed experienced endoscopists using an EG-530NW or EG-L580NW device (Fujifilm, Tokyo, Japan). At our institution, upper endoscopic examinations are performed with the subjects in an unsedated condition without anti-cholinergic drug administration, and the endoscope is typically inserted in a transnasal manner. The size of the diaphragmatic hiatus was assessed during endoscopic observation by comparing the width of the cardiac opening with the diameter of the shaft using endoscopy at the cardiac portion, with the findings used to divide the subjects into 3 groups based on the hiatus size (<1.0, 1.0-2.0, >2.0 cm). Gastric mucosal atrophy was evaluated based on endoscopic findings using the classification of Kimura and Takemoto, in which gastric mucosal atrophy is classified into six groups (C1, C2, C3, O1, O2, O3) (5). This classification has been shown to correlate well

with the histological features of atrophy. For the present study, C1-C2 was defined as mild, C3-O1 as moderate, and O2-O3 as severe gastric mucosal atrophy.

The endoscopic findings of reflux esophagitis were evaluated using the LA classification (6), and individuals with a grade of A, B, C, or D were diagnosed as positive for reflux esophagitis. All endoscopic images were reviewed by one of the authors (K.A.) who investigated the vertical and circumferential localization of esophageal mucosal breaks. For this study, only esophageal mucosal breaks that showed longitudinal extension were analyzed so as to more clearly investigate the relationship between the circumferential distribution of mucosal breaks and distance from the esophagogastric junction. Therefore, esophageal mucosal breaks that were transversely extended in grade C and D cases were excluded from the analysis. We defined the esophagogastric junction as the distal margin of the palisade vessels, based on the criteria of The Japan Esophageal Society (7). Vertical localization was determined based on the distance between the distal end of the esophageal mucosal break and the esophagogastric junction. The distance between the distal end of the esophageal mucosal break and the esophagogastric junction was examined by the scale on the endoscopic shaft during the endoscopic procedure or by retrospectively reviewing multiple endoscopic images of the lower esophagus, with findings used to divide patients into 4 groups (0-1, 1-2, 2-3, >3 cm). In this study, we did not take the existence of Barrett's epithelium into account when the distance between the esophageal mucosal break and the esophagogastric junction was determined. The circumferential location of mucosal breaks in the esophageal wall was determined according to the numbers on a clock face. For example, a mucosal break in the anterior wall was considered to be located in the 12 o'clock position, while that in the esophageal mucosa leading to the gastric lesser curvature was located in the 3 o'clock position. When multiple mucosal breaks were present, the circumferential and vertical locations of each were analyzed (Fig. 1-3).

Statistical analyses were performed using a chi-squared test, Fisher's exact test, and a paired t-test. The Stat View 5.0 (Abacus Concepts, Berkeley, USA) software program for Macintosh was used to perform statistical analyses. A *p* value <0.05 was considered to indicate statistical significance.

This study was performed in accordance with the Declaration of Helsinki, and the protocol was approved by the ethics committee of the Shimane Environment and Health Public Corporation. Written informed consent indicating that the clinical data would be used for a clinical study without the release of individual information was obtained from each subject before performing the medical checkup.

Results

Among individuals who visited our institution for an annual detailed medical checkup between April 2015 and

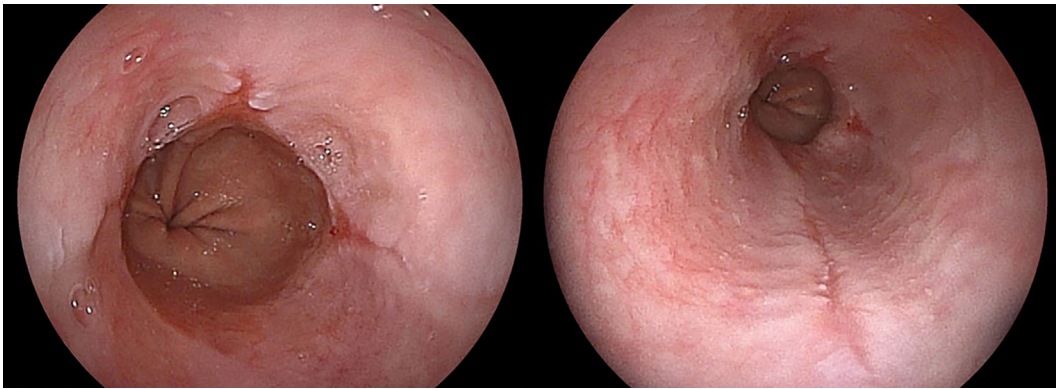


Figure 2. Representative subject with three esophageal mucosal breaks. The circumferential localization of the esophageal mucosal breaks at 0-1 cm from the esophagogastric junction was noted at 12 and 3 o'clock, while breaks at 2-3 cm from the esophagogastric junction were mainly noted at 6 o'clock.

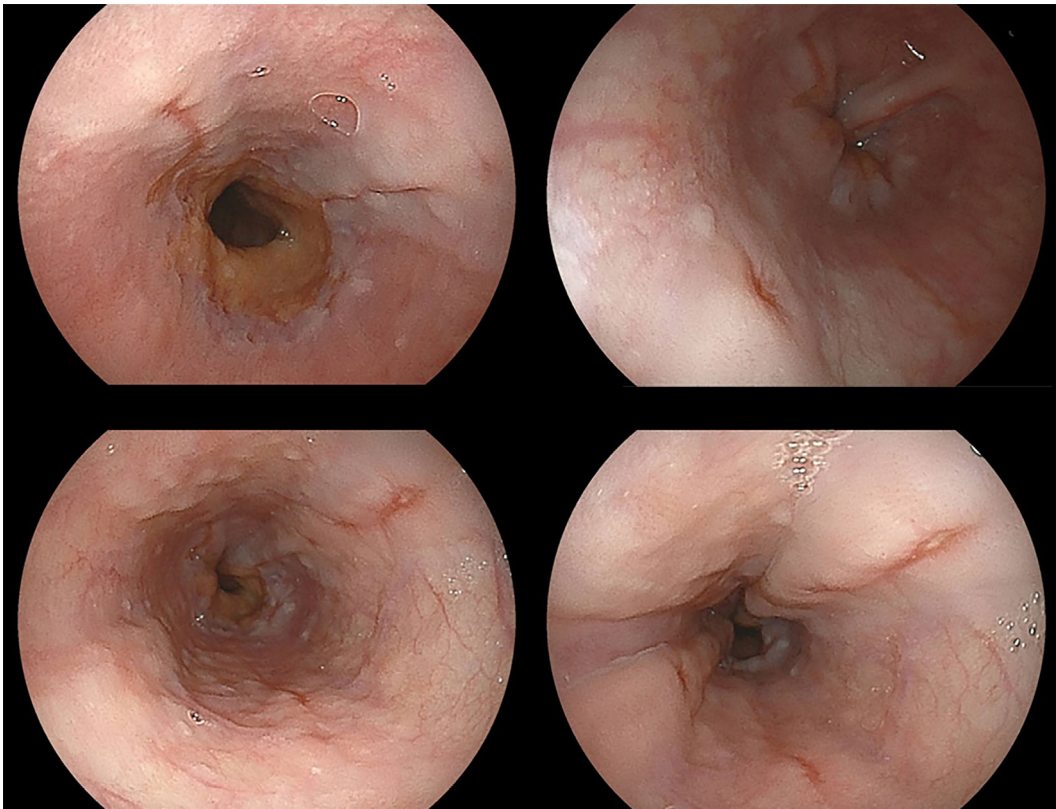


Figure 3. Representative subject with five esophageal mucosal breaks. The circumferential localization of the esophageal mucosal breaks at 0-1 cm from the esophagogastric junction was noted at 3 and 11 o'clock, while breaks observed at 2-3 cm from the esophagogastric junction were noted at 2 and 7 o'clock, and that observed >3 cm from the esophagogastric junction was noted at 5 o'clock.

March 2016, 404 were found to have reflux esophagitis. Of those, 398 (356 men, 42 women; mean age 53.1 years) had longitudinal esophageal mucosal breaks. In this study, a total of 625 longitudinal breaks were analyzed for their vertical and circumferential localization. The characteristics of the subjects with esophageal mucosal breaks are shown in Table. A total of 137 subjects had multiple mucosal breaks, and these subjects were predominantly men, compared with

the subjects with a single mucosal break. Anti-secretory drug use was more frequently observed in subjects with multiple mucosal breaks than in those with a single mucosal break, although the total number of subjects using anti-secretory drugs was small. In addition, a larger diaphragmatic hiatus was significantly more frequently observed in subjects with multiple mucosal breaks than in those with single mucosal break.

Table. Characteristics of Subjects with Esophageal Mucosal Injury.

	Number of mucosal injury		Mucosal breaks at least 2 cm from EGJ	
	Single	Multiple	Without	With
Gender, male/female	226/35	130/7*	330/40	26/2
Age, years	52.6±8.9	53.9±8.3	52.9±8.8	55.0±7.4
BMI	24.4±3.0	24.9±3.5	24.6±3.2	24.3±3.1
Smoking habit	67 (25.7%)	41 (29.9%)	100 (27.0%)	8 (28.6%)
Alcohol drinking habit	152 (58.2%)	88 (64.2%)	226 (61.1%)	14 (50.0%)
Anti-secretory drug use	4 (1.5%)	8 (5.8%)*	9 (2.4%)	3 (10.7%)**
Gastric mucosal atrophy				
mild	234 (89.7%)	116 (84.7%)	327 (88.4%)	23 (82.1%)
moderate	19 (7.3%)	12 (8.8%)	26 (7.0%)	5 (17.9%)
severe	8 (3.1%)	9 (6.6%)	17 (4.6%)	0
Diaphragmatic hiatus				
<1 cm	190 (72.8%)	68 (49.6%)*	246 (66.5%)	12 (42.8%)**
1-2 cm	60 (23.0%)	54 (39.4%)*	106 (28.7%)	8 (28.6%)**
>2 cm	11 (4.2%)	15 (10.9%)*	18 (4.9%)	8 (28.6%)**
Mucosal injury at right anterior wall in distal esophagus [#]	220 (68.3%)	102 (31.7%)*	306 (82.7%)	16 (57.1%)**

Values are expressed as the mean±SD. The degree of gastric mucosal atrophy was endoscopically evaluated using the classification of Kimura and Takemoto, with C1-C2 defined as mild, C3-O1 as moderate, and O2-O3 as severe gastric mucosal atrophy. [#]number of subjects with mucosal injury existed in 0-3 o'clock at 0-1 cm from ECJ.

*Statistically significant difference between subjects with single and multiple esophageal mucosal breaks. **Statistically significant difference between subjects with and without esophageal mucosal breaks at least 2 cm from esophagogastric junction.

ECJ: esophagogastric junction, BMI: body mass index, Anti-secretory drug use: subjects administered with proton pump inhibitor or H2 receptor antagonist at time of study.

The number of mucosal breaks in which the distal end was located 0-1, 1-2, 2-3, and >3 cm from the esophagogastric junction were 454, 125, 28, and 18, respectively. A total of 28 subjects had mucosal breaks at ≥2 cm from the esophagogastric junction. Of these, 4 had only mucosal breaks at ≥2 cm from the esophagogastric junction, while a mucosal break existed <2 cm from the esophagogastric junction in the other 24 cases. Subjects with mucosal breaks ≥2 cm from the esophagogastric junction tended to be older than those without such mucosal breaks. In addition, anti-secretory drug use was more frequently observed, and a larger diaphragmatic hiatus was significantly more frequent in subjects with mucosal breaks ≥2 cm from the esophagogastric junction than in those without such mucosal breaks, while the degree of gastric mucosal atrophy was not markedly different between the groups.

A large number of esophageal mucosal breaks in the subjects with a single mucosal break were located at 12-3 o'clock 0-1 cm from the esophagogastric junction. In addition, such mucosal breaks were less frequently observed in the subjects with mucosal breaks at ≥2 cm from the esophagogastric junction than in those without such breaks.

There was a marked difference in the circumferential distribution among the esophageal mucosal breaks when grouped by distance from the esophagogastric junction. Those 0-1 cm from the junction were mainly located on the

right anterior wall of the esophagus, while those 1-2 cm from the junction were mainly found on the right wall. In contrast, esophageal mucosal breaks 2-3 and >3 cm from the esophagogastric junction were mainly located on the posterior wall of the esophagus, although some were also noted on the right wall (Fig. 4).

Discussion

In the present study, we investigated the relationship between the vertical and circumferential localizations of esophageal mucosal breaks in patients with reflux esophagitis, with results showing that the distribution of those breaks was markedly different depending on the distance from the esophagogastric junction. Indeed, those near the junction were mainly found on the right anterior wall of the esophagus, whereas breaks located farther away from the esophagogastric junction tended to exist on the posterior wall of the esophagus.

The localization of dysplastic and cancerous lesions in short segment Barrett's esophagus (SSBE) has shown that they mainly exist in the right anterior wall of the lower esophagus (8-10), a location that fits with the main location of mucosal breaks associated with low-grade esophagitis (1-3). In addition, Omae et al. showed that the circumferential location of lesions fit with locations with the greatest

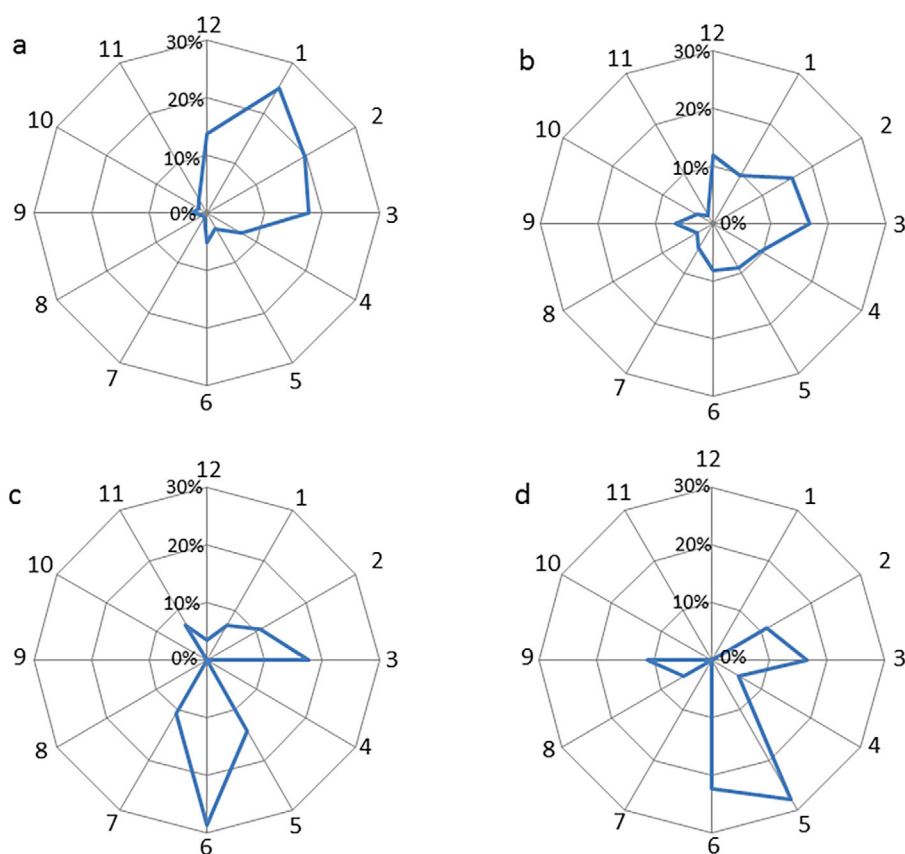


Figure 4. The circumferential distribution of the esophageal mucosal breaks at different distances from the esophagogastric junction (a: 0-1 cm, b: 1-2 cm, c: 2-3 cm, d: >3 cm).

exposure to both acidic and non-acidic refluxed gastric contents in 91% of patients with superficial Barrett's esophageal adenocarcinoma (11). Therefore, locations with high exposure to refluxed gastric contents are likely to be associated with not only the location of esophageal mucosal breaks but also the location of tumorous lesions in patients with Barrett's esophagus. In contrast to the location of tumorous lesions related to SSBE, the main circumferential location in patients with long segment Barrett's esophagus (LSBE) has not been determined. In the present study, we noted that the location of esophageal mucosal breaks tended to change from the right-anterior to the posterior side as the distance from the esophagogastric junction increased. We believe that it is important to investigate the circumferential location of LSBE tumorous lesions in a future study with a focus on the distance from the esophagogastric junction.

Our subjects with mucosal breaks at least 2 cm from the esophagi-gastric junction tended to be older than those without such mucosal breaks. It has been repeatedly shown that the prevalence of hiatal hernia increases and the esophageal motor function worsens with aging (12-14). In the present study, the diaphragmatic hiatus size in subjects with mucosal breaks ≥ 2 cm from the esophagogastric junction was larger than in those without such mucosal breaks. In addition, a larger diaphragmatic hiatus was observed significantly more frequently in subjects with multiple mucosal breaks than in those with a single mucosal break. Therefore, a large

amount of refluxed gastric acid is considered to correlate with not only the occurrence of esophageal mucosal breaks distant from the esophagogastric junction but also the formation of multiple mucosal breaks. Esophageal mucosal breaks located in the right anterior wall of the distal esophagus were frequently observed in subjects with a single mucosal break as well as in those without mucosal breaks at least 2 cm from the esophagogastric junction. Thus, esophageal mucosal breaks located in the right anterior wall of the distal esophagus might easily occur with exposure to only a small amount of refluxed gastric acid. Future studies should investigate whether or not the volume of refluxed gastric acid correlates with the vertical and circumferential localization of esophageal mucosal breaks.

This study has several limitations. Our study cohort was not representative of the general population, as they were individuals who voluntarily visited our medical center for their annual medical checkups, and the number of elderly subjects was relatively small. The prevalence of reflux esophagitis was shown to increase with aging (12-14). Therefore, an additional study is needed to confirm the relationship between the vertical and circumferential distribution of esophageal mucosal breaks in aged individuals. Furthermore, we did not perform esophageal pH monitoring to clarify the relationship between the location of esophageal mucosal breaks and areas with high levels of exposure to gastric acid. However, previous studies that used a catheter equipped with eight ra-

dially arrayed pH sensors revealed that areas highly exposed to refluxed gastric contents corresponded with the locations of esophageal mucosal breaks in patients with reflux esophagitis as well as in those with tumorous lesions associated with Barrett's esophagus (4, 11). In this study, only longitudinal mucosal breaks in cases with LA grade A and B esophagitis were analyzed, and the vertical localization of mucosal breaks was determined by the distal end of the mucosal breaks. Analyses concerning the transverse extension of mucosal breaks in cases with LA grade C and D esophagitis and the vertical length of mucosal breaks will be needed to determine the precise area highly exposed to refluxed gastric acid.

In conclusion, the present results showed that the circumferential distribution of esophageal mucosal breaks markedly differs in relation to the distance from the esophagogastric junction. Esophageal mucosal breaks near the junction were mainly found on the right anterior wall, whereas those relatively far from the junction tended to be located on the posterior wall of the esophagus.

The authors state that they have no Conflict of Interest (COI).

Acknowledgments

We wish to thank Ms. Yoko Komori, Ms. Kiyoe Kawase, Ms. Yuki Funaki, Ms. Noriko Yamauchi and Mr. Takahiro Hatanaka in Shimane Environment and Health Public Corporation, and Ms. Rika Tohma and Ms. Keiko Masuzaki in Second Department of Internal Medicine, Shimane University Faculty of Medicine for their technical support.

References

1. Katsube T, Adachi K, Furuta K, et al. Difference in localization of esophageal mucosal breaks among grades of esophagitis. *J Gastroenterol Hepatol* **21**: 1656-1659, 2006.
2. Edebo A, Vieth M, Tam W, et al. Circumferential and axial distribution of esophageal mucosal damage in reflux disease. *Dis Esophagus* **20**: 232-238, 2007.
3. Adachi K, Fujishiro H, Katsube T, et al. Predominant nocturnal acid reflux in patients with Los Angeles grade C and D reflux esophagitis. *J Gastroenterol Hepatol* **16**: 1191-1196, 2001.
4. Ohara S, Furuta K, Adachi K, et al. Radially asymmetric gastroesophageal acid reflux in the distal esophagus: examinations with novel pH sensor catheter equipped with 8 pH sensors. *J Gastroenterol* **47**: 1221-1227, 2012.
5. Kimura K, Takemoto T. An endoscopic recognition of the atrophic border and its significance in chronic gastritis. *Endoscopy* **1**: 87-97, 1969.
6. Lundell LR, Dent J, Bennett JR, et al. Endoscopic assessment of oesophagitis: clinical and functional correlates and further validation of the Los Angeles classification. *Gut* **45**: 172-180, 1999.
7. Japanese Classification of Esophageal Cancer (The 10th Edition/ Revised Version). The Japan Esophageal Society Ed. Kanehara Shuppan, Tokyo, 2008: 40-42.
8. Moriyama N, Amano Y, Okita K, Mishima Y, Ishihara S, Kinoshita Y. Localization of early-stage dysplastic Barrett's lesions in patients with short-segment Barrett's esophagus. *Am J Gastroenterol* **101**: 2666-2667, 2006.
9. Pech O, Gossner L, Manner H, et al. Prospective evaluation of the macroscopic types and location of early Barrett's neoplasia in 380 lesions. *Endoscopy* **39**: 588-593, 2007.
10. Kariyawasam VC, Bourke MJ, Hourigan LF, et al. Circumferential location predicts the risk of high-grade dysplasia and early adenocarcinoma in short-segment Barrett's esophagus. *Gastrointest Endosc* **75**: 938-944, 2012.
11. Omae M, Fujisaki J, Shimizu T, et al. Correlation of the location of superficial Barrett's esophageal adenocarcinoma (s-BEA) with the direction of gastroesophageal reflux. *Endosc Int Open* **4**: E 515-E520, 2016.
12. DeMeester TR, Lafontaine E, Joelsson BE, et al. Relationship of a hiatal hernia to the function of the body of the esophagus and the gastroesophageal junction. *J Thorac Cardiovasc Surg* **82**: 547-558, 1981.
13. Grande L, Lacima G, Ros E, et al. Deterioration of esophageal motility with age: a manometric study of 79 healthy subjects. *Am J Gastroenterol* **94**: 1795-1801, 1999.
14. Amano K, Adachi K, Katsube T, Watanabe M, Kinoshita Y. Role of hiatus hernia and gastric mucosal atrophy in the development of reflux esophagitis in the elderly. *J Gastroenterol Hepatol* **16**: 132-136, 2001.

The Internal Medicine is an Open Access journal distributed under the Creative Commons Attribution-NonCommercial-NoDerivatives 4.0 International License. To view the details of this license, please visit (<https://creativecommons.org/licenses/by-nc-nd/4.0/>).