



# Treatment of Recurrent Hemarthrosis Following Total Knee Arthroplasty Using Surgical Interventions

Keun Ho Park, MD, Dong Hwi Kim, MD\*, Se Woong Jang, MD\*, Je Hong Ryu, MD\*, Kang Yeol Ko, MD\*

*Division of Cardiology, Department of Internal Medicine, Chosun University College of Medicine, Gwangju,*

*\*Department of Orthopaedic Surgery, Chosun University College of Medicine, Gwangju, Korea*

**Background:** Recurrent hemarthrosis following total knee arthroplasty (TKA) is a rare complication. Its pathophysiology and standard treatments have not yet been established. In this study, we report 7 cases of recurrent hemarthrosis after TKA in which failure of the initial conservative treatment was followed by angiographic embolization; in 1 of the 7 cases, arthroscopic electrocauterization was also performed after treatment failure with selective embolization.

**Methods:** From January 2015 to May 2018, 7 patients visited our hospital due to recurrent hemarthrosis after TKA. Their medical records and serologic test results were reviewed to check for the presence of any bleeding disorder and history of anticoagulant use. Implant malalignment and instability were checked using X-ray. In all cases, the conservative treatment failed, so interventional angiography with selective embolization was performed, which was also followed by arthroscopic electrocauterization if the outcome was unsatisfactory.

**Results:** The interval between TKA and the onset of hemarthrosis ranged from 3 to 76 months (average, 34.1 months). There was no coagulopathy and instability. All patients underwent conservative treatment at an interval of 4.3 months and the rate of relapse was 3.1 on average. On the interventional angiography, 6 cases showed vascular blush, and 1 case had pulsatile bleeding. The average duration for interventional angiography was 90.9 minutes. The average length of follow-up was 38.8 months. Embolization was successfully performed in 4 cases. In 2 of 3 failed cases, the symptoms improved without further treatment. In the remaining 1 failed case, the patient had a relapse of hemarthrosis, so an arthroscopic procedure was performed, which led to identification of the suspicious bleeding point by using preoperative angiographic findings. Electrocauterization was performed and active bleeding was stopped. All cases with recurrent hemarthrosis achieved improvement.

**Conclusions:** Interventional angiography was used to aid in the diagnosis of recurrent hemarthrosis, and therapeutic selective embolization provided satisfactory clinical results. Even if selective embolization fails, interventional angiography may be helpful for further surgical procedures because it reveals vascular blush of a bleeding site. Therefore, interventional angiography and selective embolization should be considered to be a useful treatment for recurrent hemarthrosis after TKA.

**Keywords:** Hemarthrosis, Total knee arthroplasty, Angiography, Embolization

Received April 2, 2020; Revised June 1, 2020;

Accepted July 7, 2020

Correspondence to: Dong Hwi Kim, MD

Department of Orthopaedic Surgery, Chosun University Hospital, 365

Pilmun-daero, Dong-gu, Gwangju 61453, Korea

Tel: +82-62-220-3147, Fax: +82-62-226-3379

E-mail: oskdh@chosun.ac.kr

Recurrent hemarthrosis following total knee arthroplasty (TKA) is a rare complication, which has a low incidence rate of 0.3% to 0.65%.<sup>1-3)</sup> The number of reported cases of recurrent hemarthrosis in Korea is not abundant and there is no standard treatment for it. It has been reported that the interval between surgery and onset of hemarthrosis is so various that it ranges from 2 weeks to 12 years (2 years on average).<sup>4)</sup> Symptoms of hemarthrosis include abrupt pain and swelling of the knee with some limited range of

motion without traumatic events. Recurrent hemarthrosis can cause joint stiffness, poor postoperative function, and deep joint sepsis.<sup>5)</sup> Thus, appropriate and effective treatment is desired. It has been reported that the disease is attributable to hypervascular hypertrophied synovium, impingement of the hypertrophied synovium between the femoral and tibial components, arteriovenous fistula, pseudoaneurysm, pigmented villonodular synovitis,<sup>6)</sup> coagulopathy, anticoagulant therapy, implant malalignment or instability, and trauma.<sup>2-7)</sup> However, in some cases, the cause is uncertain. Joint fluid aspiration can be useful for identifying and diagnosing hemarthrosis, by which infection or inflammatory arthritis can be ruled out. The diagnosis of hemarthrosis is possible with symptoms and joint fluid aspiration. Recurrent hemarthrosis can be treated conservatively (joint aspiration, compression, icing, and rest by splint) or surgically (interventional angiographic embolization, radiosynovectomy, and arthroscopic/open synovectomy).<sup>3,7)</sup> However, a standard treatment method has not yet been identified. Interventional angiography was used to aid in diagnosing the disease, and therapeutic selective embolization was performed with satisfactory clinical results.<sup>7,8)</sup> Selective embolization would likely be the treatment of choice when conservative measures fail and can be repeated in the event of recurrent or persistent symptoms.<sup>9)</sup> In this study, we report 7 cases of recurrent hemarthrosis following TKA, in which conservative treatment failed and angiographic embolization was performed for treatment. We also report 1 case of arthroscopic electrocauterization, which was performed after treatment failed with selective embolization.

## METHODS

From January 2015 to May 2018, 7 patients (1 man and 6 women; age range, 60–82 years) visited our hospital due to spontaneous recurrent hemarthrosis following TKA. All the patients underwent TKA at other clinics. The interval between TKA and the onset of hemarthrosis ranged from 3 to 76 months (Table 1).

Hemarthrosis was diagnosed on the basis of the medical records from other hospitals, patient's symptoms, and joint aspiration. We were able to rule out infections or inflammatory arthritis through joint fluid analysis and serologic tests including erythrocyte sedimentation rate (ESR) and C-reactive protein (CRP). We also reviewed the patient's medical history and serologic tests including prothrombin time (PT) and activated partial thromboplastin time (aPTT) to identify the presence of bleeding disorder. In addition to reviewing their use of anticoagulants, we checked implant loosening, osteolysis, and implant failure with knee X-ray (anteroposterior view, lateral view, Rosenberg view, and varus/valgus stress view). To check for implant malalignment and instability, the hip-knee-ankle angle and joint gap were assessed in the whole leg view and varus/valgus stress view. Varus/valgus stress tests were performed as part of the clinical examination to assess the medial and lateral laxity of the knee in full extension. Patients with mild, moderate, and marked medial/lateral laxity demonstrated 5, 5–10, and 10 mm translation, respectively, on the varus/valgus stress view.<sup>10,11)</sup>

First, we provided conservative treatment (joint aspiration, compression, icing, rest by splint, and discontinuation of medication such as anticoagulants and antiplatelet

**Table 1.** Characteristics of Seven Patients Who Underwent Angiographic Embolization Procedures for Recurrent Hemarthrosis Following TKA

Patient no.	Sex	Age (yr)	Trauma history	Anticoagulant or antiplatelet	Coagulopathy	Past history	Implant type	Duration between TKA and hemarthrosis (mo)	Recurrence (times)
1	F	67	None	-	None	-	CR fixed	19	3
2	F	73	None	-	None	-	CR fixed	13	2
3	F	60	None	Aspirin	None	HTN DM	CR fixed	3	3
4	F	82	None	-	None	-	CR fixed	71	2
5	F	79	None	Lixiana (Xa inhibitor) Pletaal	None	Old CVA aortic-dissection A-fib	PS fixed	9	2
6	F	65	None	Aspirin	None	HTN	CR fixed	76	2
7	M	73	None	-	None	HTN	PS fixed	48	8
Average		71.3						34.1	3.1

TKA: total knee arthroplasty, CR: cruciate-retaining, HTN: hypertension, DM: diabetes mellitus, CVA: cerebrovascular attack, PS: posterior-stabilized.

drugs) to all patients with recurrent hemarthrosis, including repeated joint aspiration. When there was no response to two or more of the conservative treatment methods, interventional angiography was performed to diagnose, and selective embolization was performed to control bleeding. When that also failed, arthroscopic electrocauterization was performed. The interventional angiography was performed by an experienced cardiologist (KHP) using 5 Fr Torcon NB Advantage Catheter (Cook Medical Korea, Seoul, Korea), 1.8 Fr Artec microcatheter (Dalian Create Medical, Dalian, China), and EGgel S PLUS 350–560  $\mu\text{m}$  (Gelatin microparticle embolic agent, Engain, Seungnam, Korea). This study was approved by the Institutional Review Board of Chosun University Hospital (IRB No. 2020-03-018) and informed consent was waived due to retrospective nature of this study.

## RESULTS

There was no coagulopathy in all cases. On the review of the use of anticoagulants, 2 patients received only antiplatelet therapy and 1 patient received antiplatelet and anticoagulant therapy. These 3 patients who received anticoagulant or antiplatelet therapy did not respond to conservative treatment despite discontinuation of the anticoagulant therapy and hemarthrosis was persistent. All patients underwent conservative treatment for 4.3 months on average (range, 1–10 months), the average number of recurrence of hemarthrosis was 3.1 (range, 2–8). In all cases, there was no response to two or more conservative treatments (Table 1). There were no implant loosening, malalignment, and migration on the radiologic study.

From the varus/valgus stress view, mild laxity was observed in 2 cases, but no marked laxity was noted.

Interventional angiography and selective embolization were performed by the cardiologist (KHP). With interventional angiography, 6 cases of pathologic vascular blush and 1 case of pulsatile bleeding (Table 2) were identified. Of the total 7 cases, 4 cases demonstrated the bleeding focus (3 in the inferior lateral genicular artery and 1 in the middle genicular artery) and selective embolization contributed to successful hemostasis. In the remaining 3 cases, the bleeding focus was all suspected to be in the inferior lateral genicular artery, but selective embolization failed due to an overlap between the entry of the selected branch and the femoral component. The mean operation time for interventional angiography and selective embolization was 90.9 minutes (range, 58–142 minutes). Two out of the 3 failed cases showed improvement after angiography without further treatment. In the remaining 1 case of failed embolization, an arthroscopic procedure was performed to identify and treat the bleeding source. Patients were contacted by telephone in March 2020 to retrieve information on recovery or late complications. There were no recurrences or complications. The mean duration of follow-up after the last embolization or operation was 38.8 months (range, 23–63 months) (Table 2).

### Case 1

A 60-year-old female patient (patient no. 3 in Table 1) who underwent right TKA for osteoarthritis at another hospital in January 2016 was in the course of follow-up. In May 2016, she came to our hospital due to persistent hemarthrosis accompanied by abrupt pain and swelling without

**Table 2.** Interventional Data

Patient no.	Conservative period (mo)	Intervention time (min)	Bleeding site	Intervention finding and result	Surgical treatment	Duration of FU (mo)	Complication recurrence after procedure*
1	10	142	Inf lat	Vascular blush fail	-	63	None
2	1	58	Inf lat	Vascular blush fail	-	52	None
3	9	58	Inf lat	Vascular blush success	-	39	None
4	3	70	Inf lat	Vascular blush success	-	38	None
5	1	75	Middle	Active pumping success	-	31	None
6	3	102	Inf lat	Vascular blush success	-	26	None
7	4	88	Inf lat	Vascular blush fail	AS	23	None
Average	4.3	90.9				38.8	

FU: follow-up, Inf lat: inferior lateral genicular artery, Middle: middle genicular artery, AS: arthroscopy.

\*Interventional angiography or surgical treatment.

trauma after having received joint aspiration three times at the other clinic.

She stopped taking prophylactic aspirin for hypertension before presenting to our hospital. There was no evidence of bleeding tendency or infection on the serologic test. At the time of admission, the range of joint motion was restricted to 5°–100°, which was accompanied by pain. There was no loosening or malalignment of the prosthesis on simple radiographs. As the joint effusion decreased, we decided to proceed with conservative treatment such as icing and rest by splint. However, 8 months later (January 2017), she had to be hospitalized for recurrent hemarthrosis and, in turn, interventional angiography was performed.

In the interventional angiography, the vascular blush pattern was observed in the inferior lateral genicular artery, which was confirmed as a bleeding site. So selective embolization was performed using EGgel S PLUS 350–560  $\mu\text{m}$ . After selective embolization, the vascular blush was lost in the contrast image and was no longer observed (Fig. 1). After the procedure, the patient was immobilized by long leg splinting during 4 days of hospitalization period. There was no recurrence of hemarthrosis until 39 months after the last follow-up.

### Case 2

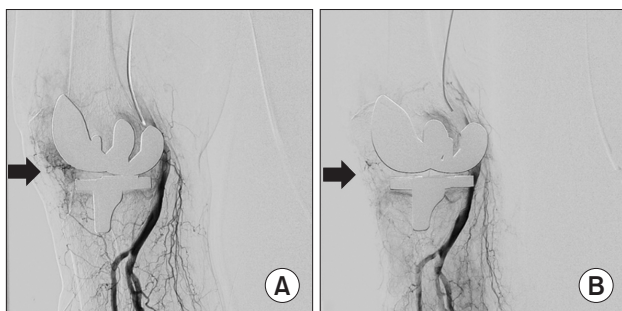
A 79-year-old woman (patient no. 5 in Table 1) who underwent left TKA for osteoarthritis at another hospital 9 months ago visited the emergency room with abrupt pain and swelling, which occurred after excessive knee flexion without any other trauma. At the time of admission, the range of motion of the knee joint was limited to 10°–30° with pain and severe swelling, and hemarthrosis of roughly 100 cc was identified through joint aspiration. There was no bacterial growth in culture. There was no

loosening or malalignment of the prosthesis on simple radiographs. The serologic test showed a slight prolongation of PT and international normalized ratio (INR): PT and aPTT were 15.6 and 31.1, respectively (normal range, 9.4–12.5 and 28.0–44.0, respectively) and INR was 1.38 (normal range, 0.9–1.27). In addition to hypertension and atrial fibrillation, the patient had a history of aortic replacement due to aortic dissection and cardiac tamponade 6 months ago. So, she took the factor Xa inhibitor, Lixiana (Daiichi Sankyo Korea, Seoul, Korea) and Pletaal (Korea Otsuka Pharmaceutical, Seoul, Korea). Because it was the first onset, we decided to perform conservative treatment (joint aspiration, rest by splint, and icing) and the symptoms improved. After 1 month, the patient revisited the emergency room due to severe knee pain and swelling with flexion contracture of 45°. In joint aspiration, 50 mL blood was punctured. Also, there was no bacterial growth in culture and the serologic tests showed a slight prolongation of PT and INR: PT and aPTT were 15.9 and 31.1, respectively and INR was 1.41. Interventional angiography was performed under the diagnosis of refractory hemarthrosis not responding to conservative treatment.

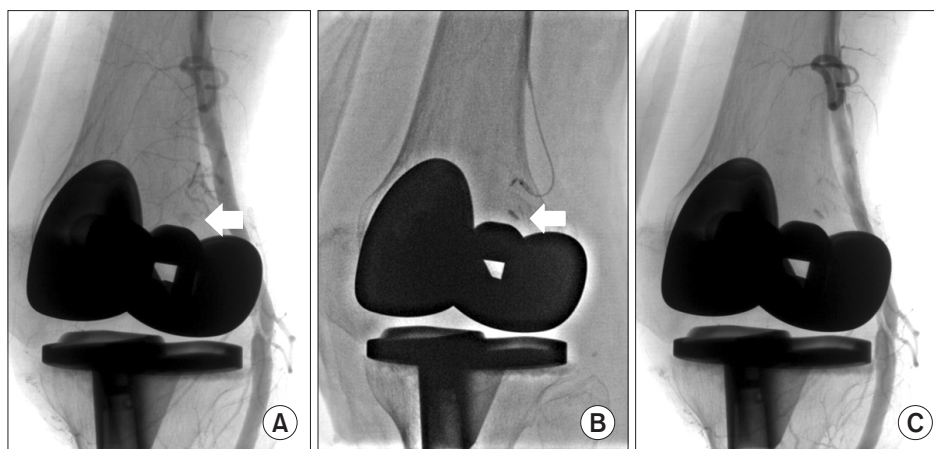
On the interventional angiography, the pulsatile active bleeding focus was identified in the terminal branch of the middle genicular artery in the posterosuperior aspect of the knee joint and this site was confirmed as a bleeding site. So selective embolization was performed using EGgel S PLUS 350–560  $\mu\text{m}$ . After embolization, further pulsatile bleeding was not observed in contrast imaging (Fig. 2). After selective embolization, symptoms improved. Lixiana, a factor Xa inhibitor, was discontinued until symptoms improved and Pletaal was maintained in consultation with the Cardiology department. The patient was treated with a drug regimen in consultation with the Cardiology department during the follow-up period of 31 months without recurrence of hemarthrosis.

### Case 3

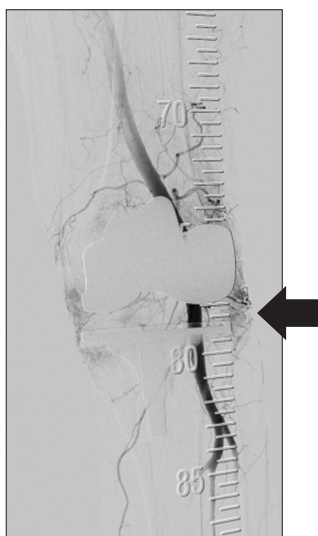
A 73-year-old man (patient no. 7 in Table 1) underwent left TKA at another hospital 4 years ago and synovectomy due to infection 9 months after the surgery. Afterwards, the patient had no problems. But he visited our hospital because of repeated pain and swelling that had been persistent despite eight times of joint aspiration at the other local hospital 4 months ago. There was no specific bleeding tendency on the serologic test and he had no history of anticoagulant medication use. There was no loosening or malalignment of the prosthesis on simple radiographs. We diagnosed the patient as having refractory hemarthrosis because he did not respond to conservative treatments



**Fig. 1.** (A) Interventional angiography demonstrating vascular blush with haziness in the right inferior lateral genicular artery (arrow). (B) Selective embolization using Gel-foam led to the immediate absence of the vascular blush and resolution of haziness.



**Fig. 2.** (A) Pulsatile active bleeding was observed in the terminal branch of the middle genicular artery connected to the posterior superior aspect of the knee joint (arrow). (B) Selective embolization using Gel-foam was performed for the terminal branch of the middle genicular artery (arrow). (C) After selective embolization of the middle genicular artery, active bleeding stopped.



**Fig. 3.** In angiography, vascular blush was observed in the left inferior lateral genicular artery (arrow).

with eight times of repetitive joint aspiration.

Interventional angiography was performed, and the vascular blush pattern was observed in the inferior lateral genicular artery, which was confirmed as a bleeding site, so selective embolization was performed (Fig. 3). However, selective embolization to the inferior lateral genicular artery failed due to the overlap between the entry of the selecting branch and the femoral component. So, we diagnosed it as refractory hemarthrosis and planned an arthroscopic procedure to identify and treat the bleeding sites.

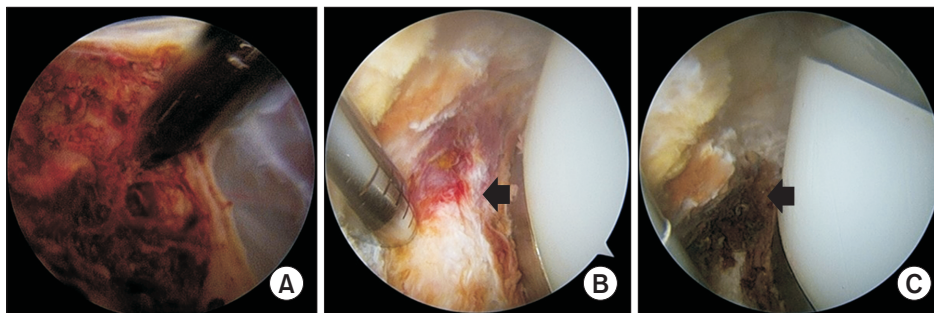
The arthroscopic procedure was performed. Even

though the pigmented hypertrophic synovium covered all areas of the joint, it was not an active bleeding site. Based on preoperative angiographic findings, we checked the posterolateral corner between the lateral aspect of the tibial component and the capsule in front of the popliteus tendon using the posteromedial viewing portal, and the suspicious bleeding site of the inferior lateral genicular artery was found. Despite the use of a tourniquet, compared with darkly pigmented synovium, there was a fresh distinctive bleeding point. Electrocauterization was performed using Arthrocare (Smith & Nephew, ArthroCare, Austin, TX, USA) on the inferior lateral genicular artery. After this procedure, active bleeding stopped (Fig. 4). The patient gradually showed progressive improvement of symptoms, and hemarthrosis no longer occurred until 23 months after the last follow-up.

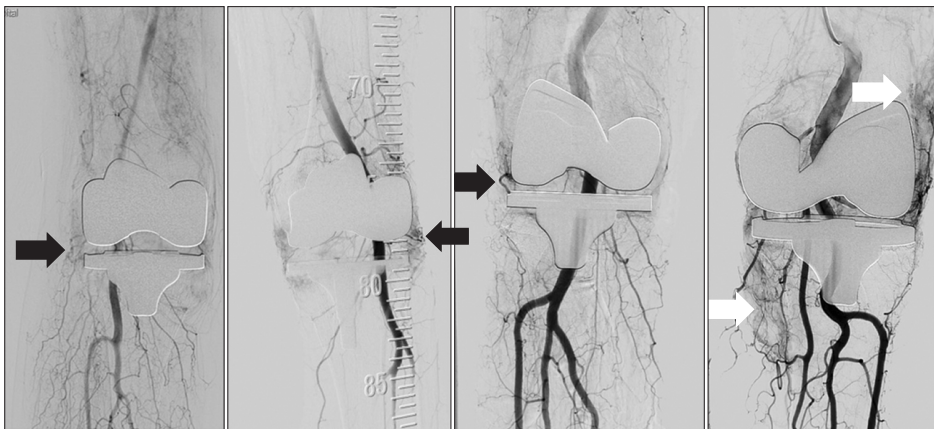
## DISCUSSION

In this study, interventional angiography was performed in all cases of recurrent hemarthrosis, which had developed in 7 patients who did not respond to conservative treatment following TKA at other hospitals. For recurrent hemarthrosis refractory to conservative treatment, angiography has been used as a first-line procedure to diagnose and then proceed with treatment.<sup>2)</sup>

Nine out of 30 patients in a study by Kindsfater and Scott<sup>4)</sup>, 3 out of 10 patients in a study by Ohdera et al.,<sup>1)</sup> and 14 out of 17 patients in a study by Yoo et al.<sup>3)</sup> were all reported to show improvement through conservative treatment. In our study, patients who had shown improvement after conservative treatment were not included, but



**Fig. 4.** (A) Hemisiderin pigmented hypertrophic synovium was observed, but there were no active bleeding sites. (B) We tried to find a suspicious bleeding point in preoperative angiography. To check the inferior lateral genicular artery by arthroscopy, a posteromedial viewing portal was used and the posterolateral corner was observed through a transseptal portal with a 70° scope (black arrow). (C) After cauterization using Arthrocare, active bleeding stopped (black arrow).



**Fig. 5.** In general, there are several areas of vascular blush on interventional angiography in patients with recurrent hemarthrosis after total knee arthroplasty, but we approached the vascular blush around the joint as the main focus of hemarthrosis. Black arrows: blush around the intra-articular area, White arrows: blush in the extra-articular area.

2 out of 3 patients in whom angiographic embolization failed showed improvement with conservative treatment.

In general, there are several areas of vascular blush on interventional angiography in patients with recurrent hemarthrosis following TKA. Kindsfater and Scott<sup>4)</sup> reported that 9 of 21 patients appeared to have a piece of synovial tissue or fat pad, which was pinched in the patellofemoral joint or femorotibial joint. So, we considered vascular blush around the joint as the main focus of hemarthrosis (Fig. 5). In 6 cases, the bleeding focus was located in the inferior lateral genicular artery, and in 1 case, it was in the middle genicular artery. Judging from these findings, the bleeding focus appears to be concentrated in the inferior lateral genicular artery and it seems to be the most common cause of bleeding focus. The inferior genicular arteries lie between the capsule and the heads of gastrocnemii and are at risk during retraction and subperiosteal release of the relevant structures during ligament balancing. When excising the menisci, the blade should be kept parallel to the posterior margin of the tibia to avoid damage to the major vascular structures.<sup>2,12,13)</sup> Statz et al.<sup>14)</sup> reported the overall rate of genicular artery injury was 38%,

with lateral inferior and middle genicular artery injury accounting for 31% and 15% of TKA, respectively. Therefore, there is a high probability that the inferior genicular artery may be damaged during TKA. However, according to previous papers reviewed by Yoo et al.<sup>3)</sup>, the most common source of bleeding confirmed with angiography is the superior lateral geniculate artery, followed by the superior medial geniculate artery and the inferior lateral geniculate artery.<sup>8,15-18)</sup> So, further studies are needed to determine which genicular artery is actually at high risk of injury in patients with hemarthrosis.

In all cases, selective embolization of vascular blush around the joint was performed but it resulted in treatment failure in 3 cases. The cause of the failure was considered to be an overlap between the entry of the selecting branch and the femoral component, so the end artery could not be found and selected.

In the literature, most of the recurrent hemarthrosis cases showed a vascular blush pattern on interventional angiography. In our study, pathologic vascular blush was identified in 6 cases, but active pulsatile bleeding was confirmed by angiography in 1 case. In the interventional an-

giography of recurrent hemarthrosis, active pulsatile patterns were rarely observed, but good results were obtained through selective embolization.

Two of the 3 failure cases did not receive any other treatment but obtained improvement after angiography. Although the embolization was unsuccessful, it seems to have improved with conservative treatment. In the remaining 1 failure case, we planned the surgery because hemarthrosis recurred several times and we could find the suspicious site of bleeding in interventional angiography. During the arthroscopic procedure, the bleeding focus at the previously suspected site based on angiographic findings was found by intensive observation, and improvement was obtained after electrocauterization. Synovium, which has been identified as the cause of spontaneous hemarthrosis in several previous papers, was not an active bleeding site in our case despite the dark pigment change. Despite the use of a tourniquet, unlike other sites, there was fresh bleeding at the site where bleeding was suspected. At the end of follow-up, 6 of the 7 patients were asymptomatic but 1 patient complained of mild pain without any problem in daily activities.

Synovectomy is recommended for recurrent hemarthrosis that does not resolve after conservative treatment.<sup>19)</sup> However, synovectomy exposes the patient to the risk of complications and morbidity associated with repeated surgery, such as loss of function and infection. In contrast, embolization can be repeated in the event of recurrent or persistent symptoms,<sup>9)</sup> so interventional angiography is less invasive and causes less morbidity. The advantages of interventional angiography are that it cannot only be used for diagnosing bleeding sites that appear to be vascular blushing on the image but also help in establishing a surgical plan based on the detected bleeding site even if selective embolization fails. As a result, it allows for a relatively easy and quick approach to the bleeding site at the time of surgery to enable successful treatment.

Computed tomography (CT) angiography is thought to be a diagnostic tool that can identify the cause of hemarthrosis including tumor and vascular injury. So, we performed CT angiography before interventional angiography in an attempt to find the bleeding site, but it was not helpful due to the interference effect of the CT artifact by the knee prosthesis and small-sized blood vessels where the actual hemorrhage site was located. However, it was confirmed that there were no arteriovenous malformations or pseudoaneurysms on CT angiography.

Inflammatory markers were elevated in 1 patient: ESR was 38 (normal range, 0–30), CRP was 1.24 (normal range, 0–0.3), the synovial white blood cell count was 5,097 (over 3,000), and synovial polymorphonuclear was 76.1%

(under 80%) in the joint fluid analysis. According to the Musculoskeletal Infection Society (MSIS) 2018 criteria for periprosthetic joint infection (PJI),<sup>20)</sup> it should have been diagnosed as PJI. In another patient, CRP was 3.15 and the other markers were within normal. According to the MSIS criteria, it indicated possible infection. But these patients did not have evidence of infection such as erythema, warmth on physical examination, and growth in joint fluid culture. Therefore, we recommend differential diagnosis and caution for infection.

Impingement of the hypertrophied synovium between the femoral and tibial components is one of the most common causes of recurrent hemarthrosis.<sup>4)</sup> We expected that mobile-bearing TKA would be more associated with impingement of the synovium between the femoral or tibial component and liner than fixed-bearing TKA. However, in this study, there was no case of mobile-bearing TKA. This is thought to be because fixed-bearing TKA is more commonly performed than mobile-bearing TKA and the number of cases in this study is small. Huang et al.<sup>21)</sup> reported a case of hemarthrosis following fracture of the polyethylene in a mobile meniscal bearing knee replacement, and to the best of our knowledge, there has been no article comparing mobile-bearing TKA and fixed-bearing TKA for impingement of the synovium.

Our study is limited by the small sample size, retrospective study design, and the lack of comparison of different treatment methods and clear treatment protocol. In particular, the indication for interventional angiography was not clearly identified because discomfort and pain are subjective symptoms of recurrent hemarthrosis and patients required different periods of conservative treatment for improvement. If there was no response to two or more conservative treatment, interventional angiography can be used for diagnosis and treatment. We also could not confirm why the bleeding focus was located in the inferior lateral genicular artery and why recurrent hemarthrosis occurred more frequently in the fixed-bearing than mobile-bearing bearing TKA. However, we believe that conservative treatment, interventional angiography, and arthroscopic procedure can all be effective for the treatment of recurrent hemarthrosis.

Interventional angiography was used to aid in the diagnosis of recurrent hemarthrosis, and therapeutic selective embolization provided satisfactory clinical results. Even if selective embolization fails, interventional angiography may be helpful for further surgical procedures because it reveals vascular blush at the bleeding site. Therefore, interventional angiography and selective embolization can be considered to be a useful treatment for recurrent hemarthrosis after TKA.

## CONFLICT OF INTEREST

No potential conflict of interest relevant to this article was reported.

## ACKNOWLEDGEMENTS

This study was supported by research fund from Chosun University Hospital, 2018.

## ORCID

Keun Ho Park <https://orcid.org/0000-0002-2303-4954>  
 Dong Hwi Kim <https://orcid.org/0000-0001-7011-8504>  
 Se Woong Jang <https://orcid.org/0000-0002-1136-9503>  
 Je Hong Ryu <https://orcid.org/0000-0002-8794-6194>  
 Kang Yeol Ko <https://orcid.org/0000-0002-8366-0287>

## REFERENCES

- Ohdera T, Tokunaga M, Hiroshima S, Yoshimoto E, Matsuda S. Recurrent hemarthrosis after knee joint arthroplasty: etiology and treatment. *J Arthroplasty*. 2004;19(2):157-61.
- Saksena J, Platts AD, Dowd GS. Recurrent haemarthrosis following total knee replacement. *Knee*. 2010;17(1):7-14.
- Yoo JH, Oh HC, Park SH, Lee S, Lee Y, Kim SH. Treatment of recurrent hemarthrosis after total knee arthroplasty. *Knee Surg Relat Res*. 2018;30(2):147-52.
- Kindsfater K, Scott R. Recurrent hemarthrosis after total knee arthroplasty. *J Arthroplasty*. 1995;10 Suppl:S52-5.
- Sharma H, Singh GK, Cavanagh SP, Kay D. Pseudoaneurysm of the inferior medial geniculate artery following primary total knee arthroplasty: delayed presentation with recurrent haemorrhagic episodes. *Knee Surg Sports Traumatol Arthrosc*. 2006;14(2):153-5.
- Hamlin BR, Duffy GP, Trousdale RT, Morrey BF. Total knee arthroplasty in patients who have pigmented villonodular synovitis. *J Bone Joint Surg Am*. 1998;80(1):76-82.
- Kapetanios GA, Papavasiliou KA, Makris V, Nikolaidis AP, Kirkos JM, Symeonides PP. Recurrent spontaneous hemarthrosis after total knee arthroplasty successfully treated with synoviorrhesis. *J Arthroplasty*. 2008;23(6):931-3.
- Katsimihas M, Robinson D, Thornton M, Langkamer VG. Therapeutic embolization of the genicular arteries for recurrent hemarthrosis after total knee arthroplasty. *J Arthroplasty*. 2001;16(7):935-7.
- van Baardewijk LJ, Hoogeveen YL, van der Geest IC, Schultze Kool LJ. Embolization of the geniculate arteries is an effective treatment of recurrent hemarthrosis following total knee arthroplasty that can be safely repeated. *J Arthroplasty*. 2018;33(4):1177-80.e1.
- Worland RL, Jessup DE, Johnson J. Posterior cruciate recession in total knee arthroplasty. *J Arthroplasty*. 1997;12(1):70-3.
- Pang HN, Yeo SJ, Chong HC, Chin PL, Ong J, Lo NN. Computer-assisted gap balancing technique improves outcome in total knee arthroplasty, compared with conventional measured resection technique. *Knee Surg Sports Traumatol Arthrosc*. 2011;19(9):1496-503.
- Dennis DA, Neumann RD, Toma P, Rosenberg G, Mallory TH. Arteriovenous fistula with false aneurysm of the inferior medial geniculate artery: a complication of total knee arthroplasty. *Clin Orthop Relat Res*. 1987;222:255-60.
- Langkamer VG. Local vascular complications after knee replacement: a review with illustrative case reports. *Knee*. 2001;8(4):259-64.
- Statz JM, Ledford CK, Chalmers BP, Taunton MJ, Mabry TM, Trousdale RT. Geniculate artery injury during primary total knee arthroplasty. *Am J Orthop (Belle Mead NJ)*. 2018;47(10).
- Cunningham RB, Mariani EM. Spontaneous hemarthrosis 6 years after total knee arthroplasty. *J Arthroplasty*. 2001;16(1):133-5.
- Maheshwari R, Kelley SP, Langkamer VG, Loveday E. Spontaneous recurrent haemarthrosis following unicompartmental knee arthroplasty and its successful treatment by coil embolisation. *Knee*. 2004;11(5):413-5.
- Rukavina A, Kerkhoffs GM, Schneider P, Kuster MS. Recurrent hemarthrosis after total knee arthroplasty. *Knee Surg Sports Traumatol Arthrosc*. 2010;18(7):898-900.
- Weidner ZD, Hamilton WG, Smirniotopoulos J, Bagla S. Recurrent Hemarthrosis Following Knee Arthroplasty Treated with Arterial Embolization. *J Arthroplasty*. 2015;30(11):2004-7.
- Oishi CS, Elliott ML, Colwell CW Jr. Recurrent hemarthrosis following a total knee arthroplasty. *J Arthroplasty*. 1995;10 Suppl 1:S56-8.
- Parvizi J, Tan TL, Goswami K, et al. The 2018 definition of periprosthetic hip and knee infection: an evidence-based and validated criteria. *J Arthroplasty*. 2018;33(5):1309-14.e2.
- Huang CH, Ho FY, Cheng CT, Ma HM. Hemarthrosis associated with failure of a mobile meniscal-bearing total knee arthroplasty: a case report. *J Bone Joint Surg Am*. 2003;85(12):2445-8.