

Asymptomatic hypernatremia in an infant with midline defects

Sangeetha Geminiganesan, Padmasani Venkat Ramanan, Dhivyalakshmi J.,
Bhogavalli Lakshmi Harshita, Deepalakshmi Sriram

*Department of Paediatric Medicine, Sri Ramachandra Institute of Higher Education and Research,
Porur, Chennai, India*

ARTICLE INFO

Corresponding author:

Sangeetha Geminiganesan
Assistant Professor
Department of Paediatric Medicine
and Division of Paediatric Nephrology
Sri Ramachandra Institute
of Higher Education and Research
Chennai
India
E-mail: sangeethaperungo@gmail.com

Key words:

holoprosencephaly, hypernatremia,
diabetes insipidus, desmopressin

ABSTRACT

Holoprosencephaly is a developmental abnormality caused due to incomplete cleavage of the rostral neural tube (basal forebrain) structures during early embryogenesis. This defect causes incomplete separation of the right and left cerebral hemispheres. Children manifest a wide spectrum of clinical manifestations, the extent of which depends upon the degree of hemispheric nonseparation. We describe an infant with midline cleft referred for preoperative evaluation in whom, asymptomatic electrolyte abnormalities and holoprosencephaly were identified. On further evaluation, the infant was diagnosed to have isolated central diabetes insipidus and she responded well to oral desmopressin therapy.

Cleft lip and palate is one of the commonest congenital malformations and midline clefts are likely to be associated with significant pituitary abnormalities. Awareness about the syndromic associations with

clefts and the associated anomalies are important for early diagnosis and intervention in these children.



INTRODUCTION

Holoprosencephaly (HPE) is a developmental malformation of the forebrain with defective midline cleavage of the cerebral hemispheres. The incidence of HPE is estimated to be 1 in 250 during early embryonic development, and 1 in 16,000 live births [1]. Midline craniofacial clefts and hypothalamic/pituitary dysfunction are commonly associated with HPE [2]. We report a 4½ months-old girl, with a midline cleft, who was found to have severe hypernatremia and polyuria on pre-operative evaluation. Investigations revealed semi-lobar HPE and central diabetes insipidus (DI). She responded well to oral desmopressin.

CASE DETAILS

A 4½ months-old girl with midline cleft lip and palate was referred to Pediatrics for preoperative evaluation prior to corrective surgery. She was the second child of a non-consanguineous marriage with an uneventful antenatal history. She was delivered by caesarean section at 36th week of gestation with a birth weight of 2 kg. In view of the midline cleft, she was started on oro-gastric feeding (through Ryle's tube), with expressed breast milk and preterm infant formula. There was no family history of a similar illness.

On examination, she had median cleft lip and palate, depressed nasal bridge, cranio-synostosis, microcephaly (31.5cm), hypotonia of all four limbs and global developmental delay with a developmental age of only 6 weeks. Her length (54 cm) and weight (4 Kg) for age Z scores were less than -3 (WHO 2006 charts).

On investigation, her complete blood count, blood sugar, renal and liver function tests were normal. Serum electrolytes which were done as a part of routine preoperative evaluation revealed hypernatremia (158mmol/L) and hyperchloremia (129mmol/L). She was on preterm formula feeds (34mg/dL sodium in 100ml feed) and on further probing, mother revealed that she was adding a pinch of salt with each feed. She was asked to stop adding salt. The baby was initiated on a term infant milk formula with a lower sodium content (16mg/dL sodium in 100ml feed).

In spite of these changes the child had worsening of hypernatremia (167mmol/L) and there was no weight gain. On questioning, the mother also reported frequent passage of urine but there were no obvious signs of dehydration. Diabetes mellitus, urinary tract infection, hypercalcaemia, hypokalaemia, renal failure and thyrotoxicosis were ruled out. Diabetes insipidus was suspected. Urine output was monitored by catheterization and it ranged from 6 ml/kg/hr to 9 ml/kg/hr. Increased serum osmolality of 308mOsm/kg (normal: 285-295mOsm/kg) with a low urine osmolality 160 mOsm/kg (50-1200mOsm/kg) was noted.

The serum and urine osmolality were calculated by the laboratory analyzer which is pre-programmed with the formula.

$$\text{Serum osmolality} = \text{Serum sodium} \times 2 + \frac{\text{Blood glucose}}{18} + \frac{\text{Blood urea nitrogen}}{2.8}$$

$$\text{Urine osmolality} = \text{Urine potassium} \times 2 + \frac{\text{Urine glucose}}{18} + \frac{\text{Urine urea nitrogen}}{2.8}$$

Serum electrolytes were measured by indirect ion selective electrodes, blood urea by urease UV, and blood glucose by hexokinase method.

As the serum osmolality was >300mOsm/kg and urine osmolality less than the serum osmolality, water deprivation test was deferred and

subcutaneous vasopressin was given at a dose of 2 microgram. Doubling of urine osmolality (160mOsmol/kg to 369mOsmol/kg), fall in serum sodium from 168 to 160mmol/L and reduction in urine output from 9ml/kg/hour to 4ml/kg/hour were observed (Table 1).

MRI brain and pituitary revealed “semi-lobar holoprosencephaly”, anatomically normal anterior pituitary with “absent pituitary bright spot” and “olfactory bulb agenesis” (Fig 1). Anterior pituitary hormonal evaluations were within normal limits. Echocardiogram and ultrasound abdomen were normal.

The child was started on oral desmopressin 10 mcg per day. Oral feeds were initiated and gradually shifted to semisolid feeds (Energy–531kcal and Protein 11.5g/ day). Eventually, serum sodium normalized and she started gaining weight. Her discharge weight was 4.35kg and serum sodium was 145 mmol/L. Genetic testing has been suggested on follow up.

DISCUSSION

Holoprosencephaly (HPE) is a complex developmental anomaly of the brain characterized by failure of the embryonic forebrain (prosencephalon) to divide into two distinct cerebral hemispheres, a process normally completed by 5th week of gestation. The etiology is multifactorial and includes genetic and environmental factors. Chromosomal abnormalities (cytogenetic abnormality of chromosome 13 and 18) and single gene disorders have been identified [3] and the common environmental risk factors include maternal smoking, alcoholism, maternal diabetes, and prenatal exposure to certain drugs [4].

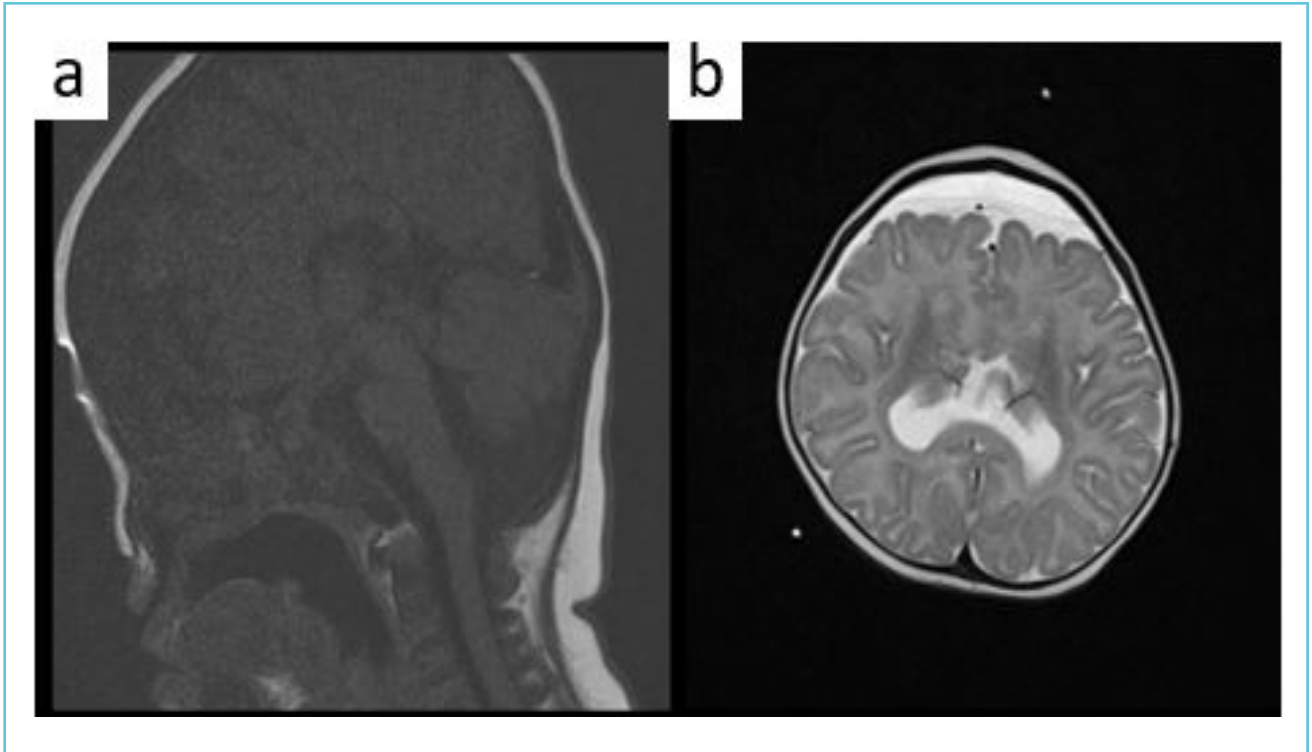
Holoprosencephaly is frequently associated with craniofacial (80%) and hypothalamic/pituitary abnormalities causing central DI in 70% [5,6].

Diabetes insipidus is characterized by polyuria (urine output >4ml/kg/hour in children and >6ml/kg/hour in infancy) and polydipsia.

Table 1 Serial investigations during the hospitalization

	Baseline	Post vasopressin challenge	At discharge
Fluid intake	1150ml/day	Nil oral	90ml/3rd hourly through nasogastric feed with demand paladai feeds
Urine output	9ml/kg/hr	4ml/kg/hr	3.2ml/kg/hr
Serum sodium	158mmol/L	154mmol/L	148
Serum chloride	121mmol/L	117mmol/L	110
Serum osmolality	308mOsm/kg	298mOsm/kg	-
Urine osmolality	160mOsm/kg	369mOsm/kg	-
Weight	4 kg	-	4.35 Kg

Figure 1 Panel a: MRI brain showing absent pituitary bright spot
Panel b: Semi-lobar holoprosencephaly



Extreme dehydration can result in hypernatremia, which can lead to neurological symptoms such as seizures, encephalopathy and coma [7,8]. In our case, despite severe hypernatremia (167 mmol/L), the child was asymptomatic.

Central DI (vasopressin-dependent) occurs due to deficiency of arginine vasopressin (AVP) in the hypothalamus or the pituitary gland, whereas nephrogenic DI (vasopressin-independent) occurs due to abnormal tubular response to AVP in the kidneys [7].

Water deprivation test with vasopressin challenge helps to differentiate central DI from nephrogenic DI; Performing water deprivation could be challenging in a young infant and may not be required in children with simultaneous hypernatremia and urine osmolality lower than serum osmolality. Hence a response to vasopressin challenge could be an easy alternative. Vasopressin will increase the urine osmolality

above the serum osmolality though maximum osmolality may not be documented immediately because of chronic lack of AVP action on the renal medulla [9].

Diagnosis of holoprosencephaly is confirmed by brain computed tomography (CT) or magnetic resonance imaging (MRI). Serum electrolytes, thyroid-stimulating hormone, free T4, cortisol, adrenocorticotropin hormone, and insulin-like growth factor 1 should be analyzed for detecting hypothalamic/pituitary defects in patients with HPE [1,2,4].

Management of children with HPE is symptomatic and supportive. Coordinated multi-disciplinary care is recommended, which may include hormone replacement therapy for pituitary dysfunction, gastrostomy tube for feeding difficulties, surgical repair of cleft lip and/or palate with special attention towards fluid and electrolyte balance during surgery [2].

Chromosomal aberrations are seen in approximately 25% to 50% of patients with HPE [2]. Hence, genetic testing may help to counsel families about the nature of this condition, probability of recurrence and prenatal detection of HPE.

LEARNING POINT

Midline cleft lip/palate is frequently associated with hypothalamic/pituitary dysfunction and hence serum electrolytes should be tested as a part of preoperative evaluation.



Compliance with ethical standards

Conflict of interests: The authors have declared that no Conflict of interest exists.

Informed consent: Informed consent was obtained from the parents.

Funding: The authors have not declared a specific grant for this research from any funding agency or source in the public, commercial or not-for-profit sectors.



REFERENCES

1. Holoprosencephaly. National Organization for Rare Disorders. Available at: <https://rarediseases.org/rare-diseases/holoprosencephaly/>. (Accessed: 10 June 2021)
2. Firth HV. Overview of craniofacial clefts and holoprosencephaly. In: Weisman LE, ed. UpToDate. Waltham, Mass.: UpToDate, 2021.
3. Nanni L, Schelper RL, Muenke MT. Molecular genetics of holoprosencephaly. *Front Biosci.* 2000;5:D334-42. doi: 10.2741/nanni.
4. Raam MS, Solomon BD, Muenke M. Holoprosencephaly: a guide to diagnosis and clinical management. *Indian Pediatr.* 2011;48(6):457-466. doi:10.1007/s13312-011-0078-x
5. Geng X, Oliver G. Pathogenesis of holoprosencephaly. *J Clin Invest.* 2009;119(6):1403-1413. doi:10.1172/JCI38937
6. Hahn JS, Hahn SM, Kammann H, Barkovich AJ, Clegg NJ, Delgado MR, Levey E. Endocrine disorders associated with holoprosencephaly. *J Pediatr Endocrinol Metab.* 2005;18(10):935-41. doi: 10.1515/jpem.2005.18.10.935.
7. Christ-Crain M, Bichet DG, Fenske WK, Goldman MB, Rittig S, Verbalis JG, Verkman AS. Diabetes insipidus. *Nat Rev Dis Primers.* 2019;5(1):54. doi: 10.1038/s41572-019-0103-2.
8. Dabrowski E, Kadakia R, Zimmerman D. Diabetes insipidus in infants and children. *Best Pract Res Clin Endocrinol Metab.* 2016;30(2):317-28. doi: 10.1016/j.beem.2016.02.006.
9. Greenbaum LA. Electrolyte and Acid- Base Disorders. In: Robert M. Kliegman, Bonita F. Stanton, Joseph W. St Geme III, Nina F. Schor, Richard E. Behrman(Eds). *Nelson textbook of paediatrics.* 20th edn. Philadelphia: Elsevier; 2016. pp.346-383.