

Tracheal Reconstruction for Complex Acute Tracheal Stenosis

Saulat H. Fatimi², M. Qasim Raza², Alina Ghani², Nilay Shah¹, Awais Ashfaq¹

¹Division of Cardiothoracic Surgery, Department of Surgery, Aga Khan University Hospital, Pakistan, ²Department of Surgery, Mayo Clinic Arizona, Arizona, United States of America

Correspondence to: Nilay Shah, 5777 E Mayo Blvd, Phoenix, AZ 85054, Tel: +1 (602) 680 8780, Email: shah.nilay1@mayo.edu

Article history

Received: 22 December 2012

Accepted: 17 February 2013

Available online: 2 June 2013

Provenance and Peer Review

Unsolicited and Editorial Review

Keywords

Acute Disease

Dyspnea

Intubation

Intratracheal

Tracheal stenosis etiology

Tracheal stenosis therapy

Abstract

Tracheal stenosis refers to a reduction in the size of the tracheal lumen and can be due to a myriad of reasons, but the most common remains trauma. In iatrogenic situations, internal trauma is the most likely culprit, resulting from prolonged intubation. Our case reviews a patient who developed severe tracheal stenosis (90% reduction in lumen size) within a month of a three-day-long intubation, and presented to the emergency room with dyspnea, orthopnea, and stridor. Tracheal reconstruction with resection of the stenosed segment and end-to-end anastomosis was done. The patient returned a month later with re-stenosis, and underwent tracheal dilatation. Subsequently, he was discharged with a tracheostomy with no problems thereafter.

© Surgical Associates Ltd. Open access under [CC BY-NC-ND license](#).

Introduction

Tracheal stenosis refers to a reduction in the tracheal lumen, to a size reduced by more than 40%, and is considered a very rare presentation. The most common cause continues to be trauma, which can be internal (resulting from prolonged endotracheal intubation, surgery, irradiation, and endotracheal burns) or external (blunt or penetrating neck trauma).

This report pertains to a patient who had an acute onset of tracheal stenosis, with a 90% reduction in lumen size within a month of a three-day-long intubation period, and presented with dyspnea, orthopnea, and stridor.

Case Report

The patient, a 44 year old male, with known pulmonary hypertension, ischemic cardiomyopathy, obstructive sleep apnea, and tracheomalacia, had undergone liposuction two months previously with a weight reduction of more than 20 kg. This resulted in a fat embolism and required three days of ventilation via endotracheal tube (ETT). This occurred at another hospital.

He presented to our Emergency Room (ER) with complaints of acute onset shortness of breath, accompanied by cough with white sputum, orthopnea, and dyspnea for the past 10 days. There was no history of fever or wheeze. Chest X-ray (CXR) on admission revealed left lower lobe atelectasis and consolidation. His Echocardiograph during this visit revealed an Ejection Fraction of 25–30%, moderate pulmonary hypertension, with mitral and tricuspid regurgitation. He had five episodes of bronchospasm during the stay, was nebulized with bronchodilators, and eventually put on BIPAP. A diagnosis of left lower lobe pneumonia was made and he was discharged from the hospital after one week on broad-spectrum antibiotics.

Five days later he presented to the ER again with dyspnea, orthopnea, and stridor. Initial investigations that included complete blood count and CXR were normal. Bronchoscopy revealed a 'pin-hole' opening (1 mm diameter), 3 cm below vocal cords, at the level of the 2nd and 3rd tracheal rings.

Consequently, a diagnosis of tracheal stenosis was made and tracheal reconstruction was planned.

The patient underwent elective resection of a stenotic tracheal region with end-to-end anastomosis. A transverse incision was made mid-way between the sternal notch and lower border of thyroid cartilage. In order to expose the distal part of the trachea, a partial sternotomy was performed from sternal notch to angle of Louis. A reinforced tube was passed distally into the trachea to continue ventilation past the incision and the laryngeal mask airway was removed. The stenosed segment was identified and resected completely and an end-to-end anastomosis was made across the resected segment.

The resected section (Figure 1) was sent to histopathology which reported the lumen's dimensions to be $0.3 \times 0.3 \times 1.5$ cm. Postoperatively, the patient remained stable and was discharged after a week. He presented again after a month with a history of worsening dyspnea and stridor. Bronchoscopy, undertaken to check the patency of trachea, on that day revealed granulation tissue and mucoid secretions at the anastomotic site causing a 70–75% occlusion in the proximal trachea, 27 mm below the cricoid cartilage.

Tracheal dilatation via rigid bronchoscopy and tracheostomy was performed which relieved the patient's symptoms significantly. Thereafter, the patient was followed for the next three months and remained stable throughout.

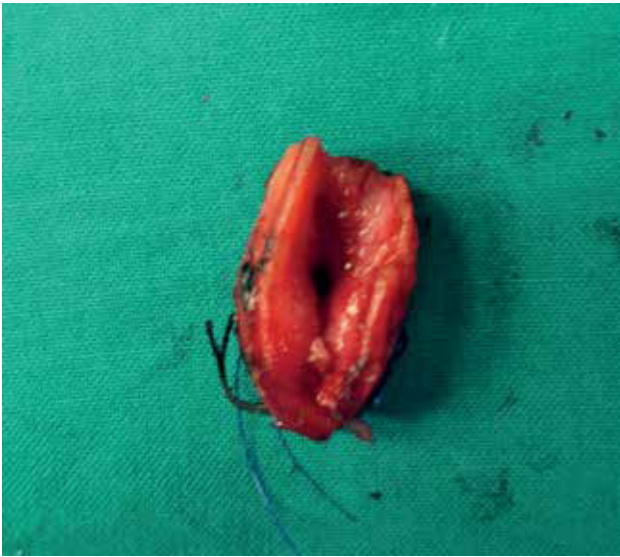

Fig 1 Resected tracheal section of the stenosed segment.

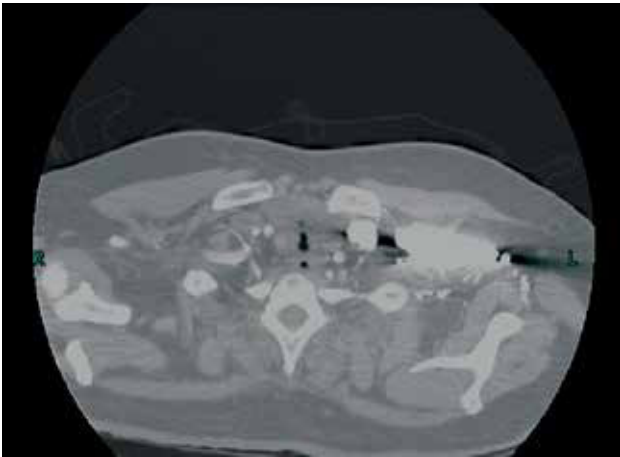


Fig 2 Computed tomography of the patient depicting tracheal stenosis 3 cm below the vocal cords.

Discussion

Iatrogenic airway damage, following ETT intubation or tracheostomy, was a common complication until the advent of high volume, low pressure cuffs. However, post intubation stenosis is still among the leading causes of acquired tracheal obstruction. When the cuff pressure of the ETT exceeds the normal capillary refilling pressure of mucosa (i.e. 30 mmHg), it impedes capillary refill in the tracheal mucosa.¹ This results in ischemic injury followed by necrosis, granulation tissue, and fibrous scar formation. Final contraction of this fibrous tissue reduces the lumen significantly.²

Clinically, tracheal stenosis presents like asthma and the lumen is reduced to 30% of the original lumen before it becomes clinically evident,³ and in the case of extreme respiratory insufficiency, stenosis has reached up to 75%.⁴ Our patient had an astonishingly acute onset with a 10 day history of orthopnea, dyspnea, and stridor. From his clinical picture, it is evident that on first presentation to the hospital, his tracheal lumen was less than 50% of the original.

Studies report an average of 4–54.5 days to develop tracheal stenosis post-intubation.^{5,6} Our patient had a history of three days of endotracheal intubation which is one of the lowest reported in literature.

The most common presentation following a short period of intubation is web-like stenosis around the cuff site.⁵ A similar case has been reported that presented three months after a history of four days of intubation with multiple membranous web like stenosis which, on histopathology, revealed granulation tissue with angiogenesis and fibroblasts.³ But our patient had a solid fibrotic growth at the site of the stenosis which was evident on CT-scans (Figure 2). He had the typical circumferential hour-glass contraction with tracheomalacia which makes this a case of complex stenosis.

Conservative treatment involving laser resection, dilation, or stenting is considered applicable in cases where length of stenosed segment is less than 1 cm, with no circumferential scarring and no loss of cartilage support, and stenosis is membranous or web-like in nature.^{3,5} Since this was not the case in our patient, surgical resection was the only option for treatment. Tracheal resection is a unique procedure considering the anaesthetic management with very high risks of complications in cases of more than 90% luminal stenosis, so a reinforcement tube method was used to ensure continuous ventilation during the procedure.

Tracheal resection is reported as a procedure with good outcomes by many sources with success ranging from 71–97%.⁶ The most common complication of this procedure is the formation of granulation tissue (33%)(7) along the suture line, but this can be avoided by using absorbable sutures, as in this case.⁶

Conclusion

In conclusion, our patient developed a complex, debilitating tracheal stenosis in a very acute setting, and the formation of granulation tissue a month after tracheal reconstruction. An aggressive approach was planned considering the severity of the patient's condition. All necessary precautions were taken, yet the patient developed a complication that led to subsequent visits. It may be speculated that there is still room for improvement in post-operative care so as to eliminate such recurrences.

Ethical approval

Consent was obtained.

Conflicts of interest

No conflicts of interest have been declared by the author.

Author contributions

SF, QR, AG – Interpretation of data, draft and revising article for critical intellectual content.

NS – Draft and revising article for critical intellectual content.

AA – Conception and design of study, acquisition and analysis of data, initial draft of the article.

Funding

No funding source declared by the author.

- 1 Spittle N, mccluskey A. Lesson of the week: tracheal stenosis after intubation. *BMJ* 2000;321(7267):1000–1002.
- 2 Goldberg M, Pearson FG. Pathogenesis of tracheal stenosis following tracheostomy with a cuffed tube. An experimental study in dogs. *Thorax* 1972;27(6):678–691.
- 3 De S. Post intubation tracheal stenosis. *Indian J Crit Care Med* 2008;12(4):194–197.
- 4 Zhou YF, Zhu SJ, Zhu SM, An XX. Anesthetic management of emergent critical tracheal stenosis. *J Zhejiang Univ Sci B* 2007;8(7):522–525.
- 5 Zias N, Chroneou A, Tappa MK, et al. Post tracheostomy and post intubation tracheal stenosis: report of 31 cases and review of the literature. *BMC Pulm Med* 2008;8:18.
- 6 Sarper A, Ayten A, Eser I, Ozbudak O, Demircan A. Tracheal stenosis after tracheostomy or intubation: review with special regard to cause and management. *Tex Heart Inst J* 2005;32(2):154–158.
- 7 Marques P, Leal L, Spratley J, Cardoso E, Santos M. Tracheal resection with primary anastomosis: 10 years experience. *Am J Otolaryngol* 2009;30(6):415–418.