

Access this article online
Quick Response Code:

Website: www.e-tjo.org
DOI: 10.4103/tjo.tjo_12_21

# Advances in refractive corneal lenticule extraction

Matthias Fuest<sup>1</sup>, Jodhbir S. Mehta<sup>2,3,4,5\*</sup>

## Abstract:

Refractive errors are the leading cause of reversible visual impairment worldwide. In addition to the desired spectacle independence, refractive procedures can improve quality of life, working ability, and daily working performance. Refractive corneal lenticule extraction (RCLE) is a relatively new technique, dependent only on a femtosecond laser (FS). This leads to potential benefits over laser-assisted *in situ* keratomileusis (LASIK) including a quicker recovery of dry eye disease, a larger functional optical zone, and no flap-related complications. SMILE, available with the VisuMax FS (Carl Zeiss Meditec AG, Jena, Germany), is the most established RCLE application, offering visual and refractive outcomes comparable to LASIK. SmartSight (SCHWIND eye-tech-solutions GmbH, Kleinostheim, Germany) and CLEAR (Ziemer Ophthalmic Systems AG, Port, Switzerland) are two new RCLE applications that received Conformité Européenne (CE) approval in 2020. In this article, we review refractive and visual outcomes, advantages, and disadvantages of RCLE and also report on the latest advances in RCLE systems.

## Keywords:

Cornea corneal surgery, laser refraction, ocular refractive surgical procedures

## Introduction

Refractive errors are the leading cause of reversible visual impairment worldwide.<sup>[1]</sup> Myopia is the most frequent form of refractive error.<sup>[2]</sup> The global prevalence of myopia is increasing, with the rate of increment being particularly alarming in many Asian countries.<sup>[2,3]</sup> Holden *et al.* predicted that the global prevalence of myopia will rise from 28% (2 billion people) in 2010 to 50% (5 billion people) in 2050.<sup>[3]</sup> The same study predicted that the global prevalence of high myopia will rise from 4% (227 million people) in 2010 to 10% (938 million) in 2050, making myopia a major public health issue.<sup>[3]</sup>

Corrective laser refractive surgery is one of the most commonly performed surgeries.<sup>[4]</sup> Refractive surgery has evolved over the decades. Advances in surface ablation techniques have seen a renaissance in its popularity.<sup>[5,6]</sup> Presbyopic treatment

options have also expanded to include new ablation profiles, intracorneal implants, and phakic intraocular implants.<sup>[5]</sup> With the improved safety and efficacy of cataract surgery, a wider variety of intraocular lens implants, with modified optics, provide more options for refractive correction in carefully selected patients.<sup>[4,5]</sup> In addition to the desired spectacle independence, refractive procedures have been reported to improve quality of life, working ability, and daily working performance.<sup>[7]</sup>

Refractive corneal lenticule extraction (RCLE) is a relatively new technique, dependent only on a femtosecond laser (FS), without the need for corneal flap creation.<sup>[8]</sup> Advances in this promising new technology will be discussed in this review.

## Developments in Laser Refractive Surgery

The cornea is the most integral structure for refractive correction, being the most

This is an open access journal, and articles are distributed under the terms of the Creative Commons Attribution-NonCommercial-ShareAlike 4.0 License, which allows others to remix, tweak, and build upon the work non-commercially, as long as appropriate credit is given and the new creations are licensed under the identical terms.

For reprints contact: WKHLRPMedknow\_reprints@wolterskluwer.com

**How to cite this article:** Fuest M, Mehta JS. Advances in refractive corneal lenticule extraction. Taiwan J Ophthalmol 2021;11:113-21.

<sup>1</sup>Department of Ophthalmology, RWTH Aachen University, Aachen, Germany, <sup>2</sup>Tissue Engineering and Stem Cell Group, Singapore Eye Research Institute, <sup>3</sup>Singapore National Eye Centre, <sup>4</sup>Eye-Academic Clinical Program, Duke-National University of Singapore Graduate Medical School, <sup>5</sup>School of Material Science and Engineering, Nanyang Technological University, Singapore

### \*Address for correspondence:

Prof. Jodhbir S. Mehta, Singapore National Eye Centre, 11 Third Hospital Avenue, Singapore 168 751. E-mail: jodmehta@gmail.com

Submission: 09-03-2021  
Accepted: 16-03-2021  
Published: 24-04-2021

accessible part of the eye and providing two-thirds of the total refractive power.<sup>[6,9]</sup> Corneal ablation techniques can potentially treat most refractive errors (including myopia, hyperopia, astigmatism, and presbyopia) within a given range, by ablating corneal tissue into a specified shape, by the use of an excimer laser.<sup>[5,6,10]</sup>

The evolution of keratorefractive surgery began with surface ablation techniques such as photorefractive keratectomy (PRK) that involved epithelial removal.<sup>[5]</sup> More recently, excimer laser ablation has been used to remove the corneal epithelium directly (transepithelial PRK).<sup>[11]</sup> The main advantage of transepithelial PRK is that the epithelial layer removal and stromal excimer ablation are performed sequentially, simplifying the treatment and saving time for patient and surgeon. Most reports have suggested that healing time and visual outcomes do not vary greatly among the different techniques of epithelium removal.<sup>[12]</sup> In recent years, PRK (and in particular transepithelial PRK) has seen a revival in interest.<sup>[13]</sup> Surface ablation has several potential advantages. Surface ablation has several potential advantages, e.g. the avoidance of flap-related complications and a greater residual stromal thickness (RST).<sup>[14]</sup> Hence, it is useful in patients with thin corneas.<sup>[5]</sup> While the refractive predictability of surface ablation is comparable with laser-assisted *in situ* keratomileusis (LASIK), myopic regression may be more common.<sup>[15]</sup> Other disadvantages of PRK are prolonged pain, because of slow epithelial healing, and subepithelial scarring (haze), that can form as an unwanted healing response in the Bowman layer and anterior corneal stroma.<sup>[16]</sup> Low-dose topical mitomycin-C (0.02%–0.04%) is used after excimer laser treatment to reduce haze formation.<sup>[17]</sup>

Using a microkeratome to create a hinged flap, under which the corneal stroma was ablated by means of an excimer laser, LASIK was introduced in 1990.<sup>[18]</sup> LASIK preserves the central corneal epithelium, which improves the comfort during the early postoperative period, allows for rapid visual recovery, and reduces the wound

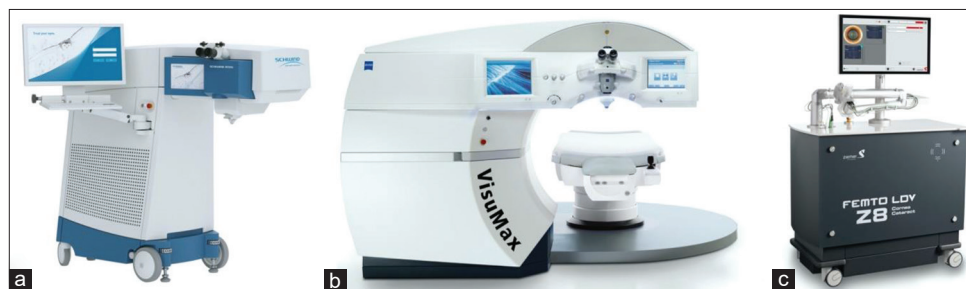healing response.<sup>[10]</sup> From 2004, FS was introduced to improve LASIK flap creation (FS-LASIK), with fewer flap-related complications (e.g., incomplete, buttonholed, free, or irregular flaps). The FS allowed customization of several flap parameters, for example, hinge position, flap diameter, hinge width, and flap thickness. This led to more precise and less variable flaps, and a lower incidence of epithelial ingrowth.<sup>[19,20]</sup>

Laser refractive surgery is now widely recognized as safe and effective, yielding excellent results in patients with low-to-moderate amounts of refractive error.<sup>[9]</sup> A review of 97 studies published since 2008 showed that up to 99.5% of patients who underwent LASIK met uncorrected distance visual acuity of better than 20/40 (considered spectacle independent), as many as 98.6% had refractive targets within  $\pm 1.0$  diopter, and almost 98.8% were satisfied with their outcome.<sup>[21]</sup> Moreover, complications that could lead to visual loss, such as corneal ectasia or infection, were very rare with laser eye surgery.<sup>[4]</sup>

### Refractive Corneal Lenticule Extraction

A precursor to modern RCLE was first described in 1996 using a picosecond laser to generate an intrastromal lenticule that was removed manually after lifting a flap in human donor eyes.<sup>[22]</sup> However, significant manual dissection was required leading to an irregular surface. The switch to FS improved the precision, and studies were performed in rabbit eyes in 1998<sup>[23]</sup> and in partially sighted eyes in 2003.<sup>[24]</sup>

Following the introduction of the VisuMax FS [Carl Zeiss Meditec AG, Jena, Germany; Figure 1b], in 2007, intrastromal lenticule refractive correction was reintroduced, in a procedure called femtosecond lenticule extraction (FLEX). Sekundo *et al.* published the 6-month results of the first 10 fully seeing eyes treated in 2008<sup>[8]</sup> and a larger series followed.<sup>[28]</sup> The procedure still included the creation of a hinged flap, under which the stromal lenticule was extracted, both cut by FS



**Figure 1:** Three femtosecond laser (FS) platforms currently allow refractive corneal lenticule extraction (RCLE). The SCHWIND ATOS FS (a; SCHWIND eye-tech-solutions GmbH, Kleinostheim, Germany) received CE approval for its SmartSight application in July 2020 and the FEMTO LDV Z8 FS (c; Ziemer Ophthalmic Systems AG, Port, Switzerland) for its CLEAR program in April 2020. SMILE, available with the VisuMax FS (b; Carl Zeiss Meditec, Jena, Germany), is the only current RCLE application with CE and FDA approval. The images were provided by the manufacturers.<sup>[25-27]</sup>

(ReLEx FLEX).<sup>[8,28]</sup> The refractive results were similar to those observed in LASIK, but visual recovery time was longer due to the lack of optimization in energy parameters and scan modes; further refinements led to much improved visual recovery times.<sup>[29]</sup>

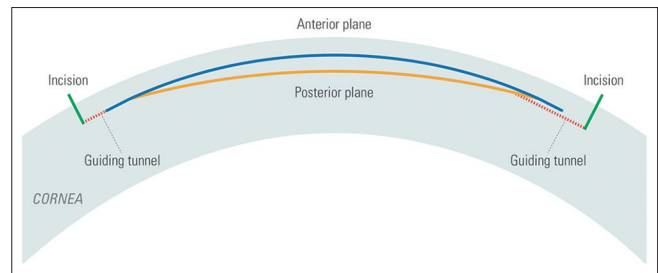
Following the successful implementation of FLEX, the procedure was advanced to small incision lenticule extraction (SMILE or ReLEx-SMILE). In SMILE, a dissector is passed through a small 2–5-mm incision to separate the lenticular interfaces and allow the lenticule to be removed, without the need to create a flap [Figure 2].<sup>[30]</sup> The SMILE procedure has gained popularity following the initial results of the first prospective trials.<sup>[30,31]</sup> In 2011, Zeiss received European conformity approval (Conformité Européenne, CE) for the SMILE application for corrections of myopia from  $-0.5$  to  $-10.0$  diopters (D) and astigmatism up to  $-5.0$  D. SMILE was then approved by the US Food and Drug Administration (FDA) for the treatment of myopia in 2016. In 2018, astigmatism correction was added, so that the current SMILE FDA approval is for myopia of  $-1.0$  to  $-10.0$  D and astigmatism of  $-0.75$  to  $-3.0$  D with a maximum spherical equivalent (myopia plus half of the astigmatism) correction of no more than  $-10.0$  D.<sup>[25]</sup>

Subsequently, other manufacturers have followed. The SCHWIND ATOS FS [SCHWIND eye-tech-solutions GmbH, Kleinostheim, Germany; Figure 1a] received CE approval for its SmartSight application in July 2020 and the FEMTO LDV Z8 platform [Ziemer Ophthalmic Systems AG, Port, Switzerland; Figure 1c] for its corneal lenticule extraction for advanced refractive (CLEAR) correction program in April 2020 [Table 1].<sup>[26,27]</sup>

In this review, we report on the latest advances in modern flap-free RCLE. When a particular RCLE application is discussed, we use the according abbreviations or acronyms [SmartSight, SMILE, or CLEAR; Table 1].

## Advantages of Refractive Corneal Lenticule Extraction

With laser refractive surgery already achieving excellent clinical visual outcomes, it is often difficult to demonstrate that newer procedures are superior to the established techniques. A recent meta-analysis revealed a similar safety, efficacy, and predictability of SMILE compared to FS-LASIK in the correction of myopia.<sup>[32]</sup> Similarly, Ang *et al.* recently published their results of a contralateral randomized clinical trial, in 70 patients, performing FS-LASIK in one eye and SMILE in the other. They found excellent, comparable outcomes in terms of refractive predictability, efficacy, and safety for both procedures at 3 months and also after 1 year



**Figure 2:** Guiding incisions (green) and tunnels (red) used in modern refractive corneal lenticule extraction (RCLE). In this case one incision guides the surgeon to the posterior and one to the anterior surfaces of the lenticule to be delineated directly and independently. This option is available with the CLEAR program on the FEMTO LDV Z8 platform (Ziemer Ophthalmic Systems AG, Port, Switzerland) and helps to prevent lenticule mis-dissection, one of the most common intraoperative complications in RCLE<sup>[27]</sup>

of follow-up.<sup>[6]</sup> Vision-related quality of life has also been found to be comparable between SMILE and LASIK.<sup>[33–35]</sup> However, potential benefits of RCLE over LASIK are a quicker recovery of dry eye disease (DED), a larger functional optical zone, and no flap-related complications.<sup>[36]</sup>

DED is one of the most common side effects after laser refractive surgery.<sup>[37]</sup> LASIK disrupts the corneal nerves during the creation of the corneal flap and during the stromal ablation. RCLE is a flapless procedure with a smaller corneal incision that results in less damage to the anterior corneal innervation, making it theoretically less prone to DED.<sup>[37,38]</sup> Both RCLE and LASIK induce a transient worsening in dry eye parameters, but there is evidence showing that RCLE has a less negative impact on ocular surface parameters and allows for an earlier recovery.<sup>[37,39]</sup> Analyzing ocular surface changes in 15 patients post SMILE and 32 post FS-LASIK, Gao *et al.* found lower fluorescein staining scores after 1 week, longer tear breakup times after 1 and 3 months, higher central corneal sensitivity at 1 week, 1 and 3 months as well as lower levels and a faster decrease of interleukin-6 and nerve growth factor in tears following SMILE compared to FS-LASIK.<sup>[40]</sup>

Corneal inflammation may play a role in postoperative DED after SMILE and FS-LASIK, but more evidence is needed to support this hypothesis. Studies have also shown faster corneal nerve regeneration<sup>[41]</sup> and improvement of corneal sensitivity<sup>[42]</sup> following SMILE, supporting the evidence for less DED.

It was previously shown that the strength of the corneal stroma decreases from anterior to posterior.<sup>[43]</sup> By preservation of a stronger anterior stromal lamella, RCLE may offer a theoretical biomechanical advantage over LASIK. Even though this has been shown using theoretical<sup>[44]</sup> and laboratory experiments,<sup>[45]</sup> three

**Table 1: Overview of current femtosecond lasers (FS) that offer Conformité Européenne (CE) marked modern refractive corneal lenticule extraction (RCLE) applications<sup>[25-27]</sup>**

FSL	ATOS SCHWIND	VisuMax Zeiss	Z8 Ziemer
RCLE program	SmartSight	SMILE	CLEAR
Possible refractive cuts	Flap/lenticule	Flap/lenticule	Flap/lenticule/arcuate incisions
Weight (kg)	<275 kg	870	215
Approval	CE	FDA/CE	CE
Treatment range (diopters, D)			
Sphere	-0.5 to -12.0	-0.5 to -10.0	-0.5 to -10.0
Cylinder	0 to -6.0	0 to -5.0	0 to -5.0
SEQ	-0.5 to -14	-0.5 to -12.5	-0.5 to -12.5
Repetition rate	Up to 4 Mhz	500 kHz	Up to 20 Mhz
Energy per pulse (nJ)	75-135	110-150	<<100
Laser/patient interface	Machine-fixed	Machine-fixed	Handheld
Contact glass on suction system	Curved (20 mm)	Curved (22 mm)	Flat
iOCT	No	No	Yes
Automatic detection of pupil	Yes	No	Yes
Pupil central offsetting	Yes	No	Yes
Cyclotorsion compensation	Yes	No	Yes
Centration	Eye tracking guided (semi-automated) centration	Manual	Eye tracking guided (semi-automated) centration
Real-time video recording	Yes	Yes	No - schematic graphic
Postsuction lenticule adjustment	Lateral electronic adjustment	Nil	Lateral electronic adjustment
Laser pattern	Arc segments-centrifugal/centrifugal	Centripetal/centrifugal	Spiral raster
Lenticule shape	No side cut	10 µm side cut	No side cut
Number of treatments performed	700+	3.5 million+	400+
Incisions (mm)	1, 2-5	1-3, 2-5	1-2, 1.5-4
Advantages	Recentring after docking Eye tracking with pupil recognition and cyclotorsion compensation Mobile device High repetition rate Lower pulse energy	Established technique Many treated cases Low IOPs during suction	Recentring after docking Eye tracking with pupil recognition and cyclotorsion compensation Mobile device Small footprint High repetition rate Low pulse energy Guiding incisions and tunnels iOCT Multi-use laser
Disadvantages	New procedure lacking clinical experience	No recentring after docking No eye tracking	New procedure lacking clinical experience

iOCT=Intraoperative OCT, OCT=Optical coherence tomography, IOP=Intraocular pressure, SEQ=Spherical equivalent, FDA=US Food and Drug Administration, CE=Conformité Européenne, FSL=Femtosecond laser

randomized controlled trials found no statistically significant differences between SMILE or flap-based procedures concerning corneal hysteresis or corneal resistance factor, as measured with the Ocular Response Analyzer (Reichert Inc., Depew, USA).<sup>[46]</sup> However, the authors speculated that the current commercially available diagnostic technology might not be optimal for detecting such differences in biomechanical stability.<sup>[46]</sup>

Using the Pentacam (Oculus Optikgeräte GmbH, Wetzlar, Germany), it has been demonstrated that the postoperative “effective/functional optical zone” is significantly larger in SMILE than that in FS-LASIK based on the same diameter of optical treatment zone.<sup>[47]</sup> This could potentially reduce pupil-related photopsia, particularly in patients with large mesopic pupils.

## Refractive Corneal Lenticule Extraction Complications and Management

Despite the fact that RCLE has been shown to be a safe technique, it is not free of complications and one of the disadvantages of the procedure has been a longer learning curve for the surgeon, when compared with conventional FS-LASIK procedures.<sup>[48,49]</sup> With the introduction of FS-created flaps, and improved excimer laser ablation profiles, FS-LASIK has demonstrated a remarkable consistency among surgeons of different experiences. However, RCLE still requires the manual removal of the lenticule following laser creation [Figure 2].

Patient head and eye movement can lead to suction loss, a common and feared complication of SMILE,

with an incidence of 0.5%–4.4%.<sup>[49-51]</sup> Suction loss is more commonly observed after SMILE, because of the lower suction pressure and longer duration compared to FS-LASIK flap creation.<sup>[49]</sup> Several factors can predispose a patient to suction loss, for example, the longer duration of suction to create the posterior refractive and the anterior nonrefractive planes in the stroma.<sup>[52]</sup> Ocular factors include a small palpebral aperture, loose corneal epithelium, excessive reflex tearing, and poor fixation. Individual factors include patient anxiety and inability to follow instructions.<sup>[49]</sup> However, Reinstein *et al.* proposed a clear management protocol and decision tree for this event.<sup>[50,51]</sup> Options range from continuing with SMILE or converting to LASIK to complete the treatment on the same day,<sup>[50,51]</sup> to aborting the surgery and repeating SMILE or another laser refractive surgery at a later date.<sup>[49]</sup> In the vast majority of cases, outcomes are excellent with no significant differences in vision or refraction compared to uncomplicated cases.<sup>[50,51]</sup>

Identifying the lenticule edge at the beginning of the surgery is crucial to ensure lamellar separation in the correct plane and to prevent lenticule mis-dissection. The surgeon can for instance make mistakes while performing the dissection and inadvertently dissect the posterior surface first. This would then compact the lenticule into the anterior cap, making anterior plane dissection more difficult and subsequent lenticule extraction more challenging. However, results on visual acuity outcomes performing anterior or posterior lenticule dissection first, have been shown to be equivalent.<sup>[53]</sup> Another issue when performing the posterior lenticule separation first, is that if the surgeon is unaware of his/her mistake, then they may inadvertently try to dissect another plane and hence create a false plane, beneath the posterior cut. Lenticule dissection and extraction is the most challenging step that can lead to a multitude of complications, such as posterior stromal damage, anterior cap tears, side-cut tears, partially retained lenticule, and completely retained lenticule.<sup>[54]</sup> However, surgical experience does play a significant role, and most complications that result in delayed visual recovery were observed in the initial 50 cases.<sup>[48]</sup> Removing the stromal lenticule in one piece can sometimes be challenging, especially in patients with low myopia and a thin lenticule.<sup>[55]</sup> For this reason, different modifications of the surgical technique have been described to ease the process of lenticule extraction, such as Chung's swing technique, lenticulerhexis, lenticuloschisis, hydroexpression, and lenticule extraction guided by optical coherence tomography (OCT).<sup>[56-60]</sup> Likewise, it is important to choose an appropriate dissector that has been validated to procedure a smooth interface, during dissection.<sup>[61]</sup>

As RCLE has gained popularity over the last decade, the treatment has continuously been optimized. Initially, the main issue was the delayed visual recovery relative to LASIK. However, detailed research into nomograms, energy levels, and spot spacing has significantly improved visual recovery, without compromising the ease of lenticule separation.<sup>[62,63]</sup>

Postoperative complications after SMILE are similar to those after LASIK. Diffuse lamellar keratitis (DLK) after SMILE has been reported to occur with an incidence of 0.45%.<sup>[64]</sup> It usually resembled the appearance following LASIK but may rarely present as a sterile multifocal inflammatory keratitis. However, topical steroid therapy resolved all reported cases of DLK, and in all cases, there were no sequelae and no adverse effect on refractive or visual outcome.<sup>[64]</sup>

Epithelial ingrowth after SMILE has been described in cases following incisional tears of the smile pocket or inadvertent implantation of loose epithelium following lenticule removal.<sup>[65]</sup> It can be treated by meticulous irrigation of the pocket, manual scraping using a blunt spatula, and forceps removal of epithelial strands.<sup>[65]</sup> Particularly, eccentric epithelial nests have also been successfully treated with a neodymium-doped yttrium aluminum garnet (Nd:YAG).<sup>[66]</sup>

In contrast to LASIK, which can be retreated by a flap re-lift, SMILE enhancement is more complicated. In cases of primary under/overcorrection or myopic regression following RCLE, different techniques have been applied. One of the most popular choices is surface ablation, which preserves the flap-free approach of the primary procedure and a higher RST. However, the aspect of pain and a slow visual recovery might render it less appealing, particularly if it needs to be done bilaterally.<sup>[67]</sup> The SMILE cap can be converted into a FS-LASIK flap for secondary excimer laser application (CIRCLE).<sup>[68]</sup> Thin-flap LASIK, with a new flap anterior to the SMILE interface, can also be created.<sup>[69]</sup> These options offer a faster visual recovery, however, at the price of flap creation. Each enhancement method usually requires adjusted nomograms and generates specific tissue responses with a different impact on corneal biomechanics dependent on the previous SMILE parameters, especially the cap thickness.<sup>[67,69]</sup>

SMILE is now a mature and established procedure that provides patients with safe and effective outcomes with current reports demonstrating that the visual and refractive results are similar to LASIK.<sup>[6,33-35]</sup> However, it is still a first-generation procedure, and as we have seen LASIK mature over the years, through multiple iterations driven in large by improvements in technology, we expect to see the same with SMILE.

## Characteristics of the Different Refractive Corneal Lenticule Extraction Systems

CLEAR is a new CE marked proprietary RCLE procedure for myopic correction of sphere  $-0.5$  D to  $-10$  D and cylinder  $0$  D to  $-5$  D [Table 1]. CLEAR is an optional software upgrade on the FEMTO LDV Z8 platform.<sup>[70,71]</sup> The platform itself can also be used for cataract surgery (i.e., femtosecond laser-assisted cataract surgery), corneal transplantation, pterygium surgery, LASIK flap creation, and presbyopic correction (pockets for inlays).<sup>[72-74]</sup> The Z8 is based on a low-energy ( $\ll 100$  nJ) high-frequency (up to 20 MHz) concept, where the miniaturized scanning optic, integrated into the handpiece and its high numerical aperture, creates highly focused laser pulses. Advantages of the low-energy concept are the decreased stromal gas generation and an accurate laser focus. The high-frequency repetition rate leads to overlapping pulses. The laser pulses are guided from the laser source through an articulated moveable arm to a handpiece that is adaptable in position and height with a very close working distance to the eye. In addition, the FEMTO LDV Z8 offers a wide range of centration options and the options of recentering the treatment area after having performed the docking, which is not possible with the current VisuMax Laser System.<sup>[27,70,71]</sup>

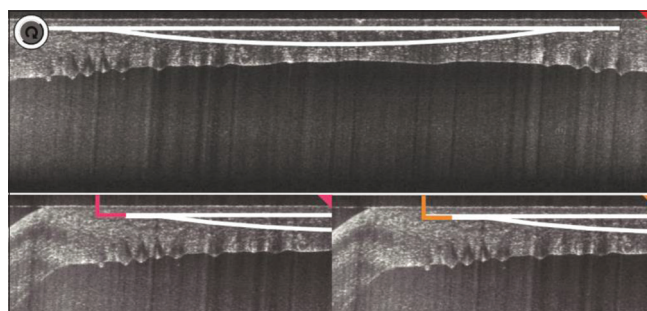
Recently, Izquierdo *et al.* reported on their initial experience with CLEAR. They marked the visual axis on the slit lamp before CLEAR.<sup>[71]</sup> If the surgeon was not satisfied with the centration after docking, the Z8 allowed recentering of the treatment area, including correction of cyclotorsion by adjustment on the touchscreen monitor, without having to release the suction.<sup>[71]</sup> This ensured accurate centration on the visual axis and adjusted cyclotorsion, which is especially important in patients with cylindrical corrections. In 5 eyes of 5 patients treated, two small incisions of 3.0 mm width were cut separately at  $35^\circ$  and  $145^\circ$  positions, with an entrance angle of  $90^\circ$ . Each incision allowed for the posterior and anterior surfaces of the lenticule to be delineated directly and independently aiding one of the most difficult and important steps of the lenticule extraction technique [Figure 2].<sup>[71]</sup> In CLEAR, the surgeon can adjust the distance between the incisions and the angle position for greater comfort and can also decide if 1 or both incisions were created and used. In all the cases reported by Izquierdo *et al.*, the lenticule had a diameter of 6.5 mm without adding any additional edge thickness. During the cutting of the lenticule, the applied vacuum level to the eye was 700 mbar, the same as habitually used for LASIK flaps with the Z8.<sup>[75]</sup> A complete dissection and removal of the lenticule was achieved in all cases without any intraoperative complications, and at postoperative day 1, all patients had a clear cornea. In the postoperative

period, 1 patient presented with a mild stromal haze in the interface that resolved with 2 weeks of topical corticosteroid treatment 4 times a day. The refractive and visual outcomes were excellent and comparable to established SMILE and LASIK procedures. However, follow-up was only 1 month. Izquierdo *et al.* speculated that the guiding incisions and tunnels leading to the anterior or posterior interface have the potential to shorten the learning curve for surgeons and lower the complication rate of RCLE,<sup>[71]</sup> which needs to be verified in future larger case series.

Another ability of the Z8 not mentioned by the previous authors is the inbuilt intraoperative OCT (iOCT) [Figure 3]. This feature may also be used following lenticule creation. This could be useful in more complicated cases, for example, CLEAR in posttransplant cases.

Performing experimental CLEAR on enucleated porcine eye balls during a medical exhibition in China, Wang *et al.* found longer time on suction peak pressure, total laser application, and total surgery time spent during CLEAR compared to SMILE.<sup>[76]</sup> However, the CLEAR group included OCT scanning and offsetting before performing the laser procedure, which took more time for these crucial steps. The anterior and posterior lenticule surfaces analyzed by scanning electron microscopy were smoother in the FEMTO LDV Z8/CLEAR group compared to the VisuMax/SMILE group. The authors speculated that this might be the reason for easier lenticule separation in CLEAR compared to SMILE.<sup>[76]</sup> The atraumatic, smooth cutting of high-frequency low-energy FS has been shown before in rabbit corneas by Riau *et al.* using the FEMTO LDV Z6 predecessor model.<sup>[77]</sup> By placing laser spots directly adjacent to each other, the Z6 and Z8 are believed to create a smooth stromal interface.<sup>[77]</sup>

Further comparative studies are necessary to evaluate whether these differences in lenticule surface roughness created by different laser platforms could result in different clinical performances with regard to postoperative refraction, optic quality, and tissue response.



**Figure 3:** Intraoperative optical coherence tomography (iOCT) can be used in CLEAR on the FEMTO LDV Z8 platform (Ziemer Ophthalmic Systems AG, Port, Switzerland)<sup>[27]</sup>

The FEMTO LDV Z8 uses a flat contact glass on its docking system, which is directly in contact with the cornea during laser applications. Previous studies have proven that the flat suction cone in FEMTO LDV models induced a higher intraocular pressure (IOP) than the curved suction cone of the VisuMax.<sup>[78,79]</sup> Although extremely uncommon,<sup>[80]</sup> the higher IOP theoretically increases the risk of ocular vessel occlusions or visual field loss. However, these complications have not been reported following FS-LASIK with the Z8 at the same suction pressure.<sup>[81,82]</sup> An advantage of the high suction is the reduction in the risk of suction loss, during the procedure. However, more clinical cases are required to validate the latter comment.

SmartSight is the new RCLE application available with the SCHWIND ATOS FS that received CE approval in 2020.<sup>[26,83]</sup> The relatively small design and “lightweight” of the ATOS laser, similar to the Z8, is supposed to allow mobility of the device.

For SmartSight, the ATOS offers eye tracking, featuring pupil recognition, and cyclotorsion compensation to allow precise centering. Eye tracking, the centering options (pupil, vertex, and user-defined offset), and the cyclotorsion compensation are known to be particularly helpful in the correction of astigmatism.<sup>[26]</sup>

The ATOS has a curved patient interface, which can be used for SmartSight and for making flaps in FS-LASIK. The curved geometry aims to reduce the pressure on the eye and patient discomfort during the contacting process. A sophisticated contact glass design allows the cutting of large flaps and RCLE treatment diameters up to 9.6 mm.<sup>[26]</sup>

The ATOS FS uses a high repetition rate up to 4 MHz to allow a quick cutting and has a high numerical aperture for optimized resolution. The energy per pulse of 75–135 nJ is lower than SMILE but higher than in CLEAR [Table 1].

According to the manufacturer, like in CLEAR, SmartSight does not use any side cuts and consequently does not have a minimal thickness as in SMILE. The lenticule tapers toward the periphery following a refractive progressive true transition zone, in an attempt to reduce epithelial remodeling and refractive regression.<sup>[26,83]</sup>

Pradhan and Mosquera described no serious complications during the treatment of their first 185 SmartSight patients. They did witness a slight tendency for overcorrection and improvement of uncorrected vision took a little longer than with LASIK, with 70% of patients reaching 6/9, decimal 0.6 by day 1, improving

to >70% in 6/6 by 1 week.<sup>[83]</sup> However, this has been described for RCLE previously and is not considered a limitation.<sup>[84]</sup> A greater number of clinical cases will allow for further nomogram refinement to improve outcomes.

ZEISS is currently developing a new generation FS named VISUMAX 800.<sup>[25]</sup> It incorporates a significantly faster laser source, which is intended to bring the time needed for a complete lenticule creation down to approximately 10 s. The new device will feature computer-assisted centration and cyclotorsion compensation. As compared to the current version of the VisuMax, the VISUMAX 800 will have a significantly smaller footprint as well. CE certification and commercialization are anticipated for the second half of 2021.<sup>[25]</sup>

Alcon (Geneva, Switzerland) and Johnson & Johnson (New Brunswick, USA) are also working on RCLE programs for their laser systems. However, further details were not published at the time of composing this review (March 2021).

To summarize, 2020 has seen the approval of two new devices for RCLE. Future studies will have to investigate whether capabilities of the new machines, for example, eye tracking, can further improve the visual outcomes already achieved, and make them more universally consistent.

## Financial support and sponsorship

Nil.

## Conflicts of interest

The authors declare that there are no conflicts of interests in this paper.

## References

1. Lou L, Yao C, Jin Y, Perez V, Ye J. Global patterns in health burden of uncorrected refractive error. *Invest Ophthalmol Vis Sci* 2016;57:6271-7.
2. Morgan IG, Ohno-Matsui K, Saw SM. Myopia. *Lancet* 2012;379:1739-48.
3. Holden BA, Fricke TR, Wilson DA, Jong M, Naidoo KS, Sankaridurg P, *et al.* Global prevalence of myopia and high myopia and temporal trends from 2000 through 2050. *Ophthalmology* 2016;123:1036-42.
4. Kim TI, Alió Del Barrio JL, Wilkins M, Cochener B, Ang M. Refractive surgery. *Lancet* 2019;393:2085-98.
5. Ang M, Gatinel D, Reinstein DZ, Mertens E, Alió Del Barrio JL, Alió JL. Refractive surgery beyond 2020. *Eye (Lond)* 2021;35:362-82.
6. Ang M, Farook M, Htoon HM, Mehta JS. Randomized clinical trial comparing femtosecond LASIK and small-incision lenticule extraction. *Ophthalmology* 2020;127:724-30.
7. Sugar A, Hood CT, Mian SI. Patient-reported outcomes following LASIK: Quality of life in the PROWL studies. *JAMA* 2017;317:204-5.
8. Sekundo W, Kunert K, Russmann C, Gille A, Bissmann W, Stobrawa G, *et al.* First efficacy and safety study of femtosecond

- lenticule extraction for the correction of myopia: Six-month results. *J Cataract Refract Surg* 2008;34:1513-20.
9. Sugar A, Rapuano CJ, Culbertson WW, Huang D, Varley GA, Agapitos PJ, *et al.* Laser *in situ* keratomileusis for myopia and astigmatism: Safety and efficacy: A report by the American Academy of Ophthalmology. *Ophthalmology* 2002;109:175-87.
  10. Ambrósio R Jr., Wilson S. LASIK vs LASEK vs PRK: Advantages and indications. *Semin Ophthalmol* 2003;18:2-10.
  11. Fadlallah A, Fahed D, Khalil K, Dunia I, Menassa J, El Rami H, *et al.* Transepithelial photorefractive keratectomy: Clinical results. *J Cataract Refract Surg* 2011;37:1852-7.
  12. Antonios R, Abdul Fattah M, Arba Mosquera S, Abiad BH, Sleiman K, Awwad ST. Single-step transepithelial versus alcohol-assisted photorefractive keratectomy in the treatment of high myopia: A comparative evaluation over 12 months. *Br J Ophthalmol* 2017;101:1106-12.
  13. Lundström M, Manning S, Barry P, Stenevi U, Henry Y, Rosen P. The European Registry of Quality Outcomes for Cataract and Refractive Surgery (EUREQUO): A database study of trends in volumes, surgical techniques and outcomes of refractive surgery. *Eye Vis (Lond)* 2015;2:8.
  14. Javadi MA, Mohammadpour M, Rabei HM. Keratectasia after LASIK but not after PRK in one patient. *J Refract Surg* 2006;22:817-20.
  15. Na KS, Chung SH, Kim JK, Jang EJ, Lee NR, Joo CK. Comparison of LASIK and surface ablation by using propensity score analysis: A multicenter study in Korea. *Invest Ophthalmol Vis Sci* 2012;53:7116-21.
  16. Wachtlin J, Langenbeck K, Schründer S, Zhang EP, Hoffmann F. Immunohistology of corneal wound healing after photorefractive keratectomy and laser *in situ* keratomileusis. [wachtlin@ukbf.fu-berlin.de](mailto:wachtlin@ukbf.fu-berlin.de). *J Refract Surg* 1999;15:451-8.
  17. Kim TI, Pak JH, Lee SY, Tchah H. Mitomycin C-induced reduction of keratocytes and fibroblasts after photorefractive keratectomy. *Invest Ophthalmol Vis Sci* 2004;45:2978-84.
  18. Reinstein DZ, Archer TJ, Gobbe M. The history of LASIK. *J Refract Surg* 2012;28:291-8.
  19. Kezirian GM, Stonecipher KG. Comparison of the IntraLase femtosecond laser and mechanical keratomes for laser *in situ* keratomileusis. *J Cataract Refract Surg* 2004;30:804-11.
  20. Kim JY, Kim MJ, Kim TI, Choi HJ, Pak JH, Tchah H. A femtosecond laser creates a stronger flap than a mechanical microkeratome. *Invest Ophthalmol Vis Sci* 2006;47:599-604.
  21. Sandoval HP, Donnenfeld ED, Kohnen T, Lindstrom RL, Potvin R, Tremblay DM, *et al.* Modern laser *in situ* keratomileusis outcomes. *J Cataract Refract Surg* 2016;42:1224-34.
  22. Ito M, Quantock AJ, Malhan S, Schanzlin DJ, Krueger RR. Picosecond laser *in situ* keratomileusis with a 1053-nm Nd:YLF laser. *J Refract Surg* 1996;12:721-8.
  23. Heisterkamp A, Mamom T, Kermani O, Drommer W, Welling H, Ertmer W, *et al.* Intrastromal refractive surgery with ultrashort laser pulses: *In vivo* study on the rabbit eye. *Graefes Arch Clin Exp Ophthalmol* 2003;41:511-517. doi: 10.1007/s00417-003-0683-z. Epub 2003 May 14.
  24. Ratkay-Traub I, Ferincz IE, Juhasz T, Kurtz RM, Krueger RR. First clinical results with the femtosecond neodymium-glass laser in refractive surgery. *J Refract Surg* 2003;19:94-103.
  25. Personal correspondence with Carl Zeiss Meditec AG, Jena, Germany.
  26. Personal correspondence with SCHWIND eye-tech-solutions GmbH, Kleinostheim, Germany.
  27. Personal correspondence with Ziemer Ophthalmic Systems AG, Port, Switzerland.
  28. Vestergaard A, Ivarsen A, Asp S, Hjortdal J. Femtosecond (FS) laser vision correction procedure for moderate to high myopia: A prospective study of ReLEx(®) flex and comparison with a retrospective study of FS-laser *in situ* keratomileusis. *Acta Ophthalmol* 2013;91:355-62.
  29. Shah R, Shah S. Effect of scanning patterns on the results of femtosecond laser lenticule extraction refractive surgery. *J Cataract Refract Surg* 2011;37:1636-47.
  30. Sekundo W, Kunert KS, Blum M. Small incision corneal refractive surgery using the small incision lenticule extraction (SMILE) procedure for the correction of myopia and myopic astigmatism: Results of a 6 month prospective study. *Br J Ophthalmol* 2011;95:335-9.
  31. Hjortdal JØ, Vestergaard AH, Ivarsen A, Ragunathan S, Asp S. Predictors for the outcome of small-incision lenticule extraction for Myopia. *J Refract Surg* 2012;28:865-71.
  32. Shen Z, Shi K, Yu Y, Yu X, Lin Y, Yao K. Small incision lenticule extraction (SMILE) versus femtosecond laser-assisted *in situ* keratomileusis (FS-LASIK) for Myopia: A systematic review and meta-analysis. *PLoS One* 2016;11:e0158176.
  33. Ang M, Ho H, Fenwick E, Lamoureux E, Htoon HM, Koh J, *et al.* Vision-related quality of life and visual outcomes after small-incision lenticule extraction and laser *in situ* keratomileusis. *J Cataract Refract Surg* 2015;41:2136-44.
  34. Ang M, Farook M, Htoon HM, Tan D, Mehta JS. Simulated night vision after small-incision lenticule extraction. *J Cataract Refract Surg* 2016;42:1173-80.
  35. Damgaard IB, Ang M, Farook M, Htoon HM, Mehta JS. Intraoperative patient experience and postoperative visual quality after SMILE and LASIK in a randomized, paired-eye, controlled study. *J Refract Surg* 2018;34:92-9.
  36. Wallerstein A, Jackson WB, Chambers J, Moezzi AM, Lin H, Simmons PA. Management of post-LASIK dry eye: A multicenter randomized comparison of a new multi-ingredient artificial tear to carboxymethylcellulose. *Clin Ophthalmol* 2018;12:839-48.
  37. Wong AH, Cheung RK, Kua WN, Shih KC, Chan TC, Wan KH. Dry eyes after smile. *Asia Pac J Ophthalmol (Phila)* 2019;8:397-405.
  38. Liu YC, Jung AS, Chin JY, Yang LW, Mehta JS. Cross-sectional study on corneal denervation in contralateral eyes following SMILE versus LASIK. *J Refract Surg* 2020;36:653-60.
  39. Liu Y-C, Yam GH-F, Lin MT-Y, Teo E, Koh S-K, Deng L, *et al.* Comparison of tear proteomic and neuromediator profiles changes between small incision lenticule extraction (SMILE) and femtosecond laser-assisted in-situ keratomileusis (LASIK). *Journal of Advanced Research*. 2021;29:67-81. DOI: <https://doi.org/10.1016/j.jare.2020.11.001>.
  40. Gao S, Li S, Liu L, Wang Y, Ding H, Li L, *et al.* Early changes in ocular surface and tear inflammatory mediators after small-incision lenticule extraction and femtosecond laser-assisted laser *in situ* keratomileusis. *PLoS One* 2014;9:e107370.
  41. Denoyer A, Landman E, Trinh L, Faure JF, Auclin F, Baudouin C. Dry eye disease after refractive surgery: Comparative outcomes of small incision lenticule extraction versus LASIK. *Ophthalmology* 2015;122:669-76.
  42. Reinstein DZ, Archer TJ, Gobbe M, Bartoli E. Corneal sensitivity after small-incision lenticule extraction and laser *in situ* keratomileusis. *J Cataract Refract Surg* 2015;41:1580-7.
  43. Scarcelli G, Pineda R, Yun SH. Brillouin optical microscopy for corneal biomechanics. *Invest Ophthalmol Vis Sci* 2012;53:185-90.
  44. Reinstein DZ, Archer TJ, Randleman JB. Mathematical model to compare the relative tensile strength of the cornea after PRK, LASIK, and small incision lenticule extraction. *J Refract Surg* 2013;29:454-60.
  45. Spuru B, Kling S, Hafezi F, Sekundo W. Biomechanical differences between femtosecond lenticule extraction (FLEx) and small incision lenticule extraction (SmILE) tested by 2D-extensometry in *ex vivo* porcine eyes. *Invest Ophthalmol Vis Sci* 2017;58:2591-5.
  46. Raevdal P, Grauslund J, Vestergaard AH. Comparison of corneal biomechanical changes after refractive surgery by noncontact tonometry: Small-incision lenticule extraction versus flap-based refractive surgery – A systematic review. *Acta Ophthalmol* 2019;97:127-36.



47. Damgaard IB, Ang M, Mahmoud AM, Farook M, Roberts CJ, Mehta JS. Functional optical zone and centration following SMILE and LASIK: A prospective, randomized, contralateral eye study. *J Refract Surg* 2019;35:230-7.
48. Titiyal JS, Kaur M, Rathi A, Falera R, Chaniyara M, Sharma N. Learning curve of small incision lenticule extraction: Challenges and complications. *Cornea* 2017;36:1377-82.
49. Wong CW, Chan C, Tan D, Mehta JS. Incidence and management of suction loss in refractive lenticule extraction. *J Cataract Refract Surg* 2014;40:2002-10.
50. Reinstein DZ, Archer TJ, Vida RS, Carp GI. Suction stability management in small incision lenticule extraction: Incidence and outcomes of suction loss in 4000 consecutive procedures. *Acta Ophthalmol* 2020;98:e72-80.
51. Reinstein DZ, Archer TJ, Vida RS, Carp GI. Suction stability management in SMILE: Development of a decision tree for managing eye movements and suction loss. *J Refract Surg* 2018;34:809-16.
52. Ang M, Chaurasia SS, Angunawela RI, Poh R, Riau A, Tan D, *et al.* Femtosecond lenticule extraction (FLEX): Clinical results, interface evaluation, and intraocular pressure variation. *Invest Ophthalmol Vis Sci* 2012;53:1414-21.
53. Reinstein DZ, Archer TJ, Gobbe M. Small incision lenticule extraction (SMILE) history, fundamentals of a new refractive surgery technique and clinical outcomes. *Eye Vis (Lond)* 2014;1:3.
54. Ivarsen A, Asp S, Hjortdal J. Safety and complications of more than 1500 small-incision lenticule extraction procedures. *Ophthalmology* 2014;121:822-8.
55. Shetty R, Negalur N, Shroff R, Deshpande K, Jayadev C. Cap lenticular adhesion during small incision lenticular extraction surgery: Causative factors and outcomes. *Asia Pac J Ophthalmol (Phila)* 2017;6:233-7.
56. Kim BK, Mun SJ, Lee DG, Choi HT, Chung YT. Chung's swing technique: A new technique for small-incision lenticule extraction. *BMC Ophthalmol* 2016;16:154.
57. Zhao Y, Li M, Yao P, Shah R, Knorz MC, Zhou X. Development of the continuous curvilinear lenticulerrhexis technique for small incision lenticule extraction. *J Refract Surg* 2015;31:16-21.
58. Ganesh S, Brar S. Lenticuloschisis: A "No Dissection" technique for lenticule extraction in small incision lenticule extraction. *J Refract Surg* 2017;33:563-6.
59. Ng AL, Cheng GP, Woo VC, Jhanji V, Chan TC. Comparing a new hydroexpression technique with conventional forceps method for SMILE lenticule removal. *Br J Ophthalmol* 2018;102:1122-6.
60. Sharma N, Urkude J, Chaniyara M, Titiyal JS. Microscope-integrated intraoperative optical coherence tomography-guided small-incision lenticule extraction: New surgical technique. *J Cataract Refract Surg* 2017;43:1245-50.
61. Available from: [http://www.asico.com/products/marker/corneal/jod-mehta-smile-pocket-dissector.html#\\_YG7CNy0et-0](http://www.asico.com/products/marker/corneal/jod-mehta-smile-pocket-dissector.html#_YG7CNy0et-0). [Last accessed on 2021 Feb 25].
62. Ji YW, Kim M, Kang DS, Reinstein DZ, Archer TJ, Choi JY, *et al.* Lower laser energy levels lead to better visual recovery after small-incision lenticule extraction: Prospective randomized clinical trial. *Am J Ophthalmol* 2017;179:159-70.
63. Li L, Schallhorn JM, Ma J, Cui T, Wang Y. Energy setting and visual outcomes in smile: A retrospective cohort study. *J Refract Surg* 2018;34:11-6.
64. Reinstein DZ, Stuart AJ, Vida RS, Archer TJ, Carp GI. Incidence and outcomes of sterile multifocal inflammatory keratitis and diffuse lamellar keratitis after smile. *J Refract Surg* 2018;34:751-9.
65. Kamiya K, Takahashi M, Shoji N, Naruse S. Two cases of epithelial ingrowth after small incision lenticule extraction. *Am J Ophthalmol Case Rep.* 2020 Jul 9;19:100819. doi: 10.1016/j.ajoc.2020.100819. PMID: 32715156; PMCID: PMC7374183.
66. Piccinini P, Vida RS, Piccinini R, Maiore I, Archer TJ, Carp GI, *et al.* Epithelial implantation treatment after small-incision lenticule extraction. *J Cataract Refract Surg* 2020;46:636-40.
67. Siedlecki J, Luft N, Priglinger SG, Dirisamer M. Enhancement options after myopic small-incision lenticule extraction (SMILE): A review. *Asia Pac J Ophthalmol (Phila)* 2019;8:406-11.
68. Siedlecki J, Luft N, Mayer WJ, Siedlecki M, Kook D, Meyer B, *et al.* CIRCLE enhancement after myopic SMILE. *J Refract Surg* 2018;34:304-9.
69. Reinstein DZ, Carp GI, Archer TJ, Vida RS. Outcomes of re-treatment by LASIK after SMILE. *J Refract Surg* 2018;34:578-88.
70. Pajic B, Cvejc Z, Pajic-Eggspuehler B. Cataract surgery performed by high frequency LDV Z8 femtosecond laser: Safety, efficacy, and its physical properties. *Sensors (Basel)* 2017;17:1429.
71. Izquierdo L Jr., Sossa D, Ben-Shaul O, Henriquez MA. Corneal lenticule extraction assisted by a low-energy femtosecond laser. *J Cataract Refract Surg* 2020;46:1217-21.
72. Fuest M, Liu YC, Coroneo MT, Mehta JS. Femtosecond laser assisted pterygium surgery. *Cornea* 2017;36:889-92.
73. Liu YC, Wittwer VV, Yusoff NZ, Lwin CN, Seah XY, Mehta JS, *et al.* Intraoperative optical coherence tomography-guided femtosecond laser-assisted deep anterior lamellar keratoplasty. *Cornea* 2019;38:648-53.
74. Liu YC, Ji AJS, Tan TE, Fuest M, Mehta JS. Femtosecond laser-assisted preparation of conjunctival autograft for pterygium surgery. *Sci Rep* 2020;10:2674.
75. Williams GP, Ang HP, George BL, Liu YC, Peh G, Izquierdo L, *et al.* Comparison of intra-ocular pressure changes with liquid or flat applanation interfaces in a femtosecond laser platform. *Sci Rep* 2015;5:14742.
76. Wang M, Zhang F, Copruz CC, Han L. First experience in small incision lenticule extraction with the femto LDV Z8 and lenticule evaluation using scanning electron microscopy. *J Ophthalmol* 2020;2020:6751826.
77. Riau AK, Liu YC, Lwin NC, Ang HP, Tan NY, Yam GH, *et al.* Comparative study of nJ- and μJ-energy level femtosecond lasers: evaluation of flap adhesion strength, stromal bed quality, and tissue responses. *Invest Ophthalmol Vis Sci.* 2014 Apr 24;55(5):3186-94.
78. Strohmaier C, Runge C, Seyeddain O, Emesz M, Nischler C, Dextl A, *et al.* Profiles of intraocular pressure in human donor eyes during femtosecond laser procedures – A comparative study. *Invest Ophthalmol Vis Sci* 2013;54:522-8.
79. Vetter JM, Holzer MP, Teping C, Weingärtner WE, Gericke A, Stoffelns B, *et al.* Intraocular pressure during corneal flap preparation: Comparison among four femtosecond lasers in porcine eyes. *J Refract Surg* 2011;27:427-33.
80. Yumusak E, Ornek K, Ozkal F. Bilateral simultaneous rhegmatogenous retinal detachment following laser *in situ* keratomileusis. *Case Rep Ophthalmol* 2016;7:341-5.
81. Verdina T, Date P, Benatti C, Lazzerini A, Fornasari E, De Maria M, *et al.* Evaluation of macular pigment optical density following femtosecond laser-assisted cataract surgery. *Clin Ophthalmol* 2019;13:821-8.
82. Pietilä J, Huhtala A, Mäkinen P, Uusitalo H. Flap characteristics, predictability, and safety of the Ziemer FEMTO LDV femtosecond laser with the disposable suction ring for LASIK. *Eye (Lond)* 2014;28:66-71.
83. Pradhan KR, Mosquera SA. Initial experience with the SCHWIND ATOS and SmartSight lenticule extraction. *J Clin Res Med* 2020;3:1-5.
84. Chiche A, Trinh L, Saada O, Faure JF, Auclin F, Baudouin C, *et al.* Early recovery of quality of vision and optical performance after refractive surgery: Small-incision lenticule extraction versus laser *in situ* keratomileusis. *J Cataract Refract Surg* 2018;44:1073-9.