



Contents lists available at ScienceDirect

International Journal of Surgery Case Reports

journal homepage: www.casereports.com

Subperiosteal orbital abscess from odontogenic origin: A case report

Joris Geusens^a, Kathia Dubron^{a,*}, Jan Meeus^a, Yannick Spaey^b, Constantinus Politis^{a,c}^a Department of Oral and Maxillofacial Surgery, Leuven University Hospitals, Leuven, Belgium^b Department of Oral and Maxillofacial Surgery, Mariaziekenhuis Noord-Limburg, Pelt, Belgium^c OMFS-IMPACT Research Group, Department of Imaging and Pathology, KU Leuven, Leuven, Belgium

ARTICLE INFO

Article history:

Received 26 May 2020

Received in revised form 1 July 2020

Accepted 3 July 2020

Available online 16 July 2020

Keywords:

Odontogenic infection
 Subperiosteal orbital abscess
 Extraoral drainage
 Antibiotics
 Corticosteroids
 Case report

ABSTRACT

INTRODUCTION: Subperiosteal orbital abscess is a rarely reported complication of odontogenic infections and can be associated visual impairment and neurological symptoms. Because of fast infection spreading, delay in diagnosis and treatment can result in permanent damage.

PRESENTATION OF CASE: A 55-year old presented with a right-sided subperiosteal orbital abscess originating from a decayed first upper molar. The associated loss of vision improved only after a extraoral surgical drainage. Three years later, recurrent headaches, photobia and ptosis still persist.

DISCUSSION: Our case demonstrates a rare but potentially hazardous complication of untreated dental infections. The effect of antibiotics is often overestimated, and lack of treatment may lead to serious sequelae, certainly when the orbital infection is located posterior to the orbital septum. When intraoral drainage is insufficient, the infection should be accessed extraorally.

CONCLUSION: Orbital infections require a thorough clinical evaluation, including the oral cavity as dental infections may be overlooked. Dental radiography plays a major role. Prompt and adequate treatment is crucial in preventing further spreading of odontogenic infections.

© 2020 The Authors. Published by Elsevier Ltd on behalf of IJS Publishing Group Ltd. This is an open access article under the CC BY-NC-ND license (<http://creativecommons.org/licenses/by-nc-nd/4.0/>).

1. Introduction

Infections of odontogenic origin are common oral pathologies in dentistry and oral surgery. However, purulent material from odontogenic abscesses can spread in various ways, often following the path of least resistance. Rare, but ominous, complications should be suspected due to rapid contiguous spread of the infection. Dental infections in the upper jaw can spread to the maxillary sinus, ultimately leading to orbital involvement. The exact localization of the infection is sometimes difficult to identify due to hampered clinical examination. Therefore, contrast enhanced computed tomography (CT) is an essential part of the diagnosis of orbital infections [1]. Accurate diagnosis and early management are critical in preventing serious ophthalmological and neurological complications [2,3].

Orbital infections can be characterized as either preseptal (peri-orbital) or postseptal (orbital) depending on its location in relation to the orbital septum [4]. Preseptal cellulitis compromises the eyelid and soft tissues anterior to the orbital septum which can often be treated with antibiotic therapy. On the other hand, postseptal infection requires a more aggressive approach, with a more frequent need for surgical intervention. In the 1970s, Chandler proposed a

Table 1

Chandler's classification system.

Group I	Preseptal	Preseptal orbital cellulitis with inflammation and edema anterior to the orbital septum
Group II	Postseptal	Postseptal orbital cellulitis with extension of the inflammation and edema beyond the orbital septum
Group III	Postseptal	Subperiosteal abscess between the periorbit and the bony wall of the orbit
Group IV	Postseptal	Intraorbital abscess where purulent collection occurs within orbit
Group V	Postseptal	Cavernous sinus thrombosis, posterior extension through the superior orbital veins

classification system for orbital infections that is still commonly used today [5]. As shown in Table 1, group 3 refers to a subperiosteal abscess and is defined as a collection of purulent material beneath the periosteum of the orbital wall. The paper-thin nature of the lamina papyracea facilitates communication between the ethmoid air cells and the subperiosteal space on the medial wall of the orbit, the most common location of orbital subperiosteal abscess formation [6]. We report a case from our academic center of subperiosteal orbital abscess in relation to an odontogenic infection. The work has been reported in line with the SCARE guidelines [7].

* Corresponding author at: Kathia Dubron, Department of Oral and Maxillofacial Surgery, Leuven University Hospitals, Kapucijnenvoer 33, 3000, Leuven, Belgium.
 E-mail address: kathia.dubron@uzleuven.be (K. Dubron).

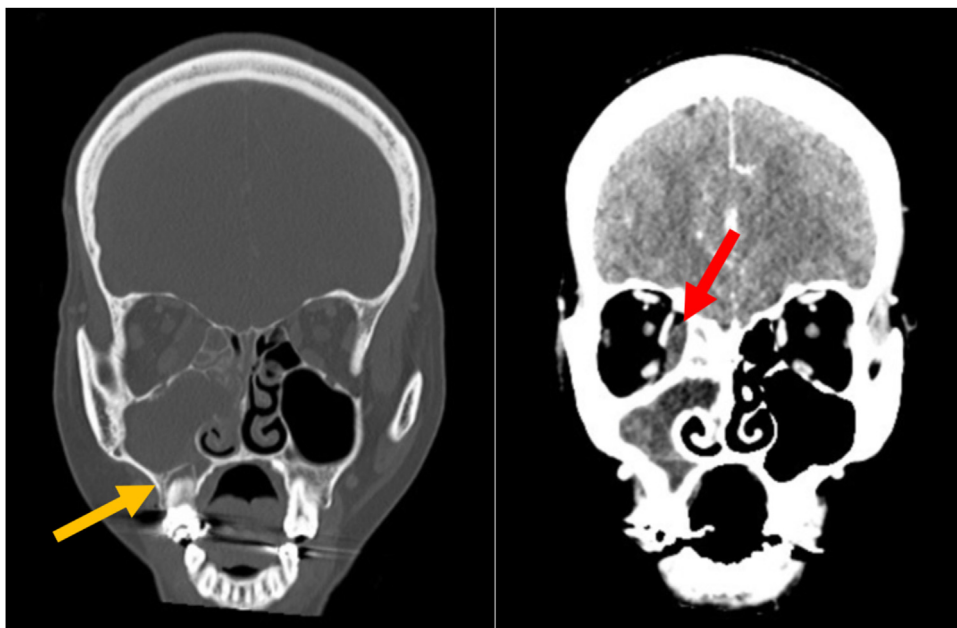


Fig. 1. CT scan on day 1, coronal view. Note the right-sided maxillary and ethmoidal sinusitis and apical translucency surrounding the first upper molar (orange arrow). The medial surface of the right orbit appears clouded, suggesting intraorbital infection spread (red arrow).

2. Case presentation

A 55-year-old, otherwise healthy woman was admitted to the hospital complaining of impaired vision, unilateral orbital swelling, and reduced and painful eye movements since one day. One week earlier, she contacted her dentist because of a dull and constant toothache on the upper right side from which she was suffering since one month. The dentist had removed decay from the distal surface of the first upper molar and placed a composite filling. She had started taking antibiotics 2 days prior admission (1500 mg amoxicillin per day) and admitted having taken an overdose of paracetamol (up to 10,000 mg in one day). Her vital signs were within normal limits except for an elevated temperature (37.8 °C) and nausea.

Clinical examination revealed swelling with redness around the right eye that was warm to the touch. The patient was not able to open her right eye because of the swelling. She reported having impaired vision and photophobia. Orthopantomographic radiography revealed apical radiolucency around the first molar in the upper right quadrant. Contrast enhanced CT (Fig. 1) showed right-sided pansinusitis of odontogenic origin and associated intraorbital fluid collection with air trapping, suggestive of a subperiosteal abscess. We found no intracranial spread of the inflammatory process or any signs indicative of cavernous sinus thrombosis. Standard laboratory testing revealed leukocytosis (20,540 WBC/mm³), elevated C-reactive protein levels (84 mg/L), and normal plasma levels of acetaminophen. Subsequently, the first molar was extracted under intravenous sedation with midazolam and fentanyl, with concomitant intraoral drainage and creation of an oroantral communication. A rubber drain was sutured into the communication to enable drainage of pus (Fig. 2). No microorganisms could be isolated. The patient was hospitalized and given an intravenous regimen of amoxicillin-clavulanate, associated with vancomycin and combined with metronidazole.

Because of increasing deterioration of visual acuity and color vision on day 3, funduscopy was performed for the right eye, revealing venous distention and tortuosity. Proptosis and chemosis were present. A new CT scan showed expansion of the subperiosteal abscess, with compression of the medial rectus

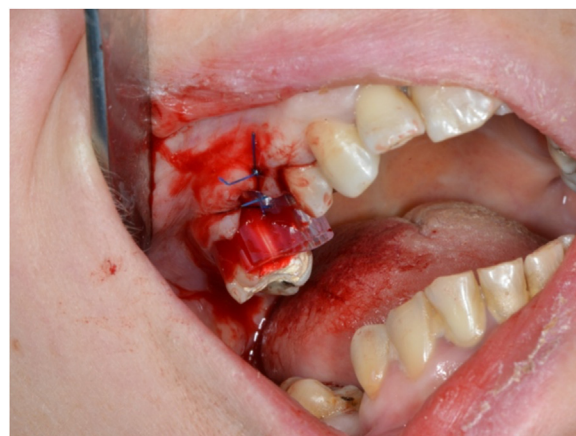

Fig. 2. Intraoral view 1 day following extraction of the first upper molar. A rubber drain is fixed in the newly created oroantral communication.

muscle and obliteration of the orbital adipose tissue surrounding the optic nerve (Fig. 3). The abscess was again drained under general anesthesia, this time the infection site was approached extraorally. Two stab incisions were made approximately 1 cm superior and inferior to the medial canthus. Purulent material was collected and *Staphylococcus epidermidis* isolated. After thorough rinsing, two drains were left in place (Fig. 4). Supported by intravenous administration of 100 mg solumedrol per day, recuperation of the patient's vision was noted. On day 9, intravenous antibiotics were switched to an oral regimen for another 5 days (500/125 mg amoxicillin/clavulanate three times per day and 500 mg metronidazole three times per day). On day 12, the extraoral drains were removed and the patient was discharged from the hospital. The criterium for removal of the drains and discharge was a continuous decrease of swelling for at least two consecutive days. On day 18, the intraoral drain was removed in the outpatient clinic, and the fistula was closed using a buccal flap. One week later, no signs of oroantral communication were present. The patient was followed up through the outpatient dental and ophthalmological departments. Three

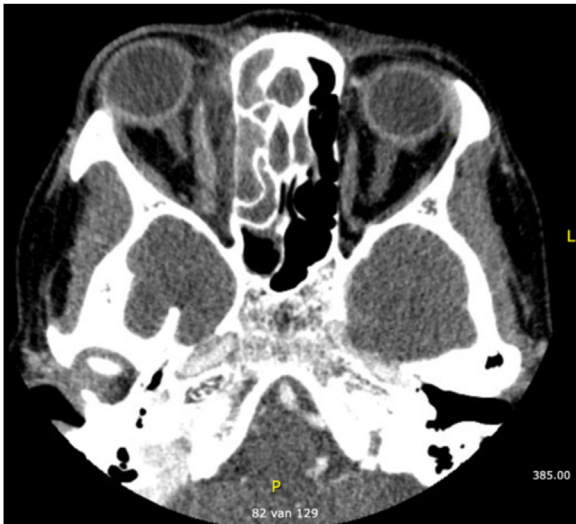


Fig. 3. CT scan of the orbital abscess on day 3, showing compression of the medial rectus muscle. Proptosis is present.

years after discharge, she still has a notable photophobia and frequent headaches. She also experiences difficulty opening the right eye, but only during physical or mental fatigue.

3. Discussion

Before the advent of the antibiotic era, profound knowledge of head and neck anatomy was needed for successful treatment of spreading dental infection. Contrary to popular belief among many health care providers, antibiotics alone are often ineffective in the treatment of acute dental infections and do not guarantee further arrest of the spread [8]. Dental infection spread can be severe and unpredictable, especially in immunocompromised patients, e.g. elderly people, recent steroid therapy, cancer therapy, HIV seropositivity or patients with inadequately controlled diabetes [8,9]. The route of infection spread is determined by the relation of the infected tooth to adjacent muscles and fascial planes. Possible routes of odontogenic infection spread are the oral and nasal cavities, maxillary sinuses, floor of mouth, submandibular space, buccal space, parapharyngeal space, the neck, periorbital area, cavernous sinus, or mediastinum [8]. Therefore, understanding the fasciae and fascial spaces as described by Dingman and others remains relevant today [10,11]. The “closed-box” anatomy of the orbit is often referred to as a predisposing factor for serious sequelae [3]. Anatomical features need to be taken into account when assessing the severity of the orbital infection. The most important anatomical barrier is the periosteum of the orbit, including its reflections at the orbital margins forming the orbital septum or palpebral fascia. Chandler’s classification system is widely used for differentiating

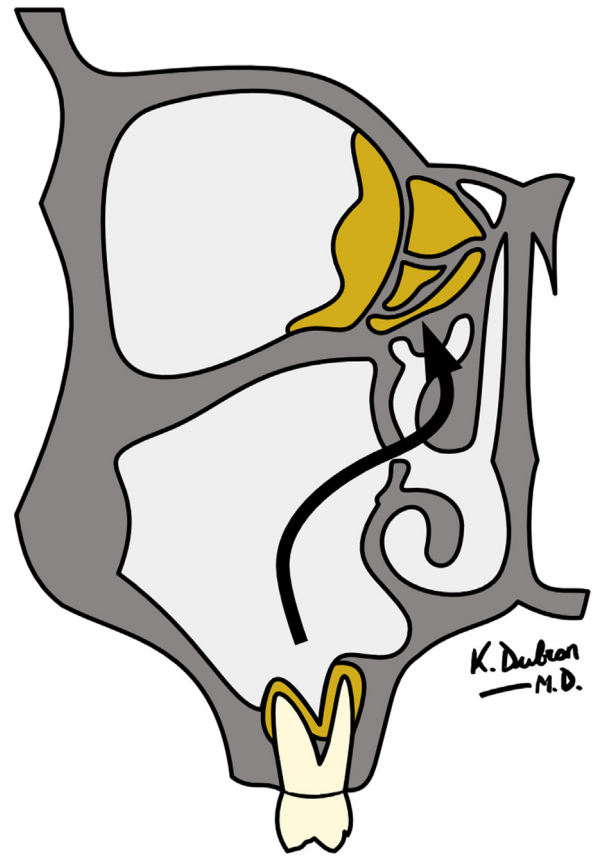


Fig. 5. Presumed route of infection spread, originating from the first upper molar. After extension into the maxillary sinus and adjacent ethmoid air cells, the medial wall of the orbit is perforated leading to a collection of pus located subperiosteally.

between types of orbital infections [5]. There is a good correlation between orbital examination and CT scan findings [12]. The presumed path of spread is illustrated in Fig. 5. The orbit is reached through the maxillary sinus, followed by the ethmoid air cells, finally perforating the medial wall of the orbit. This wall, the lamina papyracea, contains multiple natural dehiscences, as well as neurovascular perforations.

The main clinical features of orbital abscesses are periorbital swelling and proptosis. Postseptal infections extent beyond the orbital septum, increasing the pressure in and around the orbit and pushing the globe anteriorly. The optic nerve may be involved. Extraocular eye muscles can be affected due to mass effect, consequently causing limitation of eye movements with or without diplopia or pain. An ophthalmologic examination should be conducted to check whether there is a decrease of visual acuity or color vision. Chemosis and other constitutional symptoms (e.g. fever,

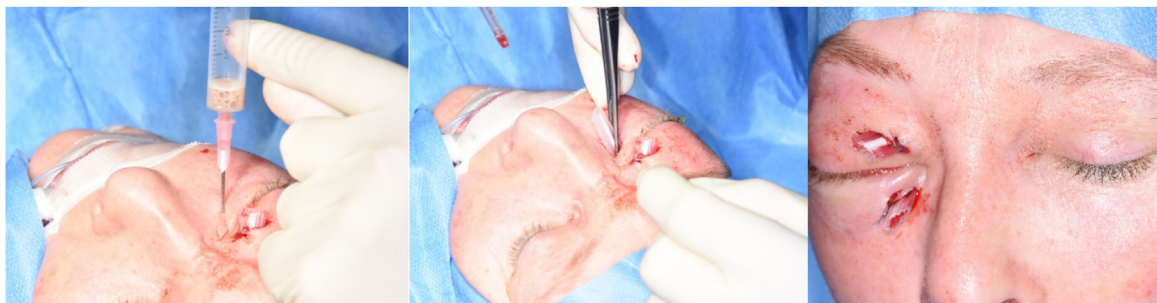

Fig. 4. Surgical exploration of the orbital abscess on day 3 through incisions made in the upper and lower eyelids. For each incision, a drain was left in place.

malaise, or elevated inflammatory markers in the blood) can occur. Periapical radiography or an orthopantomogram may be useful when a dental origin is suspected [1]. A recent dental history is very common, but toothache is not a consistent feature in orbital abscess [13]. More than 70 % of orbital infections develop as a complication of paranasal sinusitis, whereas the remaining 30 % originate from the eyelids, tonsils, intracranial areas, middle ear, and odontogenic structures [14]. Nevertheless, the presence of unilateral sinusitis should always trigger the physician to examine the oral cavity; approximately 75 % of unilateral maxillary sinusitis cases are provoked by odontogenic pathology [15].

Many antibiotic regimens have been proposed in the literature [13,16]. Bullock and Fleishman described four cases of orbital infection, one of which ended fatally due to resistance to the initially administered antibiotic, combined with delay of surgical drainage [2].

Beta-lactam antibiotics are generally used to treat orbital infections in combination with metronidazole to cover anaerobic bacteria. In this case report, glycopeptide antibiotics were added based on empirical evidence, imposed by the Department of Ophthalmology. Cautious monitoring of drug plasma levels is required when using vancomycin because of a narrow therapeutic index.

The use and posology of corticosteroids is still debated. Some authors prefer the use of oral corticosteroids [17]. Others advocate the use of intravenously administered corticosteroids, describing beneficial effects in a pediatric population [18]. In this case report, corticosteroids were administered to reduce swelling and the inflammatory response. However, serious concerns have been raised that the infection may be masked due to depression of the patient's immune response [19].

In the presented case, subperiosteal abscess was an indication for surgery. Because of odontogenic etiology, the responsible upper jaw element was extracted. Although an oroantral communication is desirable for adequate drainage in maxillary sinusitis, this is not always sufficient. If insufficient, the Caldwell Luc technique can be used, or surgical drainage can be approached extraorally. Incisions can be made in the medial or lateral superior palpebra, frontozygomatically, or even through the orbital floor [13,14]. In the described case, both the upper and lower eyelids were approached medially via stab incisions. The timing of surgical drainage influences the appearance and level of visual reduction. A literature review found that the chance of complete visual recovery is higher when drainage is performed within 24 h [13]. Generally, fast management of orbital infections is necessary, including an extraoral approach if required. If not treated properly, a true orbital abscess can result in blindness, cavernous sinus thrombosis, meningitis, subdural empyema, brain abscess, and death [2,10]. The patient in this report still suffers light hypersensitivity and frequent headaches 3 years after surgical treatment.

4. Conclusion

This case report demonstrates the importance of recognizing odontogenic infections resulting in orbital infections, which are rare but can lead to serious sequelae. The need for urgent imaging, appropriate antimicrobial therapy, and the implementation of adequate and timely surgical drainage is emphasized. Antibiotic therapy alone is not sufficient without surgical drainage. Initially, intraoral drainage should be attempted. When the infection does not resolve, extraoral drainage should be carried out urgently considering the specific anatomical features of the midface. Treatment management should involve radiologists, ophthalmologists, otolaryngologists, and oral and maxillofacial surgeons.

Declaration of Competing Interest

None.

Funding

None.

Ethical approval

No ethical approval was necessary for this case report.

Consent

Written informed consent was obtained from the patient for publication of this case report and accompanying images. A copy of the written consent is available for review by the Editor-in-Chief of this journal on request.

Author contribution

All authors have individual and substantial contribution to the article.

Geusens J.: data collection, study design, writing the paper.

Dubron K.: data collection, study design, writing the paper.

Meeus J.: data collection, review.

Spaey Y.: surgery, review.

Politis C.: surgery, writing the paper, review.

All authors approve the final article.

Registration of research studies

1 Name of the registry: /

2 Unique identifying number or registration ID: /

3 Hyperlink to your specific registration (must be publicly accessible and will be checked): /

Guarantor

Prof. dr. Constantinus Politis.

Joris Geusens, MD.

Provenance and peer review

Not commissioned, externally peer-reviewed.

Acknowledgments

None.

Appendix A. Supplementary data

Supplementary material related to this article can be found, in the online version, at doi:<https://doi.org/10.1016/j.ijscr.2020.07.014>.

References

- [1] P.A. Caruso, L.M. Watkins, P. Suwansaard, M. Yamamoto, M.L. Durand, L.V. Romo, S.P. Rincon, H.D. Curtin, Odontogenic orbital inflammation: clinical and CT findings - initial observations, *Radiology* 239 (2006) 187–194, <http://dx.doi.org/10.1148/radiol.2391041243>.
- [2] J.D. Bullock, J.A. Fleishman, The spread of odontogenic infections to the orbit: diagnosis and management, *J. Oral Maxillofac. Surg.* 43 (1985) 749–755, [http://dx.doi.org/10.1016/0278-2391\(85\)90328-3](http://dx.doi.org/10.1016/0278-2391(85)90328-3).

- [3] E.H. Miller, D.K. Kassebaum, Managing periorbital space abscess. Secondary to dentoalveolar abscess, *J. Am. Dent. Assoc.* 126 (1995) 469–472, <http://dx.doi.org/10.14219/jada.archive.1995.0209>.
- [4] A.M. Botting, D. McIntosh, M. Mahadevan, Paediatric pre- and post-septal peri-orbital infections are different diseases. A retrospective review of 262 cases, *Int. J. Pediatr. Otorhinolaryngol.* 72 (2008) 377–383, <http://dx.doi.org/10.1016/j.ijporl.2007.11.013>.
- [5] J.R. Chandler, D.J. Langenbrunner, E.R. Stevens, The pathogenesis of orbital complications in acute sinusitis, *Laryngoscope* 80 (1970) 1414–1428, <http://dx.doi.org/10.1288/00005537-197009000-00007>.
- [6] H.D. Curtin, J.D. Rabinov, Extension to the orbit from paraorbital disease: the sinuses, *Radiol. Clin. North Am.* 36 (1998) 1201–1213, [http://dx.doi.org/10.1016/S0033-8389\(05\)70240-2](http://dx.doi.org/10.1016/S0033-8389(05)70240-2).
- [7] R.A. Agha, M.R. Borrelli, R. Farwana, K. Koshy, A.J. Fowler, D.P. Orgill, For the SCARE Group, The SCARE 2018 statement: updating consensus surgical CAse REport (SCARE) guidelines, *Int. J. Surg.* 60 (2018) 132–136, <http://dx.doi.org/10.1016/j.ijvsu.2018.10.028>.
- [8] D.P. Robertson, W. Keys, R.R. Richardson, R. Burns, A.J. Smith, Management of severe acute dental infections, *BMJ* 350 (2015) 1–8, <http://dx.doi.org/10.1136/bmj.h1300>.
- [9] T.R. Flynn, Surgical management of orofacial infections, *Atlas Oral Maxillofac. Surg. Clin. North Am.* 8 (2000) 77–100, [http://dx.doi.org/10.1016/S1061-3315\(18\)30043-X](http://dx.doi.org/10.1016/S1061-3315(18)30043-X).
- [10] R.O. Dingman, The management of acute infections of the face and jaws, *Am. J. Orthod. Oral Surg.* 25 (1939) 780–794, [http://dx.doi.org/10.1016/S0096-6347\(39\)90225-5](http://dx.doi.org/10.1016/S0096-6347(39)90225-5).
- [11] M. Grodinsky, E.A. Holyoke, The fasciae and fascial spaces of the head, neck and adjacent regions, *Am. J. Anat.* 63 (1938) 367–408, <http://dx.doi.org/10.1002/aja.1000630303>.
- [12] H.J. Lee, M. Jilani, L. Frohman, S. Baker, CT of orbital trauma, *Emerg. Radiol.* 10 (2004) 168–172, <http://dx.doi.org/10.1007/s10140-003-0282-7>.
- [13] P. Procacci, A. Zangani, A. Rossetto, A. Rizzini, G. Zanette, M. Albanese, Odontogenic orbital abscess: a case report and review of literature, *Oral Maxillofac. Surg.* 21 (2017) 271–279, <http://dx.doi.org/10.1007/s10006-017-0618-1>.
- [14] B.P. Allan, M.A. Egbert, R.W.T. Myall, Orbital abscess of odontogenic origin. Case report and review of the literature, *Int. J. Oral Maxillofac. Surg.* 20 (1991) 268–270, [http://dx.doi.org/10.1016/S0901-5027\(05\)80150-X](http://dx.doi.org/10.1016/S0901-5027(05)80150-X).
- [15] M. Troeltzsch, C. Pache, M. Troeltzsch, G. Kaeppler, M. Ehrenfeld, S. Otto, F. Probst, Etiology and clinical characteristics of symptomatic unilateral maxillary sinusitis: a review of 174 cases, *J. Craniomaxillofac. Surg.* 43 (2015) 1522–1529, <http://dx.doi.org/10.1016/j.jcms.2015.07.021>.
- [16] L. Howe, N.S. Jones, Guidelines for the management of periorbital cellulitis/abscess, *Clin. Otolaryngol. Allied Sci.* 29 (2004) 725–728, <http://dx.doi.org/10.1111/j.1365-2273.2004.00889.x>.
- [17] N. Pushker, L.K. Tejwani, M.S. Bajaj, S. Khurana, T. Velpandian, M. Chandra, Role of oral corticosteroids in orbital cellulitis, *Am. J. Ophthalmol.* 156 (2013) 178–183, <http://dx.doi.org/10.1016/j.ajo.2013.01.031>, e1.
- [18] M.T. Yen, K.G. Yen, Effect of corticosteroids in the acute management of pediatric orbital cellulitis with subperiosteal abscess, *Ophthalm. Plast. Reconstr. Surg.* 21 (2005) 363–366, <http://dx.doi.org/10.1097/01.iop.0000179973.44003.f7>.
- [19] J.B. Holds, Commentary on effect of corticosteroids in the acute management of pediatric orbital cellulitis with subperiosteal abscess, *Ophthalmic Plast. Reconstr. Surg.* 21 (2005) 366–367, <http://dx.doi.org/10.1097/01.iop.0000180752.57062.36>.

Open Access

This article is published Open Access at [sciencedirect.com](https://www.sciencedirect.com). It is distributed under the [IJSCR Supplemental terms and conditions](#), which permits unrestricted non commercial use, distribution, and reproduction in any medium, provided the original authors and source are credited.