



## Original Article

# Supra-acetabular fixation and sacroiliac screws for treating unstable pelvic ring injuries: preliminary results from 20 patients<sup>☆</sup>



Rodrigo Pereira Guimarães\*, Arthur de Góes Ribeiro, Oliver Ulson, Ricardo Bertozzi de Ávila, Nelson Keiske Ono, Giancarlo Cavalli Polesello

Faculdade de Ciências Médicas da Santa Casa de São Paulo (FCMSCSP), São Paulo, SP, Brazil

## ARTICLE INFO

## Article history:

Received 30 September 2014

Accepted 6 April 2015

Available online 2 March 2016

## Keywords:

Surgical procedures, minimally invasive

External fixators

Fracture fixation, internal

Retrospective studies

## ABSTRACT

**Objective:** To analyze the treatment results from 20 patients who underwent an alternative osteosynthesis method as definitive treatment for pelvic ring fractures.

**Methods:** A retrospective analysis was conducted on a series of 20 patients with pelvic ring fractures (Tile type C) and a high risk of postoperative infection, who were treated at Santa Casa de Misericórdia de São Paulo between August 2004 and December 2012. The patients underwent percutaneous supra-acetabular external fixation in association with cannulated 7.0 mm iliosacral screws.

**Results:** The patients' mean age was 40 years (range 22–77 years) and the mean length of follow-up was 18.5 months (range 3–69 months). At the end of the treatment, ten patients (50%) were classified as having good results, nine patients (45%) had fair results and one patient (5%) did not have any improvement. Six patients presented complications, and paresthesia of the lateral femoral cutaneous nerve was the most frequent of these (two patients).

**Conclusion:** Supra-acetabular external fixation in association with iliosacral percutaneous osteosynthesis is a good definitive treatment method for patients with a high risk of postoperative infection.

© 2016 Sociedade Brasileira de Ortopedia e Traumatologia. Published by Elsevier Editora Ltda. All rights reserved.

<sup>☆</sup> Work performed in the Hip Group, Department of Orthopedics and Traumatology, Faculdade de Ciências Médicas da Santa Casa de São Paulo (FCMSCSP), Irmandade de Santa Casa de Misericórdia de São Paulo (ISCMSP), São Paulo, SP, Brazil.

\* Corresponding author.

E-mail: [clinicaguimaraes@gmail.com](mailto:clinicaguimaraes@gmail.com) (R.P. Guimarães).

<http://dx.doi.org/10.1016/j.rboe.2016.02.010>

2255-4971/© 2016 Sociedade Brasileira de Ortopedia e Traumatologia. Published by Elsevier Editora Ltda. All rights reserved.

## Tratamento das lesões instáveis do anel pélvico com fixador supra-acetabular e parafusos sacroilíacos: resultados preliminares em 20 pacientes

### R E S U M O

#### Palavras-chave:

Procedimentos cirúrgicos minimamente invasivos  
Fixadores externos  
Fixação interna de fraturas  
Estudos retrospectivos

**Objetivo:** Avaliar os resultados do tratamento de 20 pacientes que usaram como tratamento definitivo um método de osteossíntese opcional para fraturas do anel pélvico.

**Métodos:** Foi feita uma análise retrospectiva da série de 20 casos de pacientes com fratura do anel pélvico tipo C de Tile, portadores de alto risco de infecção pós-operatória, tratados na Santa Casa de Misericórdia de São Paulo entre agosto de 2004 e dezembro de 2012, submetidos a fixação externa supra-acetabular percutânea associada com parafusos canulados iliosacrais de 70 mm.

**Resultados:** A média de idade dos pacientes foi de 40 anos (mínimo de 22; máximo de 77) e o tempo médio de seguimento foi de 18,5 meses (mínimo de três; máximo de 69). Após o término do tratamento dez pacientes (50%) foram classificados com bons resultados, nove (45%) tiveram desfecho regular e um (5%) não apresentou melhora alguma. Seis apresentaram complicações. A parestesia do nervo cutâneo femoral lateral foi a mais frequente (dois pacientes).

**Conclusão:** A fixação externa supra-acetabular associada a osteossíntese percutânea iliosacral é um bom método de tratamento definitivo para os pacientes com alto risco de infecção pós-operatória.

© 2016 Sociedade Brasileira de Ortopedia e Traumatologia. Publicado por Elsevier Editora Ltda. Todos os direitos reservados.

## Introduction

Pelvic ring fractures form part of the routine within traumatology. Occurrences of higher-energy trauma and involvement of young adults in these accidents are matters of concern.<sup>1</sup> The associated traumatic injuries often require neurosurgery, abdominal surgery, colostomy, drains and lengthy stays in intensive care centers<sup>2-4</sup> and add difficulty to orthopedic treatments.

Given that osteosynthesis in critical patients needs to be effective and minimally invasive, one option for treating pelvic fractures in these patients might be supra-acetabular external fixation in association with sacroiliac percutaneous fixation.

The objective of this study was to evaluate the results from treating 20 patients with unstable fractures of the pelvic ring who underwent surgery consisting of supra-acetabular external fixation in association with sacroiliac percutaneous fixation, between August 2004 and December 2012.

## Methodology

A retrospective analysis was conducted on the medical files of 20 patients with pelvic ring fractures who were treated between August 2004 and December 2012. These patients underwent fixation of the anterior region of the pelvic ring by means of supra-acetabular pins and also sacroiliac pins using a percutaneous technique with cannulated 7 mm screws (Fig. 1A and B). The surgical fixations were performed during the same operation.

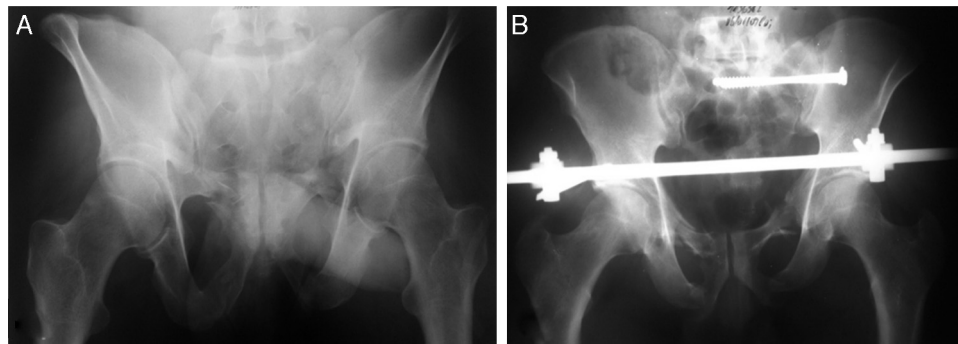
The inclusion criteria were that the patients had to be adults, aged 18–80 years, with fractures classified as Tile type C,<sup>5</sup> who presented a risk of postoperative complications with internal osteosynthesis. Prolonged hospital stay, decompensated clinical diseases, concomitant surgical diagnoses (abdominal and/or pelvic surgery) and presence of ostomy, drains and probes were considered to be risk factors leading to the need for open reduction and internal fixation with plates. The exclusion criteria were poorly filled out medical records, patients under the age of 18 years, patients with injuries classified as Tile types A and B, patients treated without surgery, patients treated by means of osteosynthesis with plates and cases of death during the preoperative period.

The epidemiological data described were sex, age, trauma mechanism, associated injuries and the result from the treatments with the surgical technique used. The injuries to the pelvic ring were described as fractures in the rami (R), disjunction of the symphysis (S) or both of these together (S + R), or as injuries of the sacroiliac complex (SI). We considered that cases presented bilateral injury when fractures were present on both sides of the pelvic ring.

The fractures were evaluated using radiographic and tomographic images, before and after the surgical treatment, always by three orthopedists. After the surgery, the reductions were stratified as anatomical, displaced by 1–5 mm or displaced more than 5 mm.

The external fixators were removed 16 weeks after the surgical treatment, except in one case in which this date had to be brought forward. No iliosacral screw was removed during the study.

The clinical result from the treatments was classified as good (full return to previous activities without complaints),



**Fig. 1 – (A) Image of the pelvis in outlet view, showing fracturing of the pubic rami and the sacrum on the left. (B) Postoperative coronal image of the pelvis with two sacroiliac screws in the S1 body and supra-acetabular external fixator.**

fair (return to activities with complaints) or poor (no return to previous activities and/or unsatisfactory return). We also compared these results with the postoperative radiographs.

## Results

Twenty patients were followed up for periods ranging from 3 to 69 months. The mean length of follow-up was 18.5 months (standard deviation, SD, of 19.99 months).

The patients' mean age was 40 years (minimum of 22 and maximum of 77; SD: 14.7). Eleven patients (55%) were male. The main cause found was being run over (ten; 50%), followed by falling from a height (five; 25%), car crashes (three; 15%) and accidents with motorcycles (two; 10%).

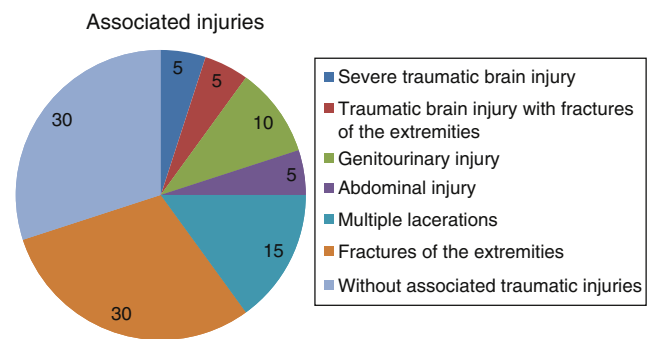
All of the 20 cases were Tile type C. In 18 cases (90%), there was fracturing of the pubic rami, while disjunction of the symphysis occurred in five patients (25%). We found 15 cases of R+SI (75%); three cases of S+R+SI (15%); and two cases of S+SI (10%).

The injury was bilateral in ten cases (50%). Two cases (10%) occurred solely on the right side and eight cases (40%) on the left side.

Fourteen patients (70%) presented some form of associated traumatic injury: one (5%) suffered severe traumatic brain injury alone; one (5%) suffered traumatic brain injury and fractures of the extremities; one (5%) presented injury to the urethra; one (5%) had an abdominal injury that required laparotomy and embolization; one (5%) underwent cystostomy; three (15%) presented abdominal and pelvic lacerations and hemorrhage, with long stays in the intensive care unit; and six (30%) presented other associated fractures alone (Fig. 2). The others (30%) had diagnoses of pelvic fracture alone, but presented contraindications for internal osteosynthesis: three (15%) with previous laparotomy; one (5%) with abdominal surgery and infection of the urinary tract; one (5%) with underlying coagulopathy; and one (5%) with deep infection on the skeletal traction pins.

Anatomical reduction was achieved in 14 cases (70%). Two cases (10%) continued to present displacements of 1–5 mm after the reduction and, in three cases (15%), the best reduction obtained still presented a displacement of more than 5 mm.

Complications occurred in six cases (30%): two (10%) presented neuropraxia of the lateral femoral cutaneous nerve;



**Fig. 2 – Presence and distribution of associated injuries at time of patients' admission to hospital.**

one (5%) presented skewed consolidation and evolved with lumbosacral and sacroiliac pain; and one (5%) continued to present occasional sacroiliac pain alone. There was one case (5%) of pseudarthrosis of the pubic rami in association with postoperative infection. This patient was treated with intravenous antibiotics and removal of the synthesis materials, and evolved with loss of reduction. One patient (5%) continued to present leg-length discrepancy. There were no deaths after the surgery and the remaining patients (14; 70%) did not present any complications.

Over the course of the clinical outpatient follow-up, ten patients (50%) returned to their activities and did not report any complaints or limitations. These patients were classified as presenting good results. Nine (45%) continued to have occasional complaints, characterized mainly by diffuse pain in the posterior region, and were classified as having fair results. One patient (5%) said that there had not been any type of improvement, with continuing lumbalgia, muscle pain and limb shortening, and was classified as a poor result.

## Discussion

For a long time, pelvic ring fractures have intrigued physicians. According to Perry,<sup>6</sup> around 2% of all fractures of the body are located in the pelvic ring, but among multiple trauma victims, this percentage may reach 25%.<sup>7,8</sup> Patients with pelvic fractures present a variety of severe associated injuries<sup>7</sup> and

higher mortality,<sup>9</sup> and survivors have a high chance of having to live with some form of permanent sequela.<sup>4</sup> Surgical treatment of these injuries during the acute phase provides the best results<sup>1-3,10</sup> and enables rehabilitation with a return to community life.

Pelvic fixation can be done using plates or external fixators.<sup>11</sup> Fractures classified as Tile type B or C are preferentially treated by means of rigid internal fixation,<sup>12</sup> but direct reduction gives rise to greater operative trauma, blood loss and risk of infection,<sup>13</sup> and for this reason needs to be considered on a case-by-case basis.<sup>11,12</sup> Thus, patients in a more severe condition and/or presenting colonization by resistant microorganisms of intensive care units may be benefited through minimally invasive orthopedic treatment.

Use of external fixators for the pelvis dates from the 1950s.<sup>14</sup> Several studies have now attempted to establish a more versatile, safer and more resistant means of construction,<sup>14-16</sup> but there is still no consensus in this regard.<sup>17</sup> Anterosuperior assemblies (above the iliac crest) and anteroinferior assemblies (supra-acetabular) are the ones most used.<sup>14</sup>

The supra-acetabular method is more stable and longer lasting, and it needs few incisions. The technique requires the aid of radioscopy. Each Schanz pin is positioned cranially to the hip joint and slightly laterally to the anteroinferior iliac spine, oriented toward the greater sciatic notch.<sup>3</sup> The stabilization is completed anteriorly by one or two bars. Care is needed, so as not to injure the lateral femoral cutaneous nerve, not to position the pin within the joint and not to invade the greater sciatic notch. A safety zone for placing the pins has been described by some authors.<sup>14-16</sup> The small cuts in the skin and the lesser degree of manipulation of the fracture make this an advantageous method in comparison with the traditional access routes for internal fixation.

Sacroiliac osteosynthesis is essential in cases classified as Tile type C,<sup>12</sup> and several types of implant form part of the therapeutic arsenal.<sup>18,19</sup>

Percutaneous fixation is simple and effective, and is the preferred method in the majority of the cases.<sup>20,21</sup> A single 7.0 mm cannulated screw is usually sufficient, but two screws may be used when there is greater instability.<sup>18,20</sup> In the operative technique, correct implant positioning with the threaded end inside the S1 body is fundamental.<sup>18</sup> Some studies have shown that intraoperative difficulties exist in situations of anatomical variations of the sacrum and inadequate fluoroscopic images.<sup>22,23</sup>

The mean age of 40 years found in our results was similar to the data in the literature,<sup>1,8</sup> as was also the frequency of occurrences according to sex (55% male). In our sample, accidents with vehicles accounted for 75% of the cases that were treated using the method described here, but motorcycle accidents did not account for the majority of these cases.

Although sacroiliac dislocation, sacral fractures and growth fractures are different injuries, they were considered together in the same group (SI), so as to have a better grouping for statistical comprehension. There would not be any advantage in separating them according to their nature, given that all of them are vertically unstable fractures that require osteosynthesis of the posterior region.

We found that up to 50% of the patients presented other associated injuries when they arrived at the hospital, which reflects the severity of these cases and corroborates the need for differentiated attendance. This proportion is in line with data established in the literature.<sup>4,3,8</sup> However, despite the severity of these patients' condition, none of them deteriorated to death after the orthopedic surgery.

In six cases (30%), the reduction obtained was not anatomical. This number was expected, since these were severe and unstable fractures, which contributed toward the incongruence. However, this result was a matter of concern for us, because chronic pain is usually a problem in these patients. In a study on 102 patients who underwent fixation by means of a sacroiliac screw, 88% presented reductions that were anatomical or close to anatomical, 12% presented residual incongruence of 1 cm or more and, over the course of the follow-up, eight patients presented displacement of the reduction that had been obtained.<sup>21</sup> McLaren et al.<sup>24</sup> showed that two thirds of their patients presented pain in cases with final incongruence greater than 1 cm, while 88% had minimal pain when the incongruence remained less than 1 cm. Thus, they demonstrated that seeking to achieve anatomical reduction is a necessity.

In our study, the functional results obtained were similar to those from techniques that are accepted as the gold standard,<sup>8,12,17</sup> with 50% of the results classified as good. Nine patients (45%) presented fair results despite consolidation of the fractures and returning to work activities. Only one patient (5%) had a poor result, in which a leg-length discrepancy of 5 cm remained and there was no improvement in the symptoms. This patient was treated through the use of insoles and footwear with a compensatory heel. Today, this patient continues to complain of pain, but is managing to work. Clinical and radiological comparisons showed that there was a direct correlation between the quality of the reduction and the presence of symptoms during the outpatient follow-up.

The injury complication rate through the method presented here reached 30% (six cases). The most frequent complications were paresthesia of the lateral femoral cutaneous nerve (two patients) and sacroiliac pain (two). The two patients with paresthesia presented complete improvement of the condition. Apraxia may occur during the dissection or introduction of the Schanz pins and its incidence during external fixation is 2%.<sup>25</sup> None of our patients presented neuropraxia of the root of L5. The neurovascular injury rate during positioning of the iliosacral screw ranges from 2 to 15% in the literature.<sup>26</sup> Rysavý et al.<sup>21</sup> reported occurrences of L5 injury in 6%, with complete remission of the deficit in all the cases. Moed and Whiting<sup>19</sup> did not report any cases of neurological injuries in their study on ten cases, after operative treatment on posterior injuries of the pelvic ring. Gao et al.<sup>27</sup> did not find any cases of neurological, vascular or urological injuries among 17 patients who underwent sacroiliac osteosynthesis.

The patients with traumatic brain injury evolved well, without neurological deficits, and were able to return to the activities that they did before the accident.

The patient who presented urethral injury continued to have sexual dysfunction and required urethral



dilatation and periodic follow-up with a urologist. The patient who underwent cystostomy evolved satisfactorily during the follow-up and did not have any complications.

One patient presented deep infection that required removal of the fixator and curettage of the orifices, which was done in a sterile environment, under anesthesia. He presented displacement of the pelvic fracture. None of the other 19 fixators that remained in place throughout the 16 weeks evolved with any deep infection. This makes it clear that local care is fundamental. Living with an external fixator in the home environment is burdensome, because activities of daily living become impaired and the patient requires constant assistance from other people.

This study presents some limitations: it was retrospective; the data were gathered from medical files; and although the inclusion criteria were very clear, the number of 20 patients may have been insufficient to portray the reality. The assessments on the patients were subjective and were not characterized through scores. Nonetheless, the patients' complaints and degree of satisfaction, and whether or not they returned to their work activities, are evident in the medical records. This study lacks statistical data of greater robustness, but this does not invalidate its importance, given that it highlights another possibility for definitive treatment for pelvic fractures.

The positive points from this study are that it reports on a series of 20 cases that were definitively treated using an optional method that is inexpensive, rapidly implemented, efficient and available in most hospitals. This study demonstrated clinical and radiographic results similar to the open techniques for internal fixation and could be easily reproduced in other hospital services.

## Conclusion

Supra-acetabular external fixation in association with percutaneous sacroiliac osteosynthesis using 7.0 mm cannulated screws for fractures classified as Tile type C is a good option for use as a definitive treatment for patients with a high risk of postoperative infection.

Multicenter randomized prospective studies with larger numbers of patients are needed for better comprehension and treatment of these patients.

## Conflicts of interest

The authors declare no conflicts of interest.

## Acknowledgements

We are deeply grateful to Prof. Drs. Emerson Kiyoshi Honda, Walter Ricioli Júnior and Marcelo Cavalheiro de Queiroz for their support, encouragement and great dedication during the study.

## REFERENCES

1. American College of Surgeons. Committee on Trauma. In: *Advanced trauma life support (ATLS)*. 8th ed. Chicago, IL: American College of Surgeons; 2008.
2. Tile M. Introduction and natural history of the pelvic ring. In: Tile M, Helfet DL, Kellan JF, editors. *Fractures of the pelvis and acetabulum*. 3rd ed. Philadelphia: Lippincott William & Wilkins; 2003. p. 3-11.
3. Stover MD, Mayo KA, Kellam JF. Pelvic ring disruptions. In: Browner BD, Jupiter JB, Levine AM, Trafton PG, Krettek C, editors. *Skeletal trauma: basic science, management, and reconstruction*. 4th ed. Philadelphia: Saunders Elsevier; 2009. p. 1107-69.
4. Grubor P, Milicevic S, Biscevic M, Tanjga R. Selection of treatment method for pelvic ring fractures. *Med Arch*. 2011;65(5):278-82.
5. Pennal GF, Tile M, Waddell JP, Garside H. Pelvic disruption: assessment and classification. *Clin Orthop Relat Res*. 1980;(151):12-21.
6. Perry JF Jr. Pelvic open fractures. *Clin Orthop Relat Res*. 1980;(151):41-5.
7. Holstein JH, Culemann U, Pohlemann T. What are predictors of mortality in patients with pelvic fractures? *Clin Orthop Relat Res*. 2012;470(8):2090-7.
8. Giannoudis PV, Grotz MR, Tzioupis C, Dinopoulos H, Wells GE, Bouamra O, et al. Prevalence of pelvic fractures, associated injuries, and mortality: the United Kingdom perspective. *J Trauma*. 2007;63:875-83.
9. Cohen MT, Guimarães JM, Motta Filho GR, Cohen JC, Goldsztnj F, Guimarães FM. Fixação percutânea com parafuso ilioacral na lesão traumática do anel pélvico. *Rev Bras Ortop*. 2005;40(1/2):32-41.
10. Papakostidis C, Kanakaris NK, Kontakis G, Giannoudis PV. Pelvic ring disruptions: treatment modalities and analysis of outcomes. *Int Orthop*. 2009;33(2):329-38.
11. Gorczyca J, Hearn T, Tile M. Biomechanics and methods of pelvic fixation. In: Tile M, Helfet DL, Kellan JF, editors. *Fractures of the pelvis and acetabulum*. 3rd ed. Philadelphia: Lippincott William & Wilkins; 2003. p. 116-29.
12. Tile M, Rubenstein J. Defining the injury: assessment of pelvic fractures. In: Tile M, Helfet DL, Kellan JF, editors. *Fractures of the pelvis and acetabulum*. 3rd ed. Philadelphia: Lippincott William & Wilkins; 2003. p. 102-15.
13. Moed BR, Kellam JF, McLren A, Tile M. Internal fixation for the injured pelvic ring. In: Tile M, Helfet DL, Kellan JF, editors. *Fractures of the pelvis and acetabulum*. 3rd ed. Philadelphia: Lippincott William & Wilkins; 2003. p. 217-93.
14. Kim WY, Hearn TC, Seleem O, Mahalingam E, Stephen D, Tile M. Effect of pin location on stability of pelvic external fixation. *Clin Orthop Relat Res*. 1999;(361):237-44.
15. Tile M. Describing the injury: classification of pelvic ring injuries. In: Tile M, Helfet DL, Kellan JF, editors. *Fractures of the pelvis and acetabulum*. 3rd ed. Philadelphia: Lippincott William & Wilkins; 2003. p. 135-49.
16. Solomon LB, Pohl AP, Sukthankar A, Chehade MJ. *J Orthop Trauma*. 2009;23(5):365-9.
17. Wolinsky P, Stephen D. Femur, shaft (incl. subtrochanteric fractures). In: Rüedi TP, Murphy WM, editors. *AO principles of fracture management*. 2nd ed. Stuttgart: Thieme Publishing Group; 2007. p. 778-99.
18. Tile M. Management of pelvic ring injuries. In: Tile M, Helfet DL, Kellan JF, editors. *Fractures of the pelvis and acetabulum*. 3rd ed. Philadelphia: Lippincott William & Wilkins; 2003. p. 168-202.

19. Moed BR, Whiting DR. Locked transsacral screw fixation of bilateral injuries of the posterior pelvic ring: initial clinical series. *J Orthop Trauma*. 2010;24(10):616-21.
20. van Zwienen CM, van den Bosch EW, Snijders CJ, Kleinrensink GJ, van Vugt AB. Biomechanical comparison of sacroiliac screw techniques for unstable pelvic ring fractures. *J Orthop Trauma*. 2004;18(9):589-95.
21. Rysavý M, Pavelka T, Khayarin M, Dzupa V. Iliosacral screw fixation of the unstable pelvic ring injuries. *Acta Chir Orthop Traumatol Cech*. 2010;77(3):209-14.
22. Miller AN, Routt ML Jr. Variations in sacral morphology and implications for iliosacral screw fixation. *J Am Acad Orthop Surg*. 2012;20(1):8-16.
23. Graves ML, Routt ML Jr. Iliosacral screw placement: are uniplanar changes realistic based on standard fluoroscopic imaging? *J Trauma*. 2011;71(1):204-8.
24. McLaren AC, Rorabeck CH, Halpenny J. Long-term pain and disability in relation to residual deformity after displaced pelvic ring fractures. *Can J Surg*. 1990;33(6):492-4.
25. Riemer BL, Butterfield SL, Diamond DL, Young JC, Raves JJ, Cottingham E, et al. Acute mortality associated with injuries to the pelvic ring: the role of early patient mobilization and external fixation. *J Trauma*. 1993;35(5):671-5.
26. Hinsche AF, Giannoudis PV, Smith RM. Fluoroscopy-based multiplanar image guidance for insertion of sacroiliac screws. *Clin Orthop Relat Res*. 2002;(395):135-44.
27. Gao H, Luo CF, Hu CF, Zhang CQ, Zeng BF. Minimally invasive fluoro-navigation screw fixation for the treatment of pelvic ring injuries. *Surg Innov*. 2011;18(3):279-84.