

Jackfruit Anaphylaxis in a Latex Allergic Non-Healthcare Worker

Allergy & Rhinology

Volume 12: 1–3

© The Author(s) 2021

Article reuse guidelines:

sagepub.com/journals-permissions

DOI: 10.1177/21526567211009195

journals.sagepub.com/home/aar



Maaz Jalil, DO¹ , Robert Hostoffer, DO², and Shan Shan Wu, DO²

Abstract

Introduction: Anaphylaxis to jackfruit (*Artocarpus heterophyllus*) is rare. Two previously reported cases have been published in two healthcare workers from jackfruit endemic regions. Latex allergy and birch pollen cross reactivity have both been associated with jackfruit anaphylaxis, providing two separate mechanisms of sensitization. We present a case of jackfruit anaphylaxis in a young latex allergic non-healthcare worker in a non-endemic region.

Case Report: A 21-year-old male had an anaphylactic reaction immediately after ingesting dried jackfruit. He had a history of allergic rhinitis and latex allergy. He was born premature and required neonatal intensive care and multiple surgeries in infancy, which could possibly be the source of his latex sensitization. Skin prick testing was positive for jackfruit and latex.

Discussion: Jackfruit anaphylaxis has only been described in conjunction with a latex allergy or a birch pollen allergy. As jackfruit becomes more available across the world, it is important for physicians and patients with these sensitivities to be aware of these possible cross reactions. Fruit sensitivities in latex allergic patients have been well established as Latex-fruit syndrome. Our case highlights the association of latex sensitization and jackfruit anaphylaxis.

Conclusion: We present a case of Jackfruit anaphylaxis associated with latex allergy in a non-healthcare worker from Midwestern United States. As jackfruit becomes more popular in non-endemic regions, its possible cross reactivity with latex, as well as birch pollen should be recognized.

Keywords

jackfruit, anaphylaxis, latex, allergy

Introduction

Jackfruit, or *Artocarpus heterophyllus*, is the world's largest edible fruit belonging to the Moraceae or mulberry family.¹ Anaphylaxis to jackfruit is rare; with only 2 published cases from Thailand and Florida.^{2,3} The literature has highlighted latex allergy and birch pollen cross-reactivity as potential contributing factors to jackfruit anaphylaxis. The prevalence of latex allergy is doubled in occupations routinely using latex supplies such as healthcare workers, with a worldwide prevalence of 9.7%, compared to 4.3% for the general population.⁴ The two previously reported cases of jackfruit anaphylaxis were both in healthcare workers.^{2,3} We report a young, latex allergic, non-healthcare worker from Midwestern United States with anaphylaxis to jackfruit.

Case Presentation

A 21-year-old Caucasian male presented to the office one week after an anaphylactic reaction following a

first-time ingestion of a small piece of dried jackfruit. Immediately after ingestion, he noted eye pruritis and periorbital swelling. Fifteen minutes later he developed chest tightness, shortness of breath, and hives all over his body. He self-administered epinephrine, which he carried for his latex allergy, 30 minutes after the start of his symptoms. En route to the hospital, he was given diphenhydramine, and in the emergency room he was treated with methylprednisolone and famotidine. After three hours of observation and resolution of his

¹University Hospitals Cleveland Medical Center, Cleveland, Ohio

²Allergy/Immunology Associates Inc, Mayfield Heights, Ohio

Submitted December 30, 2020. Revised March 19, 2021. Accepted March 23, 2021.

Corresponding Author:

Maaz Jalil, 5915 Landerbrook Drive, Suite 110, Mayfield Heights, OH 44124, USA.

Email: Mjalil570@gmail.com



shortness of breath, he was discharged with five days of prednisone. Complete resolution of his symptoms occurred a full 24 hours after ingestion.

The patient was born premature at 31 weeks of gestation. His NICU course was complicated by obstructive hydrocephalus for which he underwent a ventriculoperitoneal (VP) shunt placement at three weeks old, and a revision surgery at 6 months old. His past medical history was otherwise significant for latex allergy, allergic rhinitis, and anxiety. His daily medications include azelastine nasal spray, fluoxetine, and topiramate. He was diagnosed with a latex allergy at 6 years of age after he developed hives while playing with balloons. In 2019 his latex specific IgE ImmunoCAP (Phadia, Uppsala, Sweden), was 5.68 KU/L. He had a history of adverse reaction to raw bananas described as stomach bloating. In 2020, he tested positive for dust mites (3 mm) and mixed grasses (3 mm) on skin prick testing (SPT), but was negative for other aeroallergens including birch pollen.

SPT was conducted using canned jackfruit, latex, bananas, avocados, celery, potato, tomato, melon, peach, hazelnut, cherry, and apple. Jackfruit was positive with wheal of 3 mm and flare 5×6 mm, latex was positive with a wheal of 4 mm and flare of 9×13 mm, with a histamine of 8 mm and negative control of 0 mm (Figure 1). The patient was instructed to strictly avoid jackfruit and carry epinephrine for his jackfruit and latex allergy.

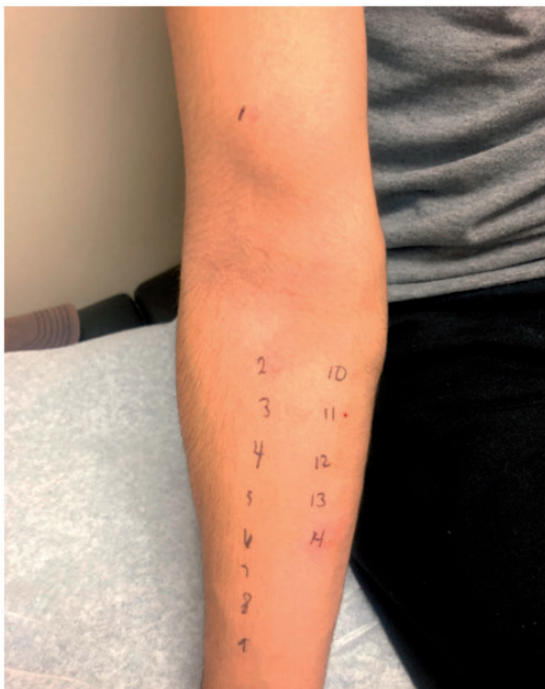

Figure 1. Patient's skin prick testing on right arm; Label 1: Jackfruit, 2: Latex, 13: negative control, 14: histamine.

Discussion

There have been two previously reported cases of anaphylaxis to jackfruit. Wongrakpanich et al. reported a 34-year-old Thai female nurse with anaphylaxis to dried jackfruit.² She had a history of allergic rhinitis, sensitized to dust mites, and atopic dermatitis. Her SPT was positive for dried and fresh jackfruit, papaya, kiwi, and two brands of latex gloves. The patient tolerated jackfruit and papayas when she was younger. However, one year after developing a latex allergy, likely due to sensitization from her profession, she had two serious allergic reactions to jackfruit and papaya. This observation along with SPT suggests that the anaphylaxis was caused by a cross-reaction between latex and jackfruit.

A second case of anaphylaxis to jackfruit was briefly described by Kabir et al.³ A 57-year old Jamaican female healthcare aid with past medical history of allergic rhinitis and oral allergy syndrome to pineapple had an anaphylactic reaction to fresh jackfruit which eventually required intubation. Her allergy testing was significant for elevated serum specific IgE to jackfruit, birch, peach, hazelnut, and almond. SPT was positive for raw jackfruit, jackfruit peel, birch, soybean, carrot, and negative to cooked jackfruit. Specific IgE and skin testing was negative for latex and related foods. This case highlights the cross-reactivity of birch pollen and fruits that cross react with the Bet V1 allergen. The relationship between Bet V1 and Moraceae fruits such as figs, mulberry, and jackfruit has been established by previous studies.^{5,6} Our patient was not sensitized to Birch pollen, making this type of cross reactivity unlikely.

Jackfruit is native to India and Malaysia, but is now commonly found in south east Asia, central and eastern Africa, the Caribbean, Florida, Puerto Rico, Brazil, Australia, and Pacific Islands.¹ Previous case reports have described jackfruit anaphylaxis in regions where jackfruit is commonly found. Our case is the first reported case of jackfruit anaphylaxis from a non-endemic region. Like the case from Thailand, our patient has a latex allergy which suggests anaphylaxis to jackfruit due to cross-reactivity with latex. It is possible that our patient was sensitized to latex during his NICU course.

Latex-fruit syndrome was first proposed in 1994 to describe the observation of specific and significant fruit hypersensitivity in patients with natural rubber latex allergy.⁷ The rate of patients with the latex-food cross reactivity have varied from 21% to 58%.⁸ The initially identified fruits causing such a reaction were: banana, avocado, chestnuts, kiwi, papaya, although, through RAST inhibition testing cross reactivity was initially only shown between latex, banana, avocado, and chestnuts. To date, many different foods have been associated with latex allergy. The growing list includes previously

listed fruits, as well as: potato, tomato, shellfish, pineapple, passion fruit, mango, fig, almond, hazelnut, stone fruits, melon, and apple. Other foods that have been observed with latex allergy include: guava, fish, carrot, pear, strawberry, peanut, pepper, grape, coconut, oregano, sage, dill, condurango bark, milk, spinach, beet, loquat, and lychee.⁸

Fifteen natural rubber latex allergen proteins have been given official nomenclature by the International Union of Immunological Societies', from Hev b1 to Hev b15.^{9,10} Each of these fifteen allergens have associated biochemical names. Allergens that have been associated with Latex-food cross reactivity are Hev b2 (endo-1,3 beta-glucosidases), Hev b7 (patatin-like proteins), Hev b8 (profilins), Hev b11 (class I chitinases), and Hev b12 (nonspecific lipid transfer proteins).^{8,9} Our present case suggests that jackfruit hypersensitivity causing anaphylaxis was related to latex allergy, however, cross reactive allergens between jackfruit and latex have not been proven by lab analysis, and further studies are required to definitively establish whether this is a true cross reaction. Lab analysis such as multiplex array testing could be useful in this patient to identify true allergen specific sensitization versus cross-reactivity.^{11,12} We report the first case of a young, latex allergic, non-healthcare worker from Midwestern United States with anaphylaxis to dried jackfruit.

Statement of Human and Animal Rights

This article does not contain any studies with human or animal subjects.

Statement of Informed Consent

There are no human subjects in this article and informed consent is not applicable.

Author Contributions

M. J.: Conception and design of the study, data generation, analysis and interpretation of the data, and preparation and clinical revision of the manuscript. R. H.: Conception and design of the study, analysis and interpretation of the data, and clinical revision of the manuscript. S. S. W.: Conception and design of the study, analysis and interpretation of the data, and clinical revision of the manuscript.

Ethical Approval

This study was approved by our institutional review board.


Declaration of Conflicting Interests

The author(s) declared no potential conflicts of interest with respect to the research, authorship, and/or publication of this article.

Funding

The author(s) received no financial support for the research, authorship, and/or publication of this article.

ORCID iD

Maaz Jalil  <https://orcid.org/0000-0003-3214-2970>

References

1. Prakash O, Kumar R, Mishra A, Gupta R. Artocarpus heterophyllus (jackfruit): an overview. *Pharmacogn Rev.* 2009;3:353–358.
2. Wongrakpanich S, Klaewsongkram J, Chantaphakul H, Ruxrunghtham K. Jackfruit anaphylaxis in a latex allergic patient. *Asian Pac J Allergy Immunol.* 2015;33(1):65–68.
3. Kabir S, Fattah S. Jackfruit induced anaphylaxis associated birchpollen-related food allergies. *Ann Allergy Asthma Immunol.* 2018;121(5):S120.
4. Wu M, McIntosh J, Liu J. Current prevalence rate of latex allergy: why it remains a problem? *J Occup Health.* 2016;58(2):138–144.
5. Bolhaar ST, Ree R, Bruijnzeel-Koomen CA, Knulst AC, Zuidmeer L. Allergy to jackfruit: a novel example of bet v 1-related food allergy. *Allergy.* 2004;59(11):1187–1192.
6. Hemmer W, Focke M, Marzban G, Swoboda R, Jarisch R, Laimer M. Identification of bet v 1-related allergens in fig and other moraceae fruits. *Clin Exp Allergy.* 2010;40(4):679–687.
7. Blanco C, Carrillo T, Castillo R, Quirarte J, Cuevas M. Latex allergy: clinical features and cross-reactivity with fruits. *Ann Allergy.* 1994;73(4):309–314.
8. Blanco C. Latex-fruit syndrome. *Curr Allergy Asthma Rep.* 2003;3(1):47–53.
9. Burks AW, Holgate ST, O'Hehir RE, et al. *Middleton's Allergy: Principles and Practice.* Amsterdam, the Netherlands: Elsevier Health Sciences; 2020.
10. Larsen JN, Lowenstein H. Allergen nomenclature. *J Allergy Clin Immunol.* 1996;97(2):577–578.
11. Čelakovská J, Bukač J, Vaňková R, et al. Cluster analysis of molecular components in 100 patients suffering from atopic dermatitis according to the ISAC multiplex testing. *Food Agric Immunol.* 2020;31(1):827–848.
12. Jakob T, Forstenlechner P, Matricardi P, Kleine-Tebbe J. Molecular allergy diagnostics using multiplex assays: methodological and practical considerations for use in research and clinical routine: part 21 of the series molecular allergology. *Allergo J Int.* 2015;24:320–332.