

Images in clinical medicine



Traumatic dilaceration of permanent central incisor

Devendra Ishwarlal Nagpal,  Ayushi Shashikant Gurharikar

Corresponding author: Ayushi Shashikant Gurharikar, Department of Paediatric and Preventive dentistry, VSPM's Dental College and Research Centre, Nagpur, Maharashtra, India. ayushi.gurharikar1@gmail.com

Received: 31 Jan 2022 - **Accepted:** 04 Apr 2022 - **Published:** 12 Apr 2022

Keywords: Dilaceration, dental trauma, surgical exposure, orthodontic traction, pediatric dentistry

Copyright: Devendra Ishwarlal Nagpal et al. Pan African Medical Journal (ISSN: 1937-8688). This is an Open Access article distributed under the terms of the Creative Commons Attribution International 4.0 License (<https://creativecommons.org/licenses/by/4.0/>), which permits unrestricted use, distribution, and reproduction in any medium, provided the original work is properly cited.

Cite this article: Devendra Ishwarlal Nagpal et al. Traumatic dilaceration of permanent central incisor. Pan African Medical Journal. 2022;41(296). 10.11604/pamj.2022.41.296.33533

Available online at: <https://www.panafrican-med-journal.com//content/article/41/296/full>

Traumatic dilaceration of permanent central incisor

Devendra Ishwarlal Nagpal¹, Ayushi Shashikant Gurharikar^{1,&}

¹Department of Paediatric and Preventive dentistry, VSPM's Dental College and Research Centre, Nagpur, Maharashtra, India

&Corresponding author

Ayushi Shashikant Gurharikar, Department of Paediatric and Preventive Dentistry, VSPM's Dental College and Research Centre, Nagpur, Maharashtra, India

Image in medicine

A 10-year-old male child reported to our department with a chief complaint of a nonerupted tooth in the upper front region of jaw. The patient's mother gave a history of trauma to anterior teeth in upper jaw 6 years back due to a road traffic accident, resulting in the intrusion of the left primary central maxillary incisor. The intruded tooth reappeared spontaneously and exfoliated normally. In the present scenario, clinical examinations showed impacted permanent maxillary left central incisor and the presence of a small hard nodule in the palatal aspect and in the labial vestibule of the same tooth. A Cone-Beam Computed Tomography (CBCT) radiographic examination was carried out in order to diagnose

the cause of an impacted tooth and revealed dilaceration of permanent left central incisor along the length of a tooth. Hence, the final diagnosis was made as impacted dilacerated permanent left

central incisor (due to trauma). Management of impacted dilacerated permanent teeth was done by surgical exposure with orthodontic traction.

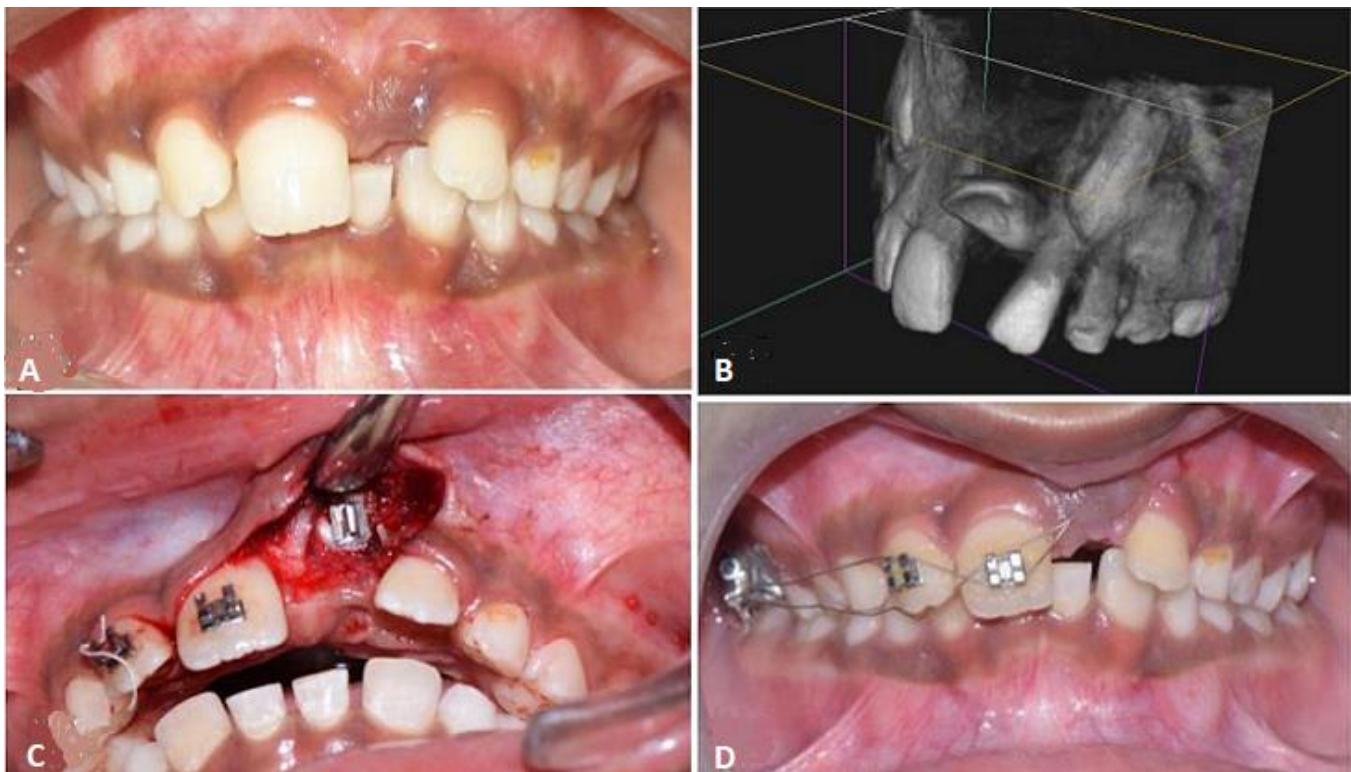


Figure 1: A) pre-operative clinical examination showing unerupted left permanent central incisor; B) perspective section of cone-beam computed tomography image showing an impacted tooth root located palatally with a large part close to palatal cortical bone; C) surgical exposure of impacted tooth followed placement of orthodontic brackets; D) orthodontic traction for inducing eruption of left permanent central incisor