

# Anterior versus posterior surgical approach for lumbosacral tuberculosis

Journal of International Medical Research

2018, Vol. 46(7) 2569–2577

© The Author(s) 2018

Reprints and permissions:

sagepub.co.uk/journalsPermissions.nav

DOI: 10.1177/0300060518764933

journals.sagepub.com/home/imr



**Bolong Zheng, Dingjun Hao, Hua Guo and Baorong He**

## Abstract

**Objective:** To compare two different approaches for the treatment of lumbosacral tuberculosis.

**Patients and Methods:** In total, 115 patients who were surgically treated in our department from July 2010 to July 2014 were included in this retrospective study. They were divided into the anterior and posterior approach groups. Intraoperative hemorrhage; the surgery time; the Cobb angle preoperatively, postoperatively, and at the follow-up visit (2 years postoperatively); visual analog scale (VAS) pain scores before and after surgery; and Oswestry Disability Index (ODI) scores before and after surgery were compared between the two groups.

**Results:** The Cobb angle and VAS and ODI scores were significantly improved in both groups after surgery. Significant differences were found in the operation time, intraoperative hemorrhage, Cobb angle correction, and loss of correction at the last follow-up. No significant differences were found in the VAS and ODI scores between the groups.

**Conclusions:** The posterior approach is superior to the anterior approach with respect to the surgery time, intraoperative hemorrhage, and Cobb angle postoperatively and at the last follow-up. When both approaches can be carried out for a patient with lumbosacral tuberculosis, the posterior approach should be favored over the anterior approach.

## Keywords

Lumbosacral tuberculosis, bone grafting, anterior approach, posterior approach, Cobb angle, visual analog scale, Oswestry Disability Index

Date received: 8 August 2017; revised 4 February 2018; accepted: 22 February 2018

## Introduction

The prevalence of spinal tuberculosis has been rising in African and Asian countries during the last decade because of the

Department of Spine Surgery, Honghui Hospital, Xi'an Jiaotong University, Xi'an, Shanxi, China

### Corresponding author:

Baorong He, Department of Spine Surgery, Honghui Hospital, Xi'an Jiaotong University, No. 555 East Friendship Rd, Xi'an, Shanxi 86710054, China.  
Email: hebr888@163.com



increasing number of patients with acquired immunodeficiency and multidrug-resistant tuberculosis.<sup>1</sup> Musculoskeletal tuberculosis accounts for approximately 10% of all types of extrapulmonary tuberculosis, and nearly half of these patients have spinal tuberculosis.<sup>2,3</sup> The main treatment for spinal tuberculosis is chemotherapy consisting of isoniazid, rifampicin, ethambutol, and pyrazinamide. However, surgical treatment is still necessary for patients with spinal cord injury and spinal instability due to tuberculosis lesions.<sup>4</sup> Both anterior and posterior approaches have been applied for the treatment of lumbosacral spinal tuberculosis, and satisfactory results have been reported by various authors.<sup>5</sup> However, there is no consensus on the optimal approach. The purpose of this study was to compare the outcomes of debridement and bone fusion by anterior or posterior procedures in the treatment of lumbosacral tuberculosis in adults and provide reference data for future clinical procedures.

## **Materials and methods**

### *Patient inclusion*

All procedures in the current study were approved by the ethics committee of Xian Honghui Hospital, Xi'an Jiaotong University. All participating patients provided verbal informed consent. The clinical data of patients with a definitive diagnosis of lumbosacral tuberculosis treated by radical debridement and a strut grafting technique were retrospectively reviewed, and those who were treated with an anterior or posterior approach were included in the current study. Whether the anterior or posterior approach was applied was decided by comprehensive analysis of the position and extension of the foci, which were evaluated by anteroposterior and lateral radiographs, computed tomography, and magnetic

resonance imaging. The surgical approach was primarily designed and recommended by the chief spine surgeon and approved by the patient after he or she had been provided with all information about the advantages and disadvantages of the two approaches.

### *Treatment strategy*

Only oral anti-tuberculosis drugs were administered in patients with no bacterial-induced spinal instability. The indications for surgical treatment were exacerbated collapse of a vertebral body, gradual worsening of pain, and radiculopathy.

Upon establishment of the clinical diagnosis in patients requiring surgery, treatment was begun with anti-tuberculosis drugs (isoniazid, 5 mg/kg; rifampicin, 10 mg/kg; ethambutol, 15 mg/kg; and pyrazinamide, 25 mg/kg) for 2 to 4 weeks prior to the operation. The surgery was carried out when the white blood cell count was normal or nearly normal, the erythrocyte sedimentation rate (ESR) and C-reactive protein were stable and started to decline, and the overall condition of the patient was adequate for surgery under general anesthesia.<sup>6</sup> The patients were treated with either anterior debridement and autologous bone grafting with instrumentation or posterior instrumentation with anterior debridement and autologous bone grafting in a titanium cage.

### *Operative procedure*

The anterior approach was performed with the patient in the lateral decubitus position, with the more severely involved side upward. An oblique hypogastric incision was made according to the segment containing the lesion. After routine retroperitoneal exposure, distractor screws on the normal vertebrae adjacent to the lesion were used to stabilize the spine and partly

correct the lordosis deformity during decompression and focal debridement. The tuberculous focus, including any prevertebral or paravertebral abscesses, collapsed intervertebral discs, or other necrotic tissues were completely removed through the healthy bleeding bone for spinal cord decompression. A suitable titanium mesh filled with autologous bone was selected and inserted into the bone to stabilize the vertebral height and locking nail-plate system (Figure 1).

The posterior approach was performed as follows. After induction of general anesthesia, the patients were placed in the prone position. A mid-spinal incision was made and the bilateral facet joints and outer parts of the lamina were exposed. Shorter segmental fixation was preferred in the lumbosacral junction (at least one above and one below the lesion). Transpedicular screws were also placed in the affected vertebrae if the upper part of the vertebrae was not destroyed by infection. Transpedicular screws could be implanted in the ilium when the first sacral vertebra was severely damaged. After screw placement, a temporary 20- to 30-degree pre-bent rod was placed on the opposite side to avoid unexpected movements of the spine during debridement. After excision of the necrotic disc and collapsed vertebrae, saline irrigation and a flush tube were used to clean the paravertebral or psoas abscess. The patient's position was changed by controlling the position of the operating table to allow removal of latent pus if necessary while flushing the abscess. Suitable autogenous struts or allogenic bone was inserted into the prepared bone trough through the same incision to reconstruct the vertebrae. The kyphosis was rectified by compression and stretching of the internal fixation instrument (Figure 2). Autologous or allograft bone particles were implanted in the lateral facet joints of diseased vertebrae and between the transverse processes.

Streptomycin (1.0 g) and isoniazid (0.2 g) were administered locally, and a drainage tube was placed before the incisions were sutured. The biopsy specimens were sent for pathological examination.

The drainage tube was removed when the drainage flow was <50 mL per 24 hours, and the patients were allowed to ambulate with protection of waist support at 1 week after removal of the drainage tube. All patients were treated with the above-mentioned antituberculous chemotherapy regimen for 12 to 18 months postoperatively. The braces were continually used for 6 to 8 months postoperatively. All patients were examined clinically and radiologically at 3, 6, and 12 months after surgery and then once a year. Radiographs, blood tests, the ESR, and hepatic function were examined.

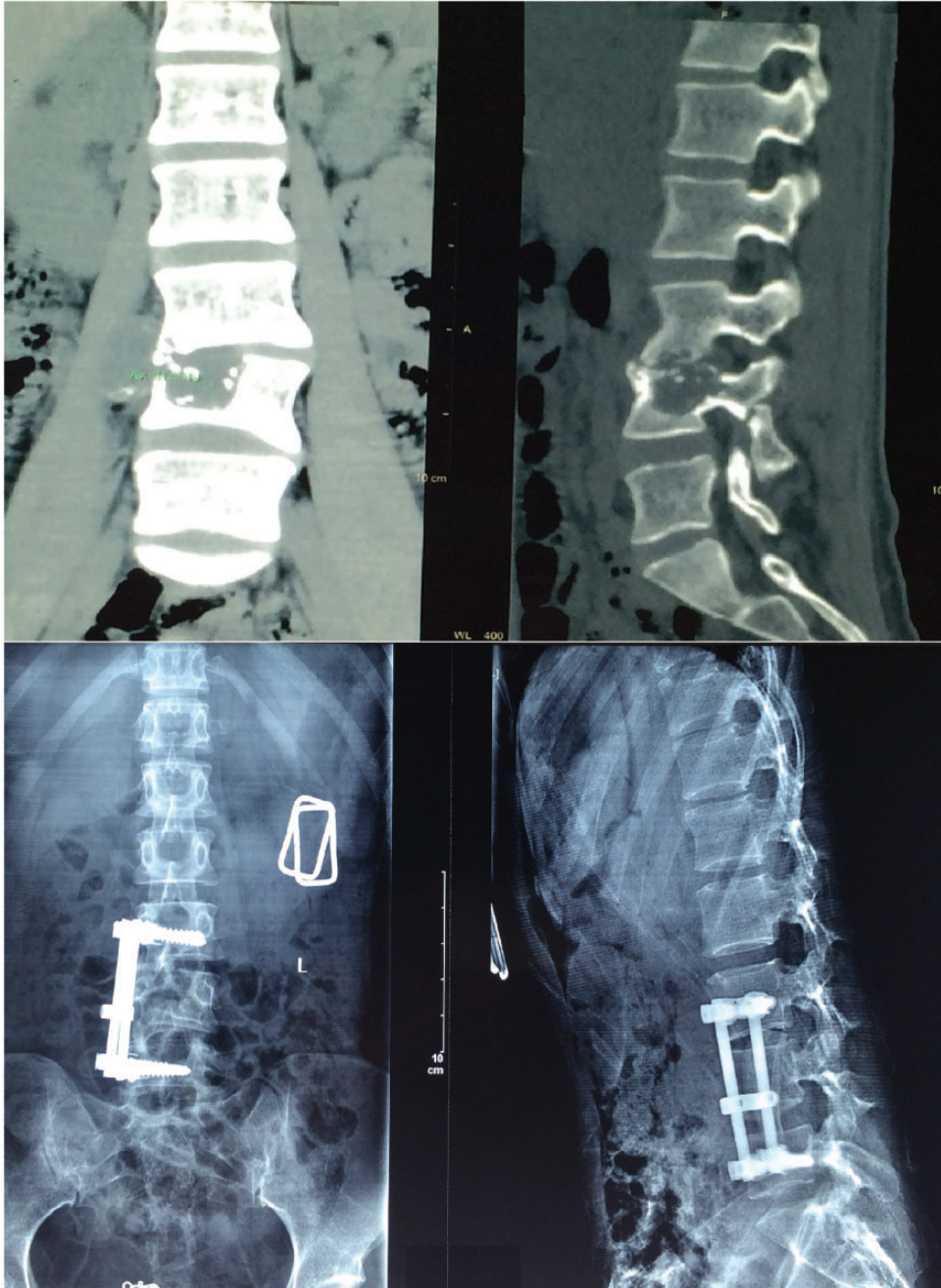
### *Statistical analysis*

Using IBM SPSS Statistics, version 19.0 (IBM Corp., Armonk, NY, USA), the lordotic angle, Oswestry disability index (ODI), and visual analog scale (VAS) pain scores were analyzed by paired t-tests preoperatively, postoperatively, and during the follow-up within groups and by independent-sample t-tests between groups. Differences were considered significant at  $P < 0.05$ .

## **Results**

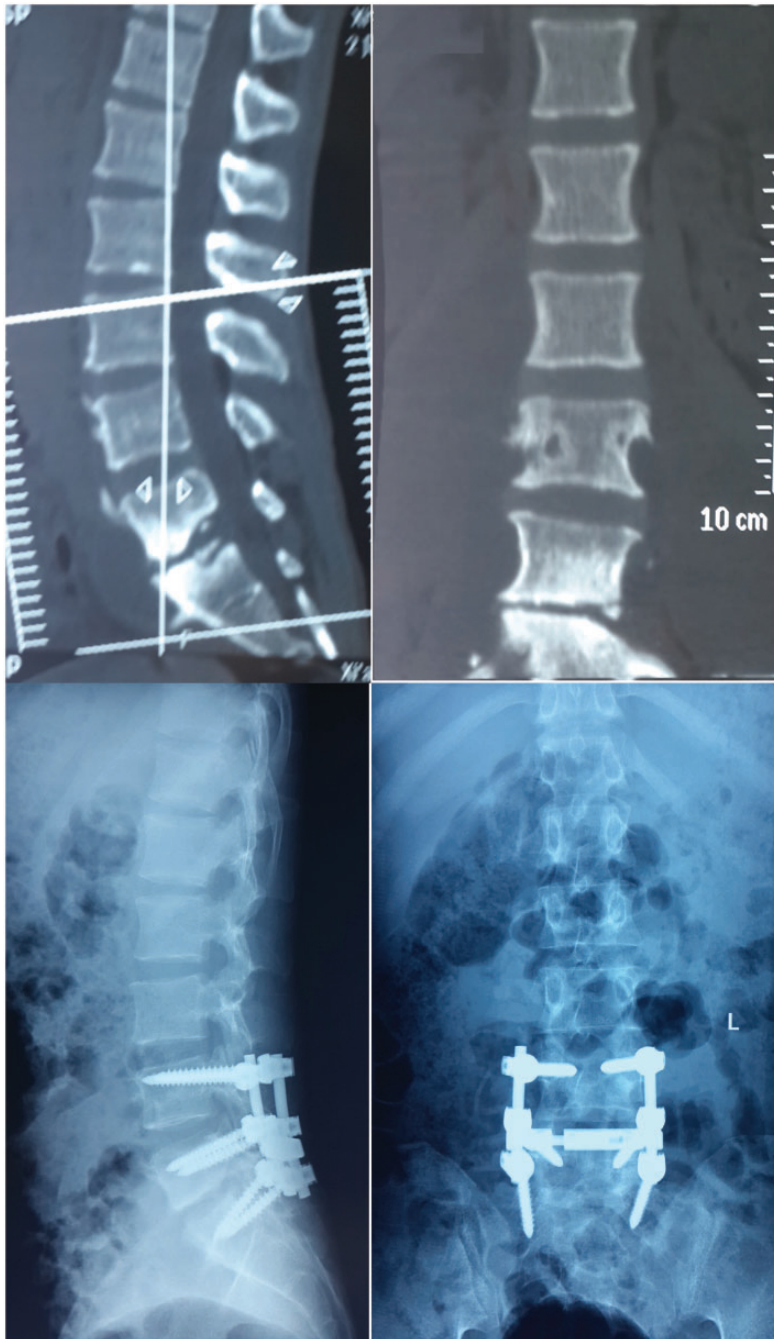
### *General patient Information*

From July 2010 to July 2014, 115 patients with lumbar lumbosacral tuberculosis underwent surgical treatment in our department (anterior debridement and autologous bone grafting with instrumentation,  $n = 50$ ; posterior instrumentation with anterior debridement and autologous bone grafting in a titanium cage,  $n = 65$ ). There were no significant differences in the sex ratio or age



**Figure 1.** Preoperative computed tomography and postoperative radiographic images of a patient who underwent anterior debridement, intervertebral fusion, and internal fixation for the treatment of lumbosacral tuberculosis.





**Figure 2.** Computed tomography and radiographic images of lumbosacral tuberculosis before and after posterior surgery.

between the two groups (Table 1). The mean operation time was 236.7 minutes for the anterior approach and 82.5 minutes for the posterior approach, and the difference was significant ( $P=0.05$ ). The mean intraoperative hemorrhage was 505.0 mL for the anterior approach and 399.3 mL for the posterior approach, and the difference was significant ( $P=0.04$ ) (Table 1).

**Treatment results**

The mean follow-up was 41.5 months (range, 24–64 months). The surgical incisions in both groups healed without chronic infection, fistula formation, or recurrence. No complications related to instrumentation occurred. Two patients developed pneumonia. These symptoms disappeared after 1 week of anti-inflammatory and symptomatic supportive treatment. All patients experienced pain relief. No graft fracture, sliding, or resorption was observed. All patients experienced significant improvement in their constitutional symptoms and back pain after surgery. The white blood cell count and ESR had normalized in all patients by 3 months after surgery. Radiographs and/or computed tomography scans showed that all patients achieved bone fusion. The average fusion time was 6.9 months (range, 5–10 months).

The average VAS pain score was 6.9 (range, 5–8) preoperatively and decreased

by 5.4 points at the last follow-up (Table 2); there were no significant differences in the alleviation of pain at each time point between the two groups. Similarly, the ODI scores were not significantly different between the two groups at each time point. The lumbosacral lordotic angle was more significantly corrected by the posterior than anterior approach. The preoperative lumbosacral lordotic angle was  $18.0 \pm 8.8$  and  $19.4 \pm 6.6$  degrees in the anterior and posterior approach groups, respectively, which was not significantly different, and the postoperative angle was  $27.1 \pm 4.9$

**Table 2.** Changes in ODI and VAS scores and lordotic angle preoperatively, postoperatively, and at the last follow-up

	Anterior approach	Posterior approach	P
<b>ODI</b>			
Preoperatively	51.4 ± 10.9	49.2 ± 11.8	0.16
Before discharge	31.3 ± 6.0	28.5 ± 5.6	0.23
At last follow-up	1.5 ± 0.4	1.6 ± 0.5	0.35
<b>VAS</b>			
Preoperatively	6.8 ± 1.0	6.4 ± 1.4	0.06
At last follow-up	0.8 ± 0.1	0.6 ± 0.1	0.18
<b>Lordotic angle</b>			
Preoperatively	18.0 ± 8.8	19.4 ± 6.6	0.52
Before discharge	27.1 ± 4.9	28.8 ± 7.0	0.00
At last follow-up	22.0 ± 3.8	27.2 ± 5.1	0.04

Data are presented as mean ± standard deviation. ODI, Oswestry Disability Index; VAS, visual analog scale.

**Table 1.** Demographic characteristics of patients and surgical procedures

	Anterior approach	Posterior approach	P
Female/male	20/30	23/42	0.70
Age, years	45.7 ± 8.4	47.2 ± 7.61	0.96
<b>Levels of lumbosacral tuberculosis lesion</b>			
L3–L4	14	16	0.87
L4–L5	19	24	
L5–S1	17	25	
Operation time, minutes	236.70 ± 36.4	182.47 ± 29.6	0.05
Intraoperative hemorrhage, mL	505.0 ± 112.4	399.31 ± 82.0	0.04

Data are presented as number of patients or mean ± standard deviation.

**Table 3.** Changes in the ASIA spinal cord injury scale

	B	C	D	E
Anterior approach				
Preoperatively	2	8	19	21
Before discharge	1	3	11	35
At last follow-up	0	2	4	44
Posterior approach				
Preoperatively	2	13	23	27
Before discharge	0	10	16	39
At last follow-up	0	3	5	57

ASIA, American Spinal Injury Association.

and  $28.8 \pm 7.0$  degrees, respectively, with a significant difference ( $P < 0.05$ ). At the last follow-up, the lordotic angle was  $22.0 \pm 3.8$  and  $27.2 \pm 5.1$  degrees in the anterior and posterior approach groups, respectively, which was also significantly different ( $P < 0.05$ ).

The neurologic deficits in all patients were improved at the follow-up examinations. Before the surgery, 4, 21, 42, and 48 patients had an American Spinal Injury Association (ASIA) spinal cord impairment scale grade of B, C, D, and E; these numbers of patients improved to 1, 13, 27, and 74 after the surgery and to 0, 5, 9, and 101 at the last follow-up (Table 3). There were no significant differences in the ASIA grades at each time point between the two groups.

## Discussion

The spine is a common site for extrapulmonary tuberculosis, and spinal tuberculosis is still the most important cause of paraplegia in developing countries. Early intervention is vital in the treatment of spinal tuberculosis. Although antituberculosis chemotherapy effectively inactivates tuberculosis, vertebral collapse may continue. Surgical treatment is a necessity for patients with vertebral collapse and those who cannot tolerate long-term immobilization.<sup>7</sup> The

main goals of surgical treatment involve removal of the focus, complete decompression of nerves, correction of the spinal deformity, and reconstruction of spinal stability.<sup>8</sup>

Various surgical methods have been applied to treat lumbosacral tuberculosis. Because the inflammation is usually located in the anterior aspect, the anterior approach allows the surgeon to directly remove the infected focus and facilitates vertebral reconstruction. However, this approach may lead to inadequate kyphosis correction and loss of correction during follow-up. It has also been reported that the anterior approach may lead to injury of the peritoneum and a high rate of vascular complications.<sup>9-11</sup> In the current study, patients treated with the anterior approach had a longer operation time, more intraoperative hemorrhage, and greater loss of the correction angle at the 2-year follow-up.

Since the application of posterior spinal instrumentation systems, a single posterior approach can now be used to finish debridement, bone grafting, and instrumentation. The posterior approach creates enough operating space through resection of one side of the lamina, facet joint, diaphysis, and pedicle, allowing operation on the vertebral body at a 270-degree angle under direct visualization of the outside of the dura mater for complete removal of the focal tuberculous lesion without injuring the spinal cord.<sup>12-14</sup> Although several reports have compared the curative effect of anterior and posterior approaches to treat spinal tuberculosis, their results have been largely inconclusive, and few have focused on tuberculosis of the lumbosacral region.<sup>15,16</sup> The results of the current retrospective study indicate that for patients with tuberculosis of the lumbosacral region, the posterior approach requires a shorter operation time, induces less intraoperative hemorrhage, and allows for more gain and correction of the lordotic angle

compared with the anterior approach. Additionally, the VAS, ODI, and ASIA scores were not significantly different between the two groups, indicating that the posterior approach may be a safer and more efficient treatment technique for lumbosacral tuberculosis. However, it is also possible that the results of this study were affected by the different patient inclusion criteria and operational technique of the surgeon. Although these factors may have introduced bias to the results of the current study, its retrospective nature makes it impossible to eliminate such bias. However, this study still suggests that the posterior approach is often more advantageous than the anterior approach.

## Conclusion

When both approaches can be carried out for a patient with lumbosacral tuberculosis, the posterior approach should be favored over the anterior approach.

## Author contributions

Bolong Zheng was responsible for patient selection and recruitment and drafting of the manuscript, Dingjun Hao was responsible for carrying out the surgical procedures, Hua Guo was responsible for the statistical analysis and drafting of the manuscript, and Baorong He was responsible for the study design, team building, and revising of the manuscript.

## Acknowledgement

We thank Professor Wei Tian for his assistance with the study design and drafting of the manuscript.

## Declaration of conflicting interest

The authors declare that there is no conflict of interest.

## Funding

This research received no specific grant from any funding agency in the public, commercial, or not-for-profit sectors.

## References

1. Garg RK, Somvanshi DS. Spinal tuberculosis: a review [J]. *J Spinal Cord Med* 2011; 34: 440–454.
2. Pietersen E, Ignatius E, Streicher EM, et al. Long-term outcomes of patients with extensively drug-resistant tuberculosis in South Africa: a cohort study. *Lancet* 2014; 383: 1230–1239.
3. Ge Z, Wang Z and Wei M. Measurement of the concentration of three antituberculosis drugs in the focus of spinal tuberculosis. *Eur Spine J* 2008; 17: 1482–1487.
4. Patel AR, Alton TB, Bransford RJ, et al. Spinal epidural abscesses: risk factors, medical versus surgical management, a retrospective review of 128 cases. *Spine J* 2014; 14: 326–330.
5. Zeng H, Wang X, Pang X, et al. Posterior only versus combined posterior and anterior approaches in surgical management of lumbosacral tuberculosis with paraspinal abscess in adults. *Eur J Trauma Emerg Surg* 2014; 40: 607–616.
6. Dai LY, Jiang LS, Wang YR, et al. Chemotherapy in anterior instrumentation for spinal tuberculosis: highlighting a 9-month three-drug regimen. *World Neurosurg* 2010; 73: 560–564.
7. Cornett CA, Vincent SA, Crow J, et al. Bacterial spine infections in adults: evaluation and management. *J Am Acad Orthop Surg* 2016; 24: 11–18.
8. Wang L, Zhang H, Tang M, et al. Comparison of three surgical approaches for thoracic spinal tuberculosis in adult: minimum 5-year follow up. *Spine* 2017; 42: 808–817.
9. Muheremu A, Niu X, Wu Z, et al. Study on anterior and posterior approaches for spinal tuberculosis: a meta-analysis. *Eur J Orthop Surg Traumatol* 2015; 25: 69–76.
10. Li J, Li X, Zhou X, et al. Surgical treatment for spinal tuberculosis with bilateral



- paraspinal abscess or bilateral psoas abscess: one-stage surgery. *J Spinal Disord Tech* 2014; 27: E309–E314.
11. Zhang T, He X, Li H, et al. Treatment of lumbosacral spinal tuberculosis by one-stage anterior debridement and fusion combined with dual screw-rod anterior instrumentation underneath the iliac vessel. *BMC Musculoskelet Disord* 2016; 17: 49.
  12. Zeng H, Zhang P, Shen X, et al. One-stage posterior-only approach in surgical treatment of single-segment thoracic spinal tuberculosis with neurological deficits in adults: a retrospective study of 34 cases. *BMC Musculoskelet Disord* 2015; 16: 186.
  13. Zhang HQ, Lin MZ, Li JS, et al. One-stage posterior debridement, transforaminal lumbar interbody fusion and instrumentation in treatment of lumbar spinal tuberculosis: a retrospective case series. *Arch Orthop Trauma Surg* 2013; 133: 333–341.
  14. Li L, Xu J, Ma Y, et al. Surgical strategy and management outcomes for adjacent multisegmental spinal tuberculosis: a retrospective study of forty-eight patients. *Spine* 2014; 39: E40–E48.
  15. Moon MS. Tuberculosis of spine: current views in diagnosis and management [J]. *Asian Spine J* 2014; 8: 97–111.
  16. Rasouli MR, Mirkoohi M, Vaccaro AR, et al. Spinal tuberculosis: diagnosis and management. *Asian Spine J* 2012; 6: 294–308.