

Letícia Baltieri^a, Eli Maria Pazzianotto-Forti^{b,*}

^a Universidade de Campinas (UNICAMP), Campinas, SP, Brazil

^b Universidade Metodista de Piracicaba (UNIMEP), Programa de Pós-graduação em Ciências do Movimento Humano (PPG-CMH), Piracicaba, SP, Brazil

* Corresponding author.

E-mail: empforti@unimep.br (E.M. Pazzianotto-Forti).

Available online 20 September 2017

<https://doi.org/10.1016/j.bjane.2017.08.004>
0104-0014/

© 2017 Sociedade Brasileira de Anestesiologia. Published by Elsevier Editora Ltda. This is an open access article under the CC BY-NC-ND license (<http://creativecommons.org/licenses/by-nc-nd/4.0/>).

Pulmonary function alteration in laparoscopic surgery with pneumoperitoneum and abdominal wall elevation



Alteração da função pulmonar em cirurgia laparoscópica com pneumoperitônio e elevação da parede abdominal

Dear Editor,

It was with great interest that we read the article published by Hiroshi Ueda and Takuo Hoshi, which addressed lung function in laparoscopic surgery with abdominal wall

elevation.¹ In general, laparoscopic surgeries require a pneumoperitoneum (PnP), which involves carbon dioxide insufflation into the peritoneal cavity, resulting in a change of respiratory mechanics. This change is associated with pulmonary base compression due to cephalic displacement of the diaphragm causing decreased functional residual capacity. In a pilot study carried out by our group at the Federal University of São Paulo – Paulista Medical School, during PnP with intra-abdominal pressure (IAP) of 20 mmHg, we identified that the cephalic displacement of the diaphragm appears to be the main component for change in lung function. However, the elevation of the abdominal wall by increasing IAP could result in diaphragmatic rectification due to costophrenic angle opening and discretely contributing to the opening of the basal regions of the

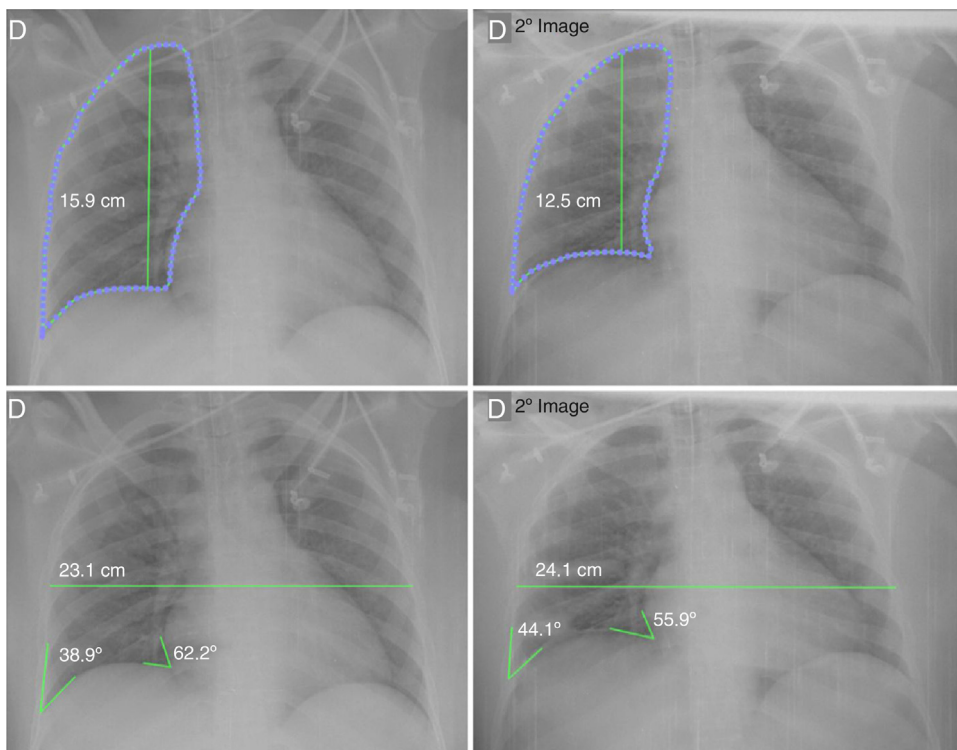


Figure 1 Female patient undergoing videolaparoscopy with pneumoperitoneum (PnP) pressure of 20 mmHg. Before PnP (first column), lung height was 15.9 cm, showing a reduction of 21.4% (3.4 cm) after PnP insufflation (second column). The laterolateral diameter had a slight increase of 4.5% (23.1–24.1 cm). The right costophrenic angle had an increase of 13.5% (ranging from 38.9° to 44.1°), corroborating for greater rectification of the diaphragm, but the cardiophrenic angle reduced its angulation by 10.1% (62.2° for 55.9°). Thus, it is possible to notice a significant reduction in lung height with insufficient diaphragmatic conformation change.

lungs, as described in the model by Ueda et al.¹ However, as illustrated in Fig. 1, the diaphragm shape does not appear to change significantly during PnP. Thus, pneumoperitoneum may cause a significant increase in atelectasis,² particularly in dependent regions.³ Cyclic recruitment of atelectasis areas may increase mechanical stress in the lung parenchyma,⁴ which, together with other areas of preoperative or intraoperative dysfunction, may produce significant perioperative pulmonary dysfunction as a potential cause of postoperative pulmonary complications (PPC).

Despite the interesting outcome found by Ueda et al.¹ regarding the increased functional residual capacity (FRC) due to abdominal wall elevation and probable change in diaphragm conformation, important points are worth noting, such as the lack of information on the use of PEEP and recruitment maneuver, which would directly affect FRC. Moreover, although there are conflicting results in the literature regarding lung compliance improvement⁵ or maintenance⁶ during abdominal wall elevation, we don't know whether the FRC improvement was sufficient to optimize pulmonary compliance. In addition, we still lack information if the FRC improvement during abdominal wall elevation is maintained postoperatively. If so, this may be a potential strategy for high-risk patients to develop PPC.

Finally, the lung characteristic heterogeneity leads us to think about the importance of lung function regional analysis using computed tomography or electrical impedance tomography. The analysis performed with Engström Carestation (GE Health Care, UK Ltd., Buckinghamshire, England) allows global measurement of lung function. The method used for abdominal wall elevation was lifting the right costal arch and umbilical region, which could mean a better improvement of the right lung FRC, maintaining the left lung potential atelectasis. Thus, the actual change in regional pulmonary function during laparoscopic surgery with abdominal wall elevation remains unknown.

Conflicts of interest

The authors declare no conflicts of interest.

References

1. Ueda H, Hoshi T. Functional residual capacity increase during laparoscopic surgery with abdominal wall lift. *Rev Bras Anesthesiol.* 2017;67:284–7.
2. Duggan M, Kavanagh BP. Pulmonary atelectasis: a pathogenic perioperative entity. *Anesthesiology.* 2005;102:838–54.
3. Magnusson L, Spahn DR. New concepts of atelectasis during general anaesthesia. *Br J Anaesth.* 2003;91:61–72.
4. Grasso S, Terragni P, Mascia L, et al. Airway pressure–time curve profile (stress index) detects tidal recruitment/hyperinflation in experimental acute lung injury. *Crit Care Med.* 2004;32:1018–27.
5. Lindgren L, Koivusalo AM, Kellokumpu I. Conventional pneumoperitoneum compared with abdominal wall lift for laparoscopic cholecystectomy. *Br J Anaesth.* 1995;75:567–72.
6. Carry PY, Gallet D, Francois Y, et al. Respiratory mechanics during laparoscopic cholecystectomy: the effects of the abdominal wall lift. *Anesth Analg.* 1998;87:1393–7.

Luiz Fernando dos Reis Falcão*, Fabrício de Paula Leite Battisti, Itamar Souza de Oliveira Júnior, David Ferez

Universidade Federal de São Paulo (Unifesp), Escola Paulista de Medicina, Disciplina de Anestesiologia, Dor e Medicina Intensiva, São Paulo, SP, Brazil

* Corresponding author.

E-mail: luizfernandofalcao@gmail.com (L.F. Falcão).

Available online 12 October 2017

<https://doi.org/10.1016/j.bjane.2017.09.002>
0104-0014/

© 2017 Sociedade Brasileira de Anestesiologia. Published by Elsevier Editora Ltda. This is an open access article under the CC BY-NC-ND license (<http://creativecommons.org/licenses/by-nc-nd/4.0/>).

Occupational hazards due to exposure to waste anesthetic gases



Riscos devido à exposição ocupacional aos resíduos de gases anestésicos

Dear Editor,

The publication on "Occupational hazards due to exposure to waste anesthetic gases" is very interesting.¹ Lucio LMC, Braz et al. noted that "The occupational hazards related to WAGs including genotoxicity, mutagenicity and oxidative stress, stand as a public health issue and must be acknowledged by exposed personnel and responsible authorities, especially in developing countries. Thus, it is

urgent to establish maximum safe limits of concentration of WAGs in ORs and educational practices and protocols for exposed professionals."¹ In fact, the occupational health of medical personnel is usually forgotten. Lack of concern and no risk monitoring is common.

In our experience from Thailand, it is approved that exposure to medical waste in hospital is a cause of carcinogenicity to medical personnel.² The important issue is how to implement a preventive measure for medical personnel. For one who works in anesthesiology, risk reduction by protective tool is needed and there is a requirement for regular monitoring for the health problem. Nevertheless, the monitoring might be complex since one has exposure to both environmental and occupational hazards. Minimizing of exposure is needed³ and it is an actual challenge in the situation of high workload for anesthesiologist at present.