

# Recurrent case of central giant cell granuloma with multiple soft tissue involvement

Department of Oral and Maxillofacial Surgery, <sup>2</sup>Department of Pedodontics and Preventive Dentistry, Kalka Dental College and Hospital, Meerut, <sup>3</sup>Department of Oral and Maxillofacial Surgery, ITS Dental College, <sup>4</sup>Department of Prosthodontics and Oral Implantology, Shree Bankey Bihari Dental College and Research Centre, Ghaziabad, Uttar Pradesh, India

Suresh Yadav, Anurag Singh<sup>1</sup>, Prince Kumar<sup>2</sup>, Shallu Tyagi<sup>3</sup>

## ABSTRACT

Central giant cell granuloma is a fairly common lesion in the jaws aetiology of which is still completely unknown but thought to be of a reactive process to some unknown stimuli. It usually arises either peripherally in periodontal ligament, mucoperiosteum, or centrally in the bone. The histological hallmark for both peripheral and central giant cell granuloma (CGCG) is the presence of distinctive multinucleated giant cells (MGCs) in a prominent fibrous stroma. Central giant cell granuloma is an uncommon benign proliferative lesion that almost exclusively occurs within the jaw. Eventually, it may become aggressive leading to the expansion and perforation of cortex resulting into mobility and displacement of teeth with root resorption. The present case focuses on the dilemma and perplexity in diagnosing aggressive CGCGs, due to its close proximity with respect to pathology, behavior and prognosis from giant cell tumors (GCT). Central giant cell granuloma persuaded extensive destruction to the hard and soft tissues with high rate of recurrence encourage us the need of exploring the possibilities of giant cell tumors having a definitive presence in the jaws.

### Address for correspondence:

Dr. Prince Kumar,  
Department of Prosthodontics and Oral Implantology, Shree Bankey Bihari Dental College and Research Centre, Ghaziabad, Uttar Pradesh, India.  
E-mail: princekumar@its.edu.in


**Key words:** Giant cells, giant cell granuloma, unilocular radiolucency

## INTRODUCTION

Giant cell lesions of the maxillofacial area can vary from asymptomatic radiolucency of slowly growing lesion to aggressive tumours showing high recurrence rate as well as rapid expansive progression characterized by root resorption and pain. GCGs of the jaws arise either peripherally in periodontal ligament, mucoperiosteum, or centrally in the bone. The World Health Organization has defined the Central giant cell granuloma as an intraosseous lesion consisting of cellular fibrous tissue that contains multiple foci of hemorrhage, aggregations of multinucleated giant cells and occasionally trabeculae of woven bone. Histologically, both peripheral and central variants of giant cell granuloma are characterized

by the presence of numerous multinucleated giant cells (MGCs) in a prominent fibrous stroma. Foci of hemorrhage with liberation of hemosiderin pigment and newly formed osteoid or bone are often seen. The MGCs are concentrated in the areas of hemorrhage and are adjacent to blood vessels. Jaffe separated CGCG from GCT of the bone on clinical and histologic grounds and suggested that MGCs in CGCG represent a phagocytic response to hemorrhage.<sup>[1]</sup>

The clinical behavior of CGCG of the jaws is variable and difficult to predict. However, it affects females more often than males, in a 2:1 ratio and is seen most frequently under the age of 30 years.<sup>[2]</sup> One study of 38 patients shows 74% to be less than 30 years of age and 61% to be less than 20 years of age.<sup>[3]</sup> The lesion commonly presents as a solitary radiolucency with a multilocular appearance or less commonly, a unilocular appearance.<sup>[3-5]</sup> It is more prevalent in the anterior than the posterior jaws, often crossing the midline, and the mandible is more commonly affected than the maxilla.<sup>[3,5]</sup> This lesion has also been reported in the small bones of the hands and feet.<sup>[6,7]</sup> The behavior of CGCG is variable, most commonly producing an asymptomatic expansion

Access this article online	
<b>Quick Response Code:</b> 	<b>Website:</b> www.njms.in
	<b>DOI:</b> 10.4103/0975-5950.140181

of the jaws.<sup>[8]</sup> However, it can be clinically aggressive, associated with pain, osseous destruction, cortical perforation, root resorption, and recurrence.<sup>[9]</sup> Cases of CGCG occurring with neurofibromatosis (type 1),<sup>[8,10-12]</sup> Noonan-like syndrome,<sup>[13,14]</sup> or both<sup>[8,15]</sup> have been reported. These lesions may possibly lead to a confusion in their correct diagnosis as many pathologists report them taking into consideration one of the prominent histopathologic feature. Such misinterpretation may be because of the small number of cases reported in the literature with uncertain clinical, radiographic and histopathologic features of these lesions. So even surgeons may end up treating these lesions inadequately or patients may need to undergo multiple surgeries.<sup>[16-18]</sup> The present case report highlights a case of recurrent and aggressive form of CGCG in the mandible.

### CASE REPORT

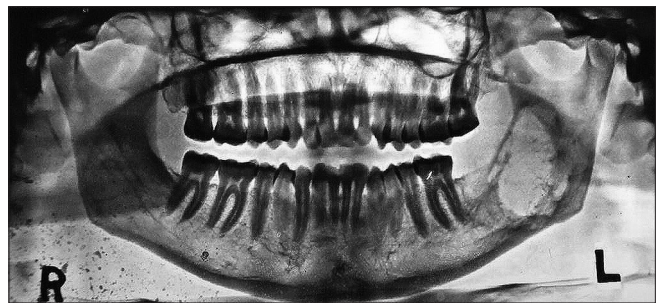
A 22-year-old man presented with a swelling in the left ramus of the jaw 2 years ago. Examination revealed a unilocular radiolucent lesion, with a scalloped inferior border [Figure 1]. The CT scan revealed a well defined hyperdense soft tissue seen in the region of and below the left coronoid process of mandible, with suspicion of sclerosis. A partial mandibulectomy was performed and a reconstruction plate with a mini plate at the anterior region along with a fibular graft in the jaw was inserted to repair the defect [Figure 2]. Microscopy of the biopsied specimen revealed a diagnosis of central giant cell granuloma.

After one year, the patient, now 23 years old, complained of a recurrent swelling in the same region. Intraorally, the patient presented with a growth in the left buccal mucosa at the level of the occlusal plane, which was excised and microscopically reviewed. Histopathological examination revealed it as a granuloma [Figure 3]. The first molar along with the premolars were removed, the region was curetted and a new reconstruction plate was given.

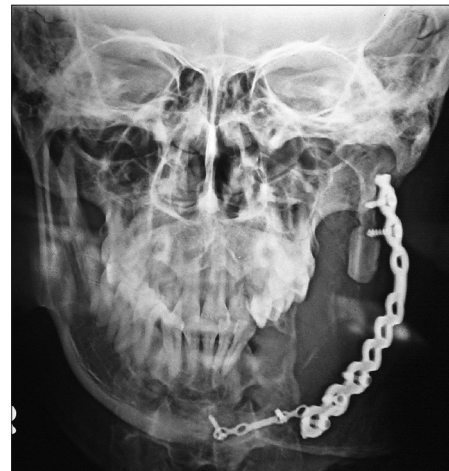
A year later, the patient now 24 years old, was referred to the Department of Oral Surgery with the complaint of pain and recurrent swelling of the left jaw [Figure 4]. The patient had difficulty in opening the mouth. There was no paresthesia and both medical and familial histories were non contributory.

Clinically the lesion extended from the corner of the mouth to the anterior part of tragus on the left side, which was 4 × 4 cm in size, irregular in shape with a rough texture. The swelling was hard in consistency, showed no secondary changes and was non tender on palpation.

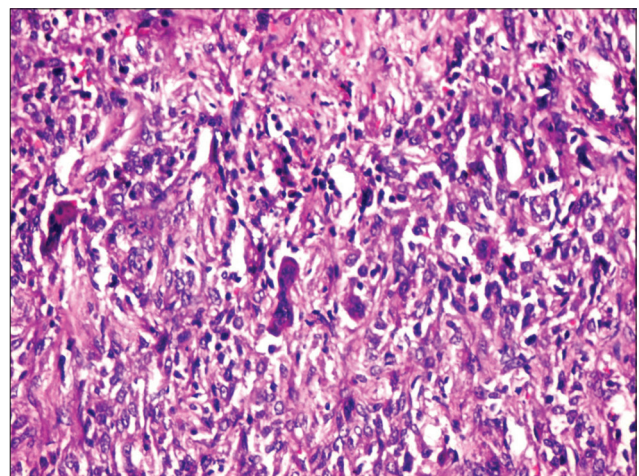
Intraoral examination revealed an exophytic growth present posteriorly near the junction of the buccal



**Figure 1:** Orthopantomograph showing a unilocular radiolucent lesion in the ramus of left jaw. The inferior border of the lesion is scalloped



**Figure 2:** Orthopantomograph showing the reconstruction plate repairing the defect in the left jaw



**Figure 3:** Photomicrograph confirming the presence of granulomatous lesion (H and E, x40)

mucosa and pterygomandibular fossa region, at the level of the occlusal plane, sized 1 × 1.5 cm and soft in consistency. It had a smooth surface with no fluctuation on palpation [Figure 5]. Presently the CT scan revealed an evidence of an expansile destructive mass (4.3 × 3.8 × 4.3 cm in the maximum anteroposterior, transverse and superoinferior dimensions) in the expected location of the left coronoid process, with thin

residual septae like areas of osseous density seen in a large soft tissue mass. This soft tissue mass showed near isodensity compared to the adjacent muscles of the left masseteric space. The lesion expanded the insertion of the left temporalis muscle and bulged anteriorly into the left buccal space and posteriorly into the left condylar head and neck and left parotid gland. Medially, the lesion led to mild pressure erosion with thinning of the buccal cortex of the left maxillary tuberosity and bulged against the left medial pterygoid muscle [Figure 6].

Routine hemogram and urine examination were normal. On the basis of clinical and radiological examination a provisional diagnosis of CGCG was made. The serum chemistry of calcium, phosphorous, parathyroid hormone was normal, there by excluding the possibility of hyperparathyroidism.

Surgery was performed by a submandibular incision at the site of the previous scar, with the removal of the

reconstruction plate, mini plate and graft, along with the condyloid process. The tumor mass and the margins of the normal tissue were removed. A careful and thorough curettage of the residual bone cavity was performed. The defect was repaired by a reconstruction plate attached to a condylar graft.

Histopathological examination of excised specimen revealed evenly dispersed (2-3/HPF) giant cells each having 2-8 nuclei in them, in close approximation with proliferating blood vessels admixed with areas of haemorrhage. The connective tissue was minimal with vesiculated fibroblast proliferation [Figure 7]. The tumor mass had infiltrating margins and residual bony spicules towards the periphery. Even the bone graft attached to the condyle showed the presence of tumor giant cells [Figure 8]. No recurrence was noticed in post operative follow-up phase of 3 years [Figure 9 and 10] and further reconstruction of mandible using iliac crest graft is intended.

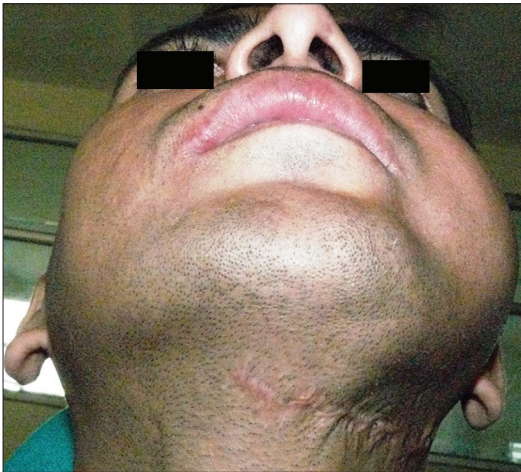

Figure 4: Extra oral swelling of the left lower jaw

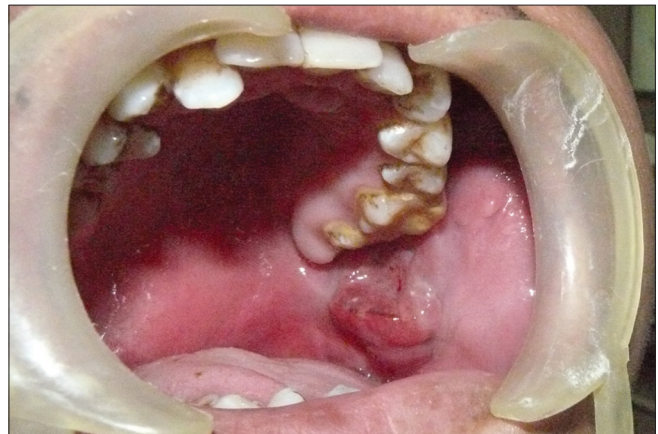

Figure 5: Intra oral photograph depicting exophytic growth in the junction of the left pterygomandibular fossa region and buccal mucosa

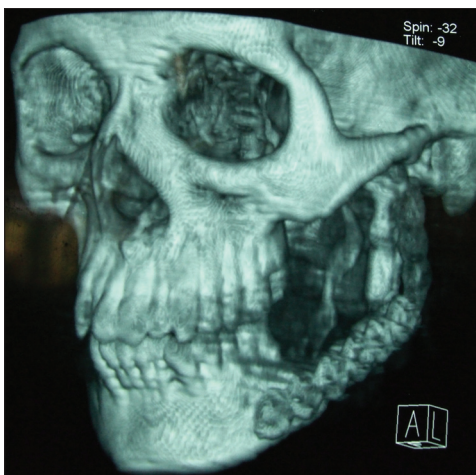

Figure 6: CT scan showing the extent of the lesion during the second recurrence

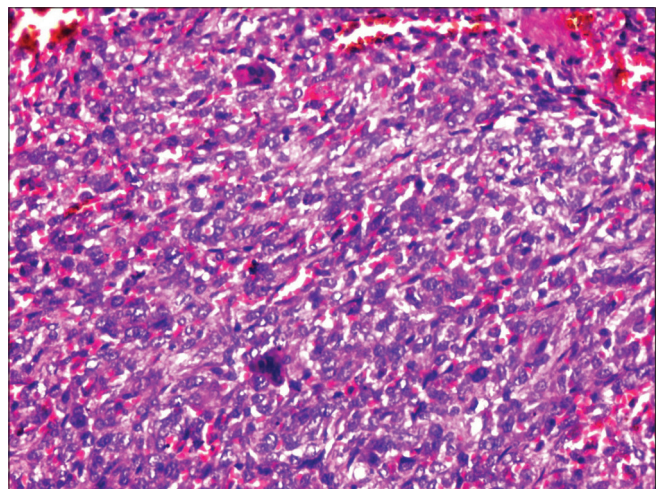
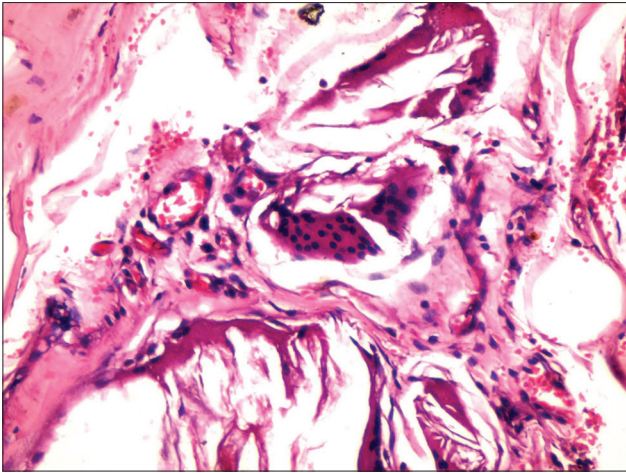
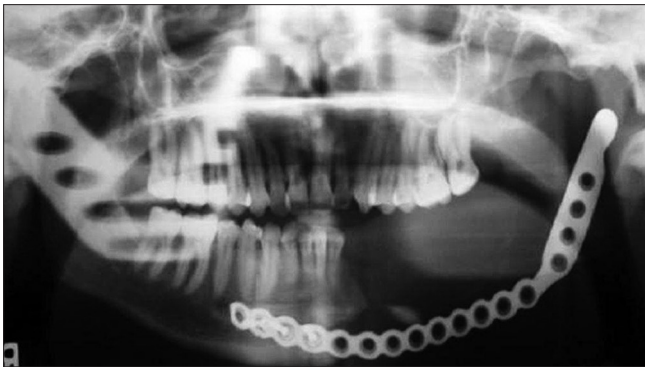


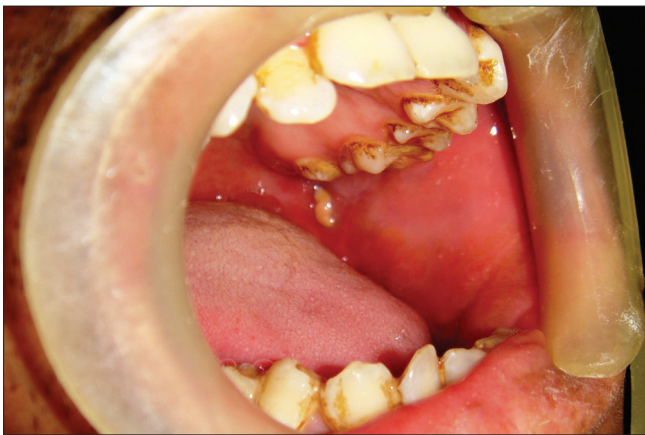Figure 7: Photomicrograph showing giant cells in a vesiculated fibroblast connective tissue stroma (H and E, x40)



**Figure 8:** Photomicrograph showing presence of giant cells near the condylar region (H and E, ×40)



**Figure 9:** Post-operative follow up OPG verifying the absence of lesion



**Figure 10:** Post-operative intraoral view

## DISCUSSION

CGCG is a nonneoplastic proliferative lesion of unknown etiology. The etiopathogenesis of the CGCG of jawbones has not been clearly established but it has been suggested that it is the result of an exacerbated reparative process related to previous trauma and intraosseous hemorrhage that triggers the reactive granulomatous process.<sup>[19,20]</sup>

Donoff and Rosenberg<sup>[21]</sup> discussed a case record of an uncomplicated extraction because of pericoronitis in the area of the lesion and claimed the local changes in the blood flow throughout the bone and local bone dysplasia could be probable etiologic factors. Unal *et al.*,<sup>[22]</sup> presented a 12-year-old girl CGCG in the mandible caused by a molar tooth extraction and explained the pathogenesis by a traumatic aetiology. Association of t(X;4)(q22;q31.3) in the etiology of GCG has been reported.<sup>[23]</sup>

Although, CGCGs are benign osseous lesions, some authors separate CGCG into two types, referring to its clinical and radiographic features: (a) Nonaggressive lesion is usually slow growing and asymptomatic, does not show cortical resorption by the lesion or root perforation in teeth affected, and it is significantly less likely to recur than the aggressive type;<sup>[24]</sup> and (b) Aggressive lesions, is usually found in younger patients and is painful, grows rapidly, is larger, often causes cortical perforation and root resorption and has a tendency to recur.<sup>[25]</sup> Predicting the behavior of CGCGs that will exhibit a higher risk of recurrence after treatment has been problematic. The rate of recurrence varies between 13-49%.<sup>[26]</sup> Whitaker and Waldron<sup>[4]</sup> reported a mean interval between diagnosis and initial treatment and treatment of a recurrence was 21 months, and stated that very few recurrences were manifested after 2 years of initial treatment. The present case shows two recurrences in the past 2 years. The most reliable factors related to an increased risk of recurrence include clinical activity of lesions (72% of recurrence in the aggressive forms, 3% of recurrence in the nonaggressive forms), younger patients, demonstrated perforation of cortical bone and tumor size.<sup>[9,27,28]</sup> There has been studies suggesting that the greater functional surface area occupied by giant cells and larger relative size of giant cells may identify tumors with aggressive behavior.<sup>[25,29]</sup> Recently, Kruse-Loser *et al.*,<sup>[9]</sup> also proved that the aggressive variant of CGCG presented a high number of giant cells, an increased mitotic activity, and a high fractional surface area. However, other studies have not been able to predict the clinical course of CGCGs from known histological or immunohistochemical features.<sup>[20]</sup>

We reviewed the archival cases of 10 CGCGs from our department which were nonaggressive and non recurrent, the demographical information, location, radiographic features and histopathological features of which are shown in Table 1.

The present case showed 2-3 giant cells per high power field, which was less compared to that seen in our archival cases. The connective tissue was minimal, but with a high cellularity and a vesiculated fibroblast population. The nonaggressive cases of CGCG showed a minimal - moderate cellularity and a non vesiculated fibroblast population. The

**Table 1: The demographic information, location, radiographic features and histopathological features of 10 nonaggressive CGCGs are as follows**

Patient no.	Age	Sex	Location	Radiographic features	Histopathological features
1	30	F	Maxilla (anterior)	Unilocular radiolucency	Number of giant cells: 7-10/H.P field Connective tissue cellularity: Minimal Vascularity: Moderate
2	17	M	Maxilla (posterior)	Unilocular radiolucency	Number of giant cells: 6-10/H.P field Connective tissue cellularity: minimal Vascularity: Marked
3	15	F	Mandible (posterior)	Unilocular radiolucency	Number of giant cells: 4-7/H.P field Connective tissue cellularity: Moderate Vascularity: Minimal
4	22	F	Mandible (anterior)	Unilocular radiolucency with few trabeculations	Number of giant cells: 1-6/H.P field Connective tissue cellularity: Minimal Vascularity: Minimal
5	24	M	Mandible (posterior)	Multilocular radiolucency	Number of giant cells: 1-10/H.P field Connective tissue cellularity: Minimal Vascularity: Marked
6	30	F	Mandible (posterior)	Unilocular radiolucency with specks of radiopacity	Number of giant cells: 2-10/H.P field Connective tissue cellularity: Moderate Vascularity: Minimal
7	24	M	Mandible (posterior)	Unilocular radiolucency with scalloped borders	Number of giant cells: 8-10/H.P field Connective tissue cellularity: Minimal Vascularity: Moderate
8	40	F	Mandible (anterior)	Unilocular radiolucency	Number of giant cells: 6-12/H.P field Connective tissue cellularity: Minimal Vascularity: Marked
9	34	F	Mandible (posterior)	Multilocular radiolucency	Number of giant cells: 5-12/H.P field Connective tissue cellularity: Minimal Vascularity: Marked
10	29	M	Mandible (anterior)	Unilocular radiolucency	Number of giant cells: 6-10/H.P field Connective tissue cellularity: Minimal Vascularity: Moderate

vascularity in the present case was minimal, which was not a differentiating factor, as cases in the archives showed a varied vascularity from minimal to marked.

The radiological appearance of CGCG is variable. Usually the lesion appears as a unilocular or multilocular radiolucency. It may be well-defined or ill-defined and shows variable expansion and destruction of the cortical plate. The radiological appearance of the lesion is not pathognomonic and may be confused with that of many

other lesions of jaws. The final diagnosis eventually rests on histopathology because the clinical and radiological features are not specific. CGCG of the jaw usually presents as a painless solitary radiolucent expansion in most of the cases. Some lesions are more destructive with a marked tendency to recur. A more aggressive type of such lesion will require more radical treatment.<sup>[30]</sup>

CGCG is composed of two distinct populations of cells viz. multinucleated giant cells and spindle shaped stromal cells. The latter are thought to be proliferating tumor cells based on available evidence.<sup>[31,32]</sup> These are osteoblast like cells with similar functions. They induce osteoclast formation from mononuclear blood cells via RANK-RANKL interaction. RANKL (receptor activator of nuclear factor kb ligand) present on stromal cells influences the differentiation of giant cells from RANK expressing mononuclear cells.<sup>[33]</sup>

Amongst all, GCT is most difficult to differentiate from CGCG without clinical and histological aids. CGCG generally occurs at younger age than GCT. Histologically, CGCG has a hemorrhagic background with presence of plump bland fibroblast, hemosiderin and fewer giant cells with smaller number of nuclei, which are less uniformly distributed. While in case of GCT, giant cells are uniformly scattered with larger number of nuclei and absence of fibroblasts and hemorrhage. Diffuse sheets of large giant cells and polygonal mononuclear cells seen in GCT are lacking in CGCG. Deposition of osteoid is observed in CGCG sometimes which is lacking in GCT. Cystic areas (the Aneurysmal Bone Cyst component) are lesser as compared to GCT. Differential diagnosis from Brown tumor is based mainly on clinical and laboratory data, as well as age of onset and multiplicity of lesions.<sup>[34]</sup>

Immunohistochemical studies on CGCG have helped to establish the lineage of the cells, but not to predict the aggressiveness of the lesion. Supporting the theory that the multinucleated giant cells are derived from macrophages is the immunoreactive response to muramidase,  $\alpha$ -1antichymotrypsin, and  $\alpha$ -1antitrypsin.<sup>[35]</sup> Aggressive and nonaggressive CGCGs stained for antibodies to CD34, CD68, factor XIIIa, and smooth muscle actin, prolyl 4-hydroxylase, Ki-67, p53 protein, RANK, and glucocorticoid receptor alpha have revealed no phenotypic differences between the types.<sup>[36,37]</sup> Calcitonin receptor expression, however, has been found to exhibit a statistically significant difference with more expression in the aggressive type.<sup>[37]</sup>

The management of CGCG will depend on the clinical and radiographic findings. Generally, curettage of well-defined localized lesions is associated with a low rate of recurrence. In extensive lesions with radiographic evidence of perforation of cortex, a more radical excision is mandatory. In such cases even partial maxillectomy or

mandibulectomy has to be done. The medical management of CGCG as an adjunct to surgery includes treatment with steroids or calcitonin which inhibits osteoclastic activity.<sup>[38]</sup> Interferon-alpha appears useful in the management of aggressive CGCG, presumably due to its anti-angiogenic effects.<sup>[39]</sup> Bisphosphonates have been administered intravenously in CGCG with promising results.<sup>[40]</sup>

## ACKNOWLEDGMENT

The authors would like to express gratitude to their colleagues in India, especially Dr. Prince Kumar, for help regarding designing, preparation and editing of the manuscript.

## CONCLUSION

Although extensive literature has been made available to the readers who envisage a keen interest in CGCG of the jaw, clarity to this entity with respect to terminology, behavior and its adjunctive nature to the GCT occurring in long bones has rarely been lucid in its understanding. The concomitant presence or initiation of this entity with various other diseases like aneurysmal bone cyst and also its histopathological similarities to diseases associated with hormonal imbalances like hyperparathyroidism/Browns tumor has compelled researchers to question its de-facto existence.

The present case highlights the perplexity in diagnosing CGCGs, which are aggressive in nature due to its close proximity with respect to pathology, behavior and prognosis from GCT. The recurrent nature of the present case and the extensive destruction caused in the hard and soft tissues convinces us the need of exploring the possibilities of the so called true 'tumors' (giant cell tumors) having a definitive presence in the jaws.

## REFERENCES

- Jaffe HJ. Giant cell reparative granuloma, traumatic bone cyst and fibrous (fibro- osseous) dysplasia of jaw bones. *Oral Surg Oral Med Oral Pathol* 1953;6:159-75.
- Motamedi MH, Eshghyar N, Jafari SM. Peripheral and central giant cell granulomas of the jaws: A demographic study. *Oral Surg Oral Med Oral Pathol Oral Radiol Endod* 2007;103:39-43.
- Waldron CA, Shafer WG. The central giant cell reparative granuloma of the jaws: An analysis of 38 cases. *Am J Clin Pathol* 1966;45:437-47.
- Whitaker SB, Waldron CA. Central giant cell lesions of the jaws: A clinical, radiologic, and histopathologic study. *Oral Surg Oral Med Oral Pathol* 1993;75:199-208.
- Kaffe I, Ardekian L, Taicher S. Radiologic features of central giant cell granuloma of the jaws. *Oral Surg Oral Med Oral Pathol Oral Radiol Endod* 1996;81:720-6.
- Lorenzo JC, Dorfman HD. Giant-cell reparative granuloma of short tubular bones of the hands and feet. *Am J Surg Pathol* 1980;4:551-63.
- Glass TA, Mills SE, Fechner RE. Giant-cell reparative granuloma of the hands and feet. *Radiology* 1983;149:65-8.
- De Lange J, Van den Akker HP. Clinical and radiological features of central giant-cell lesions of the jaw. *Oral Surg Oral Med Oral Pathol Oral Radiol Endod* 2005;99:464-70.
- Kruse-Losler B, Diallo R, Gaertner C. Central giant cell granuloma of the jaws: A clinical, radiologic, and histopathologic study of 26 cases. *Oral Surg Oral Med Oral Pathol Oral Radiol Endod* 2006;101:346-54.
- Ardekian L, Manor R, Peled M. Bilateral central giant cell granulomas in a patient with neurofibromatosis: Report of a case and review of the literature. *J Oral Maxillofac Surg* 1999;57:869-72.
- Ruggieri M, Pavone V, Polizzi A. Unusual form of recurrent giant cell granuloma of the mandible and lower extremities in a patient with neurofibromatosis type 1. *Oral Surg Oral Med Oral Pathol Oral Radiol Endod* 1999;87:67-72.
- Edwards PC, Fantasia JE, Saini T. Clinically aggressive central giant cell granulomas in two patients with neurofibromatosis. *Oral Surg Oral Med Oral Pathol Oral Radiol Endod* 2006;102:765-72.
- Cohen MM Jr, Gorlin RJ. Noonan-like/multiple giant cell lesion syndrome. *Am J Med Genet* 1991;40:159-66.
- Cancino CM, Gaiao L, Sant'Ana Filho M. Giant cell lesions with a Noonan-like phenotype: A case report. *J Contemp Dent Pract* 2007;8:67-73.
- van Damme PA, Mooren RE. Differentiation of multiple giant cell lesions, Noonan-like syndrome, and (occult) hyperparathyroidism: case report and review of the literature. *Int J Oral Maxillofac Surg* 1994;23:32-6.
- Stolovitzky JP, Waldron CA, McConnel FM. Giant cell lesions of the maxilla and paranasal sinuses. *Head Neck* 1994;16:143-8.
- Terry BC, Jacoway JR. Management of central giant cell lesions: An alternative to surgical therapy. *Oral Maxillofac Surg Clin North Am* 1994;6:579-600.
- de Lange J, van den Akker HP, Veldhuijzen van Zanten GO. Calcitonin therapy in central giant cell granuloma of the jaw: A randomized double-blind placebo-controlled study. *Int J Oral Maxillofac Surg* 2006;35:791-5.
- Ustundag E, Iseri M, Keskin G, Muezzinoglu B. Central giant cell granuloma. *Int J Pediatr Otorhinolaryngol* 2002;65:143-6.
- Kauzman A, Li SQ, Bradley G, Bells RS, Wunder JS, Kandel R. Central giant cell granuloma of the jaws: Assessment of cell cycle proteins. *J Oral Pathol Med* 2004;33:170-6.
- Donoff RB, Rosenberg AE. Case records of the Massachusetts General Hospital. Weekly clinicopathological exercises. Case 20-1993. A 23-year-old woman with a rapidly enlarging intraoral mass after a tooth extraction. *N Engl J Med* 1993;328:1478-83.
- Unal M, Karabacak T, Vayisoglu Y, Bagis HE, Pata YS, Akbas Y. Central giant cell reparative granuloma of the mandible caused by a molar tooth extraction: Special reference to the maneuver of drilling the surgical field. *Int J Pediatr Otorhinolaryngol* 2006;70:745-8.
- Buresh CJ, Seemayer TA, Nelson M, Neff JR, Dorfman HD, Bridge J. t(X; 4)(q22;q31.3) in giant cell reparative granuloma. *Cancer Genet Cytogenet* 1999;115:81-1.
- Eisenbud L, Stern M, Rothberg M, Sachs SA. Central giant cell granuloma of the jaws: Experiences in the management of 37 cases. *J Oral Maxillofac Surg* 1988;46:376-84.
- Chuong R, Kaban LB, Kozakewich H, Perez-Atayde A. Central giant cell lesions of the jaws: A clinicopathologic study. *J Oral Maxillofac Surg* 1986;44:708-13.
- de Lange J, van den Akker HP, Klip H. Incidence and disease-free survival after surgical therapy of central giant cell granulomas of the jaw in the Netherlands. *Head Neck* 2004;26:792-5.
- Minic A, Stajcic Z. Prognostic significance of cortical perforation in the recurrence of central giant cell granulomas of the jaws. *J Craniomaxillofac Surg* 1996;24:104-8.
- Bataineh AB, Al-Khateeb T, Rawashdeh MA. The surgical treatment of central giant cell granuloma of the mandible. *J Oral Maxillofac Surg* 2002;60:756-61.
- Yamaguchi T, Dorfman HD. Giant cell reparative granuloma:

- A comparative clinicopathologic study of lesions in gnathic and extragnathic sites. *Int J Surg Pathol* 2001;9:189-200.
30. Ebrahimi H, Yazdani J, Pourshahidi S, Esmali F, Zenouz AT, Mehdipour M. Central giant cell granuloma of the posterior maxilla: A case report. *J Dent Res Dent Clin Dent Prospects* 2008;2:71-5.
  31. Liu B, Yu SF, Li T. Multinucleated giant cells in various forms of giant cell containing lesions of the jaws express features of osteoclasts. *J Oral Pathol Med* 2003;32:367-75.
  32. Itonaga I, Hussein I, Kudo O, Sabokbar A, Watt-Smith S, Ferguson D, *et al.* Cellular mechanisms of osteoclast formation and lacunar resorption in giant cell granuloma of the jaw. *J Oral Pathol Med* 2003;32:224-31.
  33. Miyamoto N, Higuchi Y, Tajima M, Ito M, Tsurudome M, Nishio M. Spindle-shaped cells derived from giant-cell tumor of bone support differentiation of blood monocytes to osteoclast-like cells. *J Orthop Res* 2000;18:647-54.
  34. Murphey MD, Nomikos GC, Flemming DJ, Gannon FH, Temple HT, Kransdorf MJ. Imaging of Giant Cell Tumor and Giant Cell Reparative Granuloma of Bone: Radiologic-Pathologic Correlation. *Radiographics* 2001;21:1283-309.
  35. Regezi JA, Zarbo RJ, Lloyd RV. Muramidase, alpha-1 antitrypsin, alpha-1 antichymotrypsin, and S-100 protein immunoreactivity in giant cell lesions. *Cancer* 1987;59:64-8.
  36. O'Malley M, Pogrel MA, Stewart JC. Central giant cell granulomas of the jaws: Phenotype and proliferation-associated markers. *J Oral Pathol Med* 1997;26:159-63.
  37. Tobon-Arroyave SI, Franco-Gonzalez LM, Isaza-Guzman DM. Immunohistochemical expression of RANK, GRalpha and CTR in central giant cell granuloma of the jaws. *Oral Oncol* 2005;41:480-8.
  38. Harris M. Central giant cell granulomas regress with calcitonin therapy. *Br J Oral Maxillofac Surg* 1993;31:89-94.
  39. Kaban LB, Troulis MJ, Ebb D. Antiangiogenic therapy with interferon alpha for giant cell lesions of the jaws. *J Oral Maxillofac Surg* 2002;60:1103-11.
  40. Davis JB, Archer DJ, Fisher C, Wimabawansa SJ, Baldwin D. Multiple recurrent giant cell lesions associated with a high circulating level of parathyroid hormone related peptide in a young adult. *Br J Oral Maxillofac Surg* 1991;29:102-5.

**How to cite this article:** Yadav S, Singh A, Kumar P, Tyagi S. Recurrent case of central giant cell granuloma with multiple soft tissue involvement. *Natl J Maxillofac Surg* 2014;5:60-6.

**Source of Support:** Nil. **Conflict of Interest:** None declared.