



Since January 2020 Elsevier has created a COVID-19 resource centre with free information in English and Mandarin on the novel coronavirus COVID-19. The COVID-19 resource centre is hosted on Elsevier Connect, the company's public news and information website.

Elsevier hereby grants permission to make all its COVID-19-related research that is available on the COVID-19 resource centre - including this research content - immediately available in PubMed Central and other publicly funded repositories, such as the WHO COVID database with rights for unrestricted research re-use and analyses in any form or by any means with acknowledgement of the original source. These permissions are granted for free by Elsevier for as long as the COVID-19 resource centre remains active.

Fixed drug eruption after Pfizer-BioNTech COVID-19 vaccine:

A case report

Elodie Lellig, MD, Claudie Mouton-Faivre, MD,
Diane Abs, MD, and Anne-Claire Bursztejn, MD, PhD



Clinical Implications

We report a case of fixed drug eruption after the coronavirus disease 2019 vaccine Comirnaty®-BioNTech/Pfizer confirmed by positive patch test results with vaccine and with polyethylene glycol on the previously involved site.

A 54-year-old woman without relevant medical history except seasonal allergic rhinitis (and without regular medication) presented a 3- to 4-cm well-defined erythematous patch on her left wrist (Figure 1). This lesion occurred 24 hours after the woman received the first dose of mRNA coronavirus disease 2019 (COVID-19) vaccine Comirnaty®-BioNTech/Pfizer on her right arm. The patient did not report any other drug intake (including acetaminophen) in the days preceding the occurrence of the lesion. A desquamation occurred after 15 days. The eruption cleared gradually spontaneously in 25 days with persistence of a small residual erythematous area. She received the second dose of vaccine 28 days after the first one. Four days later, the eruption recurred at the same site. Skin biopsy of the initial lesion revealed acute vacuolar interface changes and keratinocyte necrosis with superficial perivascular infiltrate of lymphocytes. Based on clinical features, compatible delay, and histology, the diagnosis of fixed drug eruption (FDE) induced by Comirnaty®-BioNTech/Pfizer vaccine was made. The patient was treated with topical beclomethasone dipropionate. The eruption cleared in 21 days without residual hyperpigmentation.

Five weeks following the second dose, patch tests were performed on the previously involved site, using the vaccine pure and diluted at 30% in petrolatum. Patch test with vaccine diluted at 30% in petrolatum showed positive reaction (+) after 48 hours (Figure 2). We tested polyethylene glycol (PEG) diluted at 30% in petrolatum on the previously involved site: a positive patch test reaction (+) was observed after 144 hours. Patch test result with petrolatum was negative. Patch tests with vaccine diluted at 30% in petrolatum, undiluted vaccine, PEG, and petrolatum were performed on normal skin (on the back) and results were negative. Patch tests 30% vaccine in petrolatum and PEG diluted at 30% in petrolatum were done on 5 other controls and results were negative.

After discussion, we decided to contraindicate the use of PEG in injectable forms and in colic preparations (for laxative use), considering the largest amount of PEG contained in these medications. Indeed, there are alternative treatments to colic preparations. The patient has never taken PEG for laxative use before. The benefit-risk balance is positive for the vaccine if a third dose is necessary, although it contains PEG. Cross-reactivity between PEG and polysorbate has been suggested in

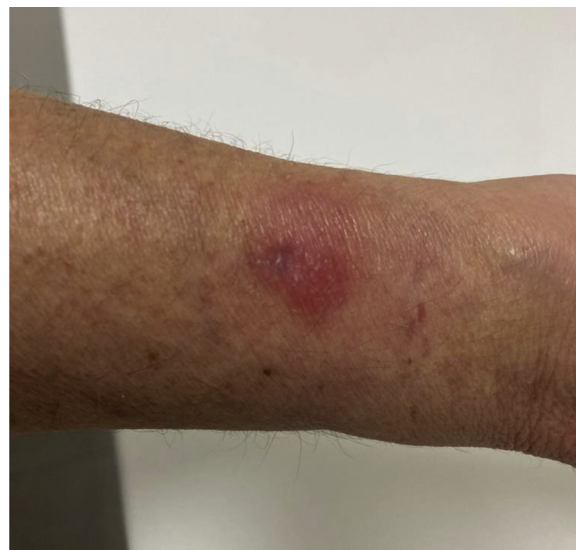

FIGURE 1. Well-defined erythematous patch on the left wrist 24 hours after the first dose of mRNA COVID-19 vaccine Comirnaty®-BioNTech/Pfizer.

immediate allergies but polysorbate 80 (PS) contained in vaccine is tolerated by PEG-allergic patients.¹ Therefore, we did not test PS nor contraindicate any PS excipient drug.

One other case of FDE after Comirnaty®-BioNTech/Pfizer vaccine is reported in the literature. Fifteen days after vaccination with Comirnaty®-BioNTech/Pfizer, the patient developed on the same arm an erythematous patch with subsequent central erosion. After the second injection, the patch recurred with vesiculations. Patch tests were not performed.²

FDE associated with vaccines is rarely described in the literature. Three cases associated with *influenza* vaccination are reported: 1 generalized bullous FDE located on bilateral hips and lower back,³ 1 FDE located on a wrist, and 1 FDE located on a hand.⁴ Among these 3 cases, patch tests were performed for 2 of them⁴ and results were positive using vaccine diluted at 10% in petrolatum. The time of onset was from 1 to 3 days. Egg protein was supposed to be imputable but was not contraindicated. One case of localized bullous FDE after the second human papilloma virus vaccine injection⁵ is described; however, delay of onset was only 2 hours and patch test results were negative. One case of bullous FDE localized to the nose⁶ was reported 4 days after yellow fever vaccination without allergological investigations. For all cases, contraindication to excipients and vaccines was not discussed.

Regarding other reactions with Comirnaty®-BioNTech/Pfizer vaccine, immediate allergic reactions are described, including urticaria, angioedema, rash, and a sense of throat closure.^{7,8} PEG is mostly known for contact dermatitis. No delayed reactions including FDE are reported after administration of a medication containing PEG.

We report a case of FDE associated with COVID-19 vaccination confirmed by positive patch test results with

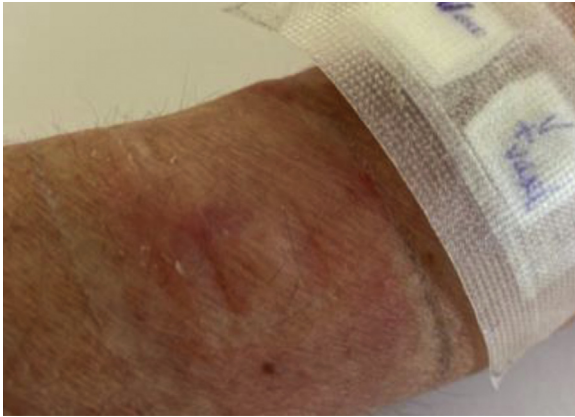


FIGURE 2. Skin test results on lesional skin with Comirnaty®-BioNTech/Pfizer diluted at 30% in petrolatum showing positive reactivity (+) after 48 hours.

Comirnaty®-BioNTech/Pfizer vaccine and PEG, on the previously involved site. To date, the etiology of allergic reactions to the mRNA COVID-19 vaccines is not clear.⁹ Regarding FDE after COVID-19 vaccine, the favorable benefit-risk ratio should encourage to complete the vaccination schedule.

Department of Dermatology and Allergology, University Hospital of Nancy, Vandœuvre-lès-Nancy, France

Conflicts of interest: The authors declare that they have no relevant conflicts of interest.

Received for publication June 8, 2021; revised February 25, 2022; accepted for publication March 29, 2022.

Available online April 22, 2022.

Corresponding author: Anne-Claire Bursztejn, MD, PhD, Dermato-Allergology Department, Bâtiment Philippe Canton, CHRU Nancy, 6 rue du Morvan, 54500 Vandœuvre-lès-Nancy, France. E-mail: ac.bursztejn@chru-nancy.fr.

2213-2198

© 2022 American Academy of Allergy, Asthma & Immunology

<https://doi.org/10.1016/j.jaip.2022.03.033>

REFERENCES

1. Sellaturay P, Gurugama P, Harper V, Dymond T, Ewan P, Nasser S. The poly-sorbate containing AstraZeneca COVID-19 vaccine is tolerated by polyethylene glycol (PEG) allergic patients. *Clin Exp Allergy* 2022;52:12-7.
2. Mintoff D, Pisani D, Betts A, Scerri L. SARS-CoV-2 mRNA vaccine-associated fixed drug eruption. *J Eur Acad Dermatol Venereol* 2021;35:560-3.
3. Byrd RC, Mournighan KJ, Baca-Atlas M, Helton MR, Syn NZ, Siegel MB. Generalized bullous fixed-drug eruption secondary to the influenza vaccine. *J Am Acad Dermatol* 2018;4:953-5.
4. Al-Mutairi N, Al-Fouzan A, Nour-Eldin O. Fixed drug eruption due to influenza vaccine. *J Cutan Med Surg* 2004;8:16-8.
5. Pyl J, Aerts O, Siozopoulou V, Lambert J, Dendooven E, Poschet K, et al. Bullous fixed drug eruption following human papilloma virus vaccination. *J Eur Acad Dermatol Venereol* 2020;34:697-8.
6. Sako EY, Rubin A, Young LC. Localized bullous fixed drug eruption following yellow fever vaccine. *J Am Acad Dermatol* 2014;70:113-4.
7. Shimabukuro T, Nair N. Allergic reactions including anaphylaxis after receipt of the first dose of Pfizer-BioNTech COVID-19 vaccine. *J Am Acad Dermatol* 2021;325:780-1.
8. Sellaturay P, Nasser S, Ewan P. Polyethylene glycol-induced systemic allergic reactions (anaphylaxis). *J Allergy Clin Immunol Pract* 2021;9:670-5.
9. Banerji A, Wickner P, Saff R, Stone CA, Robinson LB, Long AA, et al. mRNA vaccines to prevent COVID-19 disease and reported allergic reactions: current evidence and suggested approach. *J Allergy Clin Immunol Pract* 2021;9:1423-37.