

# Side-by-side partially covered self-expandable metal stent placement for malignant hilar biliary obstruction



## Authors

Katsuya Kitamura, Akira Yamamiya, Yu Ishii, Yuta Mitsui, Tomohiro Nomoto, Hitoshi Yoshida

## Institution

Division of Gastroenterology, Department of Medicine, Showa University School of Medicine, Tokyo, Japan

submitted 6.3.2017

accepted after revision 26.6.2017

## Bibliography

DOI <https://doi.org/10.1055/s-0043-117955> |

Endoscopy International Open 2017; 05: E1211–E1217

© Georg Thieme Verlag KG Stuttgart · New York

ISSN 2364-3722

## Corresponding author

Katsuya Kitamura, MD, PhD, Division of Gastroenterology, Department of Medicine, Showa University School of Medicine, 1-5-8, Hatanodai, Shinagawa-ku, Tokyo, 142-8666, Japan

Fax: +81-3-37847553

[k.kitamura@med.showa-u.ac.jp](mailto:k.kitamura@med.showa-u.ac.jp)

## ABSTRACT

**Background and study aims** This study investigated the feasibility of side-by-side (SBS) partially covered self-expandable metal stent (PCSEMS) placement for unresectable malignant hilar biliary obstruction (MHBO).

**Patients and methods** We retrospectively analyzed 33 patients from a single center who underwent endoscopic biliary drainage for unresectable MHBO from July 2013 to June 2015. In all patients with bilateral obstruction during complete bilateral intrahepatic cholangiograms, we performed endoscopic SBS placement of a 6-mm diameter PCSEMS using an 8-French delivery system. All patients un-

derwent endoscopic sphincterotomy. Generally, patients with recurrent biliary obstruction (RBO) after stent placement underwent endoscopic reintervention. Our study outcomes included the technical and functional success rates, RBO rate, time to RBO (TRBO), reintervention rate, and incidence of adverse events.

**Results** Seventeen patients with unresectable MHBO during complete bilateral intrahepatic cholangiograms underwent endoscopic SBS PCSEMS placement (median age, 78 years; men, 9). Lesions were Bismuth types II (n=10), III (n=1), and IV (n=6), including 10 cholangiocarcinomas, 3 gallbladder cancers, and 4 metastatic cancers. In all patients, the PCSEMS was placed across the duodenal papilla. The technical and functional success rates were 100% and 82%, respectively. The median procedure time was 43 minutes (interquartile range [IQR]: 36–52 minutes). Twelve patients had RBO (71%), including 9 stent occlusions due to sludge and 3 stent migrations. The median TRBO was 79 days (IQR: 58–156 days) during the follow-up period (median 192 days [IQR: 88–551 days]). The median TRBO of patients with Bismuth type II lesions was significantly longer than that of patients with Bismuth types III and IV lesions (87 days [IQR: 70–244 days] vs. 54 days [IQR: 35–100 days];  $P = 0.030$ ). Thirteen patients (76%) required endoscopic reintervention. Endoscopic stent removal was possible in 6 patients without tumor ingrowth into the uncovered distal part of the stent. One late adverse event ( $\geq 31$  days) occurred (cholangitis).

**Conclusions** Endoscopic SBS placement of a PCSEMS was feasible in patients with unresectable MHBO. Additionally, reinterventional stent removal was possible in the absence of tumor ingrowth.

## Introduction

Patients with unresectable malignant hilar biliary obstruction (MHBO) have a poor prognosis. Endoscopic biliary drainage for MHBO is a minimally invasive method of improving patient comfort. Endoscopic biliary stent placement in patients with MHBO is typically performed using a self-expandable metal stent (SEMS) or plastic stent.

A recent meta-analysis comparing SEMSs with plastic stents for malignant biliary obstruction showed that SEMSs were associated with a lower occlusion rate, fewer therapeutic failures, less need for reintervention, and a lower incidence of cholangitis [1]. The same report also indicated that SEMSs have lower short-term and long-term occlusion rates than plastic stents in patients with MHBO [1].

Uncovered SEMs (USEMSs) have been used mainly in patients with unresectable MHBO. However, stent occlusion due to tumor ingrowth often occurs in patients receiving a USEMS. In contrast, tumor ingrowth occurs less frequently after covered SEMs (CSEMS) placement, and endoscopic reintervention such as stent removal may be easy in patients receiving a CSEMS.

Endoscopic biliary SEMs placement for MHBO may be unilateral or bilateral [2, 3], and side-by-side (SBS) or stent-in-stent (SIS) [4, 5]. Currently, there is no consensus on which of these methods represents the optimal treatment for unresectable lesions. Therefore, the present study's aim was to investigate the feasibility of endoscopic SBS placement using a partially CSEMS (PCSEMS) for unresectable MHBO.

## Patients and methods

This retrospective study was approved by the Medical Ethics Committee of Showa University Hospital, and it was registered in the University Hospital Medical Information Network Clinical Trials Registry (UMIN registry number: 000019786). Written informed consent was obtained from all patients before their procedure.

### Patients

We retrospectively analyzed 33 consecutive patients who underwent endoscopic biliary drainage for unresectable MHBO at our institution from July 2013 to June 2015. Exclusion criteria were as follows: patients with unilateral intrahepatic biliary obstruction, those with altered gastrointestinal anatomy, and patients who were unable to provide informed consent.

Before endoscopic SBS PCSEMS placement, multidetector computed tomography, magnetic resonance cholangiopancreatography, and endoscopic retrograde cholangiopancreatography (ERCP) were performed to evaluate the location of the hilar biliary obstruction. In patients in whom bilateral intrahepatic cholangiography could be performed, we conducted endoscopic SBS placement of a 6-mm diameter PCSEMS, which is described later. All patients received endoscopic sphincterotomy and temporary endoscopic nasobiliary drainage before SBS PCSEMS placement. Generally, patients with recurrent biliary obstruction (RBO) [6] after SBS PCSEMS placement underwent endoscopic reintervention.

The Bismuth classification was used to describe the location of the hilar biliary obstruction [7], and the diagnosis of malignancy was confirmed pathologically based on results of endoscopic transpapillary bile duct biopsies and cytologic analysis.

### Devices

The PCSEMS we used for all patients was 6 mm in diameter and either 100 or 120 mm long. It was a braided-type stent with a silicone, membranous material covering both the inner and outer surfaces. Only the distal, 10-mm section of the stent was uncovered, and the other section was fully covered. This stent was placed using an 8-French (Fr) delivery system (Taewoong Medical Co. Ltd., Seoul, Korea) (► Fig. 1).



► **Fig. 1** A 6-mm-diameter partially covered, self-expandable metal stent with an 8-French delivery system (Taewoong Medical Co., Ltd., Seoul, Korea). Only the distal, 10 mm of the stent is uncovered (arrow), and the other section is fully covered.

ERCP was performed using a duodenoscope (JF-260V or TJF-240; Olympus Medical Systems Corp., Tokyo, Japan). All patients underwent ERCP procedures under deep sedation with benzodiazepines and/or pentazocine as analgesics. A sphincterotome, an Autotome RX44 (Boston Scientific, Natick, MA, USA) or an MTW cannula (MTW Endoscopy, Dusseldorf, Germany) was used as an ERCP catheter.

Guide wires used for selective bile duct cannulation included a 0.035-inch Jagwire (Boston Scientific), 0.035-inch Hydra Jagwire (Boston Scientific), and 0.025-inch VisiGlide 2 (Olympus Medical Systems Corp.), based on the requirements of each procedure.

Biliary dilation catheters used included a 6-F-9-Fr Soehendra Biliary Dilation Catheter (Cook Medical, Inc., Bloomington, IN, USA) and 4-mm-diameter Hurricane RX Biliary Balloon Dilation Catheter (Boston Scientific), as indicated during the procedure. An Erbotom ICC 200 unit (Surgical Technology Group, Hampshire, England) in endocut mode was used for endoscopic sphincterotomy with the effect 3 current set at an output limit of 120 W and the forced coagulation current set at an output limit of 30 W.

### SBS placement using a PCSEMS

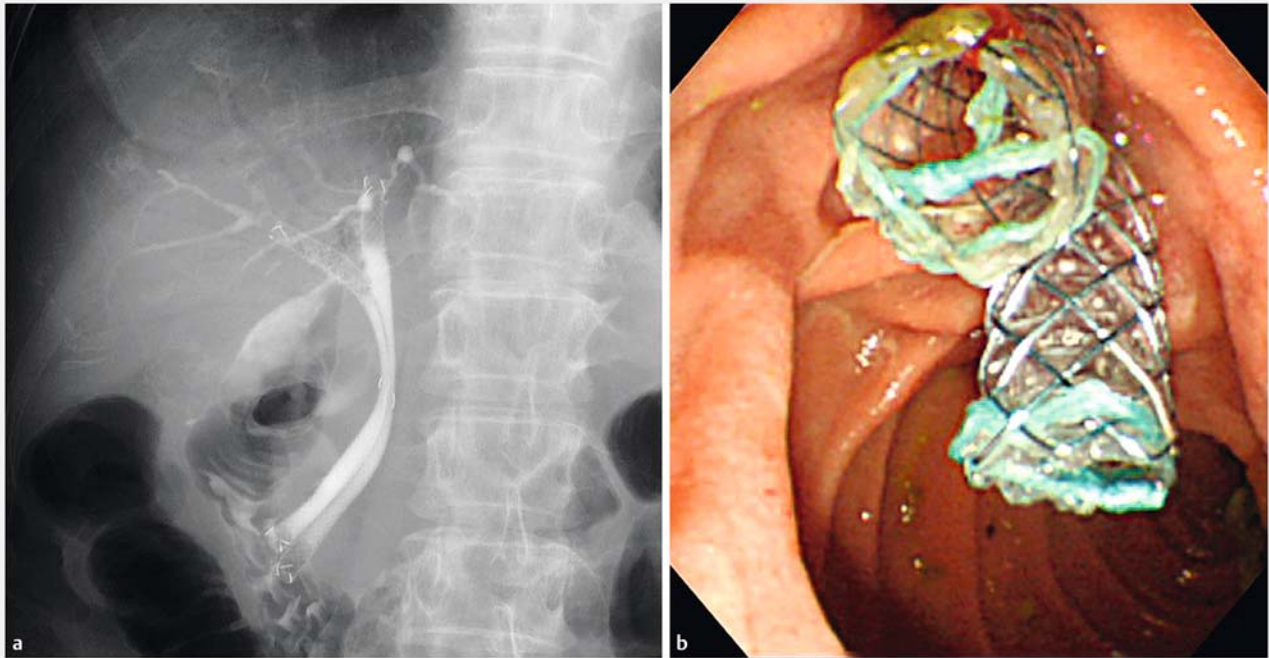
After the diagnosis of unresectable MHBO was confirmed using the aforementioned studies, endoscopic bile duct cannulation with bilateral intrahepatic cholangiography was performed using two 0.035-inch guide wires inserted into the left and right intrahepatic bile ducts through the hilar biliary obstruction.

When we encountered an extremely narrow hilar biliary obstruction, we often performed biliary dilation using a 6-F-9-Fr biliary dilation catheter or 4-mm-diameter biliary balloon dilation catheter, as required by the conditions of the patient.

Finally, each PCSEMS was placed into the left and right intrahepatic bile ducts across the duodenal papilla (► Fig. 2a and ► Fig. 2b). The length of the stent placed (100 or 120 mm) was based on the distance between a point directly above the hilar biliary obstruction and the duodenal papilla, and determined by cholangiogram findings. Several ERCP specialists performed these procedures.

### Reintervention

Endoscopic reintervention was performed if cholangitis (with or without occlusion), cholecystitis, or liver abscess occurred after endoscopic SBS PCSEMS placement. If tumor ingrowth involving the uncovered part of the distal section of the PCSEMS



► **Fig. 2** Endoscopic biliary side-by-side placement using a partially covered self-expandable metal stent (PCSEMS). **a** The cholangiogram. **b** The endoscopic image. PCSEMSs are placed from the left and right intrahepatic bile duct across the duodenal papilla.



► **Fig. 3** Partially covered self-expandable metal stents after removal during endoscopic reintervention.

was absent, the PCSEMS was removed using forceps or a snare (► **Fig. 3**) and replaced with a new SEMS. Otherwise, patients received additional endoscopic stent-in-stent placement.

### Outcome measurements

Our study outcomes were the technical success rate, functional success rate, RBO rate, time to RBO (TRBO), reintervention rate, and adverse events other than RBO. Definitions of these outcomes were based on the TOKYO criteria 2014 for transpapillary biliary stenting [6].

Technical success was defined as successful endoscopic SBS PCSEMS placement in the intended location with sufficient coverage of the MHBO. Functional success was defined as a 50% decrease in or normalization of the bilirubin level within 14 days of endoscopic SBS PCSEMS placement [6].

RBO was defined as stent occlusion or migration. Stent occlusion was diagnosed in the presence of tumor ingrowth,

tumor overgrowth, sludge, hemobilia, food impaction, bile duct kinking, and other factors. Stent migration was diagnosed when complete or partial proximal or distal stent migration was found during reintervention. TRBO was defined as the time from endoscopic SBS PCSEMS placement to the RBO [6].

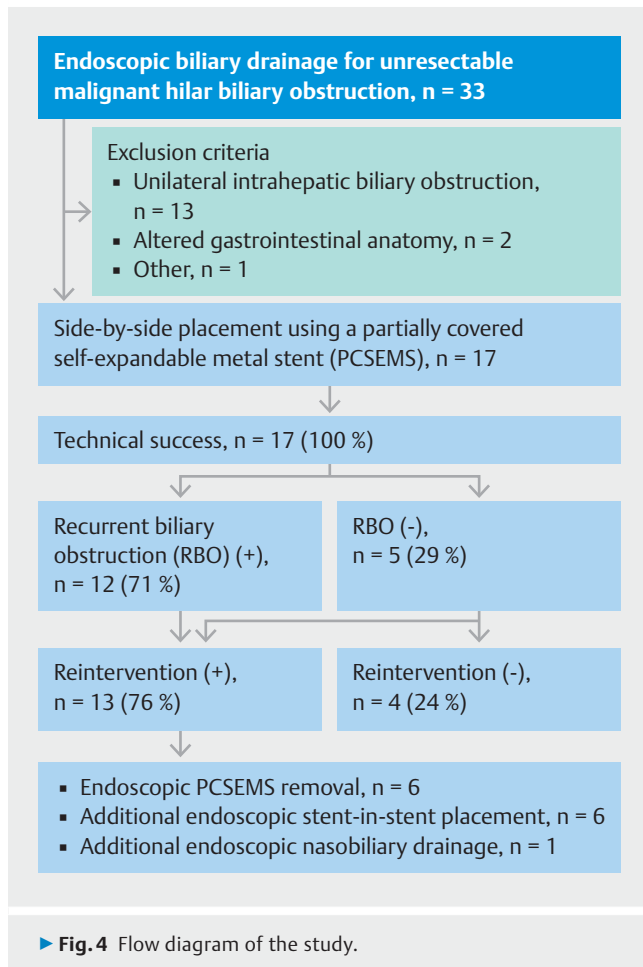
Adverse events other than RBO were categorized as follows: pancreatitis, non-occlusive cholangitis, cholecystitis, and other (bleeding, ulceration, penetration, or perforation). These events were also categorized as early (within 30 days) or late (31 days or later) based on the time to occurrence after endoscopic SBS PCSEMS placement [6].

### Statistical analysis

Continuous variables are expressed as the median (interquartile range [IQR]). TRBO was estimated using the Kaplan–Meier method and compared between groups using the log–rank test [6]. *P* values <0.05 were considered significant. Statistical analyses were performed using StatMate III software (ATMS Co., Ltd., Tokyo, Japan).

### Results

Of 33 consecutive patients who underwent endoscopic biliary drainage for unresectable MHBO, 16 were excluded (13 with unilateral intrahepatic biliary obstructions, 2 with altered gastrointestinal anatomy, and 1 with other exclusion criterion). The remaining 17 patients who received endoscopic SBS placement using a PCSEMS were investigated in this study (► **Fig. 4**). The initial few patients during endoscopic SBS PCSEMS placement were included in this study. Patient characteristics are



shown in ► **Table 1**. The median follow-up (survival) period was 192 days after endoscopic SBS PCSEMS placement. Many causes of death were the progression of cancer and exacerbation of biliary infection.

### Technical success and functional success

The technical success rate was 100 %, and all patients with bilateral intrahepatic cholangiograms were treated with endoscopic SBS PCSEMS placement across the duodenal papilla (► **Table 2**). All 3 patients with functional failure had a gradual decrease in bilirubin levels that began 14 days after endoscopic SBS PCSEMS placement.

### RBO and TRBO

RBO after PCSEMS placement occurred in 12 patients (71 %). Stent occlusions due to sludge occurred in 9 patients, and stent migrations occurred in 3 (distal migration of one stent occurred in 2 patients, and proximal migration of both stents occurred in 1 patient). The median TRBO of patients with Bismuth type II lesions was significantly longer than that of patients with lesions of Bismuth types III and IV ( $P=0.030$ ) (► **Fig. 5**) (► **Table 2**).

► **Table 1** Patient baseline characteristics.

Number of patients	17
Age: Median (IQR), years	78 (69–84)
Sex: Male/female, n	9/8
Etiology of MHBO, n (%)	
▪ Cholangiocarcinoma	10 (59)
▪ Gallbladder cancer	3 (18)
▪ Metastatic cancer	4 (23)
Bismuth classification, n (%)	
▪ Type II	10 (59)
▪ Type III	1 (6)
▪ Type IV	6 (35)
Common bile duct diameter, median (IQR), mm	9 (7–11)
Length of the PCSEMS, right/left, n (%)	
▪ 100 mm/100 mm	13 (76)
▪ 120 mm/120 mm	3 (18)
▪ 100 mm/120 mm	1 (6)
Endoscopic sphincterotomy, n (%)	17 (100)
PCSEMS placement across the duodenal papilla, n (%)	17 (100)
Chemotherapy, n (%)	7 (41)
Follow-up period, median (IQR), days	192 (88–551)

IQR, interquartile range; MHBO, malignant hilar biliary obstruction; PCSEMS, partially covered self-expandable metal stent.

### Reintervention

After SBS PCSEMS placement, 13 patients (76 %) underwent endoscopic reintervention. Endoscopic PCSEMS removal using forceps or a snare was attempted in 10 patients, and it was possible in 6 whose stent showed no tumor ingrowth to the distal uncovered section. Patients whose stent was removed underwent new SEMS placement. Six of the patients who did not undergo stent removal underwent endoscopic SIS placement, and 1 patient underwent additional endoscopic nasobiliary drainage (► **Table 2**) (► **Fig. 4**). The median number of reintervention was 1 (IQR: 1–2 times).

### Adverse events other than RBO

One patient developed non-occlusive cholangitis 31 days after stent placement (► **Table 2**). No severe adverse events were observed during the endoscopic procedures.

### Discussion

The current study's findings indicate that endoscopic SBS placement using a 6-mm diameter PCSEMS was feasible in patients with unresectable MHBO.

**► Table 2** Outcomes of endoscopic side-by-side PCSEMS placement in patients with unresectable malignant hilar biliary obstruction.

Technical success, n (%)	17 (100)
Procedure time, median (IQR), min	43 (36–52)
Functional success, n (%)	14 (82)
RBO, n (%)	12 (71)
Cause of RBO, n	
▪ Occlusion (sludge)	9
▪ Migration	3
TRBO, median (IQR), days	79 (58–156)
▪ Bismuth type II (n = 10)	87 (70–244)
▪ Bismuth types III and IV (n = 7)	54 (35–100)
Reintervention, n (%)	13 (76)
▪ Endoscopic PCSEMS removal, n	6
▪ Additional endoscopic stent-in-stent placement, n	6
▪ USEMS placement	5
▪ Plastic stent placement	1
▪ Additional endoscopic nasobiliary drainage, n	1
Adverse events other than RBO, n (%)	1 (6)
▪ Early (within 30 days), n	0
▪ Late ( $\geq 31$ days), n	1
▪ Cholangitis (non-occlusion)	1
PCSEMS, partially covered self-expandable metal stent; IQR, interquartile range; RBO, recurrent biliary obstruction; TRBO, time to recurrent biliary obstruction; USEMS, uncovered self-expandable metal stent.	

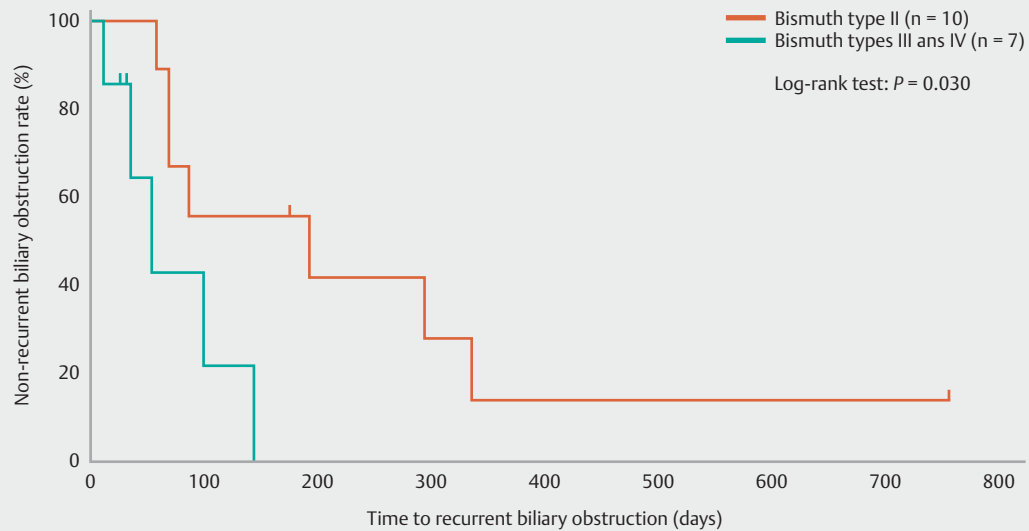
Several studies have reported a technical success rate of 73% to 100% for endoscopic SBS SEMS placement for MHBO [8–11]. In our study, we achieved successful endoscopic placement of an SBS PCSEMS in all patients with bilateral intrahepatic cholangiograms. This SBS PCSEMS placement is relatively easy, and the learning curve may be minimal. Previous studies have shown that SEMSs are preferable to plastic stents in patients with unresectable MHBO [12, 13]. A recent meta-analysis also reported that SEMSs have a lower occlusion rate than plastic stents for MHBO [1]. Until recently, a patient with unresectable MHBO usually received a USEMS because USEMS placement less frequently results in occlusion of the contralateral bile duct and intrahepatic bile duct branches than CSEMS placement. However, there are some disadvantages to the use of USEMSs. One disadvantage is that tumor extension into the stent occurs easily after USEMS placement, and another disadvantage is that guide wire insertion into USEMSs and USEMS removal are difficult to perform during endoscopic reintervention. In contrast, tumor ingrowth occurs less frequently after CSEMS placement, and endoscopic reintervention, such as stent removal, may be easy. On the basis of these findings, we used thin, 6-mm diameter

PCSEMSs to reduce the obstruction of intrahepatic bile duct branches as much as possible.

A few investigators have evaluated endoscopic CSEMS placement for MHBO. Inoue et al. reported that a 6-mm, fully CSEMS (FCSEMS) is a promising option for both primary stent placement and reintervention for MHBO. The technical success rates were 94% and 92% in the initial and reintervention groups, respectively. The median TRBO was 210 days in the initial group after bilateral placement, and 112 and 152 days in the reintervention group after bilateral and unilateral placements, respectively. They also proposed that FCSEMS could cause intrahepatic bile duct occlusion [14]. Another team that evaluated endoscopic SBS placement of a 6-mm-diameter CSEMS (FCSEMS or PCSEMS) for MHBO reported a technical success rate of 97% (FCSEMS, 94%; PCSEMS, 100%), and a mean stent patency period of 95 days (FCSEMS, 113 days; PCSEMS, 68 days). The outcomes were better after FCSEMS placement than after PCSEMS [15].

Endoscopic biliary SEMS placement for MHBO may be unilateral or bilateral [2, 3] and SBS or SIS [4, 5]. Currently, there is no consensus on which of these placement methods represents the optimal treatment for unresectable lesions. The Asia-Pacific Working Group for hepatobiliary cancers reported that optimal palliative stenting in patients with hilar cholangiocarcinoma requires drainage of 50% or more of the liver volume [16]. Given this recommendation, we investigated the clinical outcomes of endoscopic SBS placement of a PCSEMS to evaluate the feasibility of this method for palliative stent placement in patients with unresectable MHBO.

USEMS occlusion is usually caused by tumor ingrowth; however, all the PCSEMS occlusions in the present study were caused by sludge. PCSEMS occlusion due to sludge may result from the membranous material of the CSEMS or the stent's position across the duodenal papilla. Previous studies have reported that SBS stent placement for MHBO has median stent patency periods of 130–169 days when using USEMSs [9–11] and 95 days when using CSEMSs (FCSEMSs, 113 days; PCSEMSs, 68 days) [15]. The median TRBO was 210 days when using FCSEMSs as the primary stent placement [14]. In our study, the median TRBO after endoscopic SBS placement of the PCSEMS was 79 days, and it was not longer than that reported in the aforementioned studies. The relatively small sized diameter of the stent may reduce the TRBO. We may not be able to determine the benefit of this stent in terms of the TRBO; however, this period was significantly longer in patients with Bismuth type II lesions than in the combined group of patients with Bismuth type III or IV lesions, according to the evaluation with the small numbers of patients. The reason for the shorter TRBO in patients with Bismuth III or IV lesions may be due to earlier stent occlusion with tumor ingrowth and sludge in the distal section of the stent, or the shorter survival period. In patients with Bismuth III, we may consider 3 stents insertion as the optimal drainage. In the future, it is necessary to investigate whether a PCSEMS is more useful than other stents (FCSEMS, USEMS, or plastic stent) in terms of stent occlusion, patency, and cost-effectiveness.



► **Fig. 5** Results of the comparison between Bismuth type II and Bismuth types III and IV in relation to time to recurrent biliary obstruction (TRBO) during endoscopic side-by-side partially covered self-expandable metal stent placement using the Kaplan-Meier method. The median TRBO of patients with Bismuth type II was significantly longer than that of patients with Bismuth types III and IV (87 days vs. 54 days, respectively; log-rank test,  $P=0.030$ ).

In the present study, the endoscopic reintervention rate was 76% (13/17) after SBS PCSEMS placement. However, endoscopic PCSEMS removal using forceps or a snare was successful in 60% (6/10) of patients in whom reinterventional stent removal was attempted. In these six patients, no tumor ingrowth occurred in the uncovered section of the stent. New stent placement after stent removal may contribute to reduced risks of RBO and subsequent reintervention.

Stent removal is often not possible after USEMS placement due to tumor ingrowth in the stent. FCSEMSs may be superior to PCSEMSs in terms of stent removal; however, the ability to remove the stent endoscopically is one of the advantages of PCSEMSs. Additionally, because we placed PCSEMSs across the duodenal papilla, we were able to easily perform SIS placement of an additional USEMS or plastic stent during subsequent endoscopic reinterventions. We observed no serious adverse events after endoscopic SBS PCSEMS placement. This success contrasts with the failure of FCSEMS placement due to its associated risks of intrahepatic bile duct branch occlusion.

Limitations of this study are the single-center, retrospective design and the small number of patients evaluated. The percentage of patients with Bismuth III was very low in comparison to that of patients with Bismuth II, and there might be a selection of cases. In the future, multi-center, prospective, randomized, controlled trials with larger numbers of patients are needed to confirm our findings.

## Conclusions

Endoscopic SBS placement of a PCSEMS was feasible in patients with unresectable MHBO. Reinterventional stent removal was possible in the absence of tumor ingrowth. On the basis of our findings, we suggest endoscopic SBS placement of a PCSEMS for patients with unresectable MHBO, bilateral intrahepatic cholangiograms, and a life expectancy of approximately 3 months or more.

## Competing interests

None

## References

- [1] Sawas T, Al Halabi S, Parsi MA et al. Self-expandable metal stents versus plastic stents for malignant biliary obstruction: a meta-analysis. *Gastrointest Endosc* 2015; 82: 256–267.e7
- [2] Freeman ML, Overby C. Selective MRCP and CT-targeted drainage of malignant hilar biliary obstruction with self-expanding metallic stents. *Gastrointest Endosc* 2003; 58: 41–49
- [3] Naitoh I, Ohara H, Nakazawa T et al. Unilateral versus bilateral endoscopic metal stenting for malignant hilar biliary obstruction. *J Gastroenterol Hepatol* 2009; 24: 552–557
- [4] Naitoh I, Hayashi K, Nakazawa T et al. Side-by-side versus stent-in-stent deployment in bilateral endoscopic metal stenting for malignant hilar biliary obstruction. *Dig Dis Sci* 2012; 57: 3279–3285

- [5] Kim KM, Lee KH, Chung YH et al. A comparison of bilateral stenting methods for malignant hilar biliary obstruction. *Hepatogastroenterology* 2012; 59: 341–346
- [6] Isayama H, Hamada T, Yasuda I et al. TOKYO criteria 2014 for transpapillary biliary stenting. *Dig Endosc* 2015; 27: 259–264
- [7] Bismuth H, Castaing D, Traynor O. Resection or palliation: priority of surgery in the treatment of hilar cancer. *World J Surg* 1988; 12: 39–47
- [8] Dumas R, Demuth N, Buckley M et al. Endoscopic bilateral metal stent placement for malignant hilar stenoses: identification of optimal technique. *Gastrointest Endosc* 2000; 51: 334–338
- [9] Cheng JL, Bruno MJ, Bergman JJ et al. Endoscopic palliation of patients with biliary obstruction caused by nonresectable hilar cholangiocarcinoma: efficacy of self-expandable metallic Wallstents. *Gastrointest Endosc* 2002; 56: 33–39
- [10] Chennat J, Waxman I. Initial performance profile of a new 6F self-expanding metal stent for palliation of malignant hilar biliary obstruction. *Gastrointest Endosc* 2010; 72: 632–636
- [11] Lee TH, Park DH, Lee SS et al. Technical feasibility and revision efficacy of the sequential deployment of endoscopic bilateral side-by-side metal stents for malignant hilar biliary strictures: a multicenter prospective study. *Dig Dis Sci* 2013; 58: 547–555
- [12] Wagner HJ, Knyrim K, Vakili N et al. Plastic endoprotheses versus metal stents in the palliative treatment of malignant hilar biliary obstruction. A prospective and randomized trial. *Endoscopy* 1993; 25: 213–218
- [13] Perdue DG, Freeman ML, DiSario JA et al. Plastic versus self-expanding metallic stents for malignant hilar biliary obstruction: a prospective multicenter observational cohort study. *J Clin Gastroenterol* 2008; 42: 1040–1046
- [14] Inoue T, Okumura F, Naitoh I et al. Feasibility of the placement of a novel 6-mm diameter threaded fully covered self-expandable metal stent for malignant hilar biliary obstructions (with videos). *Gastrointest Endosc* 2016; 84: 352–357
- [15] Yoshida T, Hara K, Imaoka H et al. Benefits of side-by-side deployment of 6-mm covered self-expandable metal stents for hilar malignant biliary obstructions. *J Hepatobiliary Pancreat Sci* 2016; 23: 548–555
- [16] Rerknimitr R, Angsuwatcharakon P, Ratanachu-ek T et al. Asia-Pacific consensus recommendations for endoscopic and interventional management of hilar cholangiocarcinoma. *J Gastroenterol Hepatol* 2013; 28: 593–607