



Original Article

Micro-computed tomography evaluation of the prevalence and morphological features of apical bifurcations



Ting Xu, Xianhua Gao, Wei Fan, Bing Fan*

The State Key Laboratory Breeding Base of Basic Science of Stomatology (Hubei-MOST), Key Laboratory of Oral Biomedicine Ministry of Education, School and Hospital of Stomatology, Wuhan University, Wuhan, China

Received 26 April 2019; Final revision received 23 May 2019

Available online 30 December 2019

KEYWORDS

Apical bifurcation;
Micro-CT;
Morphology;
Measurement

Abstract *Background/purpose:* Apical bifurcation, as a common variation in root canal morphology, has great clinical significance for root canal treatment. The aim of this study was to investigate the morphological characteristics of the apical bifurcated canal in Chinese teeth based on a large sample size using micro-CT.

Materials and methods: One thousand and four hundred Chinese permanent teeth were scanned by using micro-CT with the resolution of 15 μm . The number of apical bifurcations was calculated and the vertical distance of apical bifurcations was recorded. The diameter and angles of the apical bifurcated canals were further measured using the centerline algorithm method.

Results: Ninety-two apical bifurcations were detected in 15 anterior teeth, 27 premolars, and 46 M. The median vertical distance of apical bifurcations was 1.1 mm from the apex (ranging from 0.3 to 3.5 mm). Ninety-eight-point nine percent of the apical bifurcations were located less than 3 mm from the apex. The smaller angle of apical bifurcated canals with the main canal was 20.4°. The larger angle of the apical bifurcated canals with the main canal was 32.9°. The median diameter of apical bifurcated canals was 195.0 μm .

Conclusion: A high prevalence of apical bifurcation can be detected in the human permanent teeth, especially in posterior teeth. Most apical bifurcations locate within the apical 3 mm with a diameter more than 200 μm .

© 2019 Association for Dental Sciences of the Republic of China. Publishing services by Elsevier B.V. This is an open access article under the CC BY-NC-ND license (<http://creativecommons.org/licenses/by-nc-nd/4.0/>).

* Corresponding author. The State Key Laboratory Breeding Base of Basic Science of Stomatology (Hubei-MOST), Key Laboratory of Oral Biomedicine Ministry of Education, School and Hospital of Stomatology, Wuhan University, 237 Luoyu Road, Wuhan, 430079, China. Fax: +0086 27 87873260.

E-mail address: bingfan@whu.edu.cn (B. Fan).

<https://doi.org/10.1016/j.jds.2019.05.005>

1991-7902/© 2019 Association for Dental Sciences of the Republic of China. Publishing services by Elsevier B.V. This is an open access article under the CC BY-NC-ND license (<http://creativecommons.org/licenses/by-nc-nd/4.0/>).

Introduction

Root canal bifurcation can occur at either cervical, middle, or apical third of root canals.¹ Some characteristics on radiographic images may indicate the existence of canal bifurcation, such as a sudden narrowing or even a disappearing canal space,² or decreased cervical-to-apical radiolucency and presence of longitudinal radiolucent lines on the root image.^{3,4} Compared with the cervical and middle bifurcations, apical bifurcations (Abs) are the most difficult to be visualized. However, the apical canal bifurcation, as a common variation in root canal morphology, has great clinical significance for root canal treatment including the debridement, instrumentation, obturation or apical surgery procedures.^{4,5}

De-Deus et al. ever reported that the apical canal bifurcation could hinder the instrument file from reaching the full working length just like a ledge.⁶ As the bifurcation located near the apex, it is very difficult to clean with traditional root canal instruments and irrigation methods. Even if the bifurcated canals are thoroughly cleaned, the poor or no filling of the bifurcated canals may also lead to the failure of endodontic therapy.^{7,8} Despite the clinical significance of Abs, the morphological knowledge about the Abs is still lacking.

Many researches regarding the morphologies of root canal system used the tooth clearing technique.^{9,10} However, due to the low efficiency in detecting the fine canal system near the apex, studies related to the morphologies of the apical bifurcated canals are lacking. In recent decades, micro-computed tomography (micro-CT) has been used for observation and analysis of the root canal system because of its non-destructive nature and the capability to analyze specimens with high resolutions.^{11,12}

Recently, Gao et al. successfully examined the morphological features of apical delta using a micro-CT technique and a centerline-fitting algorithm.^{13,14} To clarify the morphological features of the apical bifurcated canal in human teeth, the purpose of present study was to investigate the 3D morphology of the apical bifurcated canal in human teeth based on a large sample size using the micro-CT and the centerline algorithm method.

Materials and methods

Sample collection, scanning and reconstruction

One thousand and four hundred Chinese permanent teeth with well-developed root apex were collected and stored in 10% formalin solution. There were 100 teeth in each tooth type. The collection and use of samples in this study was approved by ethics committee of Wuhan University. The samples were scanned perpendicular to the length axis of the tooth with micro-CT (μ CT-50, Scanco Medical, Basersdorf, Switzerland). The scanning parameters were as follows: 15 microns resolution, 90 kV, 88 mA, 8 W, integration time 500 ms. The 3D model of root canal system was segmented using VGStudio MAX 2.1 (Volume Graphics GmbH, Heidelberg, Germany).

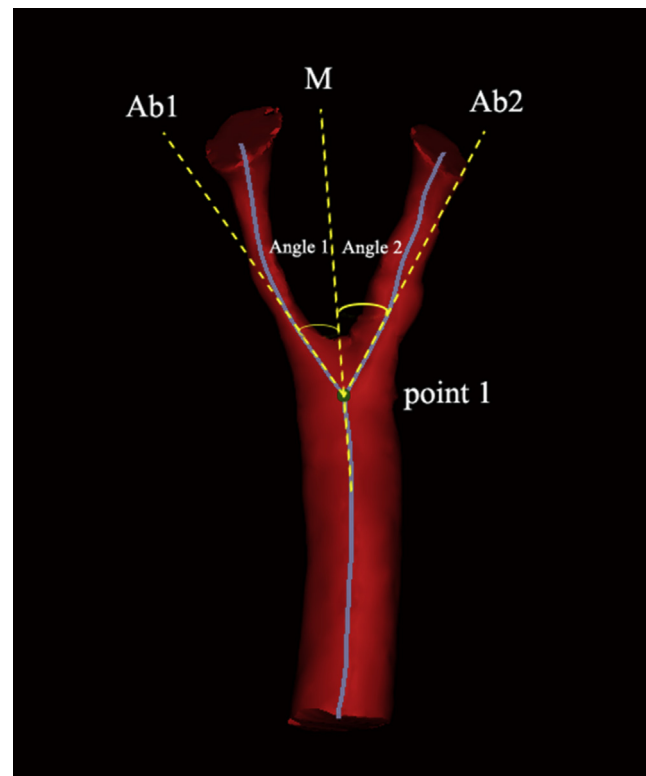


Figure 1 Illustration of small (Angle 1) and large (Angle 2) angle measurement of apical bifurcations (Abs) (point 1: bifurcation point of the main canal; dotted line M: the extension of the central line of main canal; dotted line Ab1 and Ab2: the extension of the straight part of the Abs' central lines close to the point 1; Angle 1 is the angle between the line M and Ab1; Angle 2 is the angle between the line M and Ab2).

The apical bifurcation in this study was defined as 1) the bifurcation locates within 5 mm of the apex; 2) the diameter of the two branches is similar, and the diameter of the smaller branch was not less than 2/3 of the diameter of the larger branch; 3) the bifurcation of the flat canal was not included.

Measurement of apical bifurcations

The vertical distance of apical bifurcation was measured firstly by calculating the distance between start point of the bifurcation and apex. Then, the data were imported into CTAn software (v.1.14.4.1+, SkyScan; Bruker micro-CT, Kontich, Belgium), and the two-dimensional (2d) Otsu image segmentation method was used for segmentation of the bifurcated canal and development of 3D model.

The 3D model was further imported into Mimics (v18.0; Materialize, Leuven, Belgium), and centerline of the surface-rendered bifurcated canal model was developed. The diameter of the bifurcated canals was measured with the method developed by Gao et al. and Xu et al.^{13,14} The Angle between the extension line of the main root canal and the bifurcated canal was also measured (Fig. 1) using

Table 1 Apical bifurcations (Abs) in different tooth types.

Tooth type	Root	No. teeth	No. roots	No. teeth with Abs	No. roots with Abs
Maxillary					
Central incisor		100	100	0	0
Lateral incisor		100	100	2	2
Canine		100	100	2	2
First premolar		100		4	5
	Buccal		30		4
	Palatal		30		0
	Single		70		1
Second premolar		100		6	6
	Buccal		12		4
	Palatal		12		1
	Single		88		1
First Molar		100		11	12
	Mesial-buccal		97		4
	Distal-buccal		97		6
	Palatal		100		2
	Fused		3		0
Second molar		100		11	11
	Mesial-buccal		73		6
	Distal-buccal		75		4
	Palatal		85		0
	Fused		27		1
Total		700		36	38
Mandibular					
Central incisor		100	100	4	4
Lateral incisor		100	100	4	4
Canine		100	100	3	3
First premolar		100	100	8	8
Second premolar		100	100	9	9
First Molar		100		11	11
	Mesial		97		3
	Distal		97		8
	Fused		3		0
	Others		18		0
Second molar		100		13	15
	Mesial		82		8
	Distal		82		7
	Fused		18		0
	Others		6		0
Total		700		52	54

the modified Schneider's method.¹⁵ Two angles of each bifurcation were recorded as large and small angles respectively based on the size of angle.

Statistical analysis

Chi-square test was used for analyzing the prevalence of apical bifurcated canals in different tooth types and roots. When data were not normally distributed as in the differences in the position, diameter and angle of apical bifurcated canals among the different teeth, the analysis was

performed using Kruskal–Wallis analysis of variance. Statistical significance was preset at $\alpha < 0.05$.

Results

Prevalence of apical bifurcations

A total of 92 (6.6%) Abs were detected from 1400 native Chinese teeth including 15 in anterior teeth, 27 in premolars, and 46 in molars (Table 1). The prevalence of Abs in anterior, premolars and molars was 2.5%, 6.8% and 11.5%

respectively. Molars and premolars had significantly more Abs than anterior teeth ($p < 0.05$).

Of 92 Abs, thirty eight Abs were located in maxillary teeth and 54 in mandibular teeth. Although maxillary teeth had a lower prevalence than mandibular teeth, no statistical difference was found. All of the anterior teeth and mandibular premolars showed a single root. Mandibular premolars had higher prevalence of the Abs than maxillary and mandibular anterior teeth ($p < 0.05$).

The Abs number of separate roots and fused roots was shown in Table 1. In maxillary premolars with separated roots, the prevalence of apical canal bifurcations of buccal roots (8.7%) was significantly higher than that of palatal roots (1.1%) ($p < 0.05$). In maxillary molars with separated roots, apical canal bifurcations were more located in the mesio-buccal and distal buccal roots (10.9%) than in the palatal root (2.2%) ($p < 0.05$). In mandibular molars with separated roots, no significant difference was found between the mesial root (12.0%) and distal root (16.3%) ($p > 0.05$). Of 400 M, fifty one molars had fused roots and only one apical bifurcation was observed. Abs occurred more frequently in teeth with separated roots than in teeth with single root ($p < 0.05$).

The position, angle and diameter of the apical bifurcations

Representative images of Abs after 3D reconstruction were shown in Fig. 1. The median vertical distance of Abs was 1.1 mm from the apex (ranging from 0.3 mm to 3.5 mm) (Table 2). There was no significant difference in the distances among anterior teeth, premolar and molars ($p > 0.05$). 45.7% Abs located less than 1 mm from the apex, 43.4% located between 1 and 2 mm from the apex, 9.8% Abs located between 2 and 3 mm from the apex and only 1.1% Abs located between 3 and 5 mm from the apex. Most Abs (89.1%) was located less than 2 mm from the apex ($p < 0.05$). The small angle of apical bifurcated canals with the main canal was 20.4° (range from 3.9° to 54.8°). The large angle of the apical bifurcated canals with the main canal was 32.9° (range from 11.4° to 77.9°). The difference between large and small angle showed statistical significance ($p < 0.05$). The large angle of Abs in premolars was much smaller than that in molars ($p < 0.05$). Measurements of the apical bifurcated canals in different tooth types

were presented in Table 2. The median diameter of apical bifurcated canals was $195.0 \mu\text{m}$ (ranging from 92.7 to $393.7 \mu\text{m}$) with 50.5% less than $200 \mu\text{m}$, 28.8% Abs were between 200 and $250 \mu\text{m}$ and 18.5% more than $250 \mu\text{m}$. There was no statistical difference in diameter of Abs between maxillary and mandibular teeth ($p > 0.05$). The diameter of Abs in anterior teeth and premolars was smaller than that of molars ($p < 0.05$).

The Abs located within 5 mm from the apex in anterior teeth, premolars and molars were reconstructed. The morphological characteristics of Abs were shown in Fig. 2.

Discussion

In the present study, a total of 92 Abs were detected from the 1400 Chinese human permanent teeth. The prevalence of the apical bifurcated canals has not been reported before because the apical bifurcated canals are difficult to be detected on the traditional radiographs.^{16,17} In this study, only the Abs from the round and oval main canal within 5 mm to the apex were studied, and the diameter ratio of bifurcated canals was set to more than 2/3.

The flat canal was defined as the canal with a cross-sectional long: short diameter ratio being no less than 4,¹⁸ and mostly found in maxillary premolars, mandibular incisor, mandibular premolar or the mesial-buccal root of the maxillary molars. The canal system with flat canals often present as Vertucci type I, II and III,¹⁹ and the Abs in flat canals are normally the natural continuation of buccal and lingual parts of the flat canal. Therefore, Abs of flat canals would be negotiated and shaped as two separate canals during the root canal preparation, while that Abs in round or oval canals would be much more difficult to be negotiated and cleaned. Based on these concerns, the bifurcation of flat canals was not included in this study.

The apical bifurcation level is found much closed to the apex in this study. The median bifurcation level was located 1.1 mm from the apex (ranging from 0.3 mm to 3.5 mm). About 98.9% apical bifurcation had a bifurcated level limited in the apical 3 mm. It suggested that a resection of the apical 3 mm in the apical surgery could remove 98.9% of the apical bifurcated canals together with the infections inside. The present study discovered only 1.1% apical bifurcation located more than 3 mm from the apex.

Table 2 The position, angle and diameter of the apical bifurcations (Abs).

Tooth type	No. of Abs	Position of Abs (mm)	Angle 1(°)	Angle 2(°)	Diameter 1(mm)	Diameter 2(mm)	
Maxillary	Anterior teeth	4 ^a	1.4 (1.0–1.7)	17.8 (10.8–28.6)	31.2 (18.5–37.3)	189.6 (136.6–215.6)	201.6 (171.1–316.5)
	Premolars	11 ^b	1.4 (0.4–3.5)	16.1 (5.7–30.6)	26.2 (12.0–59.3)	162.0 (92.7–177.9)	189.8 (131.4–233.5)
	Molars	23 ^b	0.8 (0.3–2.4)	24.0 (11.7–45.0)	38.13 (17.5–74.7)	186.0 (142.8–333.5)	235.1 (174.1–393.7)
Mandibular	Anterior teeth	11 ^a	0.7 (0.3–1.4)	20.4 (4.0–34.5)	31.1 (14.5–44.7)	149.2 (134.4–208.0)	193.3 (154.3–233.1)
	Premolars	17 ^b	1.2 (0.3–1.9)	18.4 (3.9–54.77)	26.8 (11.4–70.0)	182.8 (125.8–267.5)	211.2 (148.3–289.5)
	Molars	26 ^b	1.2 (0.4–2.9)	14.7 (4.2–45.3)	39.1 (18.7–77.9)	199.2 (127.2–315.4)	228.6 (156.1–377.9)

Data are expressed as median (minimum–maximum).

For each datum, groups labeled with same lower case letters are not statistically significant ($p > 0.05$).

Angle 1 was the small angle; Angle 2 was the large angle; Diameter 1 was the diameter of the smaller branch of the apical bifurcations; Diameter 2 was the diameter of the larger branch of the apical bifurcations.

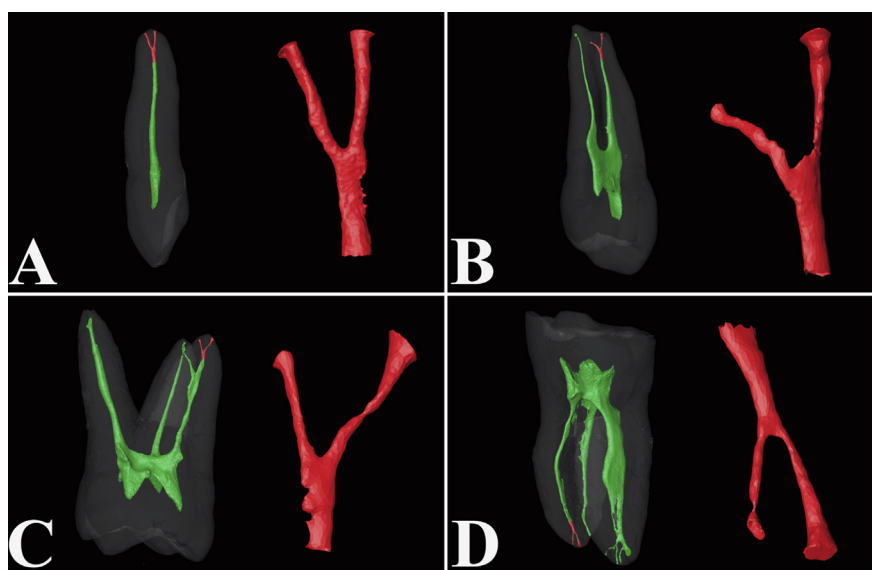


Figure 2 Reconstructed apical bifurcated canals with different morphologic characteristics in different tooth types; A) anterior tooth; B) premolar; C) maxillary molar; D) mandibular molar.

The median diameter of the apical bifurcated canals was $195.0\ \mu\text{m}$ and 18.5% apical bifurcated canals had a diameter more than $250\ \mu\text{m}$. This may imply that a small size pre-curved file sometimes may be able to pass through one or both bifurcated canals with the obtuse angle dividing from the main canal. However, when a negotiation file fails to reach the apical foramen and the main canal becomes indiscernible in the apical third of the root canal system, clinicians need to consider the presence of Abs.

Mechanical shaping the root canal can remove infected soft and hard tissue and create space for the delivery of medicaments and subsequent obturation. However, for some apical bifurcated canals, especially, the bifurcation located near the apex, small size files may not pass through to the working length. It may be impossible to achieve the thorough mechanical instrumentation. The necrotic tissue was left inside, and *Enterococcus faecalis* could survive in these bifurcations.²⁰ Coldero et al. indicated that it may not be necessary to remove the dentine in the apical part of the root canal when a suitable coronal taper is achieved to allow satisfactory irrigation of the root canal system with antimicrobial agents.²¹

The use of passive ultrasonic irrigation, apical negative pressure irrigation devices, or other dynamic modes of irrigation might be useful in enhancing disinfection and cleaning the uninstrumented Abs.²² Irrigation with NaOCl and a final flush with EDTA by means of a small-gauge needle with simultaneous aspiration led to less accumulation of debris.²³ However, the existed dentine debris and bacteria in apical bifurcation cannot be effectively cleaned by the ultrasonic irrigation.²⁴ Endoscopic vacuum-assisted closure (EndoVAC) therapy was reported to leave significantly less debris at 1 mm from WL compared with conventional needle irrigation.²⁵ Recently, GentleWave System was developed to clean the dentinal tubules in the apical third at least 4–8.5 times deeper than the ultrasonic systems in initial endodontic treatment.²⁴ Further studies on their debridement in Abs are necessary.

Albuquerque et al. advocated that obturating such root canal systems requires good clinical skill along with a dental operating microscope with higher depth of focus. One technique proposed by Hermann and Hulsmann is called the "Squirt technique".^{4,26} In this technique, both ends of the root canals are obturated simultaneously by injection of thermoplasticized gutta percha, followed by back filling. However, this method may only work in high-level bifurcations. Warm gutta-percha condensation technique may help fill the Abs only when the bifurcation canals are fully cleaned. Although the obturations of apical ramifications with fillings were sometimes shown in the X-ray film, it could not indicate that they were completely filled with filling materials. Necrotic or infected issues might still be observed in the histopathological sections.²⁷ Therefore, the clinician need to keep in mind that effectively cleaning these areas should be prior to other procedures of root canal treatment.²⁷

Declaration of Competing Interest

The authors deny any conflicts of interest related to the present study.

Acknowledgments

The study was supported by the National Natural Science Foundation of China (grant No. 81771067).

References

1. Peiris R, Malwatte U, Abayakoon J, Wettasinghe A. Variations in the root form and root canal morphology of permanent mandibular first molars in a Sri Lankan population. *Anat Res Int* 2015;2015:803671.

2. de Oliveira SH, de Moraes LC, Faig-Leite H, Camargo SE, Camargo CH. In vitro incidence of root canal bifurcation in mandibular incisors by radiovisography. *J Appl Oral Sci* 2009; 17:234–9.
3. England Jr MC, Hartwell GR, Lance JR. Detection and treatment of multiple canals in mandibular premolars. *J Endod* 1991;17:174–8.
4. Albuquerque D, Kottoor J, Hammo M. Endodontic and clinical considerations in the management of variable anatomy in mandibular premolars: a literature review. *BioMed Res Int* 2014;2014:512574.
5. Yadav SS, Shah N, Naseem A, Roy TS, Sood S. Effect of “apical clearing” and “apical foramen widening” on apical ramifications and bacterial load in root canals. *Bull Tokyo Dent Coll* 2014;55:67–75.
6. De-Deus G, Arruda TE, Souza EM, et al. The ability of the Reciproc R25 instrument to reach the full root canal working length without a glide path. *Int Endod J* 2013;46:993–8.
7. Gunday M, Sazak H, Garip Y. A comparative study of three different root canal curvature measurement techniques and measuring the canal access angle in curved canals. *J Endod* 2005;31:796–8.
8. Yoshioka T, Villegas JC, Kobayashi C, Suda H. Radiographic evaluation of root canal multiplicity in mandibular first premolars. *J Endod* 2004;30:73–4.
9. Vertucci FJ. Root canal anatomy of the human permanent teeth. *Oral Surg Oral Med Oral Pathol* 1984;58:589–99.
10. Vertucci FJ. Root canal anatomy of the mandibular anterior teeth. *J Am Dent Assoc* 1974;89:369–71.
11. Peters OA, Arias A, Paque F. A micro-computed tomographic assessment of root canal preparation with a novel instrument, trushape, in mesial roots of mandibular molars. *J Endod* 2015; 41:1545–50.
12. Li D, Jiang S, Yin X, Chang JW, Ke J, Zhang C. Efficacy of needle, ultrasonic, and endoactivator irrigation and photon-induced photoacoustic streaming in removing calcium hydroxide from the main canal and isthmus: an *in vitro* micro-computed tomography and scanning electron microscopy study. *Photomed Laser Surg* 2015;33:330–7.
13. Gao X, Tay FR, Gutmann JL, Fan W, Xu T, Fan B. Micro-CT evaluation of apical delta morphologies in human teeth. *Sci Rep* 2016;6:36501.
14. Xu T, Tay FR, Gutmann JL, et al. Micro-computed tomography assessment of apical accessory canal morphologies. *J Endod* 2016;42:798–802.
15. Schneider SW. A comparison of canal preparations in straight and curved root canals. *Oral Surg Oral Med Oral Path* 1971;32: 271–5.
16. Rankine-Wilson RW, Henry P. The bifurcated root canal in lower anterior teeth. *J Am Dent Assoc* 1965;70:1162–5.
17. Ahmed HM, Dummer PMH. Advantages and applications of a new system for classifying roots and canal systems in research and clinical practice. *Eur Endod J* 2018;3:9–17.
18. Wu MK, Wesselink PR. A primary observation on the preparation and obturation of oval canals. *Int Endod J* 2001;34: 137–41.
19. Vertucci FJ, Gegauff A. Root-canal morphology of the maxillary 1ST premolar. *J Am Dent Assoc* 1979;99:194–8.
20. Sedgley CM, Lennan SL, Appelbe OK. Survival of *Enterococcus faecalis* in root canals ex vivo. *Int Endod J* 2005;38:735–42.
21. Coldero LG, McHugh S, MacKenzie D, Saunders WP. Reduction in intracanal bacteria during root canal preparation with and without apical enlargement. *Int Endod J* 2002;35:437–46.
22. Peters OA. Current challenges and concepts in the preparation of root canal systems: a review. *J Endod* 2004;30:559–67.
23. Cruz A, Vera J, Gascon G, Palafox-Sanchez CA, Amezcua O, Mercado G. Debris remaining in the apical third of root canals after chemomechanical preparation by using sodium hypochlorite and glyde: an in vivo study. *J Endod* 2014;40: 1419–23.
24. Vandrangi P. Evaluating penetration depth of treatment fluids into dentinal tubules using the GentleWave system. *Dentistry* 2016;6:366.
25. Siu C, Baumgartner JC. Comparison of the debridement efficacy of the EndoVac irrigation system and conventional needle root canal irrigation in vivo. *J Endod* 2010;36:1782–5.
26. Da Silva D, Endal U, Reynaud A, Portenier I, Orstavik D, Haapasalo M. A comparative study of lateral condensation, heat-softened gutta-percha, and a modified master cone heat-softened backfilling technique. *Int Endod J* 2002;35: 1005–11.
27. Ricucci D, Siqueira Jr JF. Fate of the tissue in lateral canals and apical ramifications in response to pathologic conditions and treatment procedures. *J Endod* 2010;36:1–15.