

Determination of Optimal Imaging Mode for Ultrasonographic Detection of Subdermal Contraceptive Rods: Comparison of Spatial Compound, Conventional, and Tissue Harmonic Imaging Methods

Sungjun Kim, MD, PhD¹, Kyung Seo, MD, PhD², Ho-Taek Song, MD, PhD³, Jin-Suck Suh, MD, PhD³, Choon-Sik Yoon, MD, PhD¹, Jeong Ah Ryu, MD, PhD⁴, Jeong Seon Park, MD, PhD⁵, Ah Hyun Kim, MD³, Ah Young Park, MD¹, Yaena Kim, MD¹

Departments of ¹Radiology and ²Obstetrics and Gynecology, Gangnam Severance Hospital, Yonsei University College of Medicine, Seoul 135-720, Korea; ³Department of Radiology and Research Institute of Radiological Science, Severance Hospital, Yonsei University College of Medicine, Seoul 120-752, Korea; ⁴Department of Radiology, Guri Hospital, Hanyang University College of Medicine, Guri 471-701, Korea; ⁵Department of Radiology, Hanyang University Hospital, Hanyang University College of Medicine, Seoul 133-792, Korea

Objective: To determine which mode of ultrasonography (US), among the conventional, spatial compound, and tissue-harmonic methods, exhibits the best performance for the detection of Implanon® with respect to generation of posterior acoustic shadowing (PAS).

Materials and Methods: A total of 21 patients, referred for localization of impalpable Implanon®, underwent US, using the three modes with default settings (i.e., wide focal zone). Representative transverse images of the rods, according to each mode for all patients, were obtained. The resulting 63 images were reviewed by four observers. The observers provided a confidence score for the presence of PAS, using a five-point scale ranging from 1 (definitely absent) to 5 (definitely present), with scores of 4 or 5 for PAS being considered as detection. The average scores of PAS, obtained from the three different modes for each observer, were compared using one-way repeated measure ANOVA. The detection rates were compared using a weighted least square method.

Results: Statistically, the tissue harmonic mode was significantly superior to the other two modes, when comparing the average scores of PAS for all observers ($p < 0.00-1$). The detection rate was also highest for the tissue harmonic mode ($p < 0.001$).

Conclusion: Tissue harmonic mode in uS appears to be the most suitable in detecting subdermal contraceptive implant rods.

Index terms: Ultrasonography; Implanon; Subdermal contraceptive; Spatial compound; Tissue harmonic; Wide focal zone

Received February 13, 2012; accepted after revision May 29, 2012.

This work was supported by a faculty research grant of Yonsei University College of Medicine for 2009 (No. 6-2009-0119).

Corresponding author: Choon-Sik Yoon, MD, PhD, Department of Radiology, Gangnam Severance Hospital, Yonsei University College of Medicine, 211 Eonju-ro, Gangnam-gu, Seoul 135-720, Korea.

• Tel: (822) 2019-3510 • Fax: (822) 3462-5472

• E-mail: yooncs58@yuhs.ac

This is an Open Access article distributed under the terms of the Creative Commons Attribution Non-Commercial License (<http://creativecommons.org/licenses/by-nc/3.0>) which permits unrestricted non-commercial use, distribution, and reproduction in any medium, provided the original work is properly cited.

INTRODUCTION

Implanon (Organon International Inc, Roseland, NJ, USA; OSS, The Netherlands) is an implantable, subdermal, rod-shaped contraceptive device, designed to provide a long-acting contraception for up to three years. It consists of an ethylene vinyl acetate copolymer core, which is a rubber-like plastic material, containing the selective progestin etonogestrel. The rod is 40 mm in length, and 2 mm in diameter (1). This non-biodegradable implant is inserted subdermally with a unique, preloaded disposable applicator

in the upper medial aspect of the non-dominant arm, and its removal should be performed after either the maximum duration of the device, or whenever required (2). When inserted properly at the superficial location, the Implanon rod is palpable and its removal is usually quick and easy, using the "pop out" technique via a small incision (1, 2). Imaging tools are used to confirm its presence/absence, and location when the implanted rod has migrated was too deeply inserted to be palpated, or even in cases of accidental non-insertion (3).

Ultrasonography (US) is known to be the most cost efficient and accurate tool, both for detection and removal guidance (1, 3, 4). With US, the entire length of the implant is visualized as a thin echogenic line in longitudinal scans, but it is easier to visualize the implant in transverse scans (5). With transverse scans, Implanon is visualized as a small echogenic spot, exhibiting a posterior acoustic shadowing (PAS) as its characteristics US feature of plastic foreign body; which is nonradiopaque (6, 7). However, Implanon is typically first localized by identifying the PAS, rather than by identifying the echogenic spot, which is the Implanon per se (1, 8).

Ultrasonography has also been used at our institution as the primary modality, when patients are referred for Implanon localization. However, while using an up-to-date US equipment for this purpose, we experienced some difficulty in the Implanon localization, due to a lack or deficiency of PAS when US is performed in a default mode, which consists of a spatial compound imaging with a wide focal zone (WFZ). As a result, we decided to determine the optimal US imaging mode for Implanon detection among the three currently available modes, namely, conventional (CV), spatial compound (SC), and tissue harmonic (TH) modes. Thus, the objective of our study was to determine the optimal US mode for the localization of non-palpable contraceptive implants, in terms of PAS.

MATERIALS AND METHODS

Patients

From March 2009 through February 2011, 21 consecutive female patients (mean age, 34.3 years; range, 26 to 46 years), who were referred to the radiology department for US localization of the non-palpable Implanon before removal, were enrolled in this study. In all of these cases, US was performed using three different US modes, namely, CV, SC, and TH. Each of these modes was utilized during

the study period, as it was uncertain which method would prove to be the most appropriate for the detection of Implanon rods. The institutional review board waived the requirement for informed consent for this retrospective study. For each enrolled patient, the following parameters were recorded by a radiology resident, who retrospectively reviewed the patient medical records: arm in which the Implanon was implanted; reason for removal; whether or not the Implanon was detected on US; reason(s) why the Implanon rod was not palpated, including migration out of the initial insertion site and deep insertion; depth of the implant measured at the more superficial tip in millimeters; whether or not the device was located in the muscle/neurovascular sheath; whether the removal was successful if the Implanon was detected on US. Demographic and clinical data were summarized as counts and percentages for categorical variables, and the means \pm standard deviation for continuous variables.

Ultrasonographic Examination

For all patients, US was performed by a radiologist with ten years of experience in musculoskeletal US, using a 5-12-MHz linear transducer with an iU22 scanner (Philips Medical Systems, Best, The Netherlands). Scanning was carried out using default settings without any manual modulation of the associated parameters, except for the use of a special image equalization algorithm (iSCAN, Philips Medical Systems, Best, The Netherlands) to produce a more uniform ultrasound image. The iU22 scanner provides a novel automatic control focusing algorithm (iFOCUS, Philips Medical System, Best, The Netherlands). The 'iFOCUS', i.e., 'WFZ' technique comprises an automatic focusing within the defined width of the focus at the scan area, and it has the

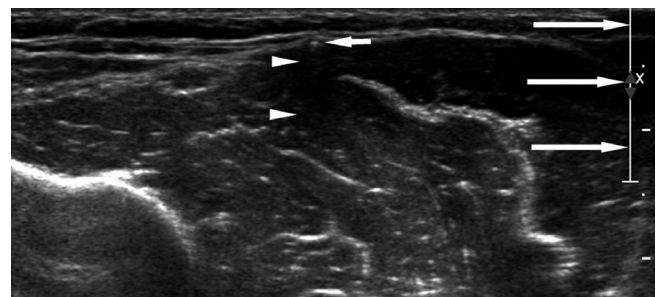


Fig. 1. Transverse ultrasonography image of Implanon device in conventional mode obtained from 32-year-old female patient. Echogenic spot (short arrow) indicates Implanon rod. Note unexpectedly ambiguous posterior acoustic shadowing (PAS) (arrowheads) cast posterior to Implanon. Linear bar seen on right side of image (long arrows) corresponds to width of focus depth, indicating that this image was obtained using wide focal zone.

added advantage of increasing a throughput by mitigating the work load of adjusting the focus for every scan. The WFZ covering the 'wide depth' was adopted as a preset default mode for the iU22 scanner, particularly for the superficial small part scan (Fig. 1). The default mode was not modulated during our US scan, and the focus width was sufficiently wide to cover the entire depth (from the skin surface to the substantially deeper layer of muscle), where the implant was expected to be located in all patients. The width of the focus was around 15 mm and the center of the focus was located approximately at the depth of the muscle fascia or of deep subcutaneous fat for all patients in the study.

During US scanning, patients were placed in the supine position. US was carried out along the medial aspect of the upper arm. Scanning was initiated from the site of the scars associated with the insertion or with the site of the attempted removal if they were identifiable. The optimal plane for detection of the Implanon is known to be the transverse plane, in which the Implanon is visualized as an echogenic spot, measuring approximately 2 mm in diameter and casting a PAS (Fig. 1) (5). Hence, the scanning of the arm was initially performed in the transverse plane because the Implanon is generally implanted along the long axis of the arm (Fig. 2) (9).

Images were obtained using all three imaging modes (CV, SC, and TH). Real-time SC imaging (Sono CT®) obtains multiple image slices from nine different viewing angles, and then combines them into a single compound image at real-time frame rates, while during the TH imaging; the beam is received at twice the transmitted frequency. The first imaging mode to be used and the order of the modes

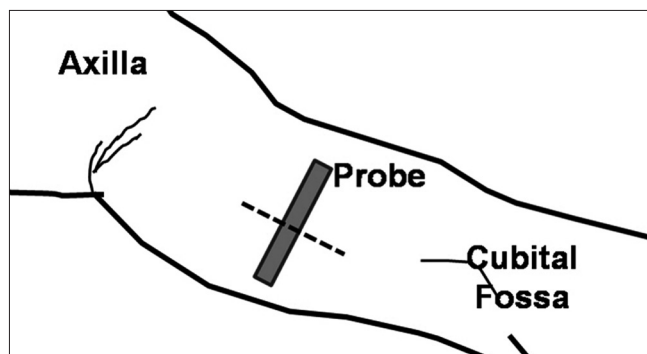


Fig. 2. Illustration of ultrasonography (US) examination of Implanon. US examination is performed in transverse plane with respect to Implanon device for ease of detection. Implanon is generally inserted at medial aspect of arm, along its long axis (dotted line). Hence, US probe (gray box) is initially placed at medial aspect of arm in respective transverse plane.

for image acquisition were randomly determined. When the Implanon was not detected within several minutes, US was carried out further by switching into the next mode. Once the Implanon was detected in a particular mode (e.g., CV), images were obtained at the site in the first mode, and then using the other two modes (e.g., SC and TH) without changing any parameters, including the imaging plane and focus (focal zone). A transverse image was obtained for each mode. The resultant transverse plane image with respect to the Implanon location was saved for each mode for each patient. The images obtained, using the three different modes, were saved in a picture archiving and communications system (Centricity 2.0; GE Health Care, Mt. Prospect, IL, USA). The images were de-identified, converted into image files in Digital Imaging and Communication in Medicine (DICOM) format, and randomly assigned to an identification number. In this way, patient information was kept confidential and evaluators were blinded to the imaging modes used for each image.

Ultrasonography examination was completed by placing a mark on the skin surface, where the proximal and distal tips of the Implanon were located, using a permanent marker for ease of removal. Removal was not performed during the US examination by a radiologist at our institution. A surgeon removed the implant, either by a US-guided percutaneous approach or by an open surgical approach, when percutaneous removal failed.

Image Review

A total of 63 images of the 21 patients were collected, using the three imaging modes (CV, SC, and TH). For interpretation of the US examination, the images were randomly divided into three sets, consisting of the same number of images and were independently reviewed by two experienced radiologists (O1 and O2; with 25 and 10 years of experience, respectively), and two novice third-year residents (O3 and O4), none of whom performed the US examination. The first two radiologists had experience in US detection of the Implanon, whereas, the resident trainees had none. Prior to the commencement of the first review session, the resident trainees were educated as to the imaging findings of the Implanon, using nine illustrative images obtained in the three different modes that were not included in the set of images to be reviewed. The three image sets were reviewed separately, at independent review sessions with two-month intervals, between each review session to minimize any bias attributable to previous

memory of the images. The image review was performed with an independent Digital Imaging and Communications in Medicine viewer (PiViewSTAR; Infinitt, Seoul, Korea). During each review session, the observers were asked to score the presence of PAS, using a five-point scale, as follows: 1) PAS definitely absent; 2) PAS probably absent; 3) PAS possibly present; 4) PAS probably present; 5) PAS definitely present.

Statistical Analysis

Scores for the presence of PAS in each mode for each observer are presented as the means \pm standard deviations. To compare the PAS generation among the modes, the mean scores of each mode were compared for each observer. Additionally, to determine whether the observers' experience affected the scores for the presence of PAS, the mean scores were compared between the experienced and novice observers for each mode, where the mean scores of each observer were separately compared. The average scores were compared using a one-way repeated measure ANOVA. When the null hypothesis, which proposed that none of the scores were significantly different, was rejected based on the results of the ANOVA, a post-multiple comparison *t* test, with Bonferroni correction, was used to determine whether the difference between the mean scores of interest were statistically significant (10).

As stated above, the Implanon is typically first localized by identifying the PAS. Hence, the scores of 4 or 5 for PAS were considered to be successful in the detection of Implanon. The detection rates (the number of images in which Implanon [i.e., PAS] was detected divided by the total number of images) were measured and recorded as percentages by mode for each observer. The weighted least square method was performed to compare the overall detection rates among the modes. Subsequent post-hoc analysis with the Bonferroni correction was performed in cases where the null hypothesis was rejected. We considered instances in which the identical scores were assigned by all observers as an accurate detection (11).

MedCalc software (version 11.6.1.0; Med-Calc Software, Mariakerke, Belgium) was used to compare the PAS scores between the modes. SAS 9.2 software (SAS Institute, Carey, NC, USA) was used to compare the detection rates among the modes (12). Differences were deemed significant for all statistical analyses when *p* values were less than 0.05.

Preliminary Qualitative Measure of the Correlation between PAS Clarity and Focus Modulation

A previous report demonstrated that CV imaging is able to clearly visualize PAS when the focus is adjusted at the depth of the Implanon location (8); however, PAS was not prominent in the CV imaging mode in our series, even though the Implanon was located within the range of focus. We speculated that this phenomenon is related to the use of WFZ. Thus, we investigated how WFZ, when the focus is set at the depth of the Implanon, affected PAS generation in each mode during the examination of the last enrolled patient, performed by a radiologist.

Images were obtained in each mode with the center of the focus located at the depth of the Implanon. The images were obtained with the focus set at the WFZ and at the 'single focus (SF)', for each mode. The PAS in each acquired image was retrospectively reviewed, and two experienced observers, in consensus, assessed whether PAS was affected by the width of the focus, in terms of its length and clarity.

RESULTS

Patient Data

The implants were inserted in the left arm of all 21 patients. The reason for the Implanon removal was reaching the maximum duration, in which the Implanon exhibits reliable efficacy (three years) in 14 patients (66.6%), intermenstrual bleeding in six patients (28.6%), and a desire for pregnancy in one patient (4.8%). Implanon was detected on US in all patients. The reasons for failure to palpate Implanon rods were deep insertion or weight gain in 18 patients (85.7%), and migration out of the insertion site in the remaining 3 patients (14.3%) (one, at the muscle/subfascial layer of axilla: one, at the muscle/subfascial layer 5 cm proximal to the insertion site; one, at the deep subcutaneous fat layer 6 cm proximal to the insertion site). The average depth of the more superficial tip of the implant measured on US was 4.9 ± 3.0 mm (range, 1.5 to 13 mm). On US, Implanon was located in the deep subcutaneous fat layer (four patients, 19.1%), at the muscle belly or subfascial layer (ten patients, 47.6%), or immediately adjacent to or within the neurovascular sheath (seven patients, 33.3%). Removal was successful for all patients.

Comparison of PAS Generation and Detection Rate Among Modes

In comparison of the mean PAS scores, assigned by the experienced observers (O1 and O2) among the imaging modes, the mean scores of the TH mode were higher than those of the other two modes ($p \leq 0.0001$) (Fig. 3). Additionally, the mean scores of the CV mode were significantly ($p < 0.03$) higher than those of the SC mode. In contrast, the mean PAS scores, assigned by the novice observers (O3 and O4) for the TH mode, were significantly ($p < 0.0001$) higher than those of the CV and SC modes, whereas, the mean scores of the CV and SC modes were not significantly different. The mean PAS scores of the TH mode were superior to those of the SC and CV modes, irrespective of the observer experience on US evaluation (Table 1). A comparison of the mean PAS scores between the observers, in terms of experience, revealed that the mean PAS scores did not differ significantly for any mode.

The detection rates for each mode based on the scores, assigned by each observer, are shown in Table 2. The comparison of the detection rates among the imaging modes, based on scores assigned by all observers combined,

resulted in the rejection of the null hypothesis. This suggested that at least two modes differed in terms of the detection rate. In the post-hoc analysis, the TH mode was found to be superior to the CV ($p < 0.0003$) and SC ($p = 0.0009$) modes, whereas the difference between the CV and SC modes was not statistically significant.

Preliminary Qualitative Measure of the Correlation between PAS Clarity and Focus Modulation

The comparison between the WFZ and SF, with the center of the focus fixed at the depth of the Implanon, indicated that the PAS in WFZ was significantly less than that in SF in the CV mode. The PAS did not differ significantly between the images with WFZ and those with SF in the SC and TH modes. The TH mode images exhibited a discrete and long PAS irrespective of the width of focus. The SC mode had an ambiguous PAS, irrespective of the width of focus (Fig. 4).

DISCUSSION

Investigations into the accuracy of US for the detection of the Implanon are rare. James et al. (3) reported that

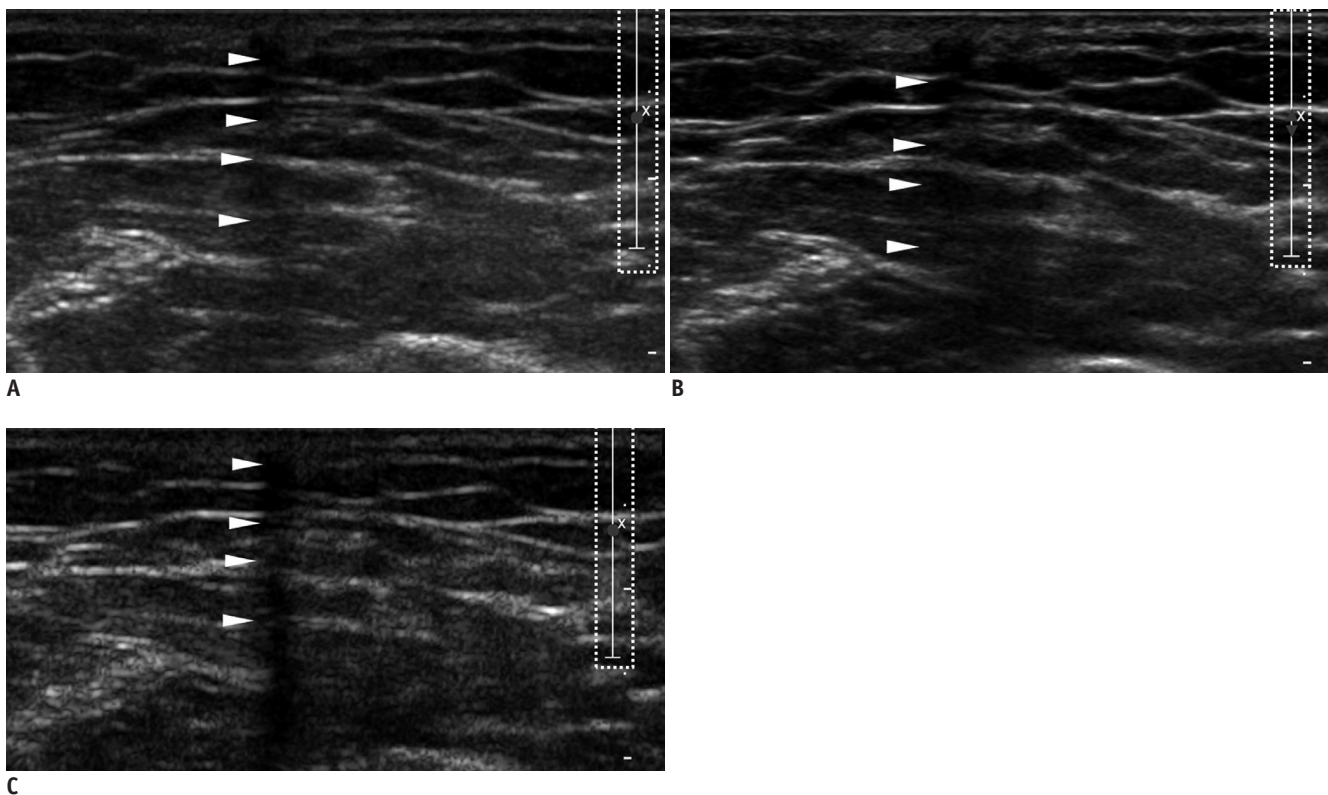


Fig. 3. Comparison of conventional (CV) (A), spatial compound (SC) (B) and tissue harmonic (TH) (C) modes in terms of posterior acoustic shadowing (PAS) generation in images obtained from 30-year-old female patient, using wide focal zone. PAS (arrowheads) appears discrete in TH mode (C), but is ambiguous or nearly absent in CV (A) and SC (B) modes (dotted boxes on right in images are markers denoting location and width of focus).

Table 1. Comparison of Average Posterior Acoustic Shadowing Scores between Imaging Modes for Each Observer

Observers	CV	SC	TH	P*		
				CV vs. SC	CV vs. TH	SC vs. TH
01 [†]	3.3 ± 0.9	2.6 ± 1.0	4.8 ± 0.4	0.0135	< 0.0001	< 0.0001
02 [†]	3.4 ± 1.1	2.6 ± 1.0	4.9 ± 0.4	0.0228	0.0001	< 0.0001
03 [‡]	3.0 ± 1.1	3.0 ± 0.8	4.9 ± 0.3	1.0000	< 0.0001	< 0.0001
04 [‡]	3.0 ± 0.9	2.8 ± 0.7	4.8 ± 0.4	1.0000	< 0.0001	< 0.0001

Note.— All average scores are presented as mean ± standard deviation. *p values indicate significance of difference between average scores of modes assigned by each observer in the post-multiple comparison t tests, [†]01 and 02 are experienced observers, [‡]03 and 04 are novice observers. CV = conventional mode, SC = spatial compound mode, TH = tissue harmonic mode

Table 2. Detection Rates for Each Mode (for Posterior Acoustic Shadowing) Based on Scores Assigned by Each Observer

Observers	CV	SC	TH
01*	47.6% (10/21)	14.3% (3/21)	100% (21/21)
02*	66.7% (14/21)	19.0% (4/21)	100% (21/21)
03 [†]	38.1% (8/21)	28.6% (6/21)	100% (21/21)
04 [†]	28.6% (6/21)	9.5% (2/21)	100% (21/21)

Note.— Detection rates are presented as percentages. Numbers in parentheses indicate number of images showing PAS/total number of images. *01 and 02 are experienced observers, [†]03 and 04 are novice observers. CV = conventional mode, SC = spatial compound mode, TH = tissue harmonic mode

the sensitivity and specificity of US with the use of high frequency transducers were both 100%. However, the mode and the focus settings that were used were not detailed in their article. Ironically, without careful consideration of the mode and focus settings by examiners according to the purpose of the examination, the accuracy of the Implanon detection can be poor, even with the use of up-to-date US equipment. Thus, we compared the PAS scores and the detection rates between CV, SC, and TH imaging modes, in order to determine which mode is best for the Implanon detection with respect to PAS generation. Our results indicated that the TH mode was superior to that of the CV and SC modes. The SC and TH modes are special imaging techniques designed to improve the diagnostic performance for soft tissue lesions (13). The results of the current study demonstrate that the knowledge of these modes, with respect to the mechanism of image generation, is critical to their appropriate use according to the purpose.

Spatial compound mode images show reduced levels of speckle, noise, clutter, and refractive shadows, and as a result, it can improve the contrast and margin conspicuity (13). Thus, SC mode is used as a default by many vendors that manufacture linear high frequency probes for US evaluation of the superficial lesions. However, the SC imaging technique manipulates echoes to ensure high-quality images. When compounding multiple images

together, real echoes will stand out, while the artifact echoes tend to be averaged out (14). This manipulation adversely affects the potentially useful artifacts, such as PAS in our study. Indeed, a previous report demonstrated that the SC mode is not recommended as a tool for the detection of the Implanon because the mode substantially minimizes PAS (8).

Unlike the SC mode, the CV mode was reported to be capable of generating PAS posterior to the Implanon in several previous reports when the focus was set at the Implanon depth (8, 15). In contrast to these reports, the CV mode was not significantly superior to the SC imaging mode, in terms of PAS generation in our study. We believe that this discrepant result is attributable to the preset US mode that was used with our belief that WFZ would enhance the operator's confidence by revealing all of the depths at which the implant could possibly be located. We do not completely understand the reason why PAS was not clear on the CV mode when WFZ was applied; however, we believe that this phenomenon was partially associated with the energy of the US beam at the Implanon location. Transducers focus and narrow the US beam to improve the lateral resolution. The depth at which the US beam is narrowest is defined as the 'focus' (13, 16), and as a result, the 'focus' is the point where the US energy is the highest. We speculate that the US energy in WFZ or with multiple

foci is not as strong as with a narrow, SF, and thus, PAS in WFZ is expected to be less distinct than in a SF image, due to the lower US energy at the depth of the Implanon. Thus, it is worthwhile for physicians or sonographers to assess the status of the 'focus' on US machines, i.e., wide/multiple focal zone versus SF, before performing US for Implanon detection.

The TH mode generated PAS that was discrete and

sufficiently long in all patients, whereas, the scores of the CV and SC modes varied according to both patients and modes. In addition, in the qualitative assessment of the influence of focus width modulation on PAS generation, only the TH mode generated PAS that was discrete and long enough to be detected, irrespective of the focus status. As stated above, the CV mode generated discrete PAS in only the in-focus imaging with the use of SF. This means

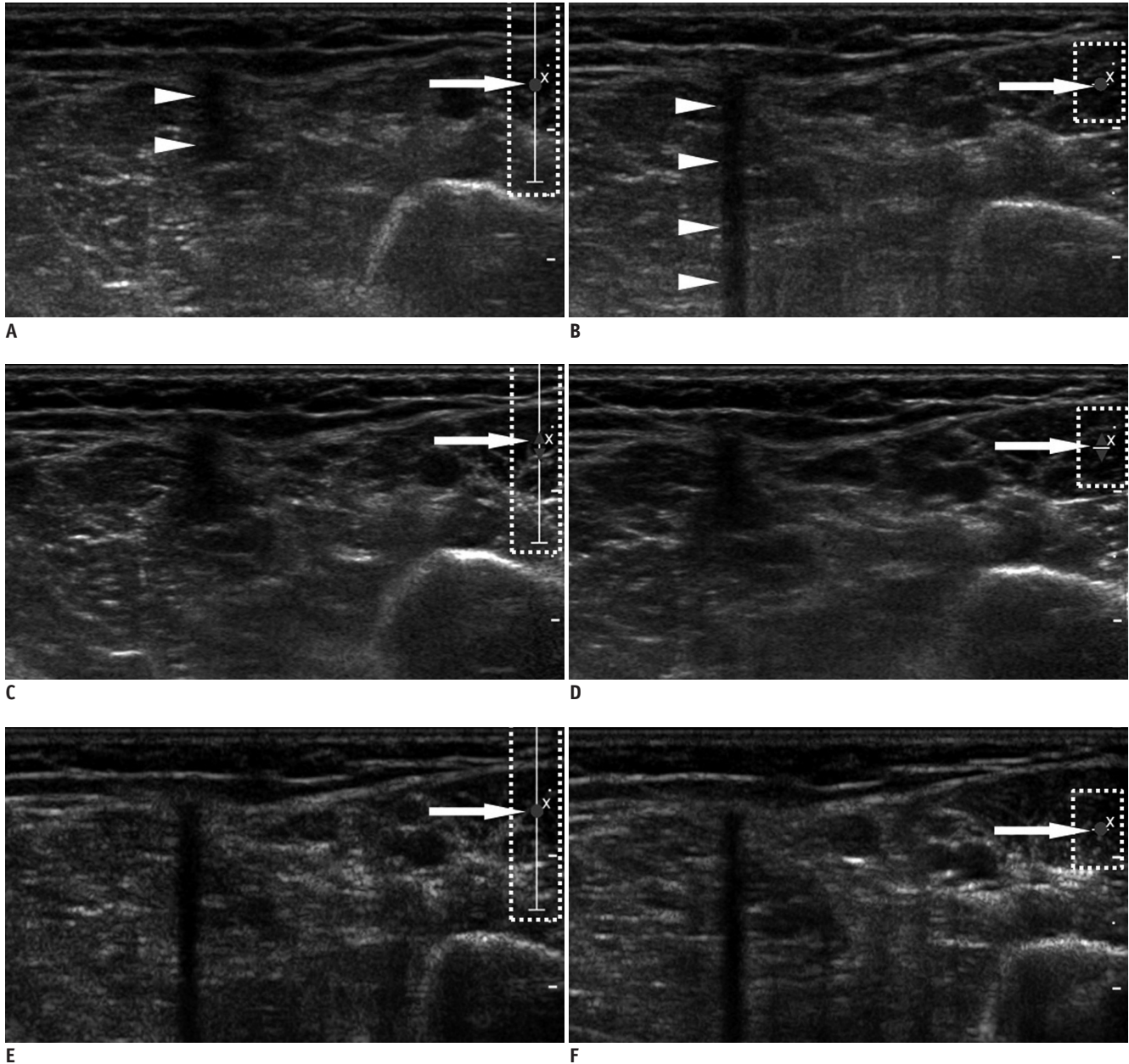


Fig. 4. Influence of focus width on posterior acoustic shadowing (PAS) generation tested with focus fixed at depth of Implanon. Images obtained from set wide focal zone (A, C, E) and from set single focus (B, D, F) are presented. In spatial compound (C, D) and tissue harmonic (E, F) modes, PAS does not appear to be significantly different between images obtained, using different focus widths. However, in conventional mode, length of PAS (arrowheads) was markedly shorter in image with wide focal zone (A) than in that with single focus (B) (dotted boxes on right in images are markers denoting location and width of focus. Arrows indicate center of focus).

that the Implanon located deeper than the focus might be missed when using the CV mode, even when SF is also used; which this possibility weakens the operator's confidence. Furthermore, a lack of confidence can sometimes be critical when the operator needs to search a wide range, including the entire arm and even the axilla where the implant can possibly be migrated. In our study, the Implanon was located at the muscle belly or subfascial layer in 47.6% of the subjects and immediately adjacent to the neurovascular bundle in 33.3% of the subjects. Additionally, the Implanon migrated away from the initial insertion site in three patients. Considering these findings, TH mode appeared to be optimal, and was in fact necessary for the Implanon detection because this mode is the least affected by the Implanon depth with respect to PAS generation. Subtle PAS in the fundamental (CV) mode is accentuated in the TH mode (17). This accentuation partially explains the better performance of the TH mode for PAS generation, irrespective to the focus modulation in our study. However, the reason PAS was less affected by the focus modulation in the TH mode, compared with that of the CV mode is unclear, and thus, should be studied in the future.

Several limitations of our study should be addressed. First, the retrospective study design precluded our ability to assess the real-time implant detection performance of the modes, including the time to detect and accuracy. This should be evaluated in the future studies; however we believe that findings from such studies would not be vastly different from our results, considering the superiority of the TH mode indicated by our observations. Second, we used machines from a single commercial vendor with a single transducer, and the effect of using different vendors with higher frequency transducers adopting similar modes and presets remain to be determined. Third, we qualitatively verified the effect of WFZ on the generation of PAS in only one case. The verification was necessary to explain the reason why PAS was not prominent on the CV mode, unlike the previous reports, and it should be further elucidated in more cases with the use of US machines from various vendors.

In conclusion, the TH mode was optimal for the detection of the Implanon devices because it is less affected by the implant depth or by the focus width. If the TH mode is not available, the CV mode can be used, but only if the focus is set at the expected implant depth.

REFERENCES

1. Shulman LP, Gabriel H. Management and localization strategies for the nonpalpable Implanon rod. *Contraception* 2006;73:325-330
2. Mascarenhas L. Insertion and removal of Implanon. *Contraception* 1998;58(6 Suppl):79S-83S
3. James P, Treneary J. Ultrasound localisation and removal of non-palpable Implanon implants. *Aust N Z J Obstet Gynaecol* 2006;46:225-228
4. Persaud T, Walling M, Geoghegan T, Buckley O, Stunell H, Torreggiani WC. Ultrasound-guided removal of Implanon devices. *Eur Radiol* 2008;18:2582-2585
5. McNeill G, Ward E, Halpenny D, Snow A, Torreggiani W. Ultrasound appearances of Implanon implanted contraceptive devices. *JBR-BTR* 2009;92:259-260
6. Horton LK, Jacobson JA, Powell A, Fessell DP, Hayes CW. Sonography and radiography of soft-tissue foreign bodies. *AJR Am J Roentgenol* 2001;176:1155-1159
7. Young AS, Shiels WE 2nd, Murakami JW, Coley BD, Hogan MJ. Self-embedding behavior: radiologic management of self-inserted soft-tissue foreign bodies. *Radiology* 2010;257:233-239
8. Gabriel H, Shulman L, Marko J, Nikolaidis P, Chirita V. Compound versus fundamental imaging in the detection of subdermal contraceptive implants. *J Ultrasound Med* 2007;26:355-359
9. Westerway SC, Picker R, Christie J. Implanon implant detection with ultrasound and magnetic resonance imaging. *Aust N Z J Obstet Gynaecol* 2003;43:346-350
10. Gönen M, Panageas KS, Larson SM. Statistical issues in analysis of diagnostic imaging experiments with multiple observations per patient. *Radiology* 2001;221:763-767
11. Agresti A. *Categorical data analysis*. Hoboken: John Wiley & Sons, 2002:481-629
12. Stokes ME, Davis CS, Koch GG. *Categorical Data Analysis Using the SAS System*, 2nd ed. Cary: SAS Institute Inc., 2000:430-437
13. Hangiandreou NJ. AAPM/RSNA physics tutorial for residents. Topics in US: B-mode US: basic concepts and new technology. *Radiographics* 2003;23:1019-1033.
14. Comstock C. *Ultrasound Equipment*. In: Bassett LW, Mahoney MC, Apple SK, D'Orsi CJ, eds. *Breast Imaging*, 1st ed. Philadelphia: Elsevier, 2011:146-152
15. Piessens SG, Palmer DC, Sampson AJ. Ultrasound localisation of non-palpable Implanon. *Aust N Z J Obstet Gynaecol* 2005;45:112-116
16. Lieu D. Ultrasound physics and instrumentation for pathologists. *Arch Pathol Lab Med* 2010;134:1541-1556
17. Desser TS, Jeffrey RB. Tissue harmonic imaging techniques: physical principles and clinical applications. *Semin Ultrasound CT MR* 2001;22:1-10