

PARACENTRAL ACUTE MIDDLE MACULOPATHY IN CENTRAL RETINAL VEIN OCCLUSION COMPLICATING AMYLOID LIGHT-CHAIN AMYLOIDOSIS

Maurizio B. Parodi, MD,* Alessandro Arrigo, MD,* Firuzeh Rajabian, MD,*
Francesco Tecilazich, MD,† Andrea Giustina, MD,† Francesco Bandello, MD,*
Lee M. Jampol, MD‡

Purpose: To describe a case of paracentral acute middle maculopathy associated with central retinal vein occlusion in a patient affected by amyloid light-chain amyloidosis.

Methods: One patient with confirmed diagnosis of amyloid light-chain amyloidosis, displaying paracentral acute middle maculopathy and central retinal vein occlusion, was recruited. The patient underwent complete ophthalmologic examination and multimodal imaging, including: fundus autofluorescence, fluorescein angiography, indocyanine green angiography, spectral-domain optical coherence tomography, and optical coherence tomography angiography.

Results: Fundus autofluorescence showed a ferning pattern, corresponding to linear hypofluorescence in late-phase indocyanine green angiography and delayed venous filling, detected by fluorescein angiography. Structural optical coherence tomography revealed a hyper-reflective line located in the outer plexiform layer, corresponding to the prominent middle limiting membrane, along with several placoid lesions. Optical coherence tomography angiography found that the superficial capillary plexus was preserved, whereas vessel density was reduced in both the deep capillary plexus and the choriocapillaris. After 1 year of follow-up, the patient achieved an almost complete morphological recovery.

Conclusion: Multimodal imaging described in depth the morphological features of a case of combined paracentral acute middle maculopathy and central retinal vein occlusion in a patient affected by amyloid light-chain amyloidosis.

RETINAL CASES & BRIEF REPORTS 16:543–546, 2022

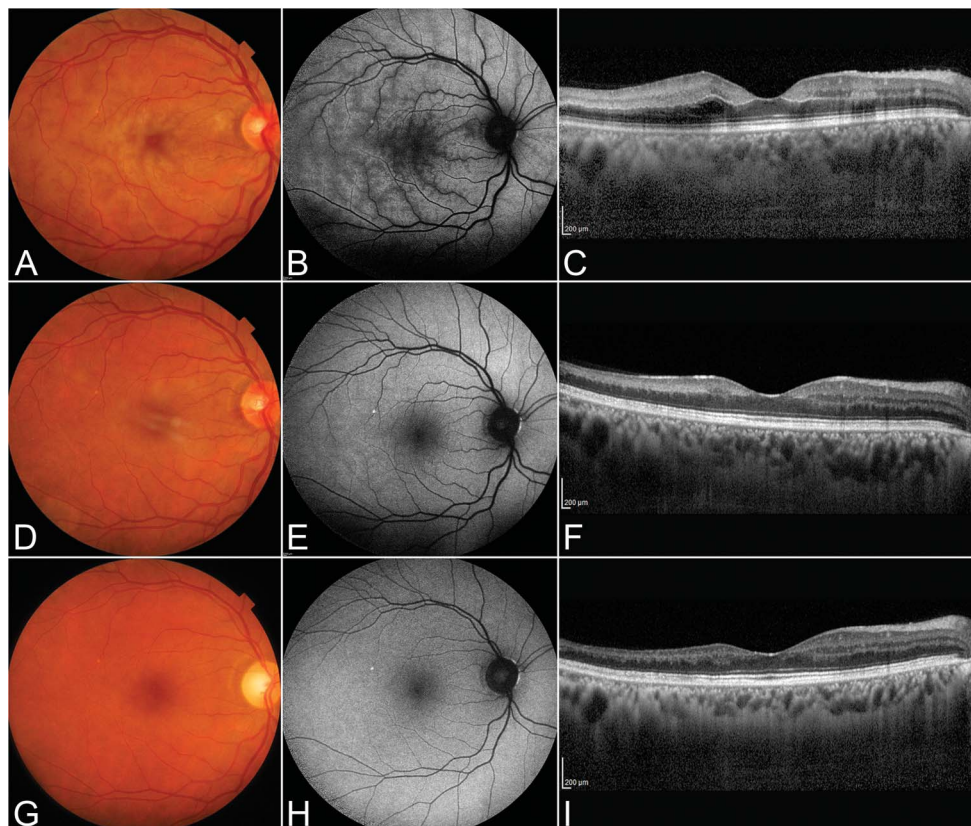
*From the *Ophthalmology Department, IRCCS San Raffaele Hospital, San Raffaele Vita-Salute University, Milan, Italy; †Division of Endocrinology, IRCCS San Raffaele Hospital, San Raffaele Vita-Salute University, Milan, Italy; and ‡Feinberg School of Medicine, Department of Ophthalmology, Northwestern University, Chicago, Illinois.*

Amyloidosis is the name for a group of rare, serious extracellular deposition diseases characterized by an abnormal accumulation of insoluble amyloid fibril, leading to architectural disruption and functional impairment of tissues or organs.¹ Immunoglobulin amyloid light-chain (AL) amyloidosis—the most common systemic amyloidosis—is caused by mis-

folded light chains produced by a B-cell clone and represents a possible complication of lymphoproliferative disorders, such as multiple myeloma; however, it has been previously shown that AL amyloidosis can also progress to multiple myeloma.^{2,3} It is noteworthy that AL amyloidosis is associated with increased risk of cardiovascular events and mortality.^{4,5}

Retinal vein occlusion (RVO) is a thrombotic obstruction of the retinal venous system, which may involve the central, hemi-central, or branch retinal veins.⁶ Paracentral acute middle maculopathy (PAMM) is a recently described condition affecting the middle layer of the retina in the parafoveal zone.^{7–9} It is known that PAMM may complicate various retinal vascular diseases,^{7–10} including venous system occlusion.

Fig. 1. Multimodal imaging over the follow-up. Baseline color fundus photography (A) showing vascular tortuosity and congestion, and retinal hemorrhages, along with grayish ill-defined linear lesions involving the entire posterior pole. The lesions correspond to hypoautofluorescence alterations (ferning pattern) detected on baseline FAF (B). Baseline structural OCT (C) shows a hyperreflective line located in the outer plexiform layer and several placoid, hyperreflective lesions crossing the inner retina, corresponding to the hypoautofluorescence lesions detected by FAF. After 2 months, a partial normalization of color fundus photography (D), FAF (E), and structural OCT (F) is visible. At the end of the follow-up, both color fundus photography (G) and FAF (H) reveal normalization, whereas an evident thinning of the inner retina is visible on structural OCT (I). Remarkably, the choroid was found to be thinner at the end of the follow-up, compared with previous images.



In this report, we describe a case of PAMM associated with central RVO (CRVO) in the context of AL amyloidosis.

Case Report

A 46-year-old man presented with acute visual loss in the right eye over a period of 1 week. His medical history was unremarkable except for the AL amyloidosis from which he had been suffering since 2016. After the diagnosis, the condition was treated with chemotherapy and corticosteroids; the diagnostic criteria for multiple myeloma¹¹ were not met. Furthermore, both laboratory and radiological investigations ruled out lymphoproliferative diseases, and the patient was observed over the next few years.

When he came to our attention, the best-corrected visual acuity was 20 of 100 in the right eye and 20 of 20 in the left. Anterior segment examination was unremarkable. Fundus evaluation of the right eye showed a modest degree of vascular tortuosity, a congested optic disk

with flame-shaped and dot hemorrhages, and grayish, ill-defined linear lesions surrounding the fovea. Fundus autofluorescence (FAF) and infrared imaging showed a corresponding ferning pattern (Figure 1). Fluorescein angiography revealed delayed venous filling and irregular capillary nonperfusion at the posterior pole, with limited leakage. Indocyanine green angiography (ICGA) clearly showed the location of capillary nonperfusion at the posterior pole, including late-phase linear hypofluorescence (Figure 2). No ICGA alterations were detected in the midextreme retinal periphery. Spectral-domain optical coherence tomography (OCT) showed a hyper-reflective line located in the outer plexiform layer corresponding to the prominent middle limiting membrane, along with several placoid, hyperreflective lesions crossing the inner retina, corresponding to the hyporefective lesions detectable on FAF and infrared imaging. A slight choroidal thickening was registered on OCT (395 μm). Enface OCT segmented at the level of the inner nuclear layer (INL) clearly showed perivenular PAMM and the ferning pattern, with incomplete reflectivity signal recovery registered at the end of the follow-up (Figure 3). Optical coherence tomography angiography (OCTA) revealed a reduced deep capillary plexus (DCP) vessel density. A similar vessel density reduction was also identified at the level of the choriocapillaris (CC) (Figure 4). All the examinations were normal in the fellow eye. The clinical and imaging findings were consistent with CRVO complicated by PAMM. A close follow-up was advised.

Two months later, the lesions gradually faded on all imaging modalities, with the exception of OCT and OCT angiography. In particular, on structural OCT, some hyper-reflective banding in the INL and a residual prominent middle limiting membrane were still recognizable. Optical coherence tomography angiography showed a persistence of decreased vessel density at the DCP, with partial CC recovery. The best-corrected visual acuity improved to 20 of 40.

The patient was regularly followed every 6 months. Two years later, the hyper-reflective lesions on structural OCT had completely

None of the authors has any financial/conflicting interests to disclose.

Reprint requests: Alessandro Arrigo, MD, Department of Ophthalmology, IRCCS Ospedale San Raffaele, University Vita-Salute, Via Olgettina 60, Milan, 20132 Italy; e-mail: alessandro.arrigo@hotmail.com

This is an open-access article distributed under the terms of the Creative Commons Attribution-Non Commercial-No Derivatives License 4.0 (CCBY-NC-ND), where it is permissible to download and share the work provided it is properly cited. The work cannot be changed in any way or used commercially without permission from the journal.

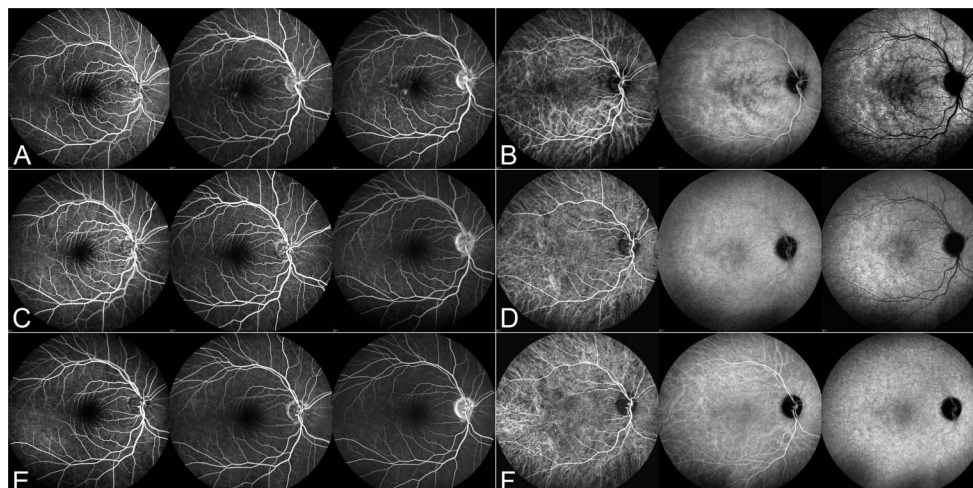


Fig. 2. Fluorescein and indocyanine green angiography changes over the follow-up. Baseline fluorescein angiography (A) reveals delayed venous filling and irregular capillary non-perfusion at the posterior pole, with limited leakage and sparse hyperfluorescent dots. Baseline ICGA (B) shows diffuse hypo-fluorescent alterations involving the entire posterior pole, which are more evident in the advanced phases. After 2 months, fluorescein angiography (C) shows no alterations, whereas ICGA (D) displays a partial recovery of the hypo-fluorescent signal. Both fluorescein angiography (E) and ICGA (F) turn out to be normal at the end of the follow-up.

disappeared, resulting in a thinning of INL, outer nuclear layer, inner plexiform layer, and outer plexiform layer. Choroidal thickness reduced to 226 μm . Optical coherence tomography angiography revealed the persistence of decreased vessel density at the level of the deep capillary plexus, with partial normalization of CC. A slight enlargement of the foveal avascular zone was visible on SCP. The last best-corrected visual acuity was 20 of 32. Interestingly, the patient was diagnosed with multiple myeloma in 2019 and underwent chemotherapy.

Discussion

Amyloid light-chain amyloidosis is a clonal non-proliferative disorder of plasma cells that can complicate lymphoproliferative conditions; more rarely, AL amyloidosis can progress to multiple myeloma.^{2,3}

The heart and kidneys are known to be the most frequently affected organs in AL amyloidosis, with 71% and 58% of patients affected, respectively.^{1,12} Indeed, cardiac involvement represents the major determinant of survival, as patients with advanced heart disease have a poor prognosis; conversely, patients with only kidney damage may survive many years.^{1,12}

Our case report describes a patient affected by PAMM in juvenile CRVO, in the context of AL amyloidosis.

Paracentral acute middle maculopathy has been described in association with local retinal vascular diseases, including CRVO, branch retinal artery occlusion/central retinal artery occlusion, diabetic retinopathy, hypertensive retinopathy, sickle cell retinopathy, Purtscher's retinopathy, along with some systemic conditions such as migraines, drug intake (amphetamines, caffeine, vasopressors, oral contraceptives), hypovolemia, orbital compression injury, upper respiratory infection, and post-H1N1 vaccine.⁵⁻⁷ Impaired blood flow due to AL amyloidosis may have acted as the most important pathogenic trigger in our patient, leading to the develop-

ment of CRVO and consequent ischemic damage at the level of the DCP (which is influenced by the venous outflow). The PAMM's preferential location close to the retinal veins supports this hypothesis. Paracentral acute middle maculopathy associated with CRVO is often hard to identify on biomicroscopy, but fundus autofluorescence can detect its typical ferning effect. In our case, structural OCT revealed a hyperreflective signal, extending from a prominent middle limiting membrane to the inner layers, which could be due to ischemic insult to the inner retina. Optical coherence tomography angiography showed a vessel density reduction in the deep capillary plexus, with a choriocapillaris defect, which could be secondary to a simple masking effect. During the follow-up, OCTA revealed a partial recovery of choriocapillaris density, but the deep capillary plexus showed persistent vessel density damage. Interestingly, a slight enlargement of the foveal avascular zone was visualized in the superficial capillary plexus. Both the damage at the level of the deep capillary plexus and the enlargement of the foveal avascular zone could account for the incomplete functional recovery.^{8,9} With respect to CC involvement, our OCTA findings are

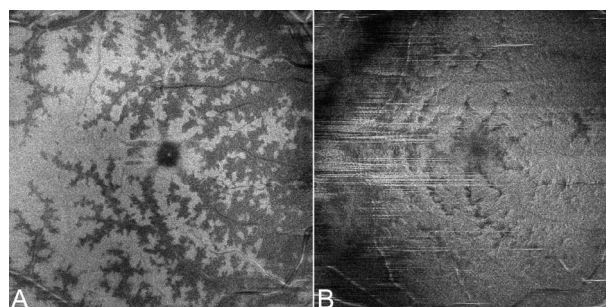
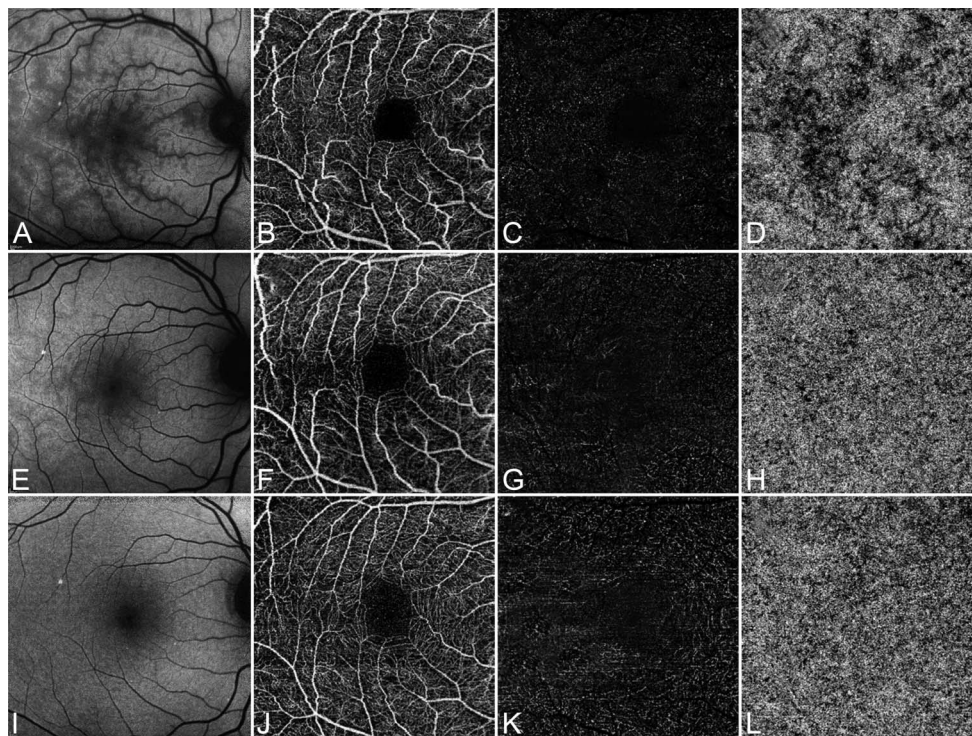


Fig. 3. Enface OCT segmented at the level of the INL clearly shows the perivenular PAMM and the ferning pattern in the acute phase of the disease (A). This imaging modality was able to detect progressive changes of the INL signal, with a remarkable, although incomplete, reflectivity signal recovery registered at the end of the follow-up (B).

Fig. 4. Optical coherence tomography angiography changes over the follow-up. Baseline FAF (A) details the involvement of the macular region, with almost preserved SCP (B), completely absent DCP (C), and diffuse alterations at the level of the CC (D). Partial FAF normalization was observed after 2 months (E), with unremarkable changes of SCP (F), and incomplete recovery at the level of DCP (G) and CC (H). At the end of the follow-up, FAF shows normalization (I), as well as SCP (J), DCP (K), and CC (L). Remarkably, DCP proved to be more rarefied in the temporal region, where structural OCT showed a residual inner retinal thinning (Figure 2). SCP, superficial capillary plexus.



in line with a previous investigation describing diffuse alterations of the CC band on structural OCT, probably secondary to choroidal depositions.¹³ The AL amyloidosis depositions at the level of the choroid might justify the impairment of the CC plexus, with consequent perfusion restoration after the resolution of the acute phase of the disease. Furthermore, CC impairment in the acute phase might also be the consequence of increased choroidal congestion leading to alterations of the pressure gradient conducting the blood flow through the choroidal/choriocapillaris interface.

In conclusion, our case demonstrates that CRVO associated with PAMM can complicate AL amyloidosis. Optical coherence tomography angiography nicely highlights the vascular damage, especially at the level of DCP.

Key words: paracentral acute middle maculopathy, central retinal vein occlusion, AL-amyloidosis, multimodal imaging.

References

- Wechalekar AD, Gillmore JD, Hawkins PN. Systemic amyloidosis. *Lancet* 2016;387:2641–2654.
- Rajkumar SV, Gertz MA, Kyle RA. Primary systemic amyloidosis with delayed progression to multiple myeloma. *Cancer* 1998;82:1501–1505.
- Ayabe T, Maekawa I, Ashida T, et al. A case of gastric amyloidosis developing into Bence-Jones type multiple myeloma, treated effectively by cyclo-VAMP chemotherapy. *Gan To Kagaku Ryoho* 1993;20:2399–2403.
- Vaxman I, Gertz M. Recent advances in the diagnosis, risk stratification, and management of systemic light-chain amyloidosis. *Acta Haematol* 2019;141:93–106.
- Kastritis E, Dimopoulos MA. Recent advances in the management of AL amyloidosis. *Br J Haematol* 2016;172:170–186.
- Sivaprasad S, Amoaku WM, Hykin P. RVO guideline group the royal college of ophthalmologists guidelines on retinal vein occlusions: executive summary. *Eye (Lond)* 2015;29:1633–1638.
- Chen X, Rahimy E, Sergott RC, et al. Spectrum of retinal vascular diseases associated with paracentral acute middle maculopathy. *Am J Ophthalmol* 2015;160:26–34.e1.
- Ghasemi Falavarjani K, Phasukkijwatana N, Freund KB, et al. En face optical coherence tomography analysis to assess the spectrum of perivenular ischemia and paracentral acute middle maculopathy in retinal vein occlusion. *Am J Ophthalmol* 2017;177:131–138.
- Phasukkijwatana N, Rahimi M, Iafe N, Sarraf D. Central retinal vein occlusion and paracentral acute middle maculopathy diagnosed with en face optical coherence tomography. *Ophthalmic Surg Lasers Imag Retina* 2016;47:862–864.
- Casalino G, Williams M, McAvoy C, et al. Optical coherence tomography angiography in paracentral acute middle maculopathy secondary to central retinal vein occlusion. *Eye (Lond)* 2016;30:888–893.
- Rajkumar SV. Myeloma today: disease definitions and treatment advances. *Am J Hematol* 2016;91:90–100.
- Gillmore JD, Hawkins PN. Pathophysiology and treatment of systemic amyloidosis. *Nat Rev Nephrol* 2013;9:574–586.
- Roybal CN, Sanfilippo CJ, Nazari H, et al. Multimodal imaging of the retina and choroid in systemic amyloidosis. *Retin Cases Brief Rep* 2015;9:339–346.