



Since January 2020 Elsevier has created a COVID-19 resource centre with free information in English and Mandarin on the novel coronavirus COVID-19. The COVID-19 resource centre is hosted on Elsevier Connect, the company's public news and information website.

Elsevier hereby grants permission to make all its COVID-19-related research that is available on the COVID-19 resource centre - including this research content - immediately available in PubMed Central and other publicly funded repositories, such as the WHO COVID database with rights for unrestricted research re-use and analyses in any form or by any means with acknowledgement of the original source. These permissions are granted for free by Elsevier for as long as the COVID-19 resource centre remains active.



Case report

Fatal pneumonia and viremia due to human parainfluenza virus type 1 in a patient with adult T-cell leukemia–lymphoma treated with mogamulizumab



Keita Tamaki ^a, Takeshi Kinjo ^b, Hajime Aoyama ^c, Takeaki Tomoyose ^a,
Sawako Nakachi ^{a,d}, Taeko Hanashiro ^a, Natsuki Shimabukuro ^{a,d}, Iori Tedokon ^a,
Kazuho Morichika ^a, Yukiko Nishi ^a, Naoya Taira ^e, Jiro Fujita ^b, Naoki Yoshimi ^c,
Takuya Fukushima ^f, Hiroaki Masuzaki ^{a,*}

^a Division of Endocrinology, Diabetes and Metabolism, Hematology and Rheumatology, Department of Medicine, Graduate School of Medicine, University of the Ryukyus, Japan

^b Department of Infectious Diseases, Respiratory and Digestive Medicine, Faculty of Medicine, University of the Ryukyus, Japan

^c Department of Pathology and Oncology, Graduate School of Medicine, University of the Ryukyus, Japan

^d Bone Marrow Transplantation Center, Ryukyu University Hospital, Japan

^e Department of Internal Medicine, Heartlife Hospital, Japan

^f Laboratory of Immunohematology, School of Health Sciences, Faculty of Medicine, University of the Ryukyus, Japan

ARTICLE INFO

Article history:

Received 15 April 2015

Received in revised form

16 June 2015

Accepted 1 July 2015

Available online 10 July 2015

Keywords:

Parainfluenza virus type 1

Viremia

Mogamulizumab

Adult T-cell leukemia–lymphoma

Viral pneumonia

ABSTRACT

We report a case of fatal pneumonia and viremia due to human parainfluenza virus type 1 (HPIV-1) in a 65-year-old male patient with adult T-cell leukemia–lymphoma (ATL) treated with mogamulizumab, a brand-new therapeutic agent for ATL. To our knowledge, this is the first report describing viremia due to HPIV-1. After administering mogamulizumab, lymphocyte count in the blood was drastically decreased and the patient suffered from complicated infections including gram-negative bacterial sepsis, cytomegalovirus antigenemia and aspergillosis. Although these infections were successfully controlled by broad spectrum antimicrobial therapy, patchy ground-glass opacities in the both lungs were gradually worsened. He finally died due to acute respiratory failure. Since findings of the chest CT was consistent with typical patterns of viral pneumonia, we screened major respiratory viruses in the peripheral blood with multiplex PCR, and it turned out that RNA of HPIV-1 was positive. Although ATL cells were not detected in the autopsied lungs and a variety of other tissues, cytoplasmic inclusion bodies, which are commonly observed in RNA viral infection, were abundantly observed in the autopsied lung tissue. These findings suggest that mogamulizumab accomplished complete remission of ATL, while the chemotherapy-induced prolonged lymphopenia caused fatal pneumonia and viremia due to HPIV-1. As it has been well recognized that community respiratory viruses including HPIV-1 often cause fatal pneumonia in patients with leukemia, but also there is no specific treatment for HPIV-1, we have to enforce standard precautions especially when we treat leukemic patients with intensively immunosuppressive agents such as mogamulizumab.

© 2015, Japanese Society of Chemotherapy and The Japanese Association for Infectious Diseases.

Published by Elsevier Ltd. All rights reserved.

1. Introduction

Adult T-cell leukemia–lymphoma (ATL) is a kind of peripheral T-cell lymphoma caused by human T-cell lymphotropic virus type 1 (HTLV-1) [1]. It is classified into four categories (acute, lymphoma, chronic, and smoldering types) depending on clinical features [2]. ATL is often resistant to chemotherapies, thus resulting in poor prognosis [3]. Since ATL *per se* induces severe impairment of

* Corresponding author. Division of Endocrinology, Diabetes and Metabolism, Hematology and Rheumatology (Second Department of Medicine), Graduate School of Medicine, University of the Ryukyus, 207 Uehara, Nishihara, Okinawa 903-0215, Japan. Tel.: +81 98 895 1146; fax: +81 98 895 1415.

E-mail address: hiroaki@med.u-ryukyu.ac.jp (H. Masuzaki).

cellular immunity, ATL patients are susceptible to opportunistic infections by cytomegalovirus (CMV), candida, *Pneumocystis jirovecii*, and *Strongyloides stercoralis* [4]. Mogamulizumab is a promising, brand-new therapeutic option for ATL. This agent binds C–C chemokine receptor 4 (CCR4) protein abundantly expressed in membrane surface of ATL cells, thereby activating natural killer cells in a manner of antibody-dependent cellular cytotoxicity [5]. In patients treated with mogamulizumab, median progression-free survival and overall survival intervals were 5.2 and 13.7 months, respectively [5]. On the other hand, its profile of robust cytotoxicity would be problematic in some cases. In fact, it has been suggested that mogamulizumab increases the risk of reactivation of CMV and hepatitis B virus [6,7].

Community respiratory viruses (CRVs) such as human rhinovirus and parainfluenza virus cause a common cold in healthy subjects. However, these viruses often cause severe pneumonia in patients with leukemia and those undergoing hematopoietic stem cell transplantation (HSCT) mainly through decreased T cell responses [8–10].

Here we report a case of fatal pneumonia and viremia due to human parainfluenza virus type 1 (HPIV-1) in a 65-year-old male patient with adult T-cell leukemia–lymphoma (ATL) treated with mogamulizumab.

2. Case report

A 65-years-old male patient was diagnosed as having an acute type of ATL after eleven years of chronic phase, because the number of white blood cells (WBC) and lactate dehydrogenase (LDH) in the peripheral blood were markedly increased to 43,700/ μL and 700 IU/L, respectively. Therefore, combined regimens with VCAP (vincristine, cyclophosphamide, doxorubicin, and prednisone), AMP (doxorubicin, ranimustine, and prednisone), and VECP (vindesine, etoposide, carboplatin, and prednisone) were started as an

induction chemotherapy. Soon after the third course of VCAP–AMP–VECP therapies were finished, the number of circulating lymphocytes and ATL cells, LDH and soluble interleukin-2 receptor (sIL-2R) were unfortunately increased rapidly, suggesting that his status was turned to refractory phase.

We therefore introduced mogamulizumab at the dosage of 1 mg/kg per week as the salvage therapy based on the finding that positive ratio of the CCR4 antigen in ATL cells was 97%. Before the treatment, the number of neutrophils, lymphocytes, and ATL cells in the peripheral blood was 2849/ μL , 10,780/ μL , and 847/ μL , respectively. On day 2 after induction of mogamulizumab, ATL cells disappeared in the peripheral blood, and the number of lymphocytes was rapidly decreased to 460/ μL , accompanied by the prolongation of severe lymphopenia (grade 3–4) (Fig. 1). Despite prophylactic medication had been administered with levofloxacin (LVFX), itraconazole (ITCZ), sulfamethoxazole/trimethoprim (ST) and acyclovir (ACV), he suffered from infectious complications including CMV antigenemia, gram-negative bacterial sepsis, and aspergillosis during the clinical course. Although these infections were well controlled by the broad spectrum antimicrobial treatment, multiple patchy ground-glass opacities in bilateral lungs, an atypical pattern of bacterial pneumonia, were appeared and gradually worsened. Due to acute respiratory failure, he died on day 48 (Figs. 1 and 2). Since chest CT showed typical patterns of viral pneumonia (Fig. 2), the peripheral blood was collected premortally and examined with multiplex PCR kit (Seeplex RV15 OneStep ACE Detection, Seegene, South Korea), which can screen most CRVs including influenza virus A/B, human adenovirus, coronavirus, parainfluenza virus 1/2/3, rhinovirus A/B/C, respiratory syncytial (RS) virus A/B, bocavirus 1/2/3/4, metapneumovirus, and enterovirus [11]. Consequently, RNA of HPIV-1 was detected in the blood and we diagnosed viremia due to HPIV-1.

In the autopsied lungs, cytoplasmic inclusion bodies and multinucleated syncytial giant cells were abundantly observed

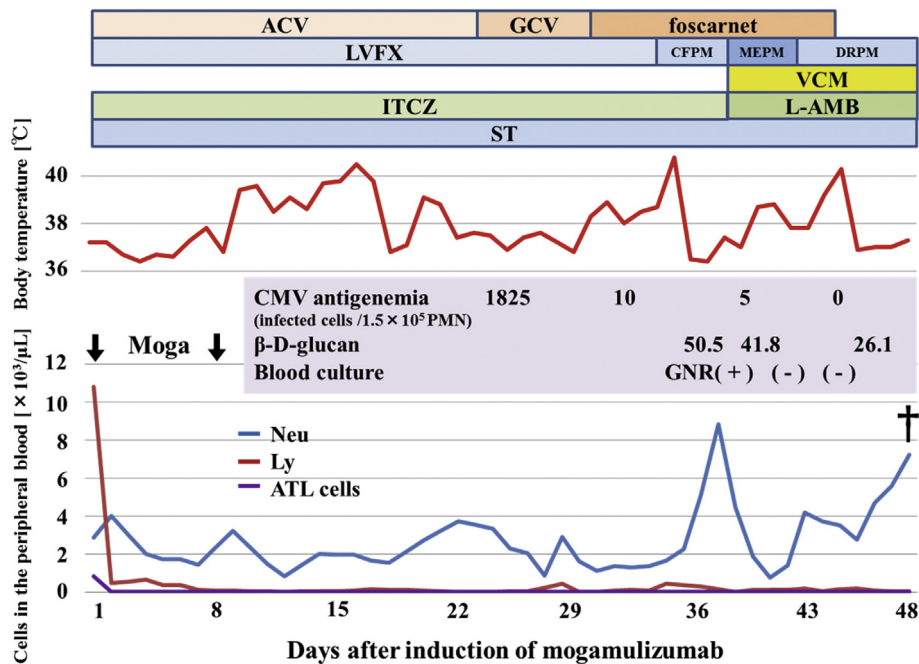


Fig. 1. Clinical course. After administration of mogamulizumab, ATL cells disappeared in the peripheral blood, accompanied by severe lymphopenia (grade 3–4). Although cytomegalovirus antigenemia, gram-negative bacterial sepsis and fungal infection were well controlled by multiple antimicrobial agents, his respiratory status was worsened and finally, he died of respiratory failure on day 48. Abbreviations: Moga: mogamulizumab, ACV: acyclovir, GCV: ganciclovir, LVFX: levofloxacin, CFPM: cefepime, MEPM: meropenem, DRPM: doripenem, VCM: vancomycin, ITCZ: itraconazole, L-AMB: liposomal amphotericin B, ST: sulfamethoxazole/trimethoprim, Neu: neutrophils, Ly: lymphocytes, GNR: gram-negative rod, PMN: polymorphonuclear leukocytes.

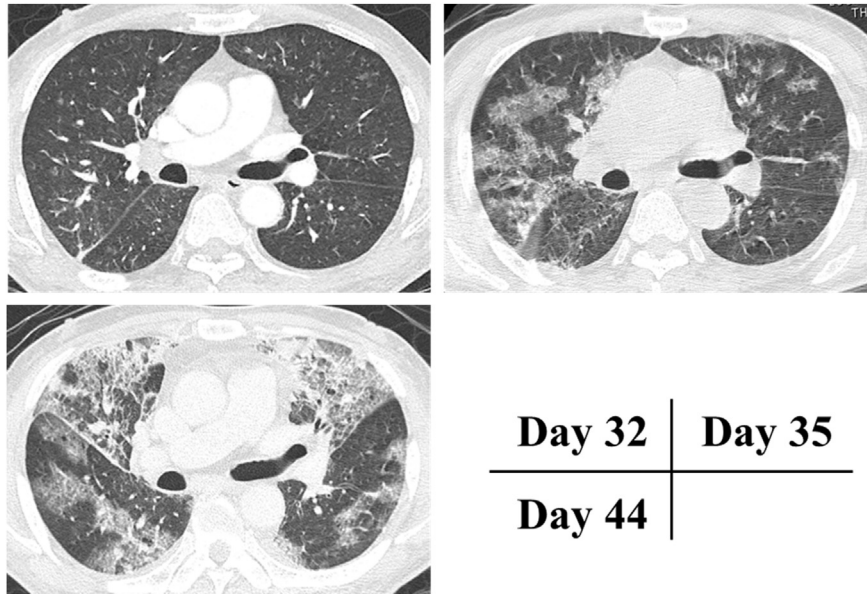


Fig. 2. Representative images of chest CT. Small centrilobular nodules suggesting bronchiolitis were observed on day 32. Multiple patchy ground-glass opacities were appeared in bilateral lungs on day 35, and these shadows were worsened on day 44.

(Fig. 3). These findings are commonly observed in viral pneumonia and especially, the former finding strongly suggests RNA viral infection. Also, hyaline membrane formation reflecting diffuse alveolar damage was observed in the lung (Fig. 3). On the other hand, neutrophilic infiltration and microorganisms including

bacteria and fungi were not observed. Also, CCR4 antigen-positive ATL cells were not detected at all in the lung and a variety of tissues, indicating that his ATL status was complete remission. Taken together, we finally diagnosed that the cause of death was severe pneumonia due to HPIV-1 infection.

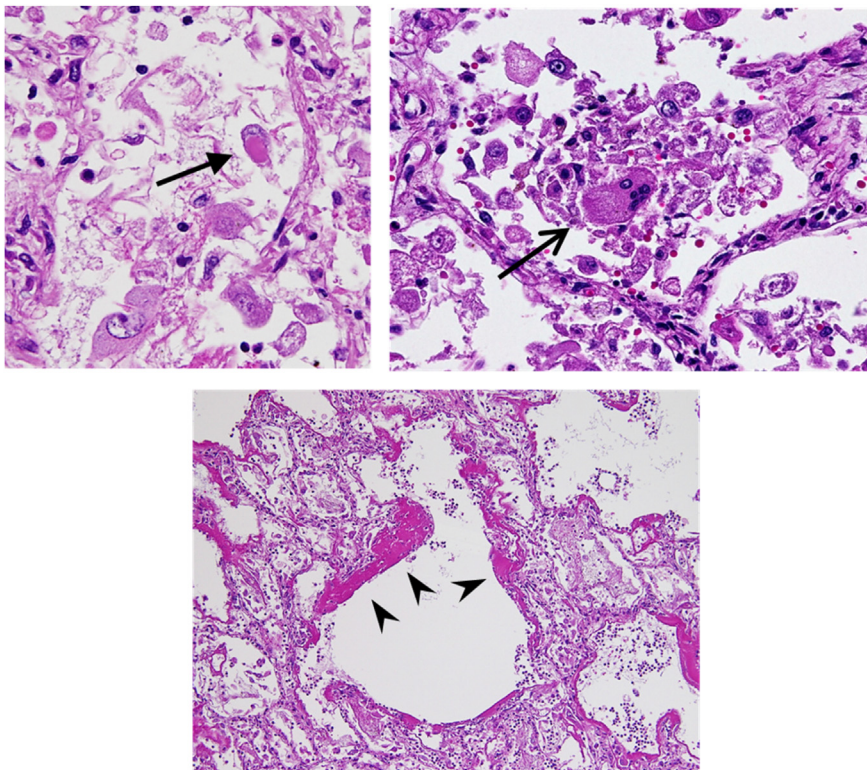


Fig. 3. Hematoxylin-eosin (HE) staining of the autopsied lung. HE staining of the autopsied lung tissue showed cytoplasmic inclusion bodies (↔), multinucleated syncytial giant cells (→), and hyaline membrane changes suggesting diffuse alveolar damage were observed (▶).

3. Discussion

We herein reported a case of fatal pneumonia and viremia due to HPIV-1 in a patient with ATL treated with mogamulizumab. There is only one report showing human parainfluenza virus type 2 (HPIV-2) viremia in a patient with acute myocarditis [12]. To our knowledge, this case is the first report documenting viremia due to HPIV-1.

CRVs are widely known as causative pathogens of upper respiratory tract infection (URTI) in healthy subjects. However, CRVs have also been recognized to cause lower respiratory tract infection (LRTI) with high mortality rate in patients with leukemia or recipients of HSCT [8,9,13–16]. LRTI due to HPIV occurred in 13%–43% in patients with leukemia and HSCT recipients, and its mortality rate was 12–50% [15]. The most important risk factor for progression to LRTI is lymphopenia. Although the thresholds vary according to studies, lymphocyte count less than 200/μL is accepted as the guideline [8,13]. In the present case, prolongation of severe lymphopenia less than 200/μL was considered as the possible main cause to develop fatal pneumonia and viremia due to HPIV-1.

Chest CT images may help to differentiate between bacterial and viral pneumonia. Generally, interstitial infiltrates including multifocal distribution of ground-glass opacities suggest viral pneumonia [17–19]. Regarding HPIV pneumonia, a recent study showed that tree-in-bud opacities reflecting bronchiolitis were the most common finding (67%) followed by bronchial wall thickening (38%) and ground-glass opacities (38%) [20]. Although the typical tree-in-bud opacities were not observed in the present case, centrilobular nodules suggesting bronchiolitis were observed on day 32, and the findings were worsened to diffuse patchy ground-glass opacities over the clinical course (Fig. 2). Thus, CT images observed in this patient were consistent with the previous report of HPIV pneumonia.

Ideally, direct detection of virus from the lung is warranted to diagnose viral pneumonia. Both immunostaining with anti-HPIV-1 antibodies and detection of HPIV-1 in the extraction liquid from lung tissue were attempted. However, it was technically difficult to detect HPIV-1 in the lung because RNA is generally unstable and long-term fixation with formalin and paraffin should be cruel condition for RNA virus including HPIV-1. We finally diagnosed HPIV-1 pneumonia based on a line of evidence as listed below; 1) HPIV-1 was detected in the blood, 2) CT images were consistent with viral pneumonia, and 3) pathological findings suggested RNA viral infection in the lung.

Undoubtedly, mogamulizumab is a promising agent for the treatment of refractory ATL. However, its robust cytotoxicity may provoke life-threatening opportunistic infections as observed in the present case. Although some reports showed ribavirin therapy with or without intravenous immunoglobulin (IVIG) was effective for the treatment of HPIV infection [9], there is no established antiviral therapy for the treatment of HPIV infection. In this context, standard precaution is the most effective countermeasure to prevent the infection and spread of HPIV [8,9].

In conclusion, we reported a case of fatal pneumonia and viremia due to HPIV-1 in a patient with ATL treated with mogamulizumab. The current case suggested that prolonged severe lymphopenia induced by mogamulizumab was most likely to let the patient susceptible to HPIV-1 infection.

Conflict of interest

None.

Acknowledgments

This work was supported in part by the Takeda Science Foundation (Specified Research Grant), the Metabolic Syndrome Foundation and the project “Establishing a research hub toward the development of an intellectual cluster in Okinawa Prefecture, Japan.” We thank M. Hirata, I. Asato, C. Noguchi, M. Shimoji and Y. Kuniyoshi for excellent secretarial assistance.

References

- [1] Uchiyama T, Yodoi J, Sagawa K, Takatsuki K, Uchino H. Adult T-cell leukemia: clinical and hematologic features of 16 cases. *Blood* 1977;50:481–92.
- [2] Shimoyama M. Diagnostic criteria and classification of clinical subtypes of adult T-cell leukaemia-lymphoma. A report from the Lymphoma Study Group (1984–87). *Br J Haematol* 1991;79:428–37.
- [3] Tsukasaki K, Hermine O, Bazarbachi A, Ratner L, Ramos JC, Harrington Jr W, et al. Definition, prognostic factors, treatment, and response criteria of adult T-cell leukemia-lymphoma: a proposal from an international consensus meeting. *J Clin Oncol* 2009;27:453–9.
- [4] Ishitsuka K, Tamura K. Human T-cell leukemia virus type I and adult T-cell leukemia-lymphoma. *Lancet Oncol* 2014;15:e517–26.
- [5] Ishida T, Joh T, Uike N, Yamamoto K, Utsunomiya A, Yoshida S, et al. Defucosylated anti-CCR4 monoclonal antibody (KW-0761) for relapsed adult T-cell leukemia-lymphoma: a multicenter phase II study. *J Clin Oncol* 2012;30:837–42.
- [6] Ishida T, Jo T, Takemoto S, Suzushima H, Uozumi K, Yamamoto K, et al. Dose-intensified chemotherapy alone or in combination with mogamulizumab in newly diagnosed aggressive adult T-cell leukemia-lymphoma: a randomized phase II study. *Br J Haematol* 2015;169:672–82.
- [7] Nakano N, Kusumoto S, Tanaka Y, Ishida T, Takeuchi S, Takatsuka Y, et al. Reactivation of hepatitis B virus in a patient with adult T-cell leukemia-lymphoma receiving the anti-CC chemokine receptor 4 antibody mogamulizumab. *Hepatology* 2014;44:354–7.
- [8] Hirsch HH, Martino R, Ward KN, Boeckh M, Einsele H, Ljungman P. Fourth European Conference on Infections in Leukaemia (ECL-4): guidelines for diagnosis and treatment of human respiratory syncytial virus, parainfluenza virus, metapneumovirus, rhinovirus, and coronavirus. *Clin Infect Dis* 2013;56:258–66.
- [9] Shah DP, Ghantaji SS, Mulanovich VE, Ariza-Heredia EJ, Chemaly RF. Management of respiratory viral infections in hematopoietic cell transplant recipients. *Am J Blood Res* 2012;2:203–18.
- [10] Duncan MD, Wilkes DS. Transplant-related immunosuppression: a review of immunosuppression and pulmonary infection. *Proc Am Thorac Soc* 2005;2:449–55.
- [11] Chun JY, Kim KJ, Hwang IT, Kim YJ, Lee DH, Lee IK, et al. Dual priming oligonucleotide system for the multiplex detection of respiratory viruses and SNP genotyping of CYP2C19 gene. *Nucleic Acids Res* 2007;35:e40.
- [12] Kalimuddin S, Sessions OM, Hou Y, Ooi EE, Sim D, Cumaraswamy S, et al. Successful clearance of human parainfluenza virus type 2 viraemia with intravenous ribavirin and immunoglobulin in a patient with acute myocarditis. *J Clin Virol* 2013;56:37–40.
- [13] Chemaly RF, Hanmod SS, Rathod DB, Ghantaji SS, Jiang Y, Doshi A, et al. The characteristics and outcomes of parainfluenza virus infections in 200 patients with leukemia or recipients of hematopoietic stem cell transplantation. *Blood* 2012;119:2738–45.
- [14] Chemaly RF, Ghosh S, Bodey GP, Rohatgi N, Safdar A, Keating MJ, et al. Respiratory viral infections in adults with hematologic malignancies and human stem cell transplantation recipients: a retrospective study at a major cancer center. *Med Baltim* 2006;85:278–87.
- [15] Renaud C, Campbell AP. Changing epidemiology of respiratory viral infections in hematopoietic cell transplant recipients and solid organ transplant recipients. *Curr Opin Infect Dis* 2011;24:333–43.
- [16] Whimbey E, Englund JA, Couch RB. Community respiratory virus infections in immunocompromised patients with cancer. *Am J Med* 1997;102:10–8.
- [17] Ruuskanen O, Lahti E, Jennings LC, Murdoch DR. Viral pneumonia. *Lancet* 2011;377:1264–75.
- [18] Jennings LC, Anderson TP, Beynon KA, Chua A, Laing RTR, Werno AM, et al. Incidence and characteristics of viral community-acquired pneumonia in adults. *Thorax* 2008;63:42–8.
- [19] Shiley KT, Van Deerlin VM, Miller Jr WT. Chest CT features of community-acquired respiratory viral infections in adult inpatients with lower respiratory tract infections. *J Thorac Imaging* 2010;25:68–75.
- [20] Herbst T, Van Deerlin VM, Miller Jr WT. The CT appearance of lower respiratory infection due to parainfluenza virus in adults. *AJR Am J Roentgenol* 2013;201:550–4.