

## Case Report

# An Option of Conservative Management of a Duodenal Injury Following Laparoscopic Cholecystectomy

**MA Modi, SS Deolekar, and AK Gvalani**

*Department of General Surgery, King Edward Memorial Hospital and Seth Gordhandas Sunderdas Medical College, Parel, Mumbai 400012, India*

Correspondence should be addressed to MA Modi; malavm25@gmail.com

Received 1 April 2014; Revised 23 September 2014; Accepted 30 September 2014; Published 21 October 2014

Academic Editor: Boris Kirshtein

Copyright © 2014 MA Modi et al. This is an open access article distributed under the Creative Commons Attribution License, which permits unrestricted use, distribution, and reproduction in any medium, provided the original work is properly cited.

Duodenal injury following laparoscopic cholecystectomy is rare complications with catastrophic sequelae. Most injuries are attributed to thermal burns with electrocautery following adhesiolysis and have a delayed presentation requiring surgical intervention. We present a case of a 47-year-old gentleman operated on for laparoscopic cholecystectomy with a bilious drain postoperatively; for which an ERC was done showing choledocholithiasis with cystic duct stump blow-out and a drain in the duodenum suggestive of an iatrogenic duodenal injury. He was managed conservatively like a duodenal fistula and recovered without undergoing any intervention.

## 1. Introduction

Bowel injuries are an uncommon complication after laparoscopic cholecystectomy but are an extremely serious complication when they do occur. Although the reported incidence rate of bowel injury is between 0.05% and 0.14% [1, 2], a large number of cases do not get reported. Most of these cases are due to injury caused while thermal injury and insertion of trocar and rarely due to dissection or adhesiolysis [3]. Most of these duodenal injuries are managed surgically, either laparoscopic or laparotomy. We present a case of an iatrogenic duodenal injury postlaparoscopic cholecystectomy managed conservatively.

## 2. Case Presentation

A 47-year-old gentleman had a 10-day history of painful obstructive jaundice. Ultrasonography revealed chronic cholecystitis with choledocholithiasis. EUS revealed a slightly dilated common bile duct (CBD) 9 mm with multiple stones impacted just above the ampulla in the lower CBD with multiple gall stones. ERC with sphincterotomy, stone extraction, and stent placement was done; complete clearance was achieved. A month later, he underwent laparoscopic

cholecystectomy at a community hospital; intraoperatively he had dense omental adhesions around Calot's triangle which were separated and the wide cystic duct was identified and clipped. In view of bleeding, while adhesiolysis a drain was placed postoperatively. On the second postoperative day, the drain was bilious in nature and was referred to our centre for further management. On arrival he was vitally stable with minimal epigastric tenderness and had a bilious drain. A CT scan done revealed a drain in the second part of the duodenum (Figure 1). We sent the patient for ERC in view of suspected duodenal and biliary injury (Figure 2). Duodenoscopy revealed the tip of the drain at the junction of D1-D2, previous stent was removed, and cholangiogram revealed mid-CBD calculi with cystic duct stump blow-out (Figure 3). Stone extraction was done and another stent was placed. The patient did not show any signs of sepsis; hence we managed him conservatively with the drain behaving like a tube duodenostomy with a daily output of around 200 mL. He was started on orals which he tolerated well. A conray gram done after 3 weeks, through the drain, showed no intraperitoneal leak and free flow of contrast into the duodenum (Figure 4). The drain was clamped and removed and this was followed by CBD stent removal (Figure 5). On 6-month follow-up, he is doing well.

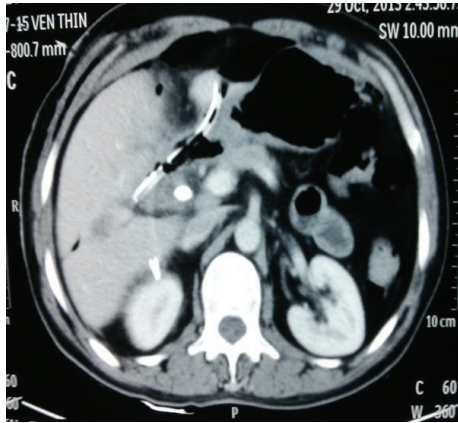


FIGURE 1: CT scan showing the drain in the 2nd part of duodenum.

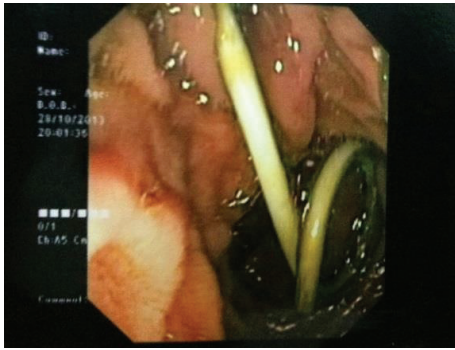


FIGURE 2: Postoperative ERCP showing a coiled drain in the duodenum.

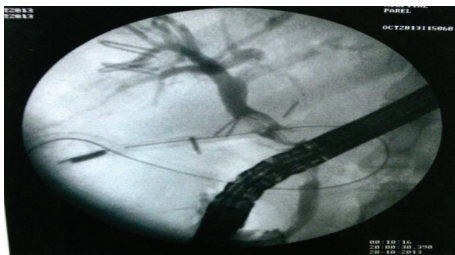


FIGURE 3: Postoperative ERCP showing a mid-CBD calculi and cystic duct stump blow-out. A drain (ryles tube) is seen in the region of duodenum.

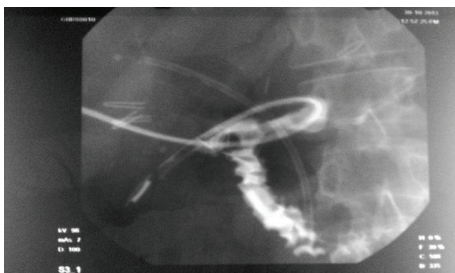

FIGURE 4: Tube conray gram showing the dye filling up in the duodenum without evidence of any intraperitoneal leak.

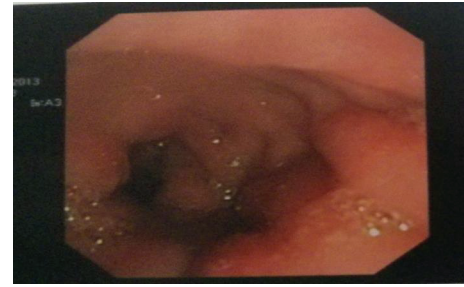


FIGURE 5: Duodenum at stent removal after removal of drain.

### 3. Discussion

Duodenal injuries are infrequent complications of laparoscopic cholecystectomy mostly seen due to dense adhesions. Acute and chronic inflammation of gallbladder causes dense adhesions around Calot's triangle and duodenal wall, thus rendering laparoscopic dissection more difficult and sometimes unsafe. In these cases, injury to duodenum may be difficult to appreciate, especially in patients in whom the apex of the duodenal bulb is tented up in front of the neck of the gallbladder [4, 5]. The reason for duodenal injury could be ascribed to the use of cautery during dissection. Thermal bowel injuries usually are not seen at the time of laparoscopic procedures and are diagnosed much later, when transmural necrosis progresses to perforation [2, 4, 6, 7]. The time of injury to onset of symptoms can vary from 18 hours to 14 days [7]. Only in 2 published cases of duodenal perforation due to electrocautery burns during LC injury was observed during surgery [6, 8]. In the other cases, focal thermal injury was unrecognized during the procedure and was presented much later until perforation of duodenal wall developed (1st to 16th postoperative day) [9–13]. Drains eroding into bowel are very well known. Trocar insertion is an early cause of duodenal injuries especially in an inflammatory condition. We do not know the exact reason for the duodenal perforation. Trocar related injury, thermal injury, and drain fistulising into the duodenum are possible hypothesis, the latter two theoretically being less likely on postoperative day two.

The late recognition of these injuries in patients leads to peritonitis and sepsis which contributes to the relatively high associated mortality. Deziel et al. [2] reported an 8.3% mortality rate among 12 patients with duodenal injuries in their analysis of 77,604 cases. El-Banna et al. [6] noted that three of four duodenal thermal injuries complicating laparoscopic cholecystectomy were fatal. Huang et al. [1] reported that 4 out of 19 (21.05%) patients with duodenal injury expired in their study of 39,238 LC cases.

Despite reports of the successful laparoscopic repair of duodenal perforation [14] during laparoscopic cholecystectomy discovered during surgery [8] or diagnosed after surgery [15], most authorities managed this dangerous complication by immediate laparotomy to assess the abdomen and secure a safe repair [2, 6, 9, 16–18].

The site of duodenal injury is important in the surgical management and prognosis. Injuries to duodenal bulb or superior flexure (as in our case) have a better prognosis than

descending duodenal injuries around the ampulla of Vater which invariably require complex surgical management and have a high mortality rate [19].

Duodenal injury is a rare but a dangerous complication of laparoscopic cholecystectomy and is associated with a high mortality. In most cases, these injuries are attributed to careless adhesiolysis with electrocautery, remain unrecognized during the procedure, and present later as peritonitis. The authors advocate placement of a drain in all patients with dense adhesions and suspicion of injury in cases of difficult laparoscopic cholecystectomy. At the end of the procedure an accurate control of the abdomen is absolutely necessary.

In conclusion, the authors wish to stress that the general practise for duodenal injuries should be to repair either laparoscopically or surgically and nonoperative management of duodenal injury in selective patients with controlled drainage.

## Consent

Written informed consent was obtained from the patient for publication of this paper and any accompanying images. A copy of the written consent is available for review by the Editor of this journal.

## Conflict of Interests

All authors declare no conflict of interests.

## Authors' Contribution

MA Modi, SS Deolekar, and AK Gvalani participated in writing the paper and revising the draft. MA Modi took the photos. All authors read and approved the final paper.

## Acknowledgment

The authors would like to thank the patient for his written consent and permission to present this paper.

## References

- [1] X. Huang, Y. Feng, and Z. Huang, "Complications of laparoscopic cholecystectomy in China: an analysis of 39 238 cases," *Chinese Medical Journal*, vol. 110, no. 9, pp. 704–706, 1997.
- [2] D. J. Deziel, K. W. Millikan, S. G. Economou, A. Doolas, S.-T. Ko, and M. C. Airan, "Complications of laparoscopic cholecystectomy: a national survey of 4,292 hospitals and an analysis of 77,604 cases," *The American Journal of Surgery*, vol. 165, no. 1, pp. 9–14, 1993.
- [3] A. Shamiyeh and W. Wayand, "Laparoscopic cholecystectomy: early and late complications and their treatment," *Langenbeck's Archives of Surgery*, vol. 389, no. 3, pp. 164–171, 2004.
- [4] C. C. Nduka, P. A. Super, J. R. T. Manson, and A. W. Darzi, "Cause and prevention of electrosurgical injuries in laparoscopy," *Journal of the American College of Surgeons*, vol. 179, no. 2, pp. 161–170, 1994.
- [5] C.-M. Lo, C.-L. Liu, S.-T. Fan, E. C. S. Lai, and J. Wong, "Prospective randomized study of early versus delayed laparoscopic cholecystectomy for acute cholecystitis," *Annals of Surgery*, vol. 227, no. 4, pp. 461–467, 1998.
- [6] M. El-Banna, M. Abdel-Atty, M. El-Meteini, and S. Aly, "Management of laparoscopic-related bowel injuries," *Surgical Endoscopy*, vol. 14, no. 9, pp. 779–782, 2000.
- [7] F. D. Loffer and D. Pent, "Indications, contraindications and complications of laparoscopy," *Obstetrical and Gynecological Survey*, vol. 30, no. 7, pp. 407–427, 1975.
- [8] C.-K. Kum, E. Eypasch, A. Aljaziri, and H. Troidl, "Randomized comparison of pulmonary function after the "French" and "American" techniques of laparoscopic cholecystectomy," *British Journal of Surgery*, vol. 83, no. 7, pp. 938–941, 1996.
- [9] A. M. Ress, M. G. Sarr, D. M. Nagorney, M. B. Farnell, J. H. Donohue, and D. C. McIlrath, "Spectrum and management of major complications of laparoscopic cholecystectomy," *American Journal of Surgery*, vol. 165, no. 6, pp. 655–662, 1993.
- [10] X. R. Chen, D. Lou, S. H. Li et al., "Avoiding serious complications in laparoscopic cholecystectomy—lessons learned from an experience of 2428 cases," *Annals of the Academy of Medicine Singapore*, vol. 25, no. 5, pp. 635–639, 1996.
- [11] D. Hebebrand, R. Menningen, H. Sommer, S. P. Roehr, and H. Troidl, "Small-bowel necrosis following laparoscopic cholecystectomy: a clinically relevant complication?" *Endoscopy*, vol. 27, no. 3, p. 281, 1995.
- [12] Z. Cala, D. Velnic, B. Cvitanovic et al., "Laparoscopic cholecystectomy: results after 1,000 procedures," *Acta Medica Croatica*, vol. 50, pp. 147–149, 1996.
- [13] S. Baev, T. Pozarliev, and G. T. Todorov, "Laparoscopic cholecystectomy: 700 consecutive cases," *International Surgery*, vol. 80, no. 4, pp. 296–298, 1995.
- [14] A.-H. Kwon, H. Inui, and Y. Kamiyama, "Laparoscopic management of bile duct and bowel injury during laparoscopic cholecystectomy," *World Journal of Surgery*, vol. 25, no. 7, pp. 856–861, 2001.
- [15] A. M. Taylor and M. K. W. Li, "Laparoscopic management of complications following laparoscopic cholecystectomy," *Australian and New Zealand Journal of Surgery*, vol. 64, no. 12, pp. 827–829, 1994.
- [16] C. G. Eden and T. G. Williams, "Duodenal perforation after laparoscopic cholecystectomy," *Endoscopy*, vol. 24, no. 9, pp. 790–792, 1992.
- [17] Y. Yamashita, T. Kurohiji, T. Kakegawa, and T. L. Dent, "Evaluation of two training programs for laparoscopic cholecystectomy: Incidence of major complications," *World Journal of Surgery*, vol. 18, no. 2, pp. 279–285, 1994.
- [18] S. M. Berry, K. J. Ose, R. H. Bell, and A. S. Fink, "Thermal injury of the posterior duodenum during laparoscopic cholecystectomy," *Surgical Endoscopy*, vol. 8, no. 3, pp. 197–200, 1994.
- [19] M. Testini, G. Piccinni, G. Lissidini et al., "Management of descending duodenal injuries secondary to laparoscopic cholecystectomy," *Digestive Surgery*, vol. 25, no. 1, pp. 12–15, 2008.