

# Distribution, side involvement, phenotype and associated anomalies of Korean patients with craniofacial clefts from single university hospital-based data obtained during 1998–2018

Jee Hyeok Chung<sup>a</sup>   
Sunjin Yim<sup>b</sup>  
Il-Sik Cho<sup>c</sup>  
Seung-Weon Lim<sup>d</sup>  
Il-Hyung Yang<sup>e</sup>  
Jeong Hyun Ha<sup>f</sup>  
Sukwha Kim<sup>g</sup>  
Seung-Hak Baek<sup>c</sup> 

<sup>a</sup>Department of Plastic and Reconstructive Surgery, Seoul National University Children's Hospital, Seoul, Korea

<sup>b</sup>Department of Orthodontics, School of Dentistry, Seoul National University, Seoul, Korea

<sup>c</sup>Private Practice, Pohang, Korea

<sup>d</sup>Department of Orthodontics, School of Dentistry, Chonnam National University, Gwangju, Korea

<sup>e</sup>Department of Orthodontics, Dental Research Institute, School of Dentistry, Seoul National University, Seoul, Korea

<sup>f</sup>Department of Plastic and Reconstructive Surgery, Seoul Metropolitan Government-Seoul National University Boramae Medical Center, Seoul, Korea

<sup>g</sup>Department of Plastic and Reconstructive Surgery, College of Medicine, Seoul National University, Seoul, Korea

**Objective:** To investigate the distribution, side involvement, phenotype, and associated anomalies of Korean patients with craniofacial clefts (CFC). **Methods:** The samples consisted of 38 CFC patients, who were treated at Seoul National University Dental Hospital during 1998–2018. The Tessier cleft type, sex, side involvement, phenotype, and associated anomalies were investigated using non-parametric statistical analysis. **Results:** The three most common types were #7 cleft, followed by #0 cleft and #14 cleft. There was no difference between the frequency of male and female. Patients with #0 cleft exhibited nasal deformity, bony defect, and missing teeth in the premaxilla, midline cleft lip, and eye problems. A patient with #3 cleft (unilateral type) exhibited bilateral cleft lip and alveolus. All patients with #4 cleft were the bilateral type, including a combination of #3 and #4 clefts, and had multiple missing teeth. A patient with #5 cleft (unilateral type) had a posterior openbite. In patients with #7 cleft, the unilateral type was more prevalent than the bilateral type (87.0% vs. 13.0%,  $p < 0.001$ ). Sixteen patients showed hemifacial microsomia (HFM), Goldenhar syndrome, and unilateral cleft lip and palate (UCLP). There was a significant match in the side involvement of #7 cleft and HFM (87.5%,  $p < 0.01$ ). Patients with #14 cleft had plagiocephaly, UCLP, or hyperterorbitism. A patient with #30 cleft exhibited tongue tie and missing tooth. **Conclusions:** Due to the diverse associated craniofacial anomalies in patients with CFC, a multidisciplinary approach involving a well-experienced cooperative team is mandatory for these patients. [Korean J Orthod 2020;50(6):383–390]

**Key words:** Craniofacial clefts, Distribution, Phenotype, Associated anomalies

Received April 14, 2020; Revised July 6, 2020; Accepted July 17, 2020.

**Corresponding author:** Seung-Hak Baek.

Professor, Department of Orthodontics, Dental Research Institute, School of Dentistry, Seoul National University, 101, Daehak-ro, Jongno-gu, Seoul 03080, Korea.

Tel +82-2-2072-3952 e-mail drwhite@unitel.co.kr

**How to cite this article:** Chung JH, Yim S, Cho IS, Lim SW, Yang IH, Ha JH, Kim S, Baek SH. Distribution, side involvement, phenotype and associated anomalies of Korean patients with craniofacial clefts from single university hospital-based data obtained during 1998–2018. Korean J Orthod 2020;50:383–390.

© 2020 The Korean Association of Orthodontists.

This is an Open Access article distributed under the terms of the Creative Commons Attribution Non-Commercial License (<http://creativecommons.org/licenses/by-nc/4.0>) which permits unrestricted non-commercial use, distribution, and reproduction in any medium, provided the original work is properly cited.

## INTRODUCTION

Craniofacial cleft is a rare congenital malformation with diverse spectrum of severity, causing significant impairment of function, facial aesthetics, and psychosocial problems for both the patients and their family.<sup>1-5</sup> Since it can occur in both the soft and hard tissues of the craniofacial region, thorough clinical examination and radiological evaluation are necessary to assess the degree and path of the craniofacial clefts.<sup>6</sup>

Although the precise etiology of craniofacial cleft is unknown, the normal embryogenesis process in the craniofacial region might be disrupted by genetic and environmental predisposing factors during the first 12 weeks of gestation.<sup>7-13</sup> The incidence of craniofacial clefts has been reported to be 1.4–6.0 per 100,000 live births.<sup>11,14</sup> The reasons for this wide range of estimate might be due to the rare occurrence of the craniofacial clefts and the lack of standard methods for data collection.<sup>15</sup>

The repairing of a craniofacial cleft needs multistage surgical treatment with pre-surgical orthopedic correction, wide tissue mobilization, and/or a bone graft.<sup>16-18</sup> In addition, some patients with craniofacial clefts exhibited other anomalies in the dentition, eye, nerve, and respiratory system. Therefore, it is necessary to establish a multidisciplinary approach with a well-experienced cooperative team that includes plastic surgeons, neurosurgeons, ophthalmologists, otolaryngologists, orthopedic surgeons, orthodontists, and psychiatrists to restore function, improve aesthetics, and resolve psychosocial issues.<sup>13,19,20</sup>

Most of the previous case reports or clinical studies have investigated the clinical characteristics of a specific type of craniofacial cleft in Korea<sup>21-30</sup> and other countries.<sup>13,31-36</sup> Furthermore, there have been no clinical demographic studies on the distribution and phenotype of all patients with craniofacial cleft in Korea to date. Therefore, the purpose of this retrospective study was to investigate the distribution, side involvement, phenotype, and associated anomalies of Korean patients with craniofacial clefts.

## MATERIALS AND METHODS

The design of this study was a retrospective one. The initial samples were patients with craniofacial cleft, who visited the Multi-disciplinary Clinic, Department of Plastic and Reconstructive Surgery, Seoul National University Children's Hospital and the Department of Orthodontics, Seoul National University Dental Hospital. The inclusion criteria were as follows: (1) patients whose ethnic background was Korean, (2) patients who were diagnosed with craniofacial clefts, (3) patients who were treated and/or followed-up from 1998 to 2018, and (4) patients

whose charts, clinical photographs, cephalometric and panoramic radiographs, and/or three-dimensional computed tomography scans were available. Patients who were not treated or followed up longitudinally were excluded.

As a result, the final cohort consisted of 38 Korean patients with craniofacial clefts (17 males and 21 females; mean age at the first consultation:  $5.34 \pm 3.03$  years). The frequency and distribution of Tessier cleft types, sex, side involvement, phenotype, and associated anomalies were investigated. This study was reviewed and approved by the Institutional Review Board of the Seoul National University Dental Hospital (ERI19030).

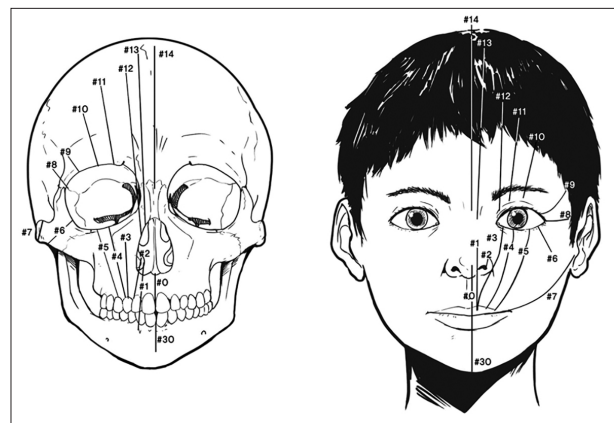
Using the orbit as the primary reference structure, Tessier<sup>37</sup> numbered craniofacial clefts from #0 to #14 in a counterclockwise fashion, extending through the lips, nostrils, maxilla, eyelids, and eye brows (Figure 1). The median cleft of the lower jaw was designated as #30 cleft. Its subgroup was divided into midline clefts (#0, #14, and #30), paramedian clefts (#1, #2, #12, and #13), orbital clefts (#3, #4, #5, #9, #10, and #11), and lateral clefts (#6, #7, and #8).

Statistical analysis was performed using descriptive statistics, chi-square goodness of fit test, and Fisher's exact test using SPSS software (ver. 12.0; SPSS Inc., Chicago, IL, USA). A *p*-value of less than 0.05 was considered a significant difference.

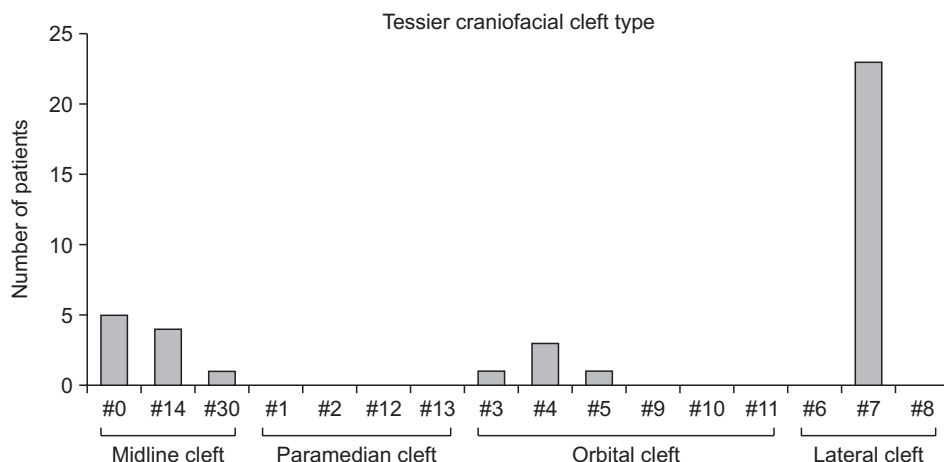
## RESULTS

### Composition of patients with craniofacial cleft (Figure 2)

The subjects included 10 patients with midline cleft (26.3%; *n* = 5 for #0 cleft, *n* = 4 for #14 cleft, and *n* = 1 for #30 cleft), 5 patients with orbital cleft (13.2%; *n* = 1 for #3 cleft, *n* = 3 for #4 cleft, *n* = 1 for #5 cleft), and 23 patients with lateral cleft (60.5%; *n* = 23 for #7 cleft).



**Figure 1.** Schematic diagram of the Tessier classification of craniofacial clefts.



**Figure 2.** Frequency and distribution of Tessier cleft types in patients with craniofacial cleft.

**Table 1.** Frequency and distribution of sex in patients with craniofacial cleft

| Tessier type in craniofacial cleft |             | Sex  |        |                    |
|------------------------------------|-------------|------|--------|--------------------|
|                                    |             | Male | Female | p-value            |
| Midline cleft (n = 10, 26.3%)      | #0 (n = 5)  | 2    | 3      | 0.754*             |
|                                    | #14 (n = 4) | 2    | 2      |                    |
|                                    | #30 (n = 1) | 0    | 1      |                    |
| Orbital cleft (n = 5, 13.2%)       | #3 (n = 1)  | 1    | 0      | 1.000*             |
|                                    | #4 (n = 3)  | 1    | 2      |                    |
|                                    | #5 (n = 1)  | 1    | 0      |                    |
| Lateral cleft (n = 23, 60.5%)      | #7 (n = 23) | 10   | 13     | 0.532 <sup>†</sup> |
| Total (n = 38)                     |             | 17   | 21     | 0.516 <sup>†</sup> |

\*Fisher’s exact test was performed.

<sup>†</sup>Chi-square goodness of fit test was performed.

**Prevalence and distribution of Tessier cleft type (Figure 2)**

The most common type was #7 cleft (n = 23), followed by #0 cleft (n = 5), #14 cleft (n = 4), #4 cleft (n = 3), and #3, #5 and #30 clefts (all n = 1). However, all paramedian clefts (#1, #2, #12, and #13 clefts) and a portion of orbital clefts (#9, #10, and #11 clefts) and lateral clefts (#6 and #8 clefts) were not detected.

**Prevalence and distribution of sex in patients with craniofacial cleft (Table 1)**

There was no difference in the prevalence of craniofacial clefts between male and female patients (total: n = 17 [44.7%] vs. n = 21 [55.3%]; midline cleft: n = 4 [40.0%] vs. n = 6 [60.0%]; orbital cleft: n = 3 [60.0%] vs. n = 2 [40.0%]; lateral cleft: n = 10 [43.5%] vs. n = 13 [56.5%]; all p > 0.05).

**Comparison of side involvement in patients with craniofacial cleft (Table 2)**

In patients with orbital cleft (#3, #4, and #5 clefts), there were no significant differences between the preva-

lence of unilateral and bilateral types (n = 2 [50.0%] vs. n = 2 [50.0%]; p > 0.05).

In patients with lateral cleft (all #7 clefts), the unilateral type was more prevalent than the bilateral type (n = 20 [87.0%] vs. n = 3 [13.0%]; p < 0.001). However, there was no significant difference between the affected side involvement of the right and left sides in the unilateral type (n = 13 [65.0%] vs. n = 7 [35.0%]; p > 0.05).

**Association with hemifacial microsomia and side involvement in patients with #7 cleft (Table 3)**

The association between hemifacial microsomia (HFM) and #7 cleft could not be stated in this study (yes: n = 16 [69.6%] vs. no: n = 7 [30.4%]; p > 0.05). However, in #7 cleft cases that had HFM, there was a significant match in the side involvement of #7 cleft and HFM (n = 14/16 [87.5%]; p < 0.01).

**Phenotype and associated anomalies in patients with midline cleft (Figure 3)**

Patients with #0 cleft (n = 5) exhibited nasal defor-

**Table 2.** Comparison of the side involvement of patients with orbital cleft and lateral cleft

|               |    | Unilateral |           | Bilateral | Right vs. Left     | Unilateral vs. Bilateral |
|---------------|----|------------|-----------|-----------|--------------------|--------------------------|
|               |    | Right side | Left side |           | p-value            | p-value                  |
| Orbital cleft | #3 | 1          | 0         | 0         | -                  | 1.000 <sup>†</sup>       |
|               | #4 | 0          | 0         | 3         |                    |                          |
|               | #5 | 1          | 0         | 0         |                    |                          |
| Lateral cleft | #7 | 13         | 7         | 3         | 0.180 <sup>†</sup> | < 0.001 <sup>***†</sup>  |
| Total         |    | 15         | 7         | 6         | 0.088 <sup>‡</sup> | 0.001 <sup>***†</sup>    |

\*\**p* < 0.01, \*\*\**p* < 0.001.

<sup>†</sup>Fisher's exact test was performed.

<sup>‡</sup>Chi-square goodness of fit test was performed.

**Table 3.** Association between HFM and #7 cleft, and degree of match of the side involvement of HFM and #7 cleft

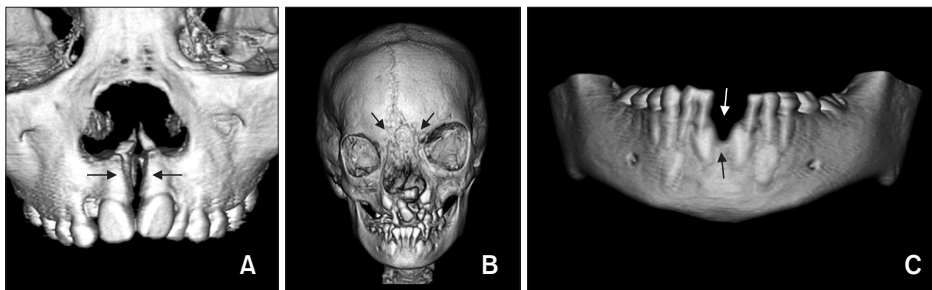
|            |            | Association with HFM |    |                    | Sidedness in cases of association with HFM |             |                       |
|------------|------------|----------------------|----|--------------------|--------------------------------------------|-------------|-----------------------|
|            |            | Yes                  | No | p-value            | Matched                                    | Not matched | p-value               |
| Unilateral | Right side | 7                    | 6  |                    | 7                                          | 0           |                       |
|            | Left side  | 6                    | 1  |                    | 6                                          | 0           |                       |
| Bilateral  |            | 2                    | 1  |                    | 2                                          | 0           |                       |
| Total      |            | 15                   | 8  | 0.061 <sup>‡</sup> | 15                                         | 0           | 0.004 <sup>***†</sup> |

HFM, Hemifacial macrosomia.

\*\**p* < 0.01.

<sup>†</sup>Fisher's exact test was performed.

<sup>‡</sup>Chi-square goodness of fit test was performed.



**Figure 3.** Examples of midline cleft. **A**, #0 cleft. **B**, #14 cleft. **C**, #30 cleft. Arrows indicate bony defect in the cleft areas.

mity (n = 3), bony defect in the premaxilla (n = 3), missing teeth in the premaxilla (n = 2), midline cleft lip (n = 3), microphthalmia (n = 2), congenital cataract (n = 1), optic nerve hypoplasia (n = 1), corpus callosum agenesis (n = 2), encephalocele (n = 3), hemangioma of neck (n = 1), duplex kidney (n = 1), pulmonary stenosis (n = 1), and funnel chest deformity (n = 1).

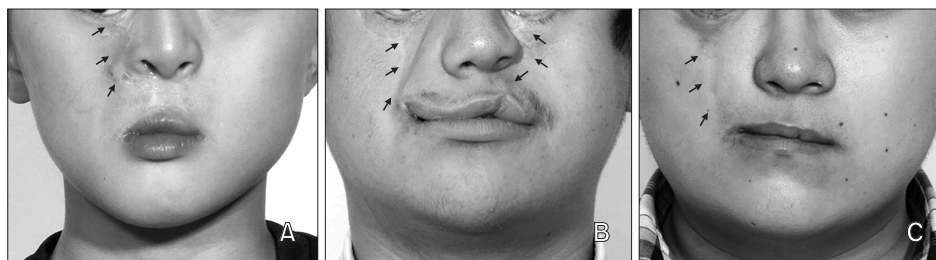
Patients with #14 cleft (n = 4) had unilateral coronal synostosis (n = 1), unilateral cleft lip and palate (UCLP) (n = 2), hyperterorbitism (n = 4), congenital ptosis with amblyopia (n = 1), strabismus (n = 2), and nasal deformity (n = 2). A patient with #30 cleft (n = 1) demonstrated tongue tie and missing mandibular left central incisor.

**Phenotype and associated anomalies in patients with orbital cleft (Figure 4)**

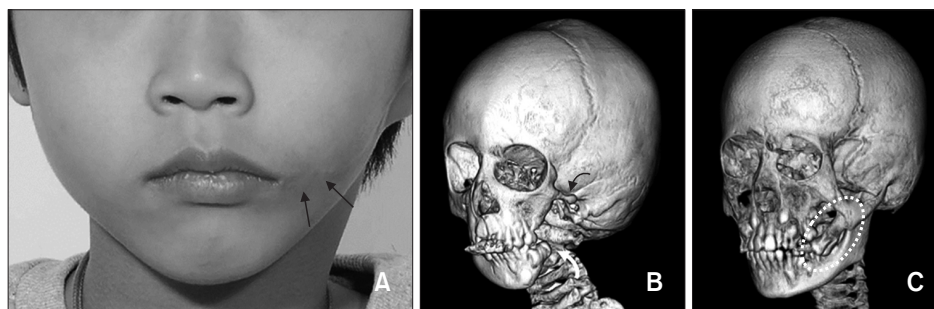
A patient with #3 cleft (n = 1) was the unilateral type (right side) and had bilateral cleft lip and alveolus (BCLA). All patients with #4 cleft (n = 3) were the bilateral type, including a combination of #3 and #4 clefts (n = 1), and had multiple teeth missing (n = 1). A patient with #5 cleft (n = 1) was a unilateral type (right side) and had a posterior openbite.

**Phenotype and associated anomalies in patients with lateral cleft (Figure 5)**

Among the patients with #7 cleft (n = 23), 20 patients were the unilateral type (87.0%; 13 right side and 7 left side) and three were the bilateral type (13.0%). A



**Figure 4.** Examples of orbital cleft. **A**, Unilateral #3 cleft. **B**, #3 cleft (left side) and #4 cleft (right side). **C**, Unilateral #5 cleft. Arrows indicate post-surgical scar tissues in the cleft surgery area.



**Figure 5.** Examples of lateral cleft. **A**, Unilateral #7 cleft (arrows indicate scar tissue). **B**, Association with hemifacial microsomia with Pruzansky-Kaban type III (white curved arrow) and hypoplasia of the zygoma (black curved arrow). **C**, Accessory bony process of the maxilla and supernumerary teeth on the left side (white dotted circle).

**Table 4.** Summary of the frequency of Tessier craniofacial cleft reported in previous studies

| Author (year)                                | Study design              | Sample size | Most common type | Rarest type                            |
|----------------------------------------------|---------------------------|-------------|------------------|----------------------------------------|
| Alonso et al. <sup>33</sup> (2008)           | Patient series            | 21          |                  | #4                                     |
| da Silva Freitas et al. <sup>17</sup> (2008) | Retrospective case review | 32          | #0               |                                        |
| Mishra and Purwar <sup>35</sup> (2009)       | Prospective cohort study  | 7           |                  | #3, #4                                 |
| da Silva Freitas et al. <sup>36</sup> (2009) | Patient series            | 6           |                  | #5                                     |
| Kalantar-Hormozi et al. <sup>13</sup> (2017) | Retrospective case review | 80          | #0 (59.5%)       | #8, #13, #30 (all 1.3%)                |
| This study (2019)                            | Retrospective case review | 38          | #7 (60.5%)       | #1, #2, #6, #8, #9, #10, #11, #12, #13 |

total of 16 patients were associated with HFM (69.6%; 12 unilateral HFM [Type I, n = 1; Type IIa, n = 5; Type IIb, n = 4; Type III, n = 2] and 4 bilateral HFM). In addition, they were associated with Goldenhar syndrome (n = 4, with internal organ anomalies, spinal anomalies and other skeletal anomalies), Klippel-Feil syndrome (n = 1, fusion of spines), and UCLP (n = 1). Seven patients were the isolated type (30.4%). Although six patients had missing teeth, two exhibited the posterior accessory bony process and supernumerary teeth.

## DISCUSSION

### Frequency and distribution of Tessier cleft types

Since it was difficult to find previous studies that investigated the frequency and distribution of whole craniofacial cleft types using PubMed, Scopus and oth-

ers, it is necessary to indirectly compare the results of this study with those of previous studies. In the present study, the most common type was #7 cleft (n = 23, 60.5%, Figure 1), followed by #0 cleft (n = 5, 13.2%, Figure 2) and #14 cleft (n = 4, 10.5%, Figure 2). These findings were similar to those reported by da Silva Freitas et al.<sup>36</sup> and Kalantar-Hormozi et al.<sup>13</sup> (Table 4). The findings that #3, #5, and #30 clefts were found in only one patient (all n = 1, 2.6%; Figure 2) and #1, #2, #6, #8, #9, #10, #11, #12, #13 were not found (all n = 0, Figure 2) were similar to the results of Mishra and Purwar,<sup>35</sup> who reported that #3 cleft was extremely rare (Table 4), and da Silva Freitas et al.,<sup>36</sup> who indicated that #5 cleft was an extremely rare craniofacial cleft (Table 4). However, although Alonso et al.<sup>33</sup> and Mishra and Purwar<sup>35</sup> reported #4 cleft as the rarest in their studies, the present study exhibited that #4 cleft was the



fourth common cleft in this study ( $n = 3$  [7.9%], Figure 2). These discrepancies might be due to the difference in the ethnic background, difficulties in visiting the hospitals, and differences in skills of the hospitals in the respective countries.

#### Frequency and distribution of sex

In the present study, there was no difference between the prevalence of craniofacial clefts in male and female patients (total, midline cleft, orbital cleft, lateral cleft; all  $p > 0.05$ ; Table 1). This was different from the results of Kalantar-Hormozi et al.,<sup>13</sup> who reported that girls are more commonly affected than boys. These discrepancies might also be due to the difference in ethnic background, and parents' attitude towards children's facial appearance according to sex in the respective countries.

#### Comparison of side involvement in patients with craniofacial cleft

In patients with orbital cleft (#3, #4, and #5 clefts), there was no statistical difference between the prevalence of the unilateral and bilateral types (50.0% vs. 50.0%;  $p > 0.05$ ; Table 2). However, this result can be attributed to the small sample size; therefore, it is necessary to analyze larger samples to validate the findings.

In patients with lateral cleft (all #7 clefts), the unilateral type was more prevalent than the bilateral type (87.0% vs. 13.0%,  $p < 0.001$ ; Table 2). This finding was similar to the results of Kim et al.<sup>21</sup> ( $n = 15$  [93.7%] vs.  $n = 1$  [6.3%]). Our results revealed that there was no significant difference between the affected side involvement of the right and left sides in the unilateral type (65.0% vs. 35.0%,  $p > 0.05$ ; Table 2), which was also similar to the results of Kim et al.<sup>21</sup> ( $n = 9$  [60.0%] vs.  $n = 6$  [40.0%]).

#### Association with hemifacial microsomia and side involvement in patients with #7 cleft

In the present study, the association between HFM and #7 cleft was not significant (yes, 69.6% vs. no, 30.4%;  $p > 0.05$ ; Table 3). However, the percentage of positive association in this study (69.6%) was higher than that reported in previous studies (Kim et al.<sup>21</sup> [ $n = 3/16$ , 18.8%] and Ryu et al.<sup>30</sup> [ $n = 4/11$ , 36.4%]). Since these results were obtained from small sample groups, it is necessary to increase the sample size to obtain a more meaningful outcome.

In patients with #7 cleft who had HFM, there was a significant match in terms of the side involvement of #7 cleft and HFM (87.5%,  $p < 0.01$ ; Table 3), indicating that these two anomalies might result from the same disturbance during the craniofacial embryogenesis process.

#### Posterior accessory bony process in patients with #7 cleft

Among patients with #7 cleft, 2 patients exhibited a posterior accessory bony process and supernumerary teeth (Figure 5). Woods et al.<sup>38</sup> reported that 55.0% of patients with #7 cleft exhibited bony abnormalities including simple clefting of the maxillary molar region, 39.0% showed maxillary duplication, and 6.0% showed intermaxillary fusion. According to Cheung et al.,<sup>39</sup> the pathogenesis of the posterior accessory bony process in patients with lateral cleft might be due to a compensatory mesenchymal growth from the temporal region rather than the duplication of the maxilla.

#### Associated anomalies with craniofacial cleft

In the present study, we found that most craniofacial clefts were associated with intra- and extra-craniofacial anomalies. Hence, there is a need of a multidisciplinary approach with a well-experienced cooperative team to tackle this issue. Although they are sporadic, orthodontists need to understand the clinical characteristics of craniofacial cleft and other anomalies associated with it.

#### Limitation of this study and suggestions for future studies

The present study attempted to provide an overview of the distribution, side involvement, phenotype, and associated anomalies of Korean patients with all types of craniofacial clefts. Despite the potential limitations due to the use of specific single university hospital-based data, we obtained meaningful basic data on the above-mentioned clinical characteristics of Korean patients with craniofacial cleft, who were diagnosed, treated, and/or followed-up over the last 20 years (1998–2018). The results of this study may provide basic data to establish a guideline for the use of health care for orthodontic treatment and surgical intervention of patients with craniofacial cleft in Korea in the near future. However, further studies are necessary to investigate the etiology of craniofacial cleft and the mechanism of its association with other anomalies during embryological development and to perform nationwide multicenter studies with systematic statistical analyses for orthodontic and surgical treatment of patients with craniofacial cleft.

## CONCLUSION

- Among the types of craniofacial clefts, #7 cleft was the most commonly found.
- In patients with #7 cleft, the unilateral type was more prevalent than the bilateral type.
- There was a high degree of match in the side involvement between #7 cleft and HFM.
- Due to the diverse associated craniofacial anomalies

in patients with craniofacial cleft, a multidisciplinary approach involving a well-experienced cooperative team is mandatory for individualized diagnosis and treatment planning of these patients.

### CONFLICTS OF INTEREST

No potential conflict of interest relevant to this article was reported.

### REFERENCES

- Tobiasen JM, Levy J, Carpenter MA, Hiebert JM. Type of facial cleft, associated congenital malformations, and parents' ratings of school and conduct problems. *Cleft Palate J* 1987;24:209-15.
- Eppley BL, van Aalst JA, Robey A, Havlik RJ, Sadove AM. The spectrum of orofacial clefting. *Plast Reconstr Surg* 2005;115:101e-14e.
- Wehby GL, Cassell CH. The impact of orofacial clefts on quality of life and healthcare use and costs. *Oral Dis* 2010;16:3-10.
- Bütow KW, Botha A. A classification and construction of congenital lateral facial clefts. *J Craniomaxillofac Surg* 2010;38:477-84.
- Racz C, Dakpé S, Kadlub N, Testelin S, Devauchelle B, Rachwalski M, et al. Phenotypic spectrum of Tessier facial cleft number 5. *J Craniomaxillofac Surg* 2018;46:22-7.
- David DJ, Moore MH, Cooter RD. Tessier clefts revisited with a third dimension. *Cleft Palate J* 1989;26:163-84; discussion 184-5.
- Fogh-Andersen P. Genetic and non-genetic factors in the etiology of facial clefts. *Scand J Plast Reconstr Surg* 1967;1:22-9.
- van der Meulen JC. Oblique facial clefts: pathology, etiology, and reconstruction. *Plast Reconstr Surg* 1985;76:212-24.
- Johnston MC. Embryology of head and neck. In: McCarthy JG, ed. *Plastic surgery*. Volume 4, cleft lip and palate and craniofacial anomalies. Philadelphia: Saunders; 1990. p. 2451-95.
- Murray JC. Face facts: genes, environment, and clefts. *Am J Hum Genet* 1995;57:227-32.
- Moore MH. Rare craniofacial clefts. *J Craniofac Surg* 1996;7:408-11.
- Bradley JP, Hurwitz DJ, Carstens MH. Embryology, classifications, and descriptions of craniofacial clefts. In: Mathes SJ, Hentz VR, eds. *Plastic surgery*. Vol. 4, pediatric plastic surgery. 2nd ed. Philadelphia: Saunders; 2006. p. 15-43.
- Kalantar-Hormozi A, Abbaszadeh-Kasbi A, Goravanchi F, Davai NR. Prevalence of rare craniofacial clefts. *J Craniofac Surg* 2017;28:e467-70.
- Kawamoto HK. Rare craniofacial clefts. In: McCarthy JG, ed. *Plastic surgery*. Philadelphia: W.B. Saunders; 1990. p. 389-550, 2952-5.
- Darzi MA, Chowdri NA. Oblique facial clefts: a report of Tessier numbers 3, 4, 5, and 9 clefts. *Cleft Palate Craniofac J* 1993;30:414-5.
- Ozaki W, Kawamoto HK Jr. Craniofacial clefting. In: Lin KY, Ogle RC, Jane JA, eds. *Craniofacial surgery: science and surgical technique*. Philadelphia: W.B. Saunders; 2002. p. 309-31.
- da Silva Freitas R, Alonso N, Shin JH, Busato L, Ono MC, Cruz GA. Surgical correction of Tessier number 0 cleft. *J Craniofac Surg* 2008;19:1348-52.
- Spolyar JL, Hnatiuk M, Shaheen KW, Mertz JK, Handler LF, Jarial R, et al. Tessier No. 3 and No. 4 clefts: sequential treatment in infancy by pre-surgical orthopedic skeletal contraction, comprehensive reconstruction, and novel surgical lengthening of the ala base-canthal distance. *J Craniomaxillofac Surg* 2015;43:1261-8.
- Forbes BJ. Congenital craniofacial anomalies. *Curr Opin Ophthalmol* 2010;21:367-74.
- Speltz ML, Richman L. Progress and limitations in the psychological study of craniofacial anomalies. *J Pediatr Psychol* 1997;22:433-8.
- Kim SH, Jeon JY, Bae YC, Kim SS. A clinical study on the Tessier classification No.7 cleft patient. *J Korean Soc Plast Reconstr Surg* 1998;25:243-51.
- Baek RM, Kim YK. Median and paramedian craniofacial cleft. *J Korean Soc Plast Reconstr Surg* 2000;27:159-64.
- Son HD, Oh K, Lee KC, Park JM, Kim JT, Kim SK. Clinical Experience of the median mandibular facial cleft. *J Korean Cleft Palate-Craniofac Assoc* 2001;2:139-42.
- Lee JH, Lee KC, Park JM, Kim SK. Postoperative analysis of the Tessier classification No.7 cleft patient. *J Korean Cleft Palate-Craniofac Assoc* 2004;5:24-30.
- Park YT, Kye JY, Kim SG, Kwon KJ, Park YW. Tessier No. 2 oblique facial cleft not associated with cleft lip or palate: a case report. *J Korean Assoc Maxillofac Plast Reconstr Surg* 2010;32:600-3.
- Bae YC, Kang KD, Kim KH. Alteration in surgical technique of Tessier classification number 7 cleft. *Arch Plast Surg* 2011;38:143-7.
- Nam SM, Kim YB. The Tessier number 14 facial cleft: a 20 years follow-up. *J Craniomaxillofac Surg* 2014;42:1397-401.
- Baek SH, Park YH, Chung JH, Kim S, Choi JY. Orthodontic and orthopedic treatment for a growing patient with Tessier number 0 cleft. *Korean J Orthod* 2018;48:113-24.
- Oh JH, Park YW. Anatomical repair of a bilateral

- Tessier No. 3 cleft by midfacial advancement. *Maxillofac Plast Reconstr Surg* 2018;40:9.
30. Ryu JY, Eo PS, Tian L, Lee JS, Lee JW, Choi KY, et al. Surgical correction for Tessier number 7 craniofacial cleft using a medially overcorrected design. *Arch Plast Surg* 2019;46:16-22.
  31. van der Meulen JC, Mazzola R, Vermey-Keers C, Stricker M, Raphael B. A morphogenetic classification of craniofacial malformations. *Plast Reconstr Surg* 1983;71:560-72.
  32. Portier-Marret N, Hohlfeld J, Hamedani M, de Buys Roessingh AS. Complete bilateral facial cleft (Tessier 4) with corneal staphyloma: a rare association. *J Pediatr Surg* 2008;43:e15-8.
  33. Alonso N, Freitas Rda S, de Oliveira e Cruz GA, Goldenberg D, Dall'oglio Tolazzi AR. Tessier no. 4 facial cleft: evolution of surgical treatment in a large series of patients. *Plast Reconstr Surg* 2008;122:1505-13.
  34. Kuriyama M, Udagawa A, Yoshimoto S, Ichinose M, Suzuki H. Tessier number 7 cleft with oblique clefts of bilateral soft palates and rare symmetric structure of zygomatic arch. *J Plast Reconstr Aesthet Surg* 2008;61:447-50.
  35. Mishra RK, Purwar R. Formatting the surgical management of Tessier cleft types 3 and 4. *Indian J Plast Surg* 2009;42 Suppl(Suppl):S174-83.
  36. da Silva Freitas R, Alonso N, Shin JH, Busato L, Dall'oglio Tolazzi AR, de Oliveria e Cruz GA. The Tessier number 5 facial cleft: surgical strategies and outcomes in six patients. *Cleft Palate Craniofac J* 2009;46:179-86.
  37. Tessier P. Anatomical classification facial, craniofacial and latero-facial clefts. *J Maxillofac Surg* 1976;4:69-92.
  38. Woods RH, Varma S, David DJ. Tessier no. 7 cleft: a new subclassification and management protocol. *Plast Reconstr Surg* 2008;122:898-905.
  39. Cheung LK, Samman N, Tideman H. Bilateral transverse facial clefts and accessory maxillae--variant or separate entity? *J Craniomaxillofac Surg* 1993;21:163-7.