

Bilateral Presumed Tuberculous Choroiditis

Naseh Mohammadi¹, MD; Fariba Ghassemi², MD; Esfandiar Shojaei³, MD; Pardis Moradnejad⁴, MD

¹Vitreoretinal Department, Razi Eye Clinic, Tehran, Iran

²Eye Research Center, Farabi Eye Hospital, Tehran University of Medical Sciences, Tehran, Iran

³Department of Infectious Diseases, Imam Khomeini Hospital, Tehran University of Medical Sciences, Tehran, Iran

⁴Department of Infectious Diseases, Rajaei Heart Hospital, Tehran University of Medical Sciences, Tehran, Iran

Abstract

Purpose: To describe a case of bilateral presumed tuberculous choroiditis which resolved promptly with a short course of antituberculous therapy.

Case Report: A 44-year-old lady presented with bilateral visual loss of 8 months' duration. Considering the presence of pan-uveitis, severe macular edema, multifocal leakage on fluorescein angiography, positive tuberculin skin test, and after excluding other diseases, she underwent anti-tuberculous therapy (ATT) for disseminated choroiditis due to presumed ocular tuberculosis. She improved promptly and completely. There were no signs of relapse 18 months after completion of the treatment course. In a young patient with disseminated choroiditis and relatively short duration of symptoms, a course of ATT for 6 months may effectively treat the disease preventing relapse for a considerable period of time.

Conclusion: In Presumed Tuberculous choroiditis early diagnosis is crucial for prompt and complete improvement.

Keywords: Pan-uveitis; Presumed Ocular Tuberculosis; Tuberculous Choroiditis

J Ophthalmic Vis Res 2016; 11 (2): 228-230.

INTRODUCTION

The lungs are most commonly affected by tuberculosis, but other organs such as the eyes, brain, kidneys, intestines and bones also may be involved. Tuberculosis (TB) was once considered the most common cause of uveitis.^[1] Today, ocular involvement due to TB is uncommon, affecting 1-2% of uveitis cases in the United States.^[1] Disseminated choroiditis is the most common presentation, characterized by deep, multiple,

discrete, yellowish lesions ranging from 0.5 to 3.0 mm in diameter.^[1] On fluorescein angiography (FA), active choroidal lesions display early hyperfluorescence with late leakage. Definitive diagnosis of TB requires isolating mycobacteria from bodily fluids or tissues, but in many cases of ocular disease, this is not possible and the diagnosis is presumptive, based on indirect evidence.^[1] Some authors believe that chronic iridocyclitis is more common than other presentations of ocular TB and usually presents bilaterally.^[2] Chronic iridocyclitis is characterized by indolent onset of blurred vision with mild or no discomfort. Periphlebitis of the retinal vessels is the second most common ocular manifestation of tuberculosis.^[2] Herein, we report a case of bilateral presumed tuberculous choroiditis.

Correspondence to:

Naseh Mohammadi, MD. Vitreoretinal Department, Razi Eye Clinic, Tehran 15176, Iran.
E-mail: nasmdi@hotmail.com

Received: 19-05-2014

Accepted: 25-03-2015

Access this article online

Quick Response Code:



Website:
www.jovr.org

DOI:
10.4103/2008-322X.183927

This is an open access article distributed under the terms of the Creative Commons Attribution-NonCommercial-ShareAlike 3.0 License, which allows others to remix, tweak, and build upon the work non-commercially, as long as the author is credited and the new creations are licensed under the identical terms.

For reprints contact: reprints@medknow.com

How to cite this article: Mohammadi N, Ghassemi F, Shojaei E, Moradnejad P. Bilateral presumed tuberculous choroiditis. *J Ophthalmic Vis Res* 2016;11:228-30.

CASE REPORT

A 44-year-old lady from Mazandaran, a province in the north of Iran, presented with decreased vision in both eyes since 8 months ago. During this period, she had frequent ophthalmological consultations where she received symptomatic treatment, including topical corticosteroids, without any improvement. The only notable finding in her history was that her husband had died 8 years earlier due to pulmonary tuberculosis.

On admission, best corrected visual acuity (BCVA) was 1/10 in both eyes, and slit lamp examination showed 3+ vitritis, and 2+ anterior chamber reaction, bilaterally. Fundus examination showed macular edema in both eyes; otherwise, the examination was unremarkable. Optical coherence tomography (OCT) revealed severe cystoid macular edema in both eyes [Figures 1a and b]. FA showed early foveal hyperfluorescence and diffuse punctate leakage in and around the macula; there was also late hyperfluorescence of the optic disc in both eyes [Figures 1c and d].

Laboratory workup showed 21 mm skin induration in reaction to tuberculous skin test (TST), and was negative for syphilis, sarcoidosis, and Lyme disease. Chest X-ray was unremarkable. She rejected to undergo intraocular fluid aspiration for microbiologic and polymerase chain reaction (PCR) studies.

Considering the data, presumed ocular tuberculosis (POT) was the most probable diagnosis. Infectious disease consultation was sought and there was no evidence of tuberculosis in other organs. The infectious disease specialist recommended anti-tuberculous therapy (ATT) and the patient received a regimen including rifampicin (600 mg/day), isoniazid (300 mg/day), pyrazinamide (150 mg/day) and ethambutol (1000 mg/day) for 2 months, followed by an additional 4 months of therapy with rifampicin (600 mg/day) and isoniazid (300 mg/day), in addition to vitamin B6 (40 mg/day) along the course.

One month after ATT, BCVA was improved to 8/10, anterior chamber and vitreous reaction had resolved and macular edema was decreased. In the next examination, 6 months after initiating ATT, both eyes had BCVA of 10/10. There was no vitreous reaction, no macular edema and fundus examination was unremarkable [Figures 2a and b]. OCT showed complete resolution of macular edema but a fine epiretinal membrane was present temporal to the fovea in the right eye [Figures 2c and d]. In the next examination 6 months later, and also at final examination 18 months after discontinuation of ATT, there were no signs of recurrence in either eye. At final exam, BCVA of the right eye was 7/10, and that of the left eye was 8/10. There were epiretinal membranes in both eyes, more severe in the right eye as shown on OCT [Figures 3a and b].

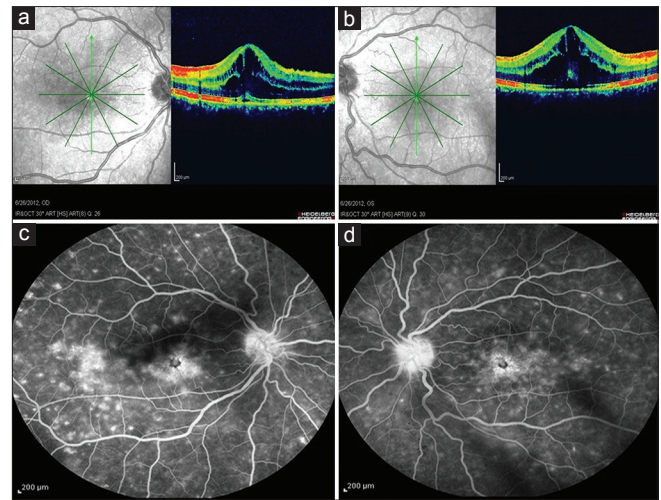


Figure 1. Top images: optical coherence tomography of the right (a) and left eye (b) at presentation, note the severe macular edema in both eyes. Bottom images: late phase fluorescein angiogram of the right (c) and left eye (d).

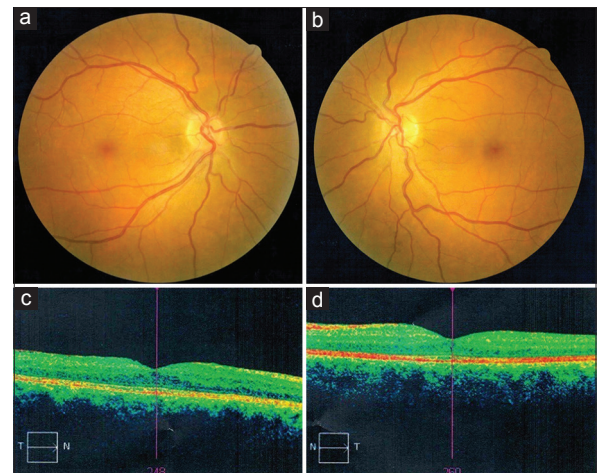


Figure 2. Fundus photograph and optical coherence tomography of the right (a and c) and left eye (b and d), six months after completion of anti-tuberculous treatment.

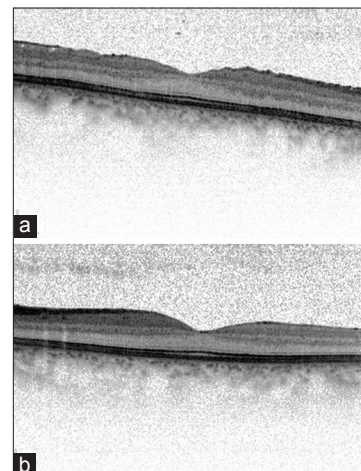


Figure 3. Optical coherence tomography of the right (a) and left eye (b), 18 months after completion of anti-tuberculous treatment.

DISCUSSION

Our patient presented with POT manifesting as choroiditis and pan-uveitis. The diagnosis of POT is made based on clinical findings of chorioretinitis, anterior uveitis, positive TST with at least 15 mm of induration, positive response to ATT within 4 weeks, and exclusion of other causes of uveitis.^[3] Other causes of chorioretinitis such as syphilis, lyme disease, sarcoidosis, and atypical cases of ocular toxoplasmosis should be excluded.

The gold standard for diagnosing ocular TB is to document a positive culture, however obtaining ocular tissues is not possible in most cases. In many cases, the diagnosis of POT is made in the setting of granulomatous ocular inflammation with positive TST or QuantiFERON-TB gold and/or isolation of myco-bacterial DNA from ocular fluids or tissues using PCR.^[4] The yield of PCR from ocular fluids in presumed ocular TB is limited. The low sensitivity of PCR from ocular fluids in mycobacterium tuberculosis (MTB) infection may be due to the low bacterial load in ocular fluids.^[5]

Six percent of patients with pulmonary TB have POT.^[6] Abrams and Schlaegel reported that out of 18 patients with presumed tubercular uveitis, chest X-ray showed no evidence of active or inactive tuberculosis in 17 cases, similar to the condition in our patient.^[7] These authors followed Woods' guidelines in patients with chronic iridocyclitis, i.e., after searching for and finding no other cause for the inflammation, patients with positive TST were given a 6 to 12 month course of ATT (usually isoniazid 300 mg every morning).^[7] They reported that improvement was complete with this guideline.^[7]

In a recently paper, Patel et al reported that the disease was controlled in 81% of patients with POT although profound visual loss occurred in 38.5%.^[8] In that study, the average time of diagnosis was 755.3 days. The authors reported that patients diagnosed after 500 days of initial ocular symptoms were at significantly higher risk of loss of vision.^[8] They also reported that relapse is more common in subjects with posterior uveitis and those receiving systemic corticosteroids.^[8] In the present case, visual acuity recovered almost completely, most probably because of the short duration of symptoms (240 days), and the patient did not show any sign of relapse up to 18 months after discontinuation of ATT. Some recommend that in TB uveitis, anti-tuberculous drugs should be continued for more than 6 to 9 months to decrease the likelihood of recurrence.^[9] The CDC recommends prolonged therapy for tuberculosis of any site that responds slowly.^[10]

Some advocate systemic corticosteroids in combination with ATT in POT cases.^[11] Our patient did not receive

systemic corticosteroids. In a study on 18 patients with POT, Zhang et al reported that all of them were treated successfully with ATT without corticosteroid use.^[12] In a study evaluating the effect of corticosteroids on visual outcomes and complications of patients with POT, it was reported that this regimen may lead to a poor visual outcome.^[3] It seems that a 6-month course of ATT may be appropriate in a young patient with relatively short duration of symptoms and rapid response to treatment such as our patient.

In summary, in patients with tuberculous choroiditis, early diagnosis is crucial for prompt and complete visual recovery and to decrease the likelihood of relapse. Therefore, in such patients, a relatively short course of ATT (6 months) may be adequate.

Financial Support and Sponsorship

Nil.

Conflicts of Interest

There are no conflicts of interest.

REFERENCES

1. American Academy of Ophthalmology. Infectious uveitis. In: BCSC, Intraocular Inflammation and Uveitis 2009-2010. Sec. 9. San Francisco: American Academy of Ophthalmology; 2009-2010. p. 223-292.
2. Knox DL. Retinal syphilis and tuberculosis. In: Ryan SJ, Editor. Retina. 4th ed. Maryland Heights: Mosby; 2006. p. 1711-1720.
3. Hamade IH, Tabbara KF. Complications of presumed ocular tuberculosis. *Acta Ophthalmol* 2010;88:905-909.
4. Gupta V, Gupta A, Rao NA. Intraocular tuberculosis – An update. *Surv Ophthalmol* 2007;52:561-587.
5. Sankar S, Ramamurthy M, Nandagopal B, Sridharan G. An appraisal of PCR-based technology in the detection of *Mycobacterium tuberculosis*. *Mol Diagn Ther* 2011;15:1-11.
6. Lara LP, Ocampo V Jr. Prevalence of presumed ocular tuberculosis among pulmonary tuberculosis patients in a tertiary hospital in the Philippines. *J Ophthalmic Inflamm Infect* 2013;3:1.
7. Abrams J, Schlaegel TF Jr. The role of the isoniazid therapeutic test in tuberculous uveitis. *Am J Ophthalmol* 1982;94:511-515.
8. Patel SS, Saraiya NV, Tessler HH, Goldstein DA. Mycobacterial ocular inflammation: Delay in diagnosis and other factors impacting morbidity. *JAMA Ophthalmol* 2013;131:752-758.
9. Ang M, Hedayatfar A, Wong W, Chee SP. Duration of anti-tubercular therapy in uveitis associated with latent tuberculosis: A case-control study. *Br J Ophthalmol* 2012;96:332-336.
10. Centers for Disease Control (CDC), American Thoracic Society, Infectious Diseases Society of America. Treatment of Tuberculosis. *MMWR Morb Mortal Wkly Rep* 2003;52:RR1.
11. Abu El-Asrar AM, Al-Mezaine HS. Anti-tuberculous therapy combined with systemic corticosteroids improves retinal sensitivity in patients with active presumed tuberculous choroiditis. *Int Ophthalmol* 2010;30:567-576.
12. Zhang M, Zhang J, Liu Y. Clinical presentations and therapeutic effect of presumed choroidal tuberculosis. *Retina* 2012;32:805-813.