



# Sequential-contingent strategy for fallopian tube evaluation using hysterosalpingo foam sonography: a cost analysis

Alberto Armijo-Sánchez<sup>1,2,3^</sup>, Esther Santamaría-López<sup>2,3^</sup>, Manuel Fernández-Sánchez<sup>2,3,4,5^</sup>, Noelia Galiano-Gutiérrez<sup>2,3</sup>, Elena Mantrana-Bermejo<sup>1,2,3</sup>

<sup>1</sup>Department of Obstetrics and Gynecology, Valme University Hospital, Seville, Spain; <sup>2</sup>Research Department, IVI-RMA Seville, Seville, Spain; <sup>3</sup>IVI Foundation, Health Research Institute La Fe (IIS La Fe), Valencia, Spain; <sup>4</sup>Department of Molecular Biology and Biochemical Engineering, Pablo de Olavide University, Seville, Spain; <sup>5</sup>Department of Surgery, Sevilla University, Seville, Spain

**Contributions:** (I) Conception and design: A Armijo-Sánchez, M Fernández-Sánchez; (II) Administrative support: E Santamaría-López, N Galiano-Gutiérrez; (III) Provision of study materials or patients: A Armijo-Sánchez, E Mantrana-Bermejo; (IV) Collection and assembly of data: A Armijo-Sánchez; (V) Data analysis and interpretation: E Santamaría-López, N Galiano-Gutiérrez; (VI) Manuscript writing: All authors; (VII) Final approval of manuscript: All authors.

**Correspondence to:** Manuel Fernández-Sánchez, MD, PhD. Research Department, IVI-RMA Seville, Avda. Américo Vespucio 19 ES-41092, Seville, Spain; IVI Foundation, Health Research Institute La Fe (IIS La Fe), Valencia, Spain; Department of Molecular Biology and Biochemical Engineering, Pablo de Olavide University, Seville, Spain; Department of Surgery, Seville University, Seville, Spain. Email: manuel.fernandez@ivirma.com.

**Background:** Tubal pathology is the etiological factor in 20% of couples with female infertility. Historically, diagnostic evaluation of the fallopian tubes has been performed by means of hysterosalpingography (HSG). Hysterosonosalingography with EXEM<sup>®</sup> foam is a recent technique with supposedly comparable effectiveness to HSG, but with better tolerability for patients.

**Methods:** Tubal patency was assessed in patients who were candidates for intrauterine insemination (IUI) between January 2020 and July 2021. (I) Hysterosonosalingography with EXEM<sup>®</sup> foam. (II) If the patient had both tubes patent, IUI was proposed. In case of inconclusive or pathological results, HSG was performed. (III) If the HSG concludes tubal patency, IUI is proposed. On the other hand, if it results in tubal obstruction, in vitro fertilization (IVF) is proposed.

**Results:** Assessment of tubal patency by HSG showed concordance with previous Hysterosonosalingography with EXEM<sup>®</sup> foam results in 45.5% (n=15) of cases of unilateral obstruction and 66.7% (n=6) of cases of bilateral obstruction. When we compare the total cost of HSG (€54,899.46) with the sum of patients who only required Hysterosonosalingography with EXEM<sup>®</sup> foam together with those who underwent both tests (€45,575.96), it shows that the latter represents a cost benefit strategy (cost difference €9,323.50).

**Conclusions:** Our results suggest a benefit of €9,323.50 when performing the contingent sequential strategy, in case of pathological or inconclusive results, compared to performing a systematic HSG in all patients. Patients with an obstructive hysterosalpingogram with EXEM<sup>®</sup> and a patent hysterosalpingogram will be the subgroup that will benefit the most, as IUI can be proposed instead of IVF. In addition, there is a benefit in terms of optimizing the medical procedure, hospital visits and speeding up the time to start assisted reproductive technology (ART).

**Keywords:** Tubal patency; hysterosonosalingography; hysterosalpingo-foam sonography (HyFoSy); hysterosalpingography (HSG); cost analysis

<sup>^</sup> ORCID: Alberto Armijo-Sánchez, 0000-0002-4724-9511; Esther Santamaría-López, 0000-0001-7727-9116; Manuel Fernández-Sánchez, 0000-0002-1214-2984.

Submitted Jun 07, 2023. Accepted for publication Oct 30, 2023. Published online Jan 02, 2024.

doi: 10.21037/qims-23-816

View this article at: <https://dx.doi.org/10.21037/qims-23-816>

## Introduction

Tubal patency is an important infertility cause with an incidence of 0.4 per 1,000 women in Europe (1). The main etiologies include pelvic inflammatory disease (PID), endometriosis and/or adhesive conditions resulting from previous surgery (2). The anatomical and functional evaluation of the Fallopian tubes is a fundamental procedure prior to performing homologous intrauterine insemination (H-IUI) or donor intrauterine insemination (D-IUI). Traditionally, the 'gold standard' technique for tubal evaluation has been laparoscopy with chromoperturbation, but due to its invasive and costly nature, it has been replaced by hysterosalpingography (HSG) for decades. However, HSG involves irradiation on the female pelvis, exposure to iodinated contrasts and involves a moderately painful procedure (3).

Over the years new techniques have been developed to avoid the drawbacks of HSG. In 2007, Emanuel *et al.* developed a new non-embryotoxic contrast medium (EXEM<sup>®</sup>) for performing hysterosalpingo-contrast sonography (HyCoSy) (4). This variant, called hysterosalpingo-foam sonography (HyFoSy), could improve diagnostic yield and efficacy compared with other ultrasonographic methods for tubal evaluation (5).

HyFoSy does not require referring patients to another center for tubal evaluation, as it can usually be performed in the fertility center itself, reducing waiting times to initiate assisted reproductive technology (ART) (4). In contrast, HSG is performed in hospitals or in free-standing radiology clinics due to the use of radiological equipment. Moreover, it is a more economical technique than HyCoSy, which can be performed by a single operator as a first tubal patency test (6). In addition, HyFoSy and HSG have similar results in assessing tubal pathology in most infertile couples and, in the cases where they differ, it does not lead to a substantial difference in pregnancy outcome (6,7), while HyFoSy is significantly better tolerated by the patients (2,7-12).

All available methods for evaluation of tubal factors have technical limitations that must be considered in case that the technique yields abnormal results. Further evaluation with a second, complementary method is suggested whenever specific diagnosis or best treatment strategy is uncertain (12).

Several published studies have justified the use of HyFoSy

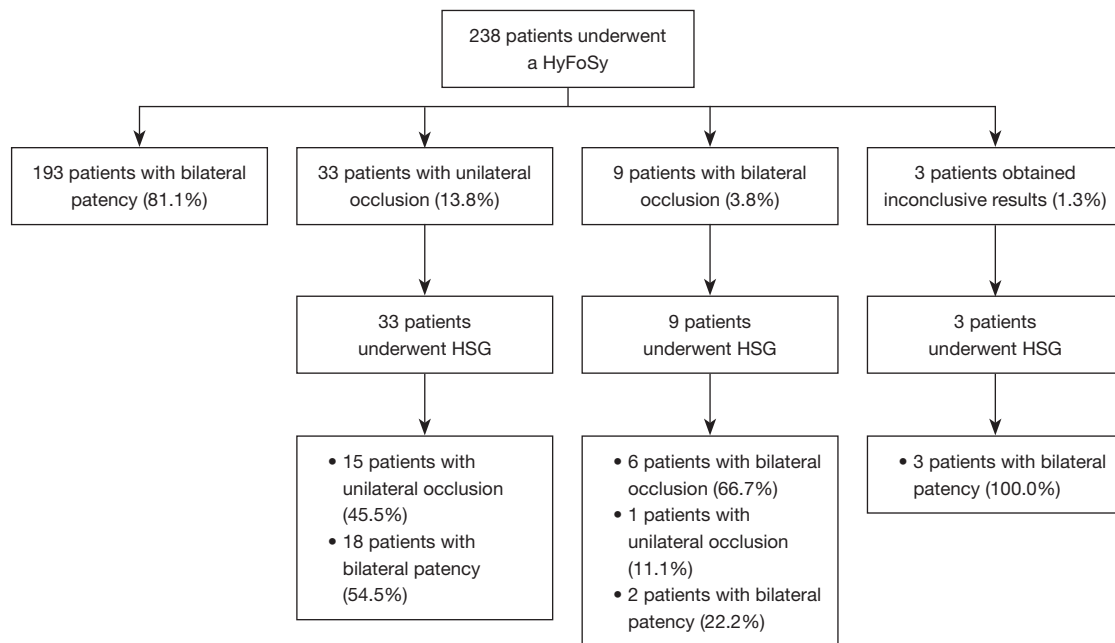
instead of HSG to be indicated as a first-choice diagnostic tool, however, HSG is still the most recommended procedure (13). No cost analysis study has been previously published comparing both techniques, although the results related to the costs of a prospective and randomized multicenter study are pending of publication (14). Therefore, the aim of this study is to demonstrate that the implementation of a sequential-contingent strategy in tubal evaluation is beneficial in economic terms compared to the performance of systematic HSG prior to the application of ART.

## Methods

### Patients

This retrospective study was approved by the Institutional Ethics Committee of Virgen de Valme University Hospital (Seville, Spain) (No. 2749-N-21) and individual consent for this retrospective analysis was waived. The study was conducted in accordance with the Declaration of Helsinki (as revised in 2013). HyFoSy as a first-choice diagnostic tool for tubal patency assessment was established in our center. In case the results are inconclusive or pathological (unilateral or bilateral occlusion), HSG is performed sequentially to confirm the data. If the HSG conclude bilateral tubal patency, IUI is proposed. In vitro fertilization (IVF) was proposed to those patients with tubal obstruction. Patients' candidates for IUI attending to our unit to be diagnosed of tubal patency between January 2020 and July 2021 were included in the analysis (*Figure 1*). The inclusion criteria to be candidates for IUI following our Institution's protocols are: women aged 18–40 years, primary infertility time of less than 1 year, body mass index (BMI) <30 kg/m<sup>2</sup>, anti-Mullerian hormone (AMH) >1 ng/mL, semen analysis with Motile sperm recovery (MSR) >5 million/mL and morphology >4%, absence of previous diagnostic test confirming tubal pathology, absence of PID, no history of pelvic surgery and no signs of endometriosis or adnexal pathology.

Given the nature of the study, we are working with information that we already have available, so we proceed to calculate the statistical power. Considering the selection criteria described and the study period indicated, it is



**Figure 1** Flowchart of eligible treatment. HyFoSy, hysterosalpingo-foam sonography; HSG, hysterosalpingography.

estimated that we will have a total of 238 patients who have gone to the clinics of the Assisted Human Reproduction Unit of the Hospital Universitario Ntra Sra. de Valme to undergo an assisted human reproduction procedure.

Given this number of patients and with the aim of observing a difference of 5.0% in the economic study, the statistical power calculated for the subsequent analyses is 100.0%.

### HSG/HyFoSy procedure

The HyFoSy procedure was performed by the same trained clinics (with more than 3 years of experience in the use of HyFoSy) and always under the same conditions. All ultrasound (US) were performed using a Toshiba-Xario (model TUS-X200) with a volumetric 4–9 MHz endovaginal probe (Model PVU-781VT) (13). Gynetics® catheter (#4220 Intrauterine insemination cannula, Gynetics Medical Products N.V., Lommel, Belgium) was used to reach and cannulate the uterine cervix. The methodology of the procedure was already explained by the authors previously (4). HSG technique was performed in the Radiology Department (X-ray) of the institution. Approximately 10 cm<sup>3</sup> of soluble iodinated contrast medium (Iomeron® 300 mg, Bracco Imaging s.p.a., Milan, Italy) was infused in the uterine cavity and fallopian tubes through

the use of a balloon catheter (Teleflex Medical Rusch® Gold Silicone Coated Latex Foley Catheters, size 7F, Teleflex Medical, Westmeath, Ireland). The contrast medium was visible on X-ray. During instillation of the contrast medium into the uterine cavity, a series radiographs were evaluated by a radiologist, to establish the patency of the Fallopian tubes.

### Economic evaluation

To carry out the economic evaluation, an individual analysis of the resources used in each procedure was performed. The Spanish healthcare model is based on 17 autonomous communities and each one has a different price for HSG. For this reason, in order to be more accurate and to be able to extrapolate the results to the centers in Spain, we have calculated the price of HSG by averaging the costs (Table 1). The cost of HyFoSy was reported by the supplier. The costs for each treatment arm were calculated by adding the resources used, making a decision-making diagram to calculate the total cost of each procedure (Table 2).

### Statistical analysis

A descriptive analysis was performed showing the main characteristics of the study population. Continuous

**Table 1** Prices of hysterosalpingography by autonomous communities

Autonomous communities	Price (€)	Source
Cataluña	129.00	Official Gazette of the Generalitat de Catalunya num. 8153—Jun 12, 2020
Canarias	144.51	Official Gazette of the Canary Islands num. 67—Apr 05, 2017
Comunidad Valenciana	185.48	Official Gazette of the Generalitat Valenciana num. 8202—Dec 30, 2017
Extremadura	215.12	Official Gazette of Extremadura num. 35—Feb 19, 2018
Islas Baleares	171.00	Official Gazette of the Balearic Islands No. 213—Dec 24, 2020
País Vasco	136.00	Official Gazette of the Basque Country No. 18—Dec 18, 2020
Mutualidad General funcionarios Civiles del Estado (MUFACE)	112.00	Official Gazette of the Basque Country No. 18—Dec 18, 2020
Average	156.15	

**Table 2** Breakdown of prices for each procedure (fiscal year 2022)

Procedure	Price (€)	Source
HSG		Spanish National Health Service
Water-soluble iodinated contrast 10 cm <sup>3</sup> ; foley catheter; radiography series [3–4]; radiology report	156.15*	
First consultation hospital care	51.77	
Successive consultations/revision hospital care	22.75	
Total cost	230.67	
HyFoSy		Dibimed-Biomedical Supply, Valencia (Spain)
ExEm <sup>®</sup> Foam Kit: 1× 10 mL syringe pre-filled with 5 mL of ExEm <sup>®</sup> Gel; 1× 10 mL syringe pre-filled with 5 mL ExEm <sup>®</sup> Water; 1× coupling device	78.65	
Intrauterine insemination cannula—IUI Memo Gynétics	4.50	
First consultation hospital care	51.77	
Successive consultations/revision hospital care	22.75	
Total cost	157.67	

\*, average price calculated in different autonomous communities. HSG, hysterosalpingography; HyFoSy, hysterosalpingo-foam sonography.

values are summarized according to mean, maximum and minimum and standard deviation. For categorical data, a diagram is presented. For the economic analysis, the direct costs derived from the medical interventions were used and the overall cost of each strategy performed was calculated. For HSG, an average price was calculated with the cost of the test in different autonomous communities (the Spanish regions's administrative division), while for HyFoSy, a sum of the cost of the resources used was calculated (*Table 1*). On the other hand, both techniques were compared using the Wilcoxon test for paired samples in order to see the

concordance between the tests if both were performed. The Statistical Package for Social Sciences version 22 was used for data analysis.

## Results

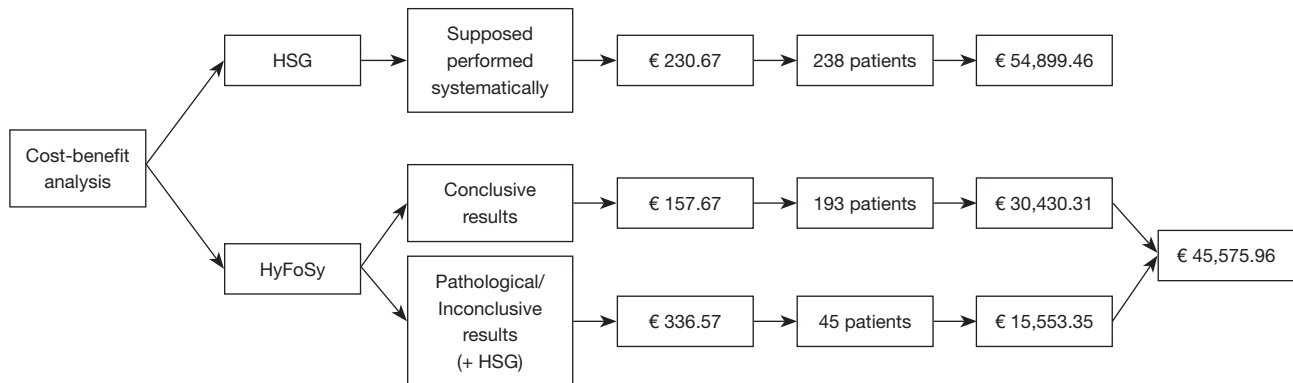
The main characteristics of the 238 included women are summarized in *Table 3*.

We compared the cost of HSG if it was supposed performed systematically on the entire sample (n=238; €54,899.46) with the sum of patients who only required

**Table 3** Patient characteristics

Variables	Patients with patent HyFoSy result (n=193)	Patients with non-patent HyFoSy result (n=45)
Age (years)	32.09±3.61 (23.00–39.00)	30.82±3.63 (20.00–39.00)
Body mass index (kg/m <sup>2</sup> )	25.30±4.32 (16.85–40.77)	24.50±4.20 (17.95–33.37)
HyFoSy duration (min)	6.52±4.06 (1.00–20.00)	7.18±3.84 (2.00–16.00)
Time between HyFoSy and ART (months)	1.60±1.37 (0.00–6.00)	0.87±1.36 (0.00–5.00)

Data are presented as mean ± SD (range). HyFoSy, hysterosalpingo-foam sonography; ART, assisted reproductive technology; SD, standard deviation.

**Figure 2** Cost according to the strategy chosen. HSG, hysterosalpingography; HyFoSy, hysterosalpingo-foam sonography.

HyFoSy and the patients who required both tests (HyFoSy + HSG) (n=193 and n=45 respectively; €45,575.96), it shows that the latter represents a cost benefit strategy (cost difference €9,323.50) (Figure 2).

As we have previously developed above, only those patients with pathological and inconclusive results after HyFoSy, were subjected to HSG for confirmation. The evaluation of tubal patency by HSG showed a concordance with previous HyFoSy results in 45.5% (n=15) of cases of unilateral obstruction and in 66.7% (n=6) of cases of bilateral obstruction. On the other hand, total discordance between the two techniques was seen. In 54.5% (n=18) of cases, tubal patency was diagnosed by HSG while HyFoSy indicated unilateral obstruction. In the case of bilateral obstruction by HyFoSy, HSG diagnosed tubal patency in 22.2% (n=2) cases and unilateral obstruction in 11.1% (n=1) (Figure 1).

Interestingly, in 23 patients with an abnormal HyFoSy result (18 patients with unilateral obstruction, 2 patients with bilateral obstruction, and 3 with inconclusive results), the HSG demonstrated bilateral tubal patency; this means that IUI was finally indicated in 9.6% of the patients,

who would have been ruled out for IUI taking exclusively the HyFoSy into account (Table 4). Our concordance results show that 33.4% (n=15) of the cases of unilateral obstruction by HSG was in agreement with previous results by HyFoSy. In addition, there was agreement in 13.3% (n=6) of cases of bilateral obstruction (P<0.001).

Finally, we analyzed the number of adverse events after the HyFoSy procedure, and no infections were reported in any patient. Four vasovagal reactions were reported (1.7%).

## Discussion

To the best of our knowledge, this is the first study that analyzes, in terms of economic cost, the implementation of HyFoSy in clinical practice. Until now, the accuracy, effectiveness and safety of HyFoSy as an alternative to HSG for the study of tubal patency has already been demonstrated.

Tubal factor is an important cause of infertility; therefore, a correct and exhaustive evaluation of Fallopian tubes will allow us to establish a correct diagnosis and select the therapeutic strategy that provides the best results after

**Table 4** Concordance between HyFoSy and HSG

Patency during HyFoSy	Patency during HSG			
	Bilateral patency (n=23)	Unilateral occlusion (n=16)	Bilateral occlusion (n=6)	Inconclusive results (n=0)
Bilateral patency	N/A	N/A	N/A	N/A
Unilateral occlusion (n=33)	18 (40.0)	15 (33.4)*	0 (0.0)	0 (0.0)
Bilateral occlusion (n=9)	2 (4.4)	1 (2.2)	6 (13.3)*	0 (0.0)
Inconclusive results (n=3)	3 (6.7)	0 (0.0)	0 (0.0)	0 (0.0)

Data are presented as number (percentage). Wilcoxon matched-pair signed-ranks test ( $P < 0.001$ ). \*, results concordant between both techniques. HyFoSy, hysterosalpingo-foam sonography; HSG, hysterosalpingography.

the application of ART. The subgroup that will benefit most from this strategy are patients with an obstructive HyFoSy and a patent HSG since we can propose IUI instead of IVF. On the other hand, patients with an obstructive HyFoSy and an obstructive HSG will only be able to perform IVF.

We have observed that the application of a sequential-contingent strategy in the evaluation of the tubes in case of pathological or inconclusive results in HyFoSy is more profitable than the performance of systematic HSG. When comparing the total cost of the HSG with the sum of the patients who only required HyFoSy together with those who underwent both tests, we can see significant economic differences. These data demonstrate that the contingent strategy represents a benefit, not only at the economic level but also at the level of optimizing medical act, hospital visits and speeding up the time to initiate ART.

Our findings are in consonance with previous publications, such as the study by Piccioni *et al.* where HyFoSy showed a high concordance (>94.4%) compared to HyCoSy with saline solution (57.8%) when both techniques were confronted with LC (9). These data have been confirmed in the meta-analysis by Melcer *et al.* in which 6 studies were included (8).

Although no infections were described after HyFoSy procedure, four vasovagal reactions were reported (1.7%). This incidence is higher than in the prospective multicentre study where only two vaso-vagal episodes and one mild urinary tract infection were reported (2).

Due to the published evidence, some authors such as Ramos *et al.* are already proposing to replace HSG with HyFoSy (5). Although we agree that HyFoSy should be the first-line diagnostic procedure to evaluate tubal patency, our results show that a non-negligible percentage of patients will benefit from confirming a suspicion of tubal pathology

with a second diagnostic test, reducing economic resources. This practice will be especially relevant in cases where there is a BMI >25 kg/m<sup>2</sup>, since it alters echogenicity generating images of poorer quality, deep endometriosis, patients with previous pelvic surgery, patients with positive serology for *Chlamydia trachomatis*, poorly-equipped US or gynecologists without HyFoSy training (14).

As for the limitations of the study, due to its retrospective nature, we do not have the indirect costs, so it was not possible to include them in the analysis. On the other hand, there is no definitive price for HSG since there is a great disparity in costs between the different Spanish regions. For this reason, the number we took as a reference is an average of the prices. Furthermore, Engels *et al.* recently concluded that couples with infertility duration of less than 18 months and women younger than 35 years with unexplained infertility were more likely to become pregnant after HyFoSy. In their study, 26.5% of patients became pregnant spontaneously during the 12 months after HyFoSy (15). Lastly, we do not have the gestation rate in patients with pathological HyFoSy and normal HSG, but since the sample is very small, we have not considered it representative. It would be interesting to investigate the pregnancy rate in this subgroup of patients in studies with larger sample sizes.

## Conclusions

HyFoSy is a more economical technique and the tubal patency results are in concordance with HSG. Our results suggest that there is an economic benefit to implementing the contingent sequential strategy, in case of pathological or inconclusive results, compared to performing a systematic HSG on all patients. Patients with an obstructive HyFoSy



and a patent HSG will be the subgroup that will benefit the most as IUI may be proposed instead of IVF.

## Acknowledgments

The authors thank all the staff at IVF Unit Valme University Hospital (Seville, Spain) for their contribution to this work.

*Funding:* None.

## Footnote

*Conflicts of Interest:* All authors have completed the ICMJE uniform disclosure form (available at <https://qims.amegroups.com/article/view/10.21037/qims-23-816/coif>). The authors have no conflicts of interest to declare.

*Ethical Statement:* The authors are accountable for all aspects of the work in ensuring that questions related to the accuracy or integrity of any part of the work are appropriately investigated and resolved. The study was conducted in accordance with the Declaration of Helsinki (as revised in 2013). The study was approved by the Institutional Ethics Committee of Virgen de Valme University Hospital (Seville, Spain) (No. 2749-N- 21) and individual consent for this retrospective analysis was waived.

*Open Access Statement:* This is an Open Access article distributed in accordance with the Creative Commons Attribution-NonCommercial-NoDerivs 4.0 International License (CC BY-NC-ND 4.0), which permits the non-commercial replication and distribution of the article with the strict proviso that no changes or edits are made and the original work is properly cited (including links to both the formal publication through the relevant DOI and the license). See: <https://creativecommons.org/licenses/by-nc-nd/4.0/>.

## References

1. Hoenderboom BM, van Benthem BHB, van Bergen JEAM, Dukers-Muijers NHTM, Götz HM, Hoebe CJPA, Hogewoning AA, Land JA, van der Sande MAB, Morré SA, van den Broek IVF. Relation between Chlamydia trachomatis infection and pelvic inflammatory disease, ectopic pregnancy and tubal factor infertility in a Dutch cohort of women previously tested for chlamydia in a chlamydia screening trial. *Sex Transm Infect* 2019;95:300-6.
2. Engels V, Medina M, Antolín E, Ros C, Amaro A, De-Guirior C, Manzour N, Sotillo L, De la Cuesta R, Rodríguez R, San-Frutos L, Peralta S, Martín-Martínez A, Alcázar JL. Feasibility, tolerability, and safety of hysterosalpingo-foam sonography (hyfosy). multicenter, prospective Spanish study. *J Gynecol Obstet Hum Reprod* 2021;50:102004.
3. Rajesh H, Lim SL, Yu SL. Hysterosalpingo-foam sonography: patient selection and perspectives. *Int J Womens Health* 2017;9:23-32.
4. Ramos J, Caligara C, Santamaría-López E, González-Ravina C, Prados N, Carranza F, Blasco V, Fernández-Sánchez M. Diagnostic Accuracy Study Comparing Hysterosalpingo-Foam Sonography and Hysterosalpingography for Fallopian Tube Patency Assessment. *J Clin Med* 2021;10:4169.
5. Ramos J, Pellicer N, Fernández-Sánchez M. Hysterosalpingography is obsolete: hysterosalpingo-contrast foam sonography should be the alternative. *Reprod Biomed Online* 2022;45:839-42.
6. Emanuel MH, van Vliet M, Weber M, Exalto N. First experiences with hysterosalpingo-foam sonography (HyFoSy) for office tubal patency testing. *Hum Reprod* 2012;27:114-7.
7. Tanaka K, Chua J, Cincotta R, Ballard EL, Duncombe G. Hysterosalpingo-foam sonography (HyFoSy): Tolerability, safety and the occurrence of pregnancy post-procedure. *Aust N Z J Obstet Gynaecol* 2018;58:114-8.
8. Melcer Y, Zilberman Sharon N, Nimrodi M, Pekar-Zlotin M, Gat I, Maymon R. Hysterosalpingo-Foam Sonography for the Diagnosis of Tubal Occlusion: A Systematic Review and Meta-analysis. *J Ultrasound Med* 2021;40:2031-7.
9. Piccioni MG, Riganelli L, Filippi V, Fuggetta E, Colagiovanni V, Imperiale L, Caccetta J, Panici PB, Porpora MG. Sonohysterosalpingography: Comparison of foam and saline solution. *J Clin Ultrasound* 2017;45:67-71.
10. Van Schoubroeck D, Van den Bosch T, Meuleman C, Tomassetti C, D'Hooghe T, Timmerman D. The use of a new gel foam for the evaluation of tubal patency. *Gynecol Obstet Invest* 2013;75:152-6.
11. van Welie N, van Rijswijk J, Dreyer K, van Hooff MHA, de Bruin JP, Verhoeve HR, et al. Can hysterosalpingo-foam sonography replace hysterosalpingography as first-choice tubal patency test? A randomized non-inferiority trial. *Hum Reprod* 2022;37:969-79.
12. Optimal evaluation of the infertile female. *Fertil Steril* 2006;86:S264-7.

13. van Rijswijk J, van Welie N, Dreyer K, van Hooff MHA, de Bruin JP, Verhoeve HR, et al. The FOAM study: is Hysterosalpingo foam sonography (HyFoSy) a cost-effective alternative for hysterosalpingography (HSG) in assessing tubal patency in subfertile women? Study protocol for a randomized controlled trial. *BMC Womens Health* 2018;18:64.
14. Hardel AS, Flye Sainte Marie H, Lorrain S, Iacobelli S, Lazaro G, Boukerrou M, Tran PL. Factors associated with non-visualisation of tubal patency during Hysterosalpingo-Foam-Sonography. *J Gynecol Obstet Hum Reprod* 2022;51:102379.
15. Engels V, Medina M, Antolín E, Ros C, Bermejo C, Manzour N, Pelayo I, Amaro A, Martínez-Ten P, De-Guirior C, Rodríguez R, Sotillo L, Brotons I, de la Cuesta-Benjumea R, Martínez O, Sancho J, Alcázar JL. Factors Associated with a Post-Procedure Spontaneous Pregnancy after a Hysterosalpingo-Foam-Sonography (HyFoSy): Results from a Multicenter Observational Study. *Diagnostics (Basel)* 2023;13:504.

**Cite this article as:** Armijo-Sánchez A, Santamaría-López E, Fernández-Sánchez M, Galiano-Gutiérrez N, Mantrana-Bermejo E. Sequential-contingent strategy for fallopian tube evaluation using hysterosalpingo foam sonography: a cost analysis. *Quant Imaging Med Surg* 2024;14(1):540-547. doi: 10.21037/qims-23-816