



Received: 2015.06.01
Accepted: 2015.06.16
Published: 2015.08.29

Authors' Contribution:

- A** Study Design
- B** Data Collection
- C** Statistical Analysis
- D** Data Interpretation
- E** Manuscript Preparation
- F** Literature Search
- G** Funds Collection

The Efficacy of One Molar Contrast Material in the Evaluation of Breast Lesions with MR Imaging

Nursen Toprak^{1ABCDEF}, Ozkan Unal^{1ADE}, Serhat Avcu^{2AE}

¹ Department of Radiology, Yüzüncü Yıl University Medical Faculty, Van, Turkey

² Department of Radiology, Gazi University Medical Faculty, Ankara, Turkey

Author's address: Serhat Avcu, Department of Radiology, Gazi University Medical Faculty, Ankara, Turkey,
e-mail: serhatavcu@hotmail.com

Background:

To investigate the efficacy of 1 molar (containing 1 mol/mL gadobutrol) contrast material in the differentiation of malignant and benign breast lesions with MRI.

Material/Methods:

Thirty-seven women (age range: 22–77 years, mean: 43.7 years) with 76 breast lesions were included in this study. Dynamic post-contrast images with 0.2 mL/kg gadobutrol (Gadovist) injection were obtained in all patients. Contrast-to-noise-ratio (CNR) of the lesions, as well as their contrast enhancement patterns (ring, heterogeneous, homogenous), and perilesional increased vascularity were studied.

Results:

Fifty-six benign and 20 malignant lesions were examined histopathologically. In malignant cases, heterogeneous and peripheral enhancements were most commonly determined, whereas homogeneous enhancement was most commonly determined in benign cases. CNR was 450% in malignant lesions, and 60% in benign lesions.

Conclusions:

Type II/III contrast-time curves, ring/heterogeneous enhancement, prominent increase in CNR, and perilesional vascularity increase are important findings determining malignancy, whereas Type I curves, homogenous enhancement, a slight increase in CNR, and absence of perilesional vascularity increase support findings of benign breast lesions. By increasing CNR and providing increased perilesional vascularity, Gadovist can help in the determination of malignant breast lesions.

MeSH Keywords:

Breast • Gadolinium DTPA • Magnetic Resonance Imaging

PDF file:

<http://www.polradiol.com/abstract/index/idArt/894863>

Background

Breast cancer is the most frequent cancer type in developed countries. It comprises 26% of all cancer incidences in women, and in mortality rate it ranks second following pulmonary cancer [1].

Early diagnosis in breast cancer is the most crucial factor affecting prognosis. Correct implementation of radiological methods is significant in early diagnosis of breast cancer and treatment planning, and therefore in prognosis improvement and mortality reduction [2]. Although the gold standard in detection and diagnosis is mammography, and despite the contributions of ultrasonography (USG), which is the most significant supportive method, the desired sensitivity and specificity levels have not been

reached in the diagnosis of breast cancer [2,3]. The mammography technique has variable specificity because of overlap of tissue densities and limited contrast between malignant and benign tissues. Furthermore, almost 10% of palpable cancers may go undetected on mammography, and both mammography and USG can be difficult to interpret in patients with breast implants, dense breast parenchyma, surgical scars, or deformity [4].

This requirement results in new ways of searching; and magnetic resonance imaging (MRI) has become a diagnostic and problem-solving method that can be applied especially to selected events as it enables dynamic contrast-enhanced imaging in addition to mammography and USG in the examination of breasts [3,5]. MRI is a modality that should be under routine application in the evaluation of

multi-centricity, breast-conserving surgery, and in the discrimination of residual lesion and granulation [6–8]. Review articles have indicated that MRI may have a key role to play in the detection and diagnosis of breast cancer, and its potential as a screening tool for women with a high risk for breast cancer has been reported. Advantageous attributes of MRI are its high soft-tissue contrast, multi-planar sectioning allowing visualization of tissue close to breast implants or the chest wall, and the absence of ionizing radiation. Gadolinium-enhanced MRI has been shown to be a sensitive technique for the detection of breast cancer, although variable specificities have been reported [4].

The recommended dose of gadolinium-based contrast agent for most clinical indications is 0.1 mmol/kg of body weight, and the recommended injection rate is 2–3 mL/second. All nonspecific gadolinium-based contrast agents are available in a concentration of 0.5 molar (M) except gadobutrol (Gd-BT-DO3A; Gadovist, Bayer Schering Pharma), which is available in a concentration of 1.0 M. Recently, the 1.0 M MR contrast agent gadobutrol became the first MR contrast agent to receive approval from the European Union for contrast-enhanced MR-Angiography (CE-MRA) [9].

The sensitivity and specificity of breast MRI using different contrast materials, especially with higher doses, has not been sufficiently investigated as a way of improving imaging quality and lesion detection. The aim of this study was to investigate contrast material activity in discrimination of malignant and benign breast lesions by utilizing a higher dose of contrast material that includes 1 M/mL (0.2 mL/kg) gadobutrol in breast MRI, and to examine the morphology, signal characteristics, and enhancement dynamics of the breast lesions.

Material and Methods

Institutional Ethics Committee approval and informed consent were obtained for this prospective study. The study was performed between December 2008 and December 2009. During that period, 37 female patients with BI-RADS ≤ 3 lesions detected on clinical examination, mammography, or US were examined with dynamic contrast-enhanced breast MRI using 1 M/mL gadobutrol intravenously. The total number of lesions examined was 76. Lesions were evaluated according to their morphological characteristics and contrast-time curve graphics. On morphological analysis, the contrast-to-noise-ratio (CNR) values, contrast enhancement patterns (rim, heterogeneous, homogeneous) of lesions, and increase in vascularity around the lesions were examined, and contrast time curves of lesions were classified as Type I, Type II, and Type III.

Breast MRI examinations were performed in the prone position with a 1.5 Tesla Magnetom Symphony (Siemens, Erlangen, Germany) using a breast array coil. The gradient force of the superconductive (Niobium-Titanium) magnet was 30 mT/m, and the maximum field of view (FOV) width was 320 mm.

Axial T2-weighted fat-suppressed turbo spin echo (TSE) (TR: 4220 seconds, TE: 134 seconds, average: 1, bandwidth: 130, matrix: 256 \times 256, slice thickness: 3 mm, slice gap:

10%), and fat-suppressed T1-weighted FLASH 3D sequences and pre-contrast and dynamic post-contrast images at the axial plane (TR: 4.3 seconds, TE: 1.51 seconds, average: 1, bandwidth: 320, matrix: 264 \times 448, slice thickness: 1.2 mm, slice gap: 50%) were obtained.

1 M/mL Gadovist (contains 604.72 mg gadobutrol) was administered intravenously (IV) with an automatic syringe at 0.2 mL/kg (0.2 mmol/kg) dose, and was followed by a 20-mL saline solution flush. Axial T2-weighted fat-suppressed TSE and fat-suppressed T1-weighted FLASH 3D sequences, and pre-contrast and dynamic post-contrast images at axial plane were obtained. A dynamic study was performed as precontrast axial T1-weighted 3D FLASH sequence once, and repeated eight times in intervals of 60 seconds after contrast material injection, and a total of 9 images were acquired. After the examination, the unenhanced images were subtracted from the first enhanced images on a pixel-by-pixel basis. After MRI examination, image post-processing and analysis were performed at a workstation (Leonardo Syngo 2002B Siemens Ag Medical Solutions, Erlangen, Germany).

Assessment was performed by one radiologist. On the basis of both the morphologic features of the lesion and kinetic enhancement information, each lesion was assigned to a BI-RADS category 1–6. On the dynamic contrast-enhanced T1-weighted images, a region of interest (ROI) was positioned in the most contrast-enhancing part of the lesion, and contrast-time curves were obtained.

According to the results of the breast MRI findings, a biopsy was performed on BI-RADS 4 and 5 lesions; lesions categorized as BI-RADS 1–3 were morphologically considered benign after evaluating enhancement kinetics, and imaging methods were monitored for 6 months to 1 year. Lesions having no morphological or dimensional changes were considered benign.

CNR values were calculated with the $CNR = (SIT - SIP) / SD$ formula from signal intensity values obtained pre- and post-contrast using 0.3–0.6 cm² ROI on each lesion (SIP: signal intensity of a normal breast; SIT: signal intensity of a tumor; SD: standard deviation of the air). Perilesional vascularity increase was evaluated by comparing with the opposite breast at MIP MRI, and by considering at least one of the enhancement criteria including increase in the number of veins, increase in vein diameter, and increase in vein clarity.

Statistical analysis

In this double-blind study, calculations were made with the SPSS version 13.0 statistical package. The level of significance in statistical calculations was taken as 0.05. A chi-square test was used to define the relationship of contrast enhancement curves and morphological characteristics with histopathological results, whereas Student's t-test was used to define the relationship of the CNR of lesions with histopathological results. Diagnostic test criteria in the benign-malignant discrimination of lesions were sensitivity, specificity, positive predictive value, negative predictive value, and accuracy rate. Those diagnostic test criteria

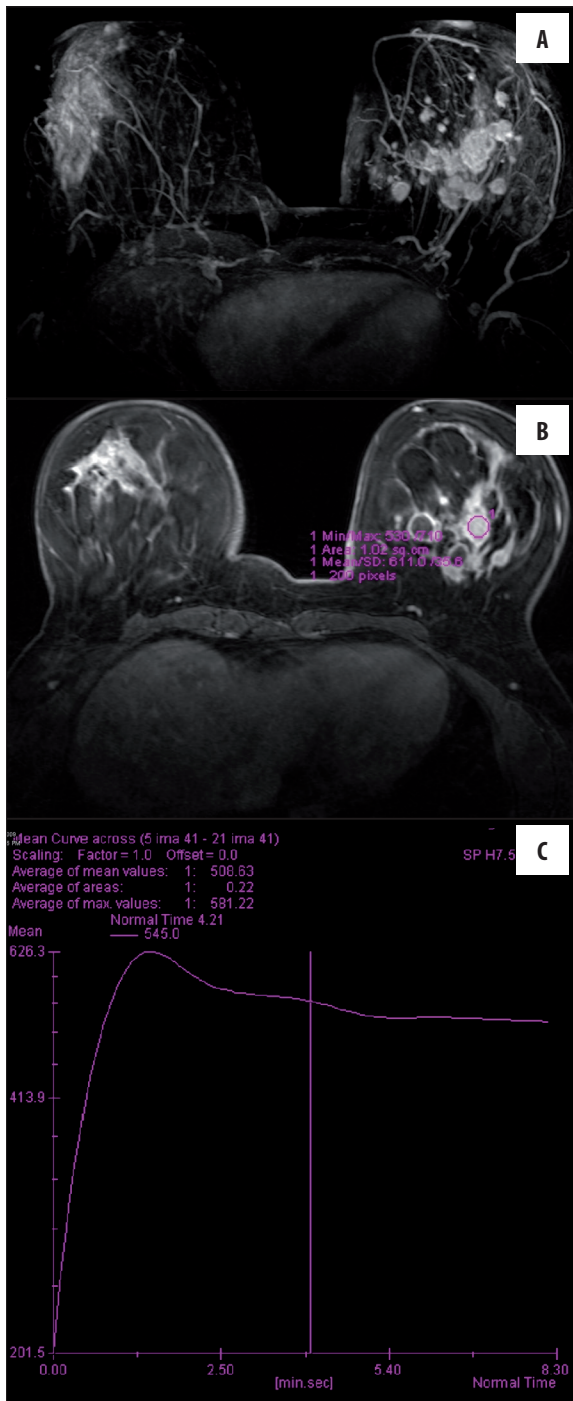


Figure 1. Left upper outer quadrant mass with satellite lesions showing heterogeneous contrast enhancement after intravenous Gadovist injection (A, B) in a 45-year-old woman. The mass displays Type III contrast-time curve (C). The histopathology of the mass revealed invasive ductal carcinoma.

were calculated for contrast curves and morphological views.

While Type I curves, homogeneous contrast, and no increase in vascularity were determined to favor benignity, Type II-III curves, heterogeneous/rim-like contrast

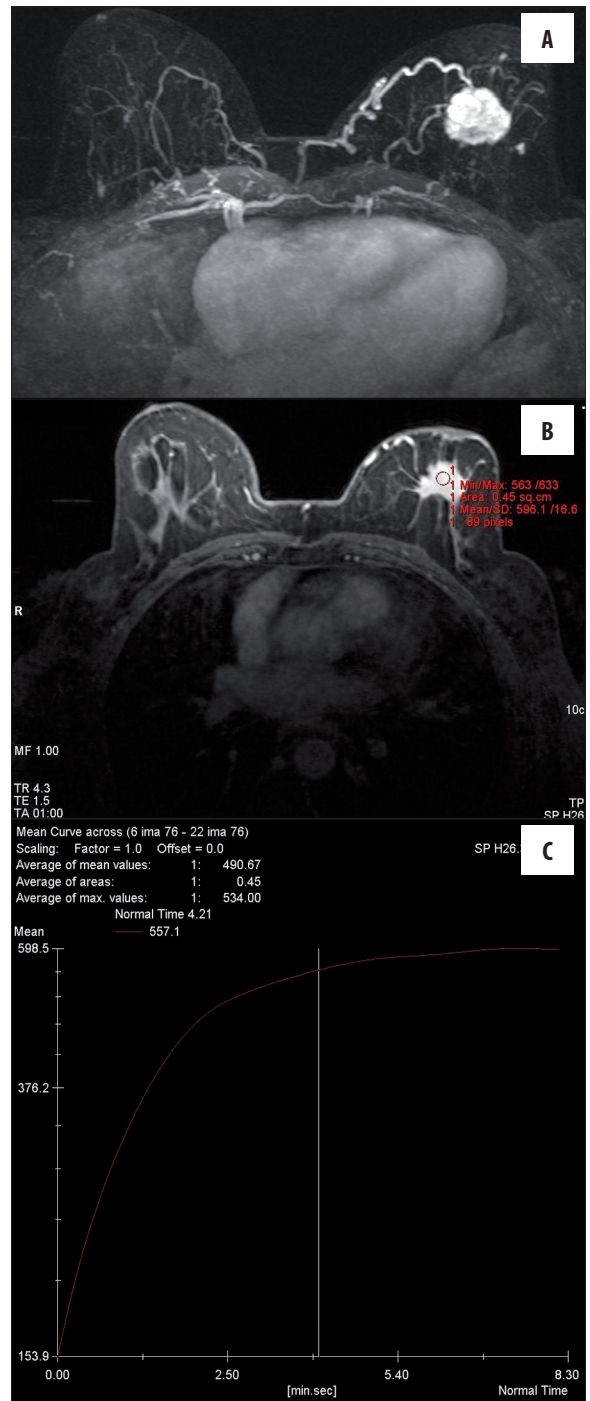


Figure 2. MIP image (A) of a 55-year-old woman showing a mass with lobulated and spiculated contour in the left breast displaying intense contrast enhancement and perilesional vascularity increase (B), with Type I contrast-time curve (C). The histopathology of the mass revealed invasive ductal carcinoma.

and vascularity increases in perilesional-side breasts were determined to favor malignancy. Diagnostic test criteria (sensitivity, specificity, negative predictive value (NPV), positive predictive value (PPV), and accuracy rate) were calculated according to these criteria.

Table 1. Patient age, lesion and satellite lesion size, and histopathological results in patients with malignant lesions.

Patient No.	Patient age	Number of lesions	Tumor size	Histopathological finding
1	38	3	3.8 cm, 1.6 cm, 1 cm	Infiltrating ductal carcinoma with satellite lesions
2	69	1	2.5 cm	Infiltrating ductal carcinoma
3	41	1	4.5 cm	Infiltrating ductal carcinoma
4	77	3	3.8 cm, 1 cm, 1.5 cm	Infiltrating ductal carcinoma with satellite lesions
5	57	1	3 cm	Infiltrating ductal carcinoma
6	55	1	3 cm	Infiltrating ductal carcinoma
7	42	1	4 cm	Infiltrating ductal carcinoma
8	45	4	1.8 cm, 1.2 cm, 1.6 cm, 1 cm	Infiltrating ductal carcinoma with satellite lesions
9	56	1	2.7 cm	Infiltrating ductal carcinoma
10	50	1	3.5 cm	Infiltrating ductal carcinoma
11	56	1	3.2 cm	Infiltrating ductal carcinoma
12	45	1	2.3 cm	Infiltrating ductal carcinoma with mucinous features

Results

In this study, a total of 76 lesions in 37 female patients were examined with breast MRI. Twenty out of 76 lesions histopathologically had malignant properties, and were diagnosed as invasive ductal carcinoma (IDC) (Figures 1, 2). Patient age, lesion and satellite lesion size, and histopathologic results in patients with malignant lesions are displayed in Table 1.

Fifty-six out of 76 lesions were considered benign. Twenty-two lesions that were considered benign also had a histopathological diagnosis. In histopathological analysis, 3 lesions were evaluated as granulomatous mastitis (Figure 3), 11 lesions as fibroadenoma (FA), 3 lesions as adenosis (benign glandular changes), 2 lesions as papilloma, 1 lesion as intramammary lymph node (IMLN), 1 lesion as fibroadenolipoma (FAL) (Figure 4), and 1 lesion as post-operative scar tissue and radiation necrosis (Figure 5).

Thirty-four other lesions whose MRI characteristics were considered to favor benignity were followed up with radiological imaging methods (5 lesions with MRI, 2 lesions with MM, 27 lesions with US). The criteria for benignity included no increment in dimension and no change in morphological characteristics of the lesions. Patient age, lesion size, and histopathologic results in patients with benign lesions are demonstrated in Table 2.

Evaluation of contrast-time curves

The results of contrast-time curves for malignant and benign lesions are shown in Tables 3, 4, and Figure 6.

Of the lesions with Type I kinetic curves in MR imaging, 31 lesions (96.9%) were benign, whereas 1 (3.1%) was malignant. Of the lesions with Type II curves, 19 (65.5%) were benign, whereas 10 (34.5%) were malignant. Of the lesions with Type III curves, 6 (40%) were benign, and 9 (60%) were malignant. According to the chi-square statistical

analysis, there was a significant relationship between contrast-time curves and histopathology ($p < 0.05$) (Table 5).

In terms of showing benignity, the sensitivity, specificity, PPV, NPV, and accuracy rate of Type I curves were 55%, 95%, 96%, 56%, and 65%, respectively. In terms of showing malignancy, the sensitivity, specificity, PPV, NPV, and accuracy rate of Type II curves were 50%, 66%, 34%, 21%, and 61%, respectively. In terms of showing malignancy, the sensitivity, specificity, PPV, NPV, and accuracy rate of Type III curves were 45%, 89%, 60%, 18%, and 77%, respectively.

Morphological evaluation – contrast enhancement pattern

In post-contrast examinations following Gadovist injection, lesions showed rim-like, heterogeneous, and homogeneous patterns of contrast enhancement. Rim-like pattern of contrast enhancement was monitored in 17 lesions. Seven of those lesions were malignant IDC events. Ten lesions were benign, and of those 5 were fat necrosis, 1 was an infected cyst, and 4 lesions were centrally-calcified FA.

Heterogeneous contrast enhancement was monitored in 23 lesions. Eight of the lesions were malignant. Fifteen lesions were benign: 3 lesions were diagnosed as granulomatous mastitis, 2 lesions as post-operative scar tissue, 3 lesions as papilloma, 1 lesion as adenosis, 4 lesions as FA, and 2 lesions as FAL.

Homogenous contrast enhancement was monitored in 36 lesions. Five of the lesions were IDC and malignant. Thirty-one lesions were benign, consisting of 6 adenosis lesions, 3 IMLNs and 22 FA lesions.

The classifications of malignant and benign lesions according to contrast enhancement patterns are given in Table 6 and Figure 7.

In terms of showing malignancy, the sensitivity, specificity, PPV, NPV, and accuracy rate of rim-like contrast

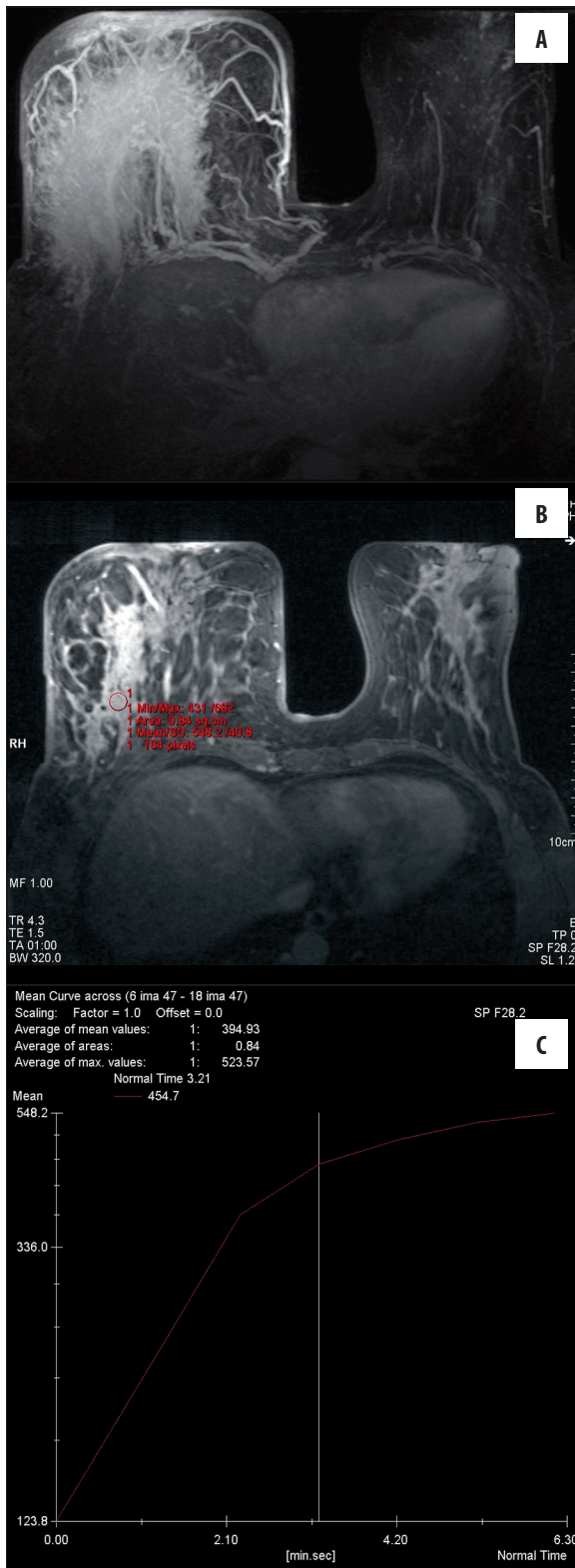


Figure 3. MIP image (A) of the enlarged right breast in a 47-year-old woman displays intense heterogeneous contrast enhancement and vascularity increase with Gadovist. Post-contrast T1-weighted image (B) shows heterogeneous enhancing fibroglandular tissue. The lesion displays Type I contrast-time curve (C). The histopathology of the lesion revealed granulomatous mastitis.

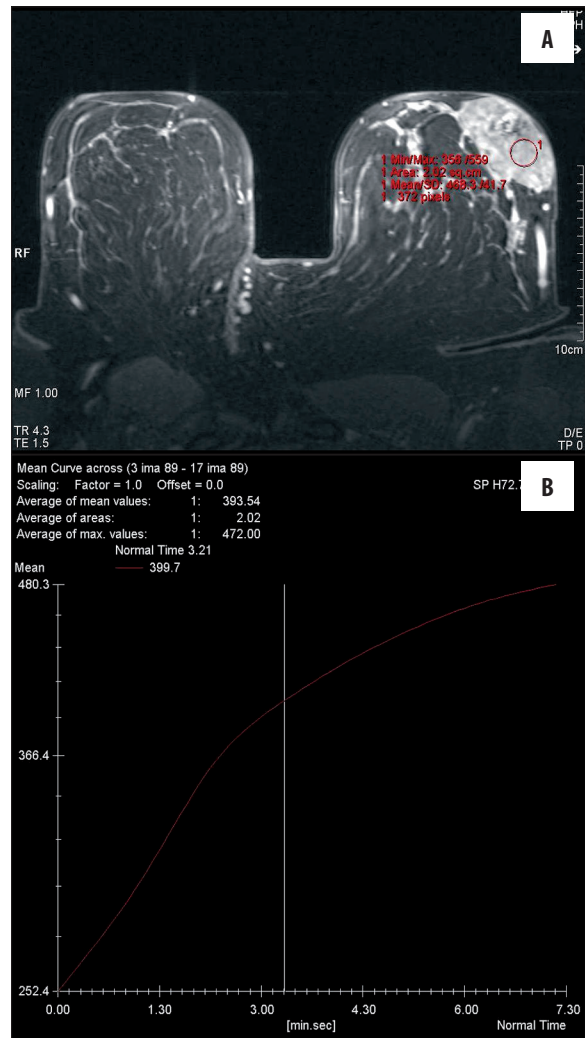


Figure 4. Post-Gadovist T1-weighted image (A) of a 37-year-old woman shows heterogeneous enhanced mass lesion in the left breast. The lesion displays Type I contrast-time curve (B). The histopathology of the lesion revealed hamartoma.

enhancement were 35%, 82%, 41%, 22%, and 69%, respectively, while those values were 40%, 73%, 34%, 22%, and 64% for heterogeneous contrast enhancement. In terms of showing benignity, the sensitivity, specificity, PPV, NPV, and accuracy rate of homogeneous contrast enhancement were 54%, 75%, 86%, 63%, and 60%, respectively.

Morphological evaluation – perilesional vascularity increase

There was increased vascularity in the breast mass region with lesions in 16 patients. Increased vascularity was monitored more clearly in MIP imaging. Eleven of the cases with increased vascularity were malignant and 5 were benign. Malignant lesions were IDC in 11 patients, while benign lesions were 2 granulomatous mastitis, 1 infected cyst, 1 post-operative scar tissue, and 1 papilloma (Table 7).

The sensitivity, specificity, PPV, NPV, and accuracy rate of increased vascularity in terms of supporting malignancy were 91%, 80%, 68%, 95%, and 83%, respectively. According to the chi-square analysis, the association between

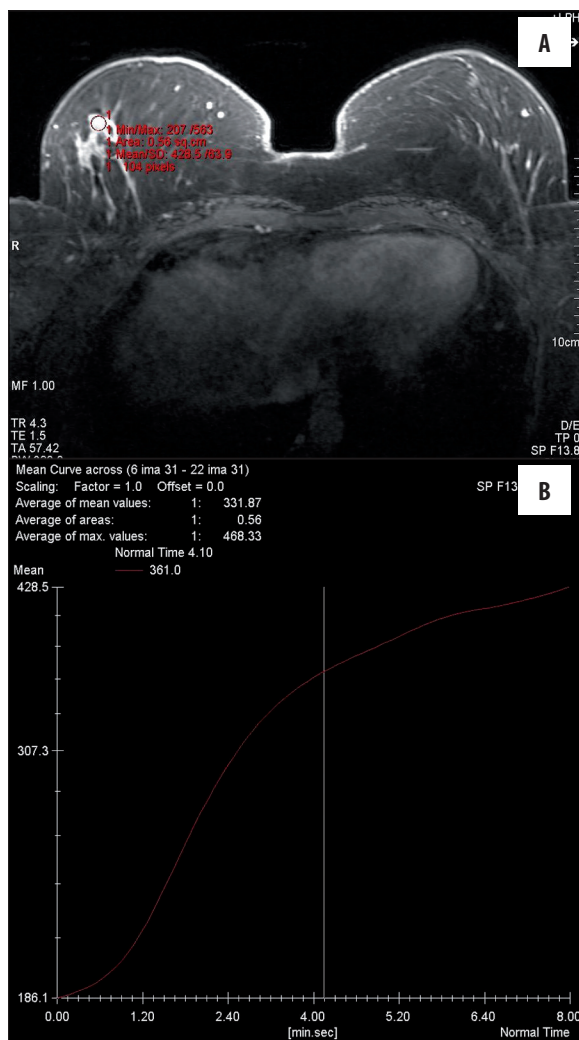


Figure 5. Post-Gadovist T1-weighted image (A) of a 35-year-old woman shows heterogeneous enhanced mass lesion with a spiculated contour in the right breast. The lesion displays Type I contrast-time curve (B). The histopathology of the lesion revealed fat necrosis.

increased vascularity and histopathological analysis was statistically significant ($p < 0.05$).

Morphological evaluation – CNR

When lesions were categorized as malignant or benign, the average increased CNR at each lesion was 60% in benign lesions, and 450% in malignant lesions. CNR of malignant lesions was significantly higher than of benign lesions according to the Student's t-test analysis.

Discussion

MRI can be used for any woman, providing additional facilities such as three-dimensional imaging and angiogenesis evaluation are available [9]. According to the latest publications, MRI is the method with the highest sensitivity for the detection of malignant breast lesions. In various publications the sensitivity has been reported as 90–95% and specificity as 37–97% [9–12].

The necessity to utilize contrast material in breast MRI is proven; however, there is no agreement on doses and types of contrast material to be used. In MRI, lesion staining depends on venous permeability, the diffusion ratio of contrast material, the content of the interstitial tumor matrix, and base and post-contrast material T1 relaxation ratios of the tissue [12,13].

In our study, we investigated the characteristics of a single 1 molar contrast material, Gadovist, for the detection and definition of breast lesions. Gadovist contrast material is generally used in central nervous system lesions, perfusion MRI and MR angiography studies. There are various studies regarding its multiple usage areas in the relevant literature; however, we have not encountered any study of its use in breast MRI.

Some Gadovist studies on its use in extramammary MRI examinations available in the literature reveal that Gadovist detects a higher number of metastatic and multiple sclerosis lesions compared to other contrast materials, and shows improvement in lesion imaging over materials with less contrast enhancement. At the same time, as it increases CNR more than other contrast materials, it enhances lesion clarity, and thus detection. With its high concentration, Gadovist is an angiogenic contrast material that enhances the signal-to-noise-ratio (SNR) of veins. We believe that these characteristics of Gadovist may increase the chance of detection of lesions at an early stage when less contrast enhancement is evident due to incomplete angiogenesis in breast lesions.

When we compared our study with the study of Kvistad et al. [14] on Omniscan, we observed that time-contrast curves did not change greatly in malignant lesion separation, yet Type II benign lesion contrast curves increased. This may be attributed to the 1 molar content of Gadovist. Gadovist includes gadolinium at a high concentration. In our study, the moving of kinetic curve separation in benign lesions to Type II by highly concentrated contrast material could be considered a disadvantage of a 1 molar contrast agent used in breast MRI.

Kuhl's [13] contrast enhancement dynamic for malignant lesions is generally agreed upon in the literature. These rates are 60% Type III, 30% Type II, and 10% Type I. However, these rates are not similar to our findings or the results of Kvistad with Omniscan. Both in our study and Kvistad's study with Omniscan, this dissimilarity is observed in Type III and Type II separation. This may be attributed to the fact that both studies utilized high doses of contrast material. Although there is limited agreement on the dose and type of contrast material to be used in breast MRI, doses of 0.1–0.2 mmol/kg have been reported [13,14]. However, the dose of contrast material in both studies is given as 0.2 mmol/kg, and while this amount is the maximum limit for 0.5 molar Omniscan, it is more than the dose amount routinely used for 1 molar Gadovist. As a result, in contrast to the literature [15], contrast enhancement of malignant lesions in both studies moved to Type II. This is considered a disadvantage for high-dose use.

Table 2. Patient age, lesion size, and histopathological results in patients with benign lesions.

Patient No.	Patient age	Number of lesions	Tumor size	Histopathological finding
1	27	2	1.5 cm, 1.6 cm	Both fat necrosis
2	47	2	5.1 cm, 2.6 cm	Both abscess in the presence of mastitis
3	38	1	3.5 cm	Infected cyst
4	44	1	1.5 cm	Fibrocystic change and adenosis
5	42	1	1 cm	Fibrocystic change and adenosis
6	23	2	2.5 cm, 1 cm	Fibroadenoma, fibrocystic change and adenosis
7	22	1	1.5 cm	Fibroadenoma
8	35	2	2.3 cm, 1.6 cm	Both fat necrosis
9	30	3	1 cm, 1.3 cm, 1.5 cm	Adenosis, adenosis, hematoma
10	39	1	1.8 cm	Fibroadenoma
11	39	1	4 cm	Mastitis
12	55	1	4.3 cm	Postoperative scar tissue
13	39	1	2 cm	Fibroadenoma
14	62	2	1 cm, 1.7 cm	Fat necrosis, adenosis
15	29	1	2 cm	Adenosis
16	57	2	0.7 cm, 0.9 cm	Intramammary lymph node, fibroadenoma
17	36	1	0.9 cm	Intramammary lymph node
18	53	1	1 cm	Intramammary lymph node
19	37	3	7 cm, 1.2 cm, 1.5 cm	Fibroadenolipoma, papilloma, papilloma
20	23	22	Range max. 3.2 cm – min. 1 cm, 4.5 cm	22 fibroadenomas, 1 fibroadenolipoma
21	56	1	2.2 cm	Fibroadenoma
22	47	1	4 cm	Postoperative scar tissue
23	27	1	1.7 cm	Papilloma
24	39	1	1.6 cm	Fibroadenoma
25	44	2	1 cm, 1.5 cm	Both fibroadenoma

Table 3. The contrast-time curve distribution of malignant lesions.

Histopathology	Type I	Type II	Type III	Total
Malignant	1 (5%)	10 (50%)	9 (45%)	20

Table 4. The contrast-time curve distribution of benign lesions.

Histopathology	Type I	Type II	Type III	Total
Benign	31 (56%)	19 (34%)	6 (10%)	56

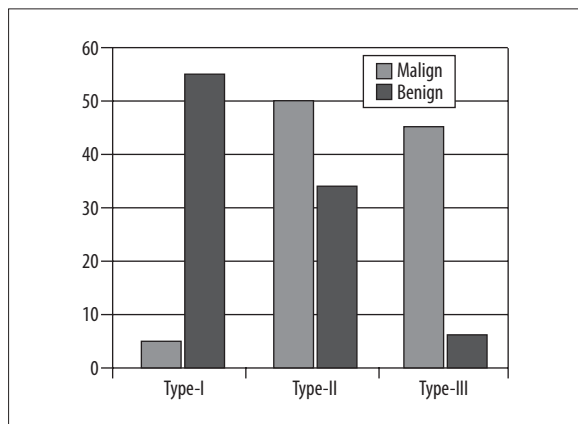


Figure 6. Contrast-time curve distribution of histopathological results

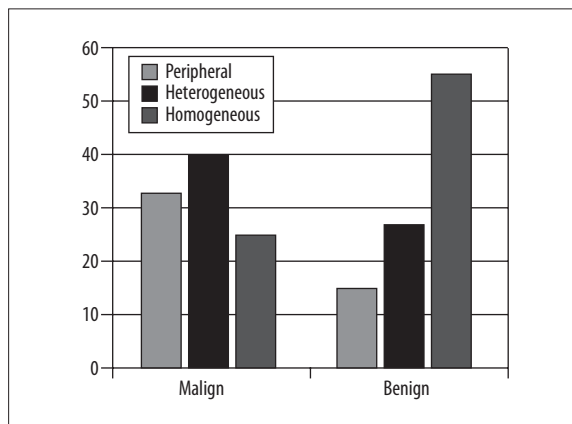


Figure 7. The distribution of malignant and benign lesions with corresponding contrast enhancement patterns

Table 5. Contrast-time curve distribution of histopathological results.

	Benign	Malignant	Total
Type I	31 (56%)	1 (5%)	32
Type II	19 (34%)	10 (50%)	29
Type III	6 (10%)	9 (45%)	15

Table 6. The enhancement characteristics of malignant and benign lesions.

	Rim	Heterogeneous	Homogeneous	Total
Malignant	7 (35%)	8 (40%)	5 (25%)	20
Benign	10 (17.8%)	15 (26.8%)	31 (55.4%)	56

Table 7. The vascularity change at the side of breast lesion with histopathological correlation.

	Malignant	Benign
Increase in vascularity	11 (91.7%)	5 (20%)
No increase in vascularity	1 (8.3%)	20 (80%)

When the sensitivity and specificity of contrast – time curves obtained with Gadovist are compared to those in the study on Magnevist by Macura et al. [16], increased specificity in Type I curves and increased sensitivity in Type II and III curves are observed. According to this result, while Type I curves are more specific to benign lesions in our study on Gadovist, Type II and III curves are more sensitive for detecting malignant lesions. However, the lower specificity of Type II curves in malignancy in our study is attributed to the more frequent appearance of Type II curves in benign lesions.

Our data indicate that contrast–time curves in breast MRI with Gadovist are more compatible with histopathology than those obtained with Magnevist. However, the disadvantage of lower specificity in Type II curves increases the possibility of false positive results for malignancy.

In breast MRI, contrast enhancement characteristics are also evaluated while examining lesions [14]. In the literature, malignancy in rim-like contrast enhancement was found to be 79%. In our study, rim-like enhancement following Gadovist injection was at PPV 41% in indicating malignancy. Rim-like contrast is a result of Type III contrast-time curves, namely the wash-out period of a lesion. In our case, malignant lesions indicated 50% Type II kinetic curves. As a result, increased heterogeneous-homogeneous contrast in malignant lesions caused lower levels of PPV than expected for rim-like contrast enhancement.

In the literature, rim-like contrast enhancement is defined as a characteristic of malignant lesions, but it can be observed in inflamed cysts, abscess foci, centrally calcified FA, and fat necrosis as well. Thus, this type of enhancement could cause false positive results [15]. One

fat necrosis event that showed higher rim-like contrast enhancement compared to the average benign lesions in our study, one infected cyst case, and FA cases were observed; this is considered another reason for lower PPV.

For homogeneously enhancing masses, PPV is defined at 93–97% for benignity. In our study, PPV was 86% when homogenous contrast enhancement indicated benignity ($p=0.059$). That result was lower than in the literature. The high dose of contrast material increased enhancement in malignant lesions and induced homogenous evaluation of morphological view in benign lesions.

In a retrospective study that compared a standard dose of Magnevist (0.1 mmol/kg) with three different doses of Multihance (gadobenate dimeglumine) (0.05, 0.1, 0.2 mmol/kg) by Sardanelli et al. [17], increased vascularity in the breast was indicative of same-side breast cancer. The sensitivity of Multihance for same-side breast cancer was found to be 88%, specificity 82%, PPV 94%, NPV 70%, and accuracy rate 87%. No variation was observed for comparing different doses of Multihance. However, it is agreed that vascular score rates obtained with Multihance were superior when compared to 0.1 mmol/kg Magnevist [17].

In our study with high-dose Gadovist, the detection of same-side breast cancer was increased; we observed similar sensitivity and specificity when comparing vascularity indicating breast cancer to values reported in the literature. In perilesional vascularity evaluation, Gadovist is an effective angiographic contrast material with similar characteristics to Multihance whose T1 relaxivity is higher than for all other MRI contrast materials.

In a study that compared Multihance with Magnevist by Pediconi et al. [18] on CNR in breast MRI, the CNR obtained with Multihance was significantly higher than the CNR obtained with Magnevist. This study indicated that breast MRI carried out with Multihance (with a higher T1 relaxivity) has higher sensitivity in detecting lesions than material with less enhanced contrast.

Although we did not come across any study that indicates CNR dissimilarity between malignant and benign lesions in the literature, post-injection increased mean CNR in our study was 60% in benign lesions, but 450% in malignant lesions, and CNR of malignant lesions was significantly higher than that of benign lesions. Gadovist has the highest T1 relaxivity among extracellular contrast materials. This suggests that an increase in CNR with Gadovist increases the likelihood of detecting mass lesions and malignant lesions at its early stages. This may be an advantage of high-dose use of contrast material.

In a study with a high dose (0.2 mL/kg) of Gadovist, sensitivity of contrasting dynamic and morphological criteria in detecting malignancy is 95%, and specificity is 55.4% ($p=0.001$). In the literature, Kuhl et al. [13] observed the sensitivity of contrast enhancement dynamic and morphology in detecting malignancy at 91% and specificity at 83% in MRI in a study that considers Type I pattern as benign lesions, Type III pattern as malignant, and Type II both as benign and malignant.

When we compare Kuhl's data with our study, sensitivity was increased with a high dose of contrast material, giving the opportunity to detect small lesions and lesser contrast-enhancing lesions at an early stage. However, the rate of specificity is decreased, so the rate of false positives in malignancy is increased. Furthermore, according to a study that compares Multihance at higher doses, by Carbonaro et al. in breast MRI, there was no gain in sensitivity with a double dose (0.2 mmol/kg). When different doses of gadobenate dimeglumine were compared, the number of false-positives was greater with the double dose than with the single dose of gadobenate dimeglumine. According to this study, the single dose of gadobenate dimeglumine was optimal for gadolinium-enhanced breast MRI [19].

Gadovist is an MRI contrast material that contains 1 molar gadolinium component with higher T1 relaxivity than that of other extracellular contrast materials. Detecting small and less contrast-enhanced lesions is an advantage over other contrast materials. Its use in breast MRI has not been reported before. Our study is the first study on the use of high-molar contrast material in the breast. According to the results of our study, concurrent evaluation of post-injection contrast curves and morphologies of Gadovist enhances the possibility of detecting malignant lesions with increased levels of sensitivity at an early stage when angiogenesis is incomplete and lesions are small. This could reduce the mortality rates with early diagnosis of breast lesions. In addition, following the detection of primary tumor tissue, it is important to detect less contrast-enhanced satellite lesions to plan breast-conservation treatment. We agree that high sensitivity levels in our study with Gadovist and contrast material at high concentration are advantageous here. However, specificity levels lower than in the literature data [18] may increase false positive results. This results in unnecessary biopsies.

We have not encountered any literature data on the use of CNR levels in the separation of malignant and benign breast lesions. According to the results of our study, CNR is a contributory diagnostic finding, and is a criterion that should be taken into consideration in addition to evident increases in malignant lesions, contrast curves, and types of contrast enhancement (rim-like, heterogeneous, homogeneous), and lesion evaluation.

Gadovist indicates increased vascularity in cancerous breast in MRI; and is an effective contrast material in defining whether lesions in cancer cases with susceptible morphology and contrast enhancement dynamics are malignant or benign. Due to the angiographic impact of high dosage, we obtained high-quality vascular images in MIP MRI. High doses of contrast material may enable the detection of tumor tissue *in situ* by revealing neoangiogenesis surrounding cancer focal points at an early stage, especially when tumor tissue cannot be clearly identified [20]. In our study, we observed that high doses significantly affected this parameter.

Conclusions

Gadovist is a sensitive contrast material that can be used with increased sensitivity levels in contrast curves,

morphological evaluation and in evaluating increased vascularity. However, it may result in increased possibility of false positive levels by reducing specificity. Increased CNR in malignant lesions and indications of increased vascularity provide diagnostic contribution. In addition, in order to minimize false positive results, reduce costs and perform breast MRI by administering a lower dose of contrast material to the patient, we need to evaluate if the same effects can be observed with lower doses of Gadovist (0.1 mL/kg).

Moreover, increased CNR levels in malignant lesions are a finding that can be utilized in breast MRI; however, this should also be validated with studies on different contrast materials in a wider series.

Conflicts of interest

The authors declare that they have no conflicts of interest.

References:

1. Hall FM, Storella JM, Silverstone DZ, Wyshak G: Non-palpable breast lesions: recommendation for biopsy based on suspicion of breast carcinoma at mammography. *Radiology*, 1988; 167: 353-58
2. Tabàr L, Fagerberg G, Duffy SW et al: Update of the Swedish two county program of mamographic screening for breast cancer. *Radiol Clin North Am*, 1992; 30: 187-210
3. Leung JW: Screening mammography reduces morbidity of breast cancer treatment. *Am J Roentgenol*, 2005; 184: 1508-9
4. Knopp MV, Bourne MW, Sardanelli F et al: Gadobenate dimeglumine - enhanced MRI of the breast: analysis of dose response and comparison with gadopentetate dimeglumine. *Am J Roentgenol*, 2003; 181: 663-76
5. Rankin SC: MRI of the breast. *Br J Radiol*, 2000; 73: 806-18
6. Szabó BK, Aspelin P, Wiberg MK, Boné B: Dynamic MR imaging of the breast analysis of kinetic and morphologic diagnostic criteria. *Acta Radiol*, 2003; 44: 379-86
7. Segel MC, Paulus DD, Hortobagyi GN: Advanced primary breast cancer: assessment at mammography of response to induction chemotherapy. *Radiology*, 1988; 169: 49-54
8. Kolb TM, Lichy J, Newhouse JH: Comparison of the performance of screening mammography, physical examination and breast US and evaluation of factors that influence them: an analysis of 27,825 patient evaluations. *Radiology*, 2002; 225: 165-75
9. Fink C, Puderbach M, Ley S et al: Intraindividual comparison of 1.0 M gadobutrol and 0.5 M gadopentetate dimeglumine for time-resolved contrast-enhanced three-dimensional magnetic resonance angiography of the upper torso. *J. Magn Reson Imaging*, 2005; 22: 286-90
10. Lee CH: Problem solving MR imaging of the breast. *Radiol Clin North Am*, 2004; 42: 919-34
11. Heywang-Köbrunner SH, Viehweg P, Heinig A, Küchler C: Contrast-enhanced MRI of the breast: accuracy, value, controversies, solutions. *Eur J Radiol*, 1997; 24: 94-108
12. Kuhl CK: Concepts for differential diagnosis in breast MR imaging. *Magn Reson Imaging Clin N Am*, 2006; 14: 305-28
13. Kuhl CK, Mielcareck P, Klaschik S et al: Dynamic breast MR imaging: are signal intensity time course data useful for differential diagnosis of enhancing lesions? *Radiology*, 1999; 211: 101-10
14. Kvistad KA, Rydland J, Vainio J et al: Breast lesions: evaluation with dynamic contrast-enhanced T1-weighted MR imaging and with T2*-weighted first-pass perfusion MR imaging. *Radiology*, 2000; 216: 545-53
15. Buadu LD, Murakami J, Murayama S et al: Breast lesions: correlation of contrast medium enhancement patterns on MR images with histopathologic findings and tumor angiogenesis. *Radiology*, 1996; 200: 639-49
16. Macura KJ, Ouwerkerk R, Jacobs MA, Bluemke DA: Patterns of enhancement on breast MR images: interpretation and imaging pitfalls. *Radiographics*, 2006; 26: 1719-34
17. Sardanelli F, Iozzelli A, Fausto A et al: Gadobenate Dimeglumine - enhanced MR imaging breast vascular maps: association between invasive cancer and ipsilateral increased vascularity. *Radiology*, 2005; 235: 791-97
18. Pediconi F, Catalano C, Occhiato R et al: Breast lesion detection and characterization at contrast-enhanced MR mammography: Gadobenate Dimeglumine versus Gadopentetate Dimeglumine. *Radiology*, 2005; 237: 45-56
19. Carbonaro LA, Pediconi F, Verardi N et al: Breast MRI using a high-relaxivity contrast agent: an overview. *Am J Roentgenol*, 2011; 196: 942-55
20. Morris EA: Breast MR imaging lexicon updated. *Magn Reson Imaging Clin N Am*, 2006; 14: 293-303