

# Ultrasound-Guided Unification of Noncommunicating Uterine Cavities

Bijoy T. Mulleserill, MD, Daniel A. Dumesic, MD, Mark A. Damario, MD, Donna R. Session, MD

## ABSTRACT

**Background:** The benefits of ultrasound-guided hysteroscopic metroplasty have been well described in the management of the partial septate uterus. The use of ultrasonography at the time of hysteroscopy provides visualization of the intrauterine instruments within the uterine cavity. This report describes a case where ultrasound-guidance was used to enter a noncommunicating uterine cavity hysteroscopically.

**Methods:** A 22-year-old female after her third miscarriage experienced worsening dysmenorrhea. The patient underwent a laparoscopy and hysteroscopy to further evaluate the cause of pelvic pain and to treat the Müllerian anomaly. Under ultrasound-guidance, the 2 uterine cavities were unified by hysteroscopic metroplasty.

**Results:** Postoperative sonohysterography demonstrated unification of the 2 cavities.

**Conclusions:** This unique application of ultrasound-guidance in hysteroscopic surgery may aid the surgeon in entering a noncommunicating uterine cavity.

**Key Words:** Müllerian anomalies, Ultrasound-guidance, Hysteroscopy, Recurrent pregnancy loss.

## INTRODUCTION

Müllerian anomalies occur in approximately 1 in 400 women<sup>1</sup> and have been associated with reproductive failure and pelvic pain from endometriosis and hematometra. Noncommunicating uterine cavities pose a challenge to the surgeon performing a hysteroscopic metroplasty because the position of the hysteroscope in relation to the cervix and ipsilateral uterine cavity is not known. Ultrasound-guidance may aid the surgeon in the treatment of this specific type of anomaly.

## CASE REPORT

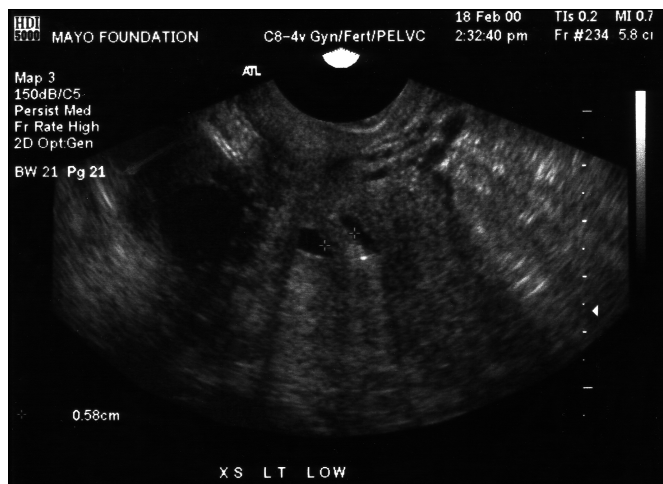
This report was completed after approval by the institutional review board. A 22-year-old G3 P0030 female with a history of 3 consecutive pregnancy losses presented with secondary dysmenorrhea. The past surgical history was significant for a laparoscopy performed by the patient's local physician after a Müllerian anomaly was suspected at the time of a miscarriage. The laparoscopy revealed a heart-shaped outer appearance of the uterus. Hysteroscopy performed at the same surgery revealed 2 uterine cavities with 2 tubal ostia separated by a septum. A pelvic examination showed 2 cervical ostia. An MRI revealed complete duplication of the endometrial canal with normal kidneys and bladder. Sonohysterography cannulating both cervical ostia documented noncommunicating right and left uterine cavities. The septal thickness varied from 5.8 mm near the internal cervical os to 8.6 mm at the fundus (**Figure 1**). The uterine cavities deviated laterally at the fundus with a normal myometrial thickness.

Laparoscopy and hysteroscopy were performed with the patient under general anesthesia. The urinary bladder was distended with a triple lumen catheter. A speculum was placed in the vagina, and the 2 cervical ostia were visualized. The right cervix was grasped with a single tooth tenaculum. A uterine manipulator (Kronner Medical Manufacturing, Cooper Surgical, Shelton, CT) was placed in the left uterine canal and indigo carmine was instilled. The right cervix was dilated to admit a 22 F operative hysteroscope (Karl Storz, Endoscopy America Inc, Culver City, CA) through which the right uterine cavity was visualized and the right tubal ostia identified.

Department of Obstetrics and Gynecology, Mayo Clinic, Rochester, Minnesota, USA (all authors).

Address reprint requests to: Donna R. Session, MD, Division of Reproductive Endocrinology and Infertility, Department of Obstetrics and Gynecology, Mayo Clinic, 200 First Street SW, Rochester, MN 55905, USA. Telephone: 507 266 3845, Fax: 507 284 1774, E-mail: session.donna@mayo.edu

© 2003 by JSLS, *Journal of the Society of Laparoendoscopic Surgeons*. Published by the Society of Laparoendoscopic Surgeons, Inc.

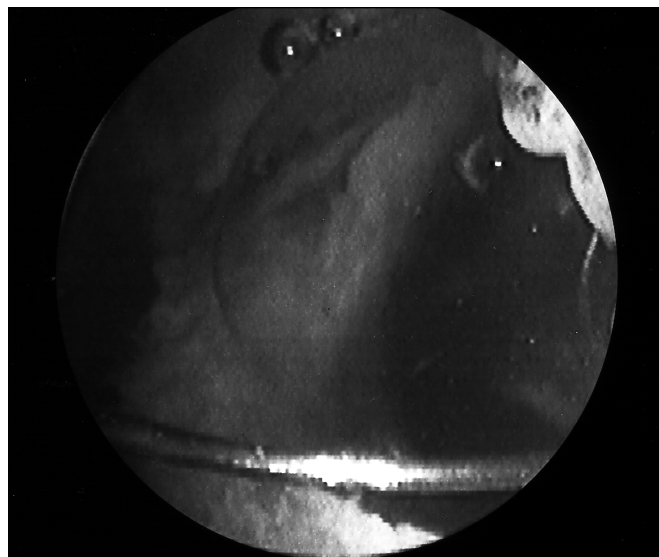


**Figure 1.** Preoperative sonohysterographic image of the 2 uterine cavities.

Under transabdominal ultrasound-guidance (ATL HDI 5000 Ultrasound System, Bothell, WA), the wall between the 2 uterine cavities was incised at its narrowest point above the internal cervical os with a resectoscope until indigo carmine overflowed into the right-sided cavity (**Figure 2**). The incision was extended to the fundus and the internal os. A concomitant laparoscopy revealed a heart-shaped uterus, normal tubes, and ovaries. Minimal endometriosis was identified on the right uterosacral ligament and left ovary, which was treated with a laser. Chromopertubation revealed bilateral patency of the fallopian tubes. A balloon uterine stent (Cook OB/GYN, Spencer, IN) was placed inside the uterus, instilled with 2.5 cc of saline, and left in place for 1 week. Postoperative sonohysterography performed a few months after the surgery revealed an arcuate uterine cavity.

## DISCUSSION

The uterus and cervix are derived embryologically from paired Müllerian ducts that fuse medially to form the uterine isthmus and cervix. The fundal portion of the uterus is created by rapid proliferation of cells from the medial walls of the ducts into a septum followed by resorption. Anomalies of the uterus result from abnormal fusion of the Müllerian ducts or from failure of absorption of the septum. This patient's anomaly consisted of an externally divided fundus, a well-formed septum, and cervical



**Figure 2.** Hysteroscopic view at resection of the uterine septum. The image was taken immediately after the ipsilateral uterine cavity was entered in the lower uterine segment. The septum is identified in the midline.

duplication. Thompson et al<sup>2</sup> noted at the time of surgery that in 5 out of 12 cases of double uteri, the uteri divided externally with a well-formed septum internally. Thompson et al<sup>2</sup> did not report the incidence of cervical duplication in this series; however, several case reports have described cervical duplication with or without a uterine or vaginal septum.<sup>3-6</sup> Although patients with double uteri may have normal reproductive outcomes, studies have demonstrated improved outcomes after correction when a history of pregnancy complications exists.<sup>7-10</sup>

Since Ruge<sup>11</sup> reported a successful pregnancy after removal of a septum in 1884, many procedures have been described for the treatment of Müllerian anomalies. Alternative methods to resect the septum have been described by Strassmann,<sup>12</sup> Tompkins,<sup>13</sup> and Jones<sup>8</sup> with numerous modifications.<sup>14</sup> The surgical management of Müllerian anomalies has evolved since the first descriptions, being modified due to evolving techniques. The choice of technique is influenced by vascularity of the incision, trauma to remaining myometrium, and soundness of the uterine scar.<sup>7,14</sup> Theoretically, a minimal amount of myometrial tissue should be removed with the repair. Hysteroscopic metroplasty has the benefits of

minimal myometrial tissue disruption and outpatient care. The benefits of ultrasound-guided hysteroscopic metroplasty have been well described for a partially septate uterus.<sup>15</sup>

The use of ultrasonography at the time of intrauterine surgery provides visualization of the intrauterine instruments as well as the myometrium and septum. In this case, ultrasound identified the area of the septum to incise hysteroscopically. The area initially incised was the narrowest width above the internal os of the cervix. The internal cervical os was identified sonographically at the angle of the cervix with the uterine body.

Although a small series did not find a high risk of cervical incompetence with resection of the cervical septum,<sup>16</sup> the theoretical risk of cervical incompetence remains.<sup>17</sup> In addition, in this patient, unification of the cervix would have been technically difficult due to the wide separation of the ostia. Alternatively, this procedure could be performed blindly with the guidance of a uterine sound or cervical dilator; however, the direction of the resection and relationship to the cervix is less obvious than with ultrasound. In summary, the use of ultrasound may aid the surgeon in entering a noncommunicating uterine horn during a hysteroscopic metroplasty.

**References:**

1. Green LK, Harris RE. Uterine anomalies. Frequency of diagnosis and associated obstetrical complications. *Obstet Gynecol.* 1976;147:427-429.
2. Thompson JP, Smith RA, Welch JS. Reproductive ability after metroplasty. *Obstet Gynecol.* 1966;28:363-368.
3. Giraldo JL, Habana A, Duleba AJ, Dokras A. Septate uterus associated with cervical duplication and vaginal septum. *J Am Assoc Gynecol Laparosc.* 2000;7:277-279.
4. Lev-Toaff AS, Kim SS, Toaff ME. Communicating septate uterus with double cervix: a rare malformation. *Obstet Gynecol.* 1992;79:828-830.
5. Tavassoli F. Unusual uterine malformation. Double cervix with single corpus and single vagina. *Obstet Gynecol.* 1977;49: 366-369.

6. Candiani M, Busacca M, Natale A, Sambruni I. Bicervical uterus and septate vagina: report of a previously undescribed Müllerian anomaly. *Hum Reprod.* 1996;11:218-219.
7. Rock JA, Jones HW Jr. The clinical management of the double uterus. *Fertil Steril.* 1977;28:798-806.
8. Jones HW Jr, Jones GES. Double uterus as an etiological factor for repeated abortion, indication for surgical repair. *Am J Obstet Gynecol.* 1953;65:325-339.
9. Jones HW Jr, Wheelless CR. Salvage of the reproductive potential of women with anomalous development of the Müllerian ducts. *Am J Obstet Gynecol.* 1969;104:348-364.
10. Steinberg W. Strassmann's metroplasty with management of bipartite uterus causing sterility or habitual abortion. *Obstet Gynecol Survey.* 1955;10:400-430.
11. Ruge P. Fall von Schwangerschaft bei Uterus Septus. *Z Geburtshilfe Gynaekol.* 1884;10:141-143.
12. Strassmann P. Die operative Vereinigung eines doppletten uterus. *Zentralbl Gynaekol.* 1907;43:1322-1338.
13. Tompkins P. Comments on the bicornuate uterus and twinning. *Surg Clin North Am.* 1962;42:1049-1062.
14. Jones HW Jr, Delfs MD, Jones GES. Reproductive difficulties in double uterus: the place of plastic reconstruction. *Am J Obstet Gynecol.* 1956;72:865-883.
15. Dabirashrafi H, Mohamad K, Moghadami-Tabrizi N. Three-contrast method hysteroscopy: the use of real-time ultrasonography for monitoring intrauterine operations. *Fertil Steril.* 1992; 57:450-452.
16. Vercellini P, Ragni G, Trespidi L, Oldani S, Panazza S, Crosignani PG. A modified technique for correction of the complete septate uterus. *Acta Obstet Gynecol Scand.* 1994;73:425-428.
17. Rock JA, Roberts CP, Hesla JS. Hysteroscopic metroplasty of the class Va uterus with preservation of the cervical septum. *Fertil Steril.* 1999;72:942-945.

---

Disclosure: No relevant financial support or conflict of interest by any author or reviewer exists.