

Available online at [www.sciencedirect.com](http://www.sciencedirect.com)

ScienceDirect

journal homepage: [www.elsevier.com/locate/ihj](http://www.elsevier.com/locate/ihj)

## Case Report

# Device closure of patent ductus arteriosus in interrupted inferior vena cava



Neeraj Aggarwal\*, Mridul Agarwal, Raja Joshi, Reena K. Joshi

Department of Pediatric Cardiac Sciences, Sir Ganga Ram Hospital, New Delhi, India

## ARTICLE INFO

## Article history:

Received 7 August 2015

Accepted 8 September 2015

Available online 18 January 2016

## Keywords:

Device

Interrupted IVC

PDA

Transjugular

Vascular access

## ABSTRACT

**Introduction:** A 3-year-old child, weighing 8 kg, presented with patent ductus arteriosus (PDA) and interrupted inferior vena cava (IVC). The patient underwent successful PDA device closure via transjugular route after failing attempt at femoral venous route.

**Case summary:** PDA device closure was attempted via femoral venous route but could not be accomplished due to difficult curves to negotiate. Following this, PDA could be closed by device from jugular venous route with ease.

**Discussion:** Interrupted IVC poses challenges for PDA device closure and various alternative routes are described like internal jugular, transhepatic, or femoral venous – azygous route. Our case describes difficulties associated with femoral venous route and advantages of jugular venous route in such cases.

**Conclusion:** Internal jugular access is a safe and feasible method of PDA device closure in cases of interrupted IVC even in smaller children.

© 2016 Published by Elsevier B.V. on behalf of Cardiological Society of India.

## 1. Introduction

Device closure is an established method for treatment of PDA and mostly femoral venous access is used to cross and deploy the device. Presence of interrupted IVC hinders the direct access to PDA and presents technical challenges for the operators. We present a case to compare the different approaches for PDA device closure in presence of interrupted IVC.

## 2. Case summary

This is a 3-year-old female child, weighing 8 kg, who was having recurrent chest infections and failure to thrive. Echo

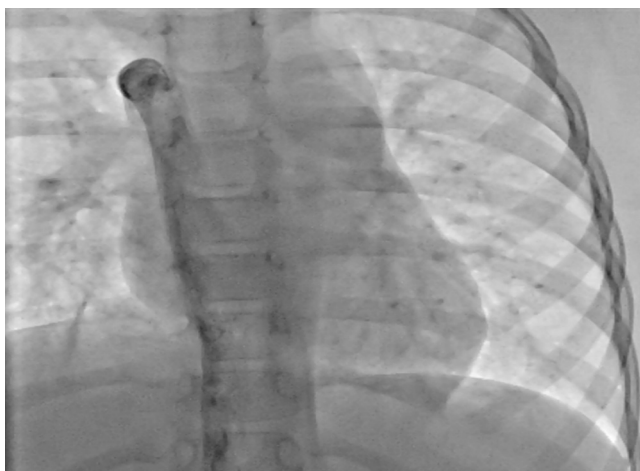evaluation showed interrupted inferior vena cava (IVC), a 3 mm patent ductus arteriosus (PDA) with left to right shunt, peak gradient of 80 mmHg along with dilated left atria and left ventricle. She was planned for PDA device closure after consent. Plan was to first confirm IVC interruption through femoral vein injection and close the PDA through IVC-azygous route. Backup plan was to go through internal jugular route, under general anesthesia if required, considering the small age of child. Femoral venous angiogram confirmed IVC interruption (Fig. 1). Descending Aortogram showed a 3 mm PDA with 6 mm Ampulla. First attempt was through IVC-azygous route and PDA was crossed by 5 French multipurpose catheter (MP catheter) and a j tip .025 terumo wire which was snared through femoral artery to give support to catheter (Fig. 2). A super stiff wire was passed through MP catheter and 6 French

\* Corresponding author.

E-mail address: [dmeeraj\\_12@yahoo.co.in](mailto:dmeeraj_12@yahoo.co.in) (N. Aggarwal).

<http://dx.doi.org/10.1016/j.ihj.2015.09.015>

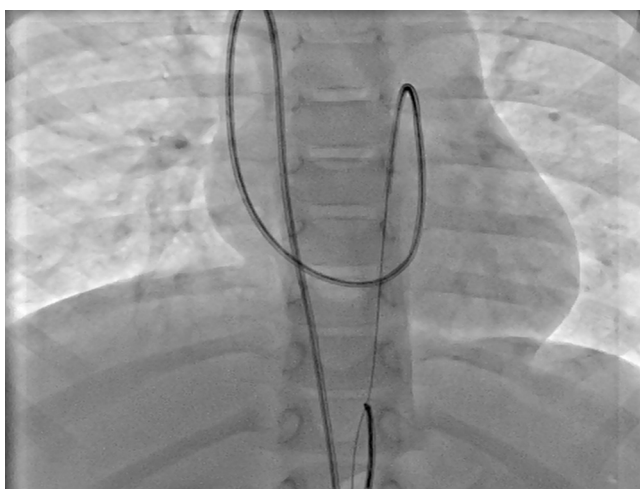
0019-4832/© 2016 Published by Elsevier B.V. on behalf of Cardiological Society of India.



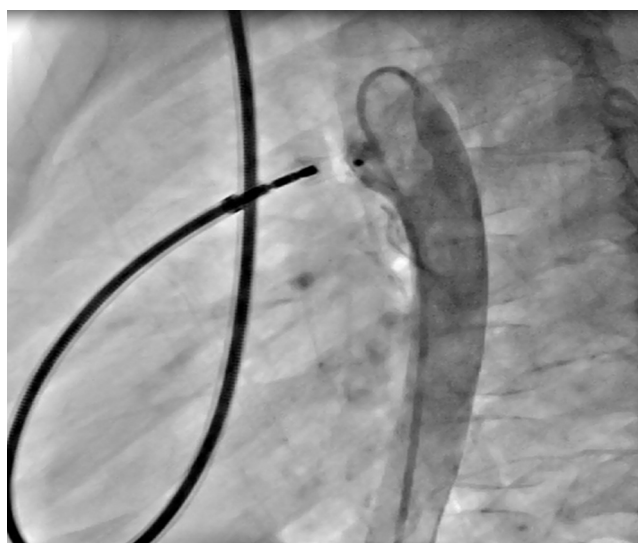
**Fig. 1 – Femoral vein hand injection in anteroposterior view showing interruption of inferior vena cava with azygous continuation.**

Amplatz delivery sheath was passed over super stiff wire. This was a difficult track for a delivery sheath, passing at 2 angulations, first at azygous – Superior vena cava (SVC) junction and second at right ventricular outflow tract to PDA. Delivery sheath was difficult to negotiate at PDA and a snare was used to pull the sheath into descending aorta. A 6/4 mm device was passed through the delivery sheath and aortic end opened in the descending aorta and the snare was released. While pulling the delivery system from descending aorta to PDA, the control was very poor due to a curve at IVC-azygous route with stretching of right atria, leading to hemodynamic instability and device could not be deployed.

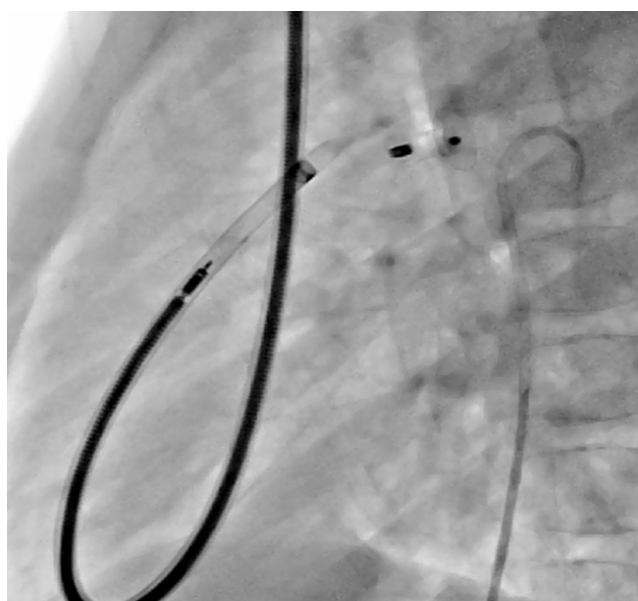
So the operators decided to go through Internal jugular access. A 5 F MP catheter was passed through PDA and then 6 F delivery sheath was used to cross the PDA. Delivery sheath



**Fig. 2 – Fluoroscopy showing a multipurpose catheter course as passing through interrupted IVC azygous route to RA and then crossing the PDA. Terumo wire is also seen which was snared through femoral arterial route.**



**Fig. 3 – Descending aortogram showing device in situ, with no residual shunt across PDA, connected to delivery cable via internal jugular route.**



**Fig. 4 – Fluoroscopy showing PDA device in situ after release and delivery cable being pulled into delivery sheath.**

was passed over the super stiff wire, crossing the PDA was easy, and the manoeuvrability was good. The device was deployed under Fluoroscopic guidance without much trouble (Figs. 3 and 4). No Thrombus was noted in internal jugular vein or SVC on follow-up Doppler study after 7 days.

### 3. Discussion

PDA device closure via femoral venous access is considered a standard risk-free procedure with high success rate.

Challenges arise in cases of variable PDA anatomy, variable systemic venous anomalies, and smaller weight of patients. Interrupted IVC/congenital stenosis is reported as an uncommon anomaly with an incidence of 0.15% in a study based on abdominal computed tomography examinations.<sup>1</sup> This is mostly associated with left isomerism and complex congenital heart diseases.

Presence of interrupted IVC poses technical challenges and successful PDA device closure in interrupted IVC is described both by femoral venous routes and by internal jugular routes<sup>2,3</sup> but to our knowledge, the comparison between these two methods is not described. Femoral venous route may be associated with kinking of catheters and delivery sheath, and failure to advance the delivery sheath.<sup>4</sup> Jugular venous route may limit the sheath size and may be dangerous in already heparinised patients. Other access option is to use transhepatic route but needs help of an interventional radiologist, is more invasive, and experience with this technique is also limited. Use of ADO 11 via femoral artery is also reported to be convenient and easy in experienced hands.<sup>5</sup>

We planned to close it first by femoral venous route and not by internal jugular route as we had already got the femoral venous access, it allows for larger delivery sheath if needed, and transjugular access might have needed general anaesthesia considering small weight of the child. Smallest child reported to undergo PDA device closure via transjugular route is 19 month old where pseudo-interruption of IVC was noted.<sup>6</sup>

The formation of arterio venous loop through femoral venous route is described with successful closure, but in our case, it was not successful due to stretch at azygous-SVC level while pulling the delivery sheath across PDA. Also, it was difficult to advance the sheath over the super stiff wire.

We found internal jugular route convenient and safe in terms of crossing the PDA and device deployment, as it significantly avoided the azygous-SVC loop.

---

#### 4. Conclusion

In cases of Interrupted IVC, Internal Jugular route is a feasible and safe method even in a small child and may prove easier compared to IVC-azygous route for PDA device closure, due to fewer curves to negotiate and better control on delivery of device.

---

#### Conflicts of interest

The authors have none to declare.

---

#### REFERENCES

1. Koc Z, Oguzkurt L. Interruption or congenital stenosis of the inferior vena cava: prevalence, imaging, and clinical findings. *Eur J Radiol.* 2007;62:257-266.
2. Akhtar S, Samad SM, Atiq M. Tran catheter closure of a patent ductus arteriosus in a patient with an anomalous inferior vena cava. *Pediatr Cardiol.* 2010;31:1093-1095.
3. Patel NH, Madan TH, Panchal AM, Thakkar BM. Percutaneous closure of patent ductus arteriosus via internal jugular vein in patient with interrupted inferior vena cava. *Ann Pediatr Cardiol.* 2009;2:162-164.
4. Tefera E, Bermudez-Cañete R. Percutaneous closure of patent ductus arteriosus in interrupted inferior caval vein through femoral vein approach. *Ann Pediatr Card.* 2014;7:55-57.
5. Koh GT, Mokhtar SA, Hamzah A, Kaur J. Transcatheter closure of patent ductus arteriosus and interruption of inferior vena cava with azygos continuation using an Amplatzer duct occluder II. *Ann Pediatr Cardiol.* 2009;2:159-161.
6. Subramanian V, Mahadevan KK, Sivasubramonian S, Tharakan J. Pseudo interruption of the inferior vena cava complicating the device closure of patent ductus arteriosus: case report and short review of venous system embryology. *Ann Pediatr Card.* 2014;7:64-66.