



Contents lists available at ScienceDirect

# Indian Pacing and Electrophysiology Journal

journal homepage: [www.elsevier.com/locate/IPEJ](http://www.elsevier.com/locate/IPEJ)

## An unexpected complication of intracardiac device implantation: Contralateral pneumothorax and pneumopericardium

Nitin Kumar Parashar<sup>a</sup>, Siddharthan Deepti<sup>a,\*</sup>, Rakesh Yadav<sup>a</sup>, Mumun Sinha<sup>b</sup>, Venkatakrishnan Ramakumar<sup>a</sup>

<sup>a</sup> Department of Cardiology and Cardiovascular Radiology and Endovascular Interventions, Cardiothoracic Sciences Center, All India Institute of Medical Sciences, Ansari Nagar, New Delhi, India

<sup>b</sup> Cardiovascular Radiology and Endovascular Interventions, Cardiothoracic Sciences Center, All India Institute of Medical Sciences, Ansari Nagar, New Delhi, India

### ARTICLE INFO

#### Article history:

Received 18 February 2019

Received in revised form

1 April 2019

Accepted 11 April 2019

Available online 11 April 2019

#### Keywords:

Contralateral pneumothorax

Pneumopericardium

Dual-chamber pacemaker

### ABSTRACT

A 62-year-old man developed concomitant right-sided pneumothorax and pneumopericardium after undergoing implantation of a left-sided dual-chamber pacemaker. The case is reported for its rarity. The possible mechanisms and management options for this extremely rare complication are discussed.

Copyright © 2019, Indian Heart Rhythm Society. Production and hosting by Elsevier B.V. This is an open access article under the CC BY-NC-ND license (<http://creativecommons.org/licenses/by-nc-nd/4.0/>).

### 1. Introduction

Ipsilateral pneumothorax after pacemaker implantation is an uncommon complication. It has been variably reported in 0.5%–0.66% of implantations, usually caused by needle injury during venous access [1]. However, development of contralateral pneumothorax is very rare. Association of contralateral pneumothorax with pneumopericardium is even rarer. We present a case of concomitant right-sided pneumothorax and pneumopericardium following left-sided pacemaker implantation.

### 2. Case report

A-62-year-old man presented with complaints of recurrent episodes of presyncope for nine months. There was no history of syncope. The baseline electrocardiogram revealed trifascicular block. Twenty-four hour Holter monitoring revealed intermittent high-grade second degree atrioventricular (AV) block. There was no

structural heart disease on echocardiography and biventricular function was normal.

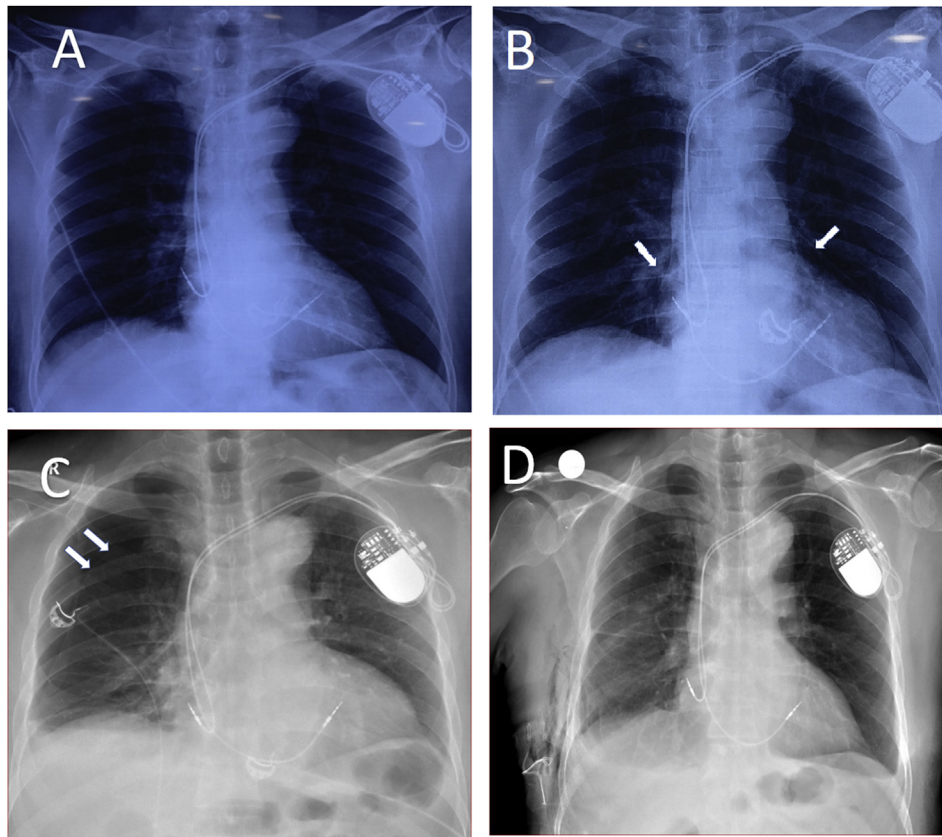
Accordingly, the patient underwent dual-chamber permanent pacemaker (Medtronic Attest, LDR MRI SureScan, ATDRL1- Medtronic, MN, USA) implantation through left axillary venous access. Active fixation leads were used both in right atrium (RA) and right ventricle (RV). At implantation, atrial lead pacing threshold was 0.75 V at 0.4 ms, sensing was 2.8 mV and impedance was 495 Ω. Ventricular lead pacing threshold was 0.5 V at 0.4 ms and impedance was 644 Ω. The procedure was uneventful without any in-laboratory complications. Postprocedure chest radiograph done 2 h after the implantation showed normal lead position and no evidence of pneumothorax. Postprocedure echocardiogram showed no pericardial effusion.

About 7 h after the procedure, the patient complained of sudden onset central chest pain that worsened with inspiration. The pulse rate was 84 bpm, blood pressure was 124/82 mm Hg and respiratory rate was 22 per minute. The lungs were clear with normal intensity of breath sounds on both sides. The heart sounds were of normal intensity and not muffled. A bedside chest radiograph was repeated in supine position which revealed no abnormality and showed normally positioned pacemaker leads (Fig. 1A). Device interrogation demonstrated no significant change in the lead parameters. There was no pericardial effusion on echocardiogram

\* Corresponding author. Department of Cardiology, Cardio-thoracic Sciences Center, All India Institute of Medical Sciences, Ansari Nagar, New Delhi, 110029, India.

E-mail address: [deeptikailath@gmail.com](mailto:deeptikailath@gmail.com) (S. Deepti).

Peer review under responsibility of Indian Heart Rhythm Society.



**Fig. 1.** A) Chest radiograph done 2 hours after pacemaker implantation showing normally positioned right atrial and ventricular leads without any pneumothorax or pneumopericardium. B) Chest radiograph done 6 hours after the onset of symptoms showing pneumopericardium (white arrows). C) Chest radiograph showing right pneumothorax (double white arrows). D) Chest radiograph after one week showing resolved pneumothorax and pneumopericardium.

with good echocardiographic windows. The patient was given symptomatic treatment.

However, the pain persisted and a decrease in the breath sounds on the right side of the chest was noted afterwards. Importantly, mediastinal crunch was heard on auscultation of the precordium. A bedside chest radiograph was repeated in semi-reclining position 6 h after the onset of symptoms which revealed pneumopericardium (Fig. 1B). A non-contrast computed tomography (CT) of chest was immediately performed which showed right-sided pneumothorax with partial collapse of right lung with concomitant pneumopericardium (Fig. 2A). There was no evidence of chronic lung disease or bullae on CT. There was no obvious perforation of the RA wall by the atrial lead tip. However, a probable extrusion of the helix of the RA lead could not be ruled out definitively due to the artifacts created by the lead helix (Fig. 2B and C). A subsequent chest radiograph in the standing position clearly showed the right-sided pneumothorax (Fig. 1C).

In view of the size of the pneumothorax (~50%), right-sided intercostal drainage tube was inserted. There was immediate resolution of pneumopericardium with gradual resolution of the pneumothorax over the next three days. Repeat device interrogation showed no change in device parameters and RA lead repositioning was not required. The patient remained stable and one week later, the chest radiograph showed no abnormality (Fig. 1D).

### 3. Discussion

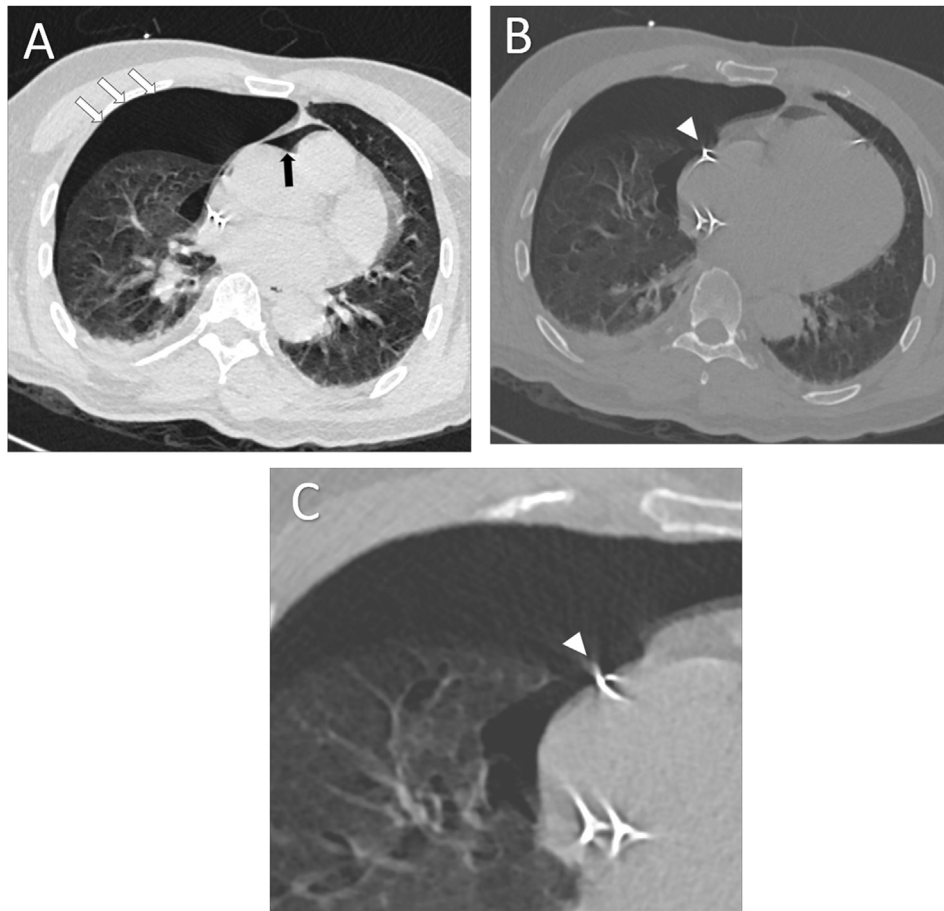
Permanent pacemaker implantation is usually a safe procedure; however, it can be associated with serious complications including pneumothorax and pericardial effusion. Pneumothorax is reported

in <1% cases of permanent pacemaker implantation [1] and is related to needle injury to the ipsilateral pleura during venous cannulation.

Almost always, pneumothorax develops on the ipsilateral side. Pneumothorax of contralateral side has been uncommonly reported. Two possible mechanisms have been proposed for the development of contralateral pneumothorax after pacemaker implantation. The helix of an active fixation lead may perforate through the RA free wall causing injury to the adjacent pericardium and right pleura. The second mechanism is right pleural injury during Seldinger set introduction, especially due to injury to the extrapericardial part of the superior vena cava (SVC) with the guidewire or the dilator of the sheath.

Association of contralateral pneumothorax with pneumopericardium is even rarer. To the best of our knowledge, only three cases have been described so far, the salient details of which have been summarized in Table 1 [2–4]. In all these cases, the cause was perforation of the RA free wall by the atrial lead.

Patients usually present within a few days of the procedure with complaints of shortness of breath and pleuritic chest pain. The factors which increase the risk of atrial wall perforation include use of active fixation (screw-in) atrial leads, variations in RA anatomy such as thin walled or multilobed atrial appendage and fixation of lead in lateral or anterolateral wall of atrium. Lead design may have a bearing, especially in the case of magnetic resonance imaging-compatible leads which have increased diameter and stiffness [2]. Caution should be exercised in screwing of the atrial lead during placement especially in patients with bullous emphysematous changes in lung parenchyma due to chronic obstructive pulmonary disease (COPD) [2,3].



**Fig. 2.** Chest non-contrast computed tomography (CT) image. A) Axial CT scan image showing the right-sided pneumothorax (white arrows) and pneumopericardium (black arrow). B and C) Axial CT images showing probable extrusion of the helix (arrowhead) of atrial lead through the right atrial anterolateral wall.

**Table 1**  
Reported cases with contralateral pneumothorax and pneumopericardium following pacemaker implantation.

Authors	Age (yrs)/Sex	Diagnosis	Associated conditions	Atrial lead			Symptoms and time to onset after implant	Chest X Ray	Change in lead parameters	Management
				Position	Type	Model				
Sebastian et al. [3]	73/M	Mobitz type II AV block	COPD	A/L RA	Active fixation	CapSureFix Novus, Medtronic	Chest pain; 2 days	50% PTx Moderate sized pneumo-pericardium	No	Intercostal drainage tube
Srivathsan et al. [2]	77/F	Symptomatic SSS	COPD	A/L RA	Active fixation	Model 5076, Medtronic	Shortness of breath 8 hours	30% PTx Moderate sized pneumo-pericardium	No	Intercostal drainage tube, Atrial lead extraction
Nantsupawat et al. [4]	83/M	Tachybrady syndrome	CAD LV dysfunction	A/L RA	Active fixation	Ingevity7740 Boston Scientific	Chest and neck pain; 1 day	10% PTx Small pneumo-pericardium	No	Observation, O <sub>2</sub> inhalation
Present case	62/M	Mobitz type II AV block	None	A/L RA	Active fixation	CapSureFix Novus MRI, Medtronic	Chest pain; 7 hours	50% PTx Small pneumo-pericardium	No	Intercostal drainage tube

yrs = years; M = Male; F=Female; AV = Atrioventricular; SSS=Sick sinus syndrome; COPD = chronic obstructive pulmonary disease; CAD = coronary artery disease; LV = Left ventricular; A/L = Anterolateral; PTx = pneumothorax; RA = right atrium; O<sub>2</sub>=Oxygen.

Penetration of a pacemaker lead through the atrial wall is not uncommon. An autopsy study showed perforation of active fixation RA lead helices across the atrial wall through the pericardium into the pleura in 27% cases [5]. The majority of patients are asymptomatic and complications are rare.

Usually, the lead parameters change after lead perforation; however, there might be no change in lead parameters in some cases. This could be due to extrusion of the helix alone which is not

a part of the electrode. A large part of electrode may remain in contact with atrial myocardium even after extrusion of the helix.

Pericardial effusion may not be seen, as in our case, likely due to plugging of the pericardial defect by the atrial lead itself. Since an obvious RA wall perforation could not be conclusively demonstrated in our case, an alternative explanation could be injury to the extrapericardial SVC and right pleura by the guidewire or sheath-dilator system with seepage of air into the pericardial space via a

congenital defect in the pericardium or microscopic pleuro-pericardial fistulas.

The insertion of intercostal tube should be considered when pneumothorax involves more than 10% of pleural space or hemopneumothorax is present. In our case, intercostal drainage was required because there was involvement of ~50% of pleural space. Lead repositioning was not performed as the parameters remained unchanged on repeated device interrogation and the defect was felt to be healing with fibrosis so that lead removal could actually increase complications.

#### 4. Conclusion

Contralateral pneumothorax with or without pneumopericardium is a rare complication and may be missed on an initial chest radiograph (as in our case) and may be associated with no abnormality on device interrogation. Awareness about the possibility of this complication is important. In cases with high suspicion, a chest radiograph should be repeated or a CT scan should be performed. The management depends upon the presence of symptoms, the hemodynamic status, the size of the pneumothorax and device parameters.

#### Author contributions

Dr. Nitin Kumar Parashar was responsible for drafting the article.

Dr. Siddharthan Deepti was involved in data analysis and critical revision of the article.

Dr. Rakesh Yadav contributed to critical revision and final approval of the article.

Dr. Mumun Sinha and Dr. Venkatakrishnan Ramakumar were involved in data collection and interpretation.

#### Conflicts of interest

Authors declare no conflict of interest.

#### References

- [1] Kirkfeldt RE, Johansen JB, Nohr EA, Møller M, Arnsbo P, Nielsen JC. Pneumothorax in cardiac pacing: a population-based cohort study of 28,860 Danish patients. *Europace* 2012;14(8):1132–8.
- [2] Srivathsan K, Byrne RA, Appleton CP, Scott LRP. Pneumopericardium and pneumothorax contralateral to venous access site after permanent pacemaker implantation. *Europace* 2003;5(4):361–3.
- [3] Sebastian CC, Wu W-C, Shafer M, Choudhary G, Patel PM. Pneumopericardium and pneumothorax after permanent pacemaker implantation. *Pacing Clin Electrophysiol* 2005;28(5):466–8.
- [4] Nantsupawat T, Li JM, Benditt DG, Adabag S. Contralateral pneumothorax and pneumopericardium after dual-chamber pacemaker implantation: mechanism, diagnosis, and treatment. *HeartRhythm Case Rep* 2018;4(6):256.
- [5] Ishikawa K. Myocardial perforation and/or penetration by a permanent endocardial electrode of the pacemaker in autopsy cases. *J Arrhythmia* 1999;15:39–44.