

A rare case of chondroblastoma of the acromion



Murat Arıkan^a, Güray Toğral^a, Ahmet Yıldırım^{a,*}, Çiğdem Irkkan^b

^a Department of Orthopaedics and Traumatology, Oncology State Hospital, Ankara, Turkey

^b Department of Pathology, Oncology State Hospital, Ankara, Turkey

ARTICLE INFO

Article history:

Received 13 July 2014

Received in revised form

1 October 2014

Accepted 15 November 2014

Available online 10 December 2016

Keywords:

Chondroblastoma

Bone

Acromion

Resection

ABSTRACT

We present a 37-year-old patient with a chondroblastoma in his right acromion. The acromion is an unusual site for this type of tumor and the typical surgical treatment involves resection of the involved acromion bone. The patient was surgically treated with resection of the right acromion and autogenous iliac bone grafting. Twenty five months postoperatively, he demonstrated full shoulder function, without evidence of local recurrence or metastasis.

© 2016 Turkish Association of Orthopaedics and Traumatology. Publishing services by Elsevier B.V. This is an open access article under the CC BY-NC-ND license (<http://creativecommons.org/licenses/by-nc-nd/4.0/>).

Introduction

Chondroblastomas are rare, primary bone tumors of cartilaginous origin that account for nearly 1% of all primary bone tumors(1), with the most frequently involved bones being the hips, knees, and shoulders. 70% of the tumors have nearly seen at the femur, humerus and tibia, in descending order. The epiphyseal regions have been mostly affected parts in the long bones by chondroblastoma. Many of these lesions have extended into the adjacent metaphysis. Secondary centers of ossification have provided few examples and acromion is a very rare localization region.¹ The tumor's radiographic appearance is characteristically a single, lytic lesion with lobulated margins, septations, cortical expansion, and a sclerotic rim.^{2,3} Like the other bone tumors, the symptoms are nonspecific. Pain in the region of the tumor was a significant symptom in almost all of the cases; soft tissue swelling and impairment of the joint function may be the other symptoms.¹ The acromion is a very rare site for this tumor to occur; as a result of this it becomes difficult to diagnose. Typical surgical treatment includes aggressive curettage or resection of the involved acromion bone.

Case presentation

A 34-year-old man, with complaints of pain and a palpable mass over the tip of his right shoulder, was admitted to our orthopedic department. He stated that his complaints had persisted for nearly 2 years and had progressively worsened. The patient could not recall any precipitating trauma and did not have any other systemic or metabolic conditions. A clinical examination revealed a tender, firm mass on the lateral aspect of the acromion and some restriction of the range of abduction of his right shoulder. Plain radiographs showed a lytic, expansile, and septated bone lesion with irregular, spicular calcifications in the right acromion, suggestive of a bone tumor of chondroid origin (Fig. 1A). Magnetic resonance imaging revealed an expansile and destructive bone lesion, iso-intense in T1-imaging and heterogeneously hyperintense in T2 images, in the right acromion adjacent to the acromio clavicular joint (Fig. 1B–C). The lesion had a large soft tissue extension in the superior pole of the acromion, extending up almost through the skin plane.

An incisional biopsy was performed and indicated a chondroblastoma. A histological examination of the excised tissue confirmed the typical features of a chondroblastoma. The cellular areas were predominantly composed of large mononuclear cells, with oval nuclei, and osteoclast-like, multinucleated giant cells in immature chondroid material (Fig. 2A–C). On the basis of the diagnosis, we performed a marginal excision of the tumor,

* Corresponding author.

E-mail address: dr1907@gmail.com (A. Yıldırım).

Peer review under responsibility of Turkish Association of Orthopaedics and Traumatology.

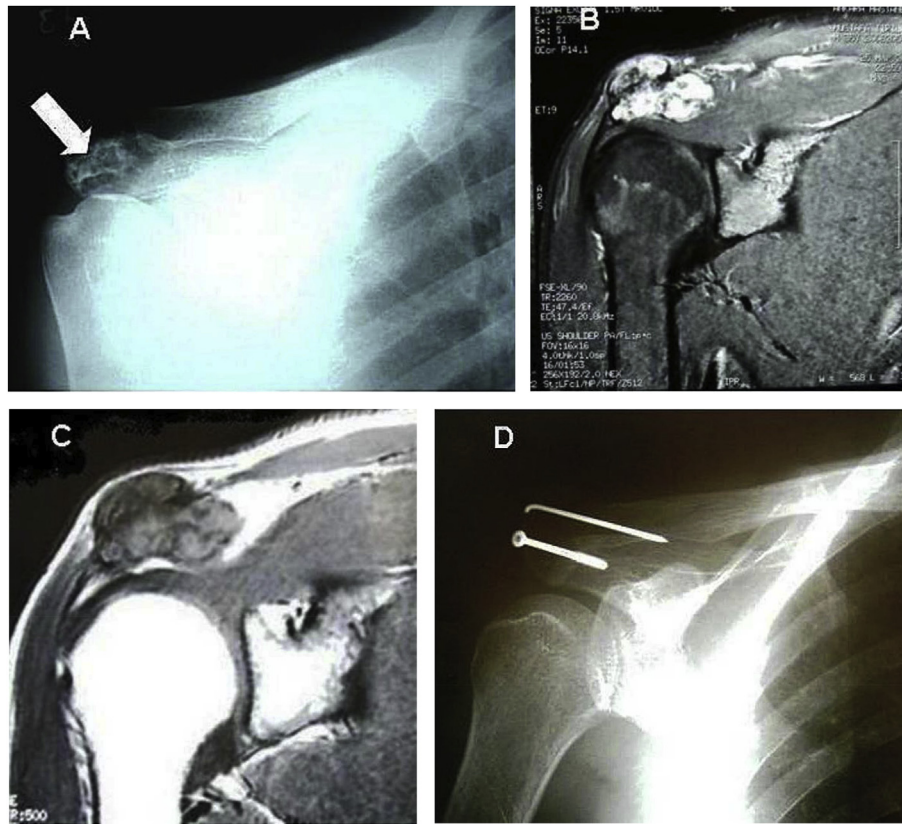


Fig. 1. A: Anterior-posterior image showing an expansile and septated bone lesion on the right acromion, no evidence of bone destruction is noted. B: T1-weighted coronal MRI revealing an isointense, expansile bone lesion, having a large soft tissue component in the superior-lateral position of the right acromion. C: T2-weighted coronal image revealing a hyperintense and lobulated bone lesion. D: An image showing the fixation of the autogenous iliac bone graft, with a K-wire, to the clavicle, and a partially threaded spongiosa screw toward neck of coracoid process.

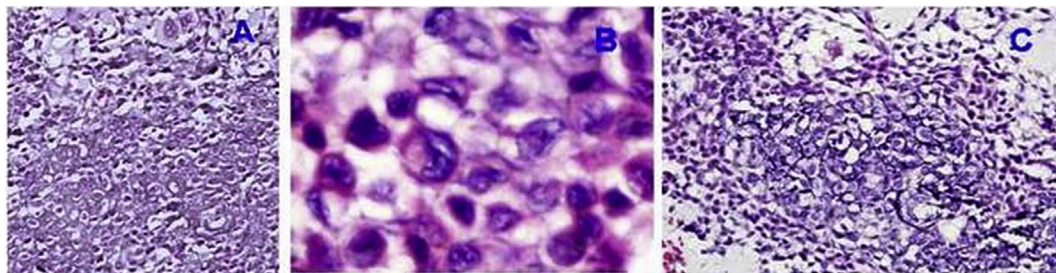


Fig. 2. Histological sections of the excised lesion. Histo-pathological examination revealing large mononuclear cells with oval nuclei and osteoclast-like multinucleated giant cells embedded within an immature chondroid material.

including the acromion and its soft tissue extension. This was followed by iliac bone grafting fixation. The autogenous iliac bone graft was fixed with a K-wire to the clavicle and with a partially threaded spongiosa screw to the neck of the scapula's coracoid process in order to obtain proper shoulder function (Fig. 1D).

Intraoperative and postoperative complications were not observed in this patient. The K-wire, used for securing the iliac bone graft to the clavicle, was removed 6 months postoperatively. After 25 months of follow-up, the patient had not experienced any pain and had regained a nearly complete range of motion in his right shoulder.

Discussion

Chondroblastomas are rare, benign bone tumors that account for less than 1% of all primary bone tumors. The most common localizations for this type of tumor include the epiphyseal parts of the knees, the proximal humerus, and the proximal femur. Besides the long bones, chondroblastomas may also occur in the hands, feet, or pelvic bones; localization to the flat bones is unusual. In the shoulder girdle, the tumors have a predilection for the proximal humerus, with development in the acromion being exceptional. To our knowledge, this is only the fifth report of this tumor type being localized in the acromion.⁴

Chondroblastomas usually present during the second decade of life, making our 34-year-old patient older than a typical patient. However, when the tumors develop in the flat bones, they have been reported to be more aggressive than in the long bones,^{4,5} making tru-cut or fine needle biopsies mandatory for their diagnosis. In this case, we preferred an open incisional biopsy to avoid a possible misdiagnosis. Prior to confirmation of the tumor type, particularly in the extremities, giant cell tumors, epiphyseal enchondroma, chondroma, central chondrosarcoma, and clear cell sarcoma should be considered.⁵

As a result, radiographic diagnosis of an atypical chondroblastoma is more difficult because of a variety of possible diagnoses, including benign and malignant lesions as aneurysmal bone cyst, malign chondroblastoma, fibrosarcoma, several metastases, etc.^{1,6}

Magnetic resonance images of chondroblastoma are typical. The tumor shows an intermediate signal intensity on T1-, and a high signal intensity on T2-weighted images with a halo of bone oedema.^{2,3} CT-scans can be helpful to see the matrix calcifications.³ Fibrous dysplasia can be excluded by the presence of matrix calcifications. A biopsy will be the gold standard to obtain the correct diagnosis.^{3–5}

The accepted treatment method of a chondroblastoma is curettage and filling of the bone defect with a bone graft generally resulting in good outcomes. Previous surgery for a chondroblastoma in the same location is the thought to be together with an increased local recurrence rate. Although the majority of chondroblastomas behave in a benign fashion, local recurrence and distant metastasis, especially to the lungs, have been described.⁵ As in the current case, marginal resection is necessary for aggressive tumors, as curettage can increase the local recurrence rate. In atypical anatomical locations, such as the acromion, local recurrence has been reported to be as high as 15%.⁷

This is the fifth aggressive chondroblastoma case reported in the acromion.⁴ Among the five patients reported, including one who

died due to lung metastasis, this is the third patient treated with marginal resection, followed by autogenous iliac bone graft fixation, who demonstrated a good clinical outcome without evidence of metastasis or recurrence.^{8–10} Surgical resection should be the treatment of choice in the shoulder region because of the high suspected recurrence rate.

Disclosure statement

The authors declare that there are no conflicts of interest regarding the publication of this paper.

References

1. Dahlin DC, Ivins JC. Benign chondroblastoma. A study of 125 cases. *Cancer*. 1972;30:401–413.
2. Macdonald D, Fornasier V, Holtby R. Chondromyxoid fibroma of the acromion with soft tissue extension. *Skelet Radiol*. 2000;29:168–170.
3. Holt EM, Murphy GJ. Chondroblastoma of the acromion. *Skelet Radio*. 1995 Apr;24(3):223.
4. Ozkurt B, Başarır K, Yildiz Y, Sağlık Y. Aggressive chondroblastoma of the acromion in a forty-one-year-old patient. *J Shoulder Elb Surg*. 2008;17:e14–e17.
5. Ozkoc G, Gonlusen G, Ozalay M, Kayaselcuk F, Pourbagher A, Tandogan RN. Giant chondroblastoma of the scapula with pulmonary metastases. *Skelet Radiol*. 2006;35:42–48.
6. Davila JA, Amrami KK, Sundaram M, Adkins MC, Unni KK. Chondroblastoma of the hands and feet. *Skelet Radiol*. 2004;33:582–587.
7. Resendes M, Parker BR, Kempson RL, Jones HH, Nagel DA. Case report 663. Unusual chondroblastoma of the scapula. *Skelet Radiol*. 1991;20:222–225.
8. Vestring T, Edel G, Muller-Miny H, et al. Lokalisa-tionsabhängige Befundmuster beim Chondroblastom. *Rofo Fortschr Geb Rontgenstr Neuen Bildgeb Verfahr*. 1993;159:331–336.
9. Wellmann KF. Chondroblastoma of the scapula. A case report with ultra-structural observations. *Cancer*. 1969;24:408–416.
10. Gebert C, Hards J, Streitbürger A, et al. Chondroblastoma of the acromion mimicking fibrous dysplasia. *Acta Orthop Belg*. 2004;70:616–618.