


## Case Report

# Bilateral vocal cord paralysis in a hanging survivor: a case report

Mayuko Kunii,<sup>1</sup>  Kenichiro Ishida,<sup>1</sup> Masahiro Ojima,<sup>1</sup> Taku Sogabe,<sup>1</sup> Keiichiro Shimono,<sup>1</sup> and Tasuke Tanaka,<sup>1</sup> Mitsuo Ohnishi<sup>1,2</sup>

<sup>1</sup>Department of Acute Medicine and Critical Care Medical Center, Osaka National Hospital, and <sup>2</sup>Department of Traumatology and Acute Critical Medicine, Osaka University Graduate School of Medicine, Osaka, Japan

**Background:** Complications in survivors after typical hanging have not been well characterized because of the high mortality rate.

**Case Presentation:** We present a patient with bilateral vocal cord paralysis following typical hanging. A 39-year-old man with depression attempted suicide by hanging. He was in a coma and was transported to our hospital. Emergency endotracheal intubation was carried out. After 10 days of mechanical ventilation, he was extubated. After extubation, his voice was hoarse and stridor was heard. Vocal cord paralysis became apparent by laryngeal fiberscopy, and a tracheotomy was carried out. It resolved gradually 2 months after injury without surgery or drug treatment.

**Conclusion:** Although vocal cord paralysis after typical hanging is rare, there is a need for adequate assessment of the airways in survivors of typical hanging as a differential diagnosis of airway edema after extubation.

**Key words:** Hanging, hoarseness, hyoid bone fracture, typical hanging, vocal cord paralysis

## INTRODUCTION

HANGING IS A leading method of completed suicide with a mortality rate as high as 70%.<sup>1,2</sup> Little is known about complications in survivors after hanging due to the high mortality rate. Hyoid bone fracture or thyroid cartilage fracture is reported in 60–70% of autopsy cases of typical hanging,<sup>3,4</sup> and vocal cord paralysis in survivors is considered a rare complication.<sup>5</sup> Vocal cord paralysis has several etiologies, including surgery, malignant neoplasms, trauma, and central nervous system disorders, as well as idiopathic cases.<sup>6</sup> Respiratory symptoms such as hoarseness, dysphasia, and dyspnea could occur after vocal cord paralysis, which sometimes requires surgery.<sup>6</sup> Although there have been reports of vocal cord paralysis associated with cervical trauma,<sup>7,8</sup> the cause and time course of paralysis have not been discussed in sufficient detail.

**Corresponding:** Mayuko Kunii, MD, Department of Acute Medicine and Critical Care Medical Center, Osaka National Hospital, National Hospital Organization, 2-1-14 Hoenzaka, Chuo-ku, Osaka 540-0006, Japan. E-mail: mayu921tf@yahoo.co.jp.

Received 31 Jan, 2020; accepted 28 Apr, 2020

Funding information

No funding information provided.

Here, we present a case of bilateral vocal cord paralysis in a survivor after typical hanging, which was associated with traumatic changes to the laryngeal muscles.

## CASE REPORT

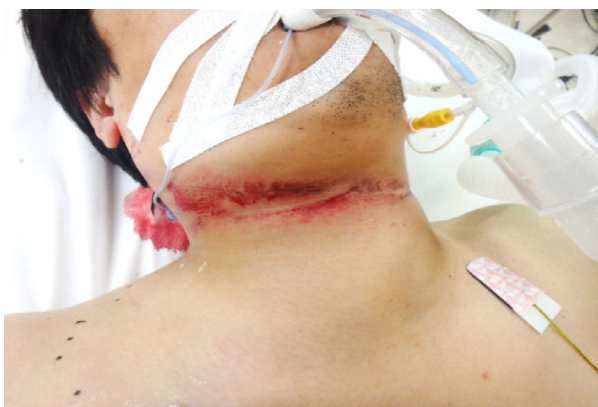THE PATIENT WAS a 39-year-old man with depression. He attempted suicide by hanging using a rope tied around his neck on a third-floor balcony. He was found immediately and rescued from a window on the second floor. When emergency medical services arrived, he was in a coma and was transported to our hospital.

On admission to our hospital, his vital signs were as follows: respiratory rate, 20 breaths/min; peripheral oxygen saturation level, 95% with 10 L/min of oxygen through a bag valve mask; blood pressure, 214/158 mmHg; heart rate, 135 b.p.m.; and level of consciousness as measured using the Glasgow Coma Scale, E1V1M2. Arterial blood gas analyses showed mixed acid-base disturbances (pH, 7.210; PaO<sub>2</sub>, 67.8 mmHg; PaCO<sub>2</sub>, 59.6 mmHg; HCO<sub>3</sub><sup>-</sup>, 18.5 mmol/L; base excess, -11.5 mmol/L; lactate, 127 mg/dL). Immediately after his arrival, a board-certified emergency physician carried out endotracheal intubation with neuromuscular blockade, because the patient was in a coma. The emergency physician confirmed that his vocal cords

were open symmetrically. However, we could not evaluate the movement of vocal cords because of the effects of neuromuscular blockade. Physical examination revealed swelling of the anterior neck. Rope marks and subcutaneous emphysema were seen on his neck (Fig. 1). A computed tomography scan demonstrated a fracture of the right side of the hyoid bone and subcutaneous emphysema (Fig. 2). He was admitted to the intensive care unit for further treatment.

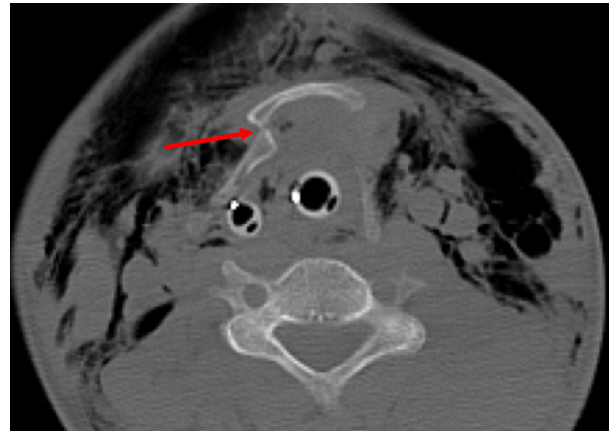
The patient recovered consciousness on the 5th hospital day, and extubation was planned. However, the cuff leak test was carried out, and the amount of leakage was too little to extubate the patient. On the 10th hospital day, he was weaned from mechanical ventilation and extubated after treatment with i.v. steroids. Following extubation, he was alert and was able to speak, with a hoarse voice. Moreover, medical staff noted stridor, and at that time considered it to be due to postextubation laryngeal edema. Adrenaline inhalation was administered. However, the patient's hoarseness and stridor continued, and his hypoxemia gradually worsened. Impaired bilateral vocal cord movement and laryngeal edema were observed by an otolaryngologist using a laryngeal fiberscope on hospital day 12. The otolaryngologist diagnosed vocal cord paralysis as the main cause of the airway stenosis because the vocal cords were bilaterally adducted near the midline position, although laryngeal edema could have also been the cause of airway obstruction. The patient was reintubated because his airway was at risk of obstruction. A tracheostomy was undertaken the next day to maintain the vocal cords at rest.

After the tracheostomy, it was difficult to evaluate the presence of hoarseness. Therefore, the otolaryngologist regularly followed the movement of the vocal cords by laryngeal fiberscope, and found that cord movement gradually

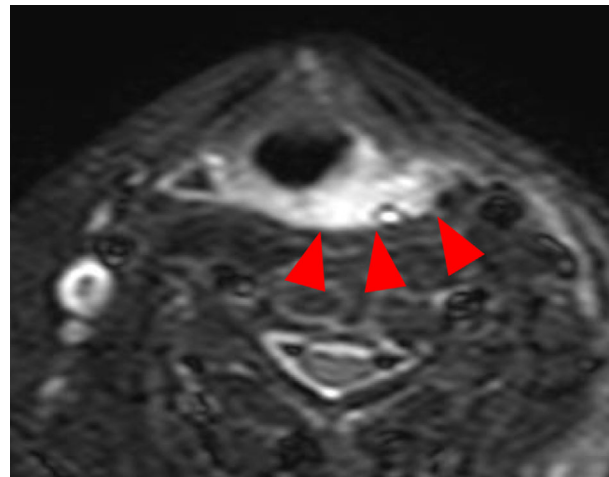


**Fig. 1.** Physical findings on admission of a 39-year-old man who attempted suicide by hanging. Swelling, rope marks, and subcutaneous emphysema were seen on his neck.

improved. Magnetic resonance imaging of the neck 5 weeks after hospital admission demonstrated edema in the laryngeal muscles and posterior pharyngeal wall (Fig. 3). The patient was then able to speak with a speech cannula, and his hoarseness gradually improved. In addition, he had dysphagia, which healed with rehabilitation. The tracheostomy tube was removed as vocal cord movement returned to normal 2 months after hospital admission. After receiving



**Fig. 2.** Non-enhanced axial neck computed tomography on admission of a 39-year-old man who attempted suicide by hanging. The scan demonstrated a fracture of the right side of the hyoid bone (arrow) and subcutaneous emphysema.



**Fig. 3.** Axial neck short tau inversion recovery magnetic resonance imaging of a 39-year-old man who attempted suicide by hanging. The image, taken 5 weeks after injury, demonstrated a signal increase in the laryngeal muscles and pharyngeal posterior wall, indicating edematous changes (arrowheads).

psychiatric treatment, he was discharged home. There were no physical complications 1 year after the injury.

## DISCUSSION

**T**HIS CASE REPORT raises two important issues: (i) bilateral vocal cord paralysis could be caused by hanging, (ii) vocal cord paralysis caused by hanging may become apparent after hospitalization and may improve without surgical intervention.

In this hanging patient, swelling and subcutaneous emphysema were seen in his neck, and a computed tomography scan on hospital arrival showed a fracture of the right side of the hyoid bone. Vocal cord paralysis after cervical injury has previously been reported.<sup>7,8</sup> Hoarseness and laryngeal edema can occur after fracture of the hyoid bone.<sup>9</sup> Moreover, patients suffering hyoid bone fractures may develop rapid hemoptysis, edema, ecchymosis, and airway spasm, resulting in life-threatening asphyxia.<sup>10</sup> Physicians should consider the possibility of airway stenosis after hyoid bone fracture.

Vocal cord paralysis in this patient became apparent after extubation, and it improved without surgical treatment. On admission to our hospital, he was in a coma and unable to speak, which means that we could not evaluate hoarseness or airway stenosis sufficiently. Moreover, we could not evaluate movement of the vocal cords because of neuromuscular blockade, although we confirmed that the vocal cords were open symmetrically. Therefore, it was difficult to determine whether vocal cord paralysis in our patient was caused by hanging or by tracheal intubation, as apparent vocal cord paralysis was not observed on arrival. However, we concluded that the vocal cord paralysis in this patient was associated with traumatic changes to the laryngeal muscles, based on the following two observations: (i) the presence of injury to the neck, with hyoid bone fracture, (ii) magnetic resonance imaging of the neck at 5 weeks after injury, demonstrating edema in the laryngeal muscles and posterior pharyngeal wall (Fig. 3). In this patient, vocal cord paralysis was improved with conservative treatment, although the cervical trauma was severe enough to cause cervical structure displacement. A previous report indicated that management options for vocal cord paralysis vary depending on the underlying etiology.<sup>6</sup> In our patient, we concluded that the swelling of edematous laryngeal muscles restricting vocal cord movement had diminished, and vocal cord paralysis had been reversed.<sup>8</sup> Our case report indicates that impaired bilateral vocal cord movement following neck injury could become apparent after hospitalization, and it may improve after diminishing the edema and muscle damage, without surgical intervention.

## CONCLUSION

**W**E PRESENTED A case of bilateral vocal cord paralysis in a survivor of typical hanging, which was apparent after hospitalization. Although rare, there is a need for appropriate assessment of the airways in hanging survivors as a differential diagnosis of airway edema after extubation.

## ACKNOWLEDGEMENTS

**T**HE AUTHORS ACKNOWLEDGE with much appreciation the contributions of Kanako Akita, Department of Otolaryngology, Osaka National Hospital, National Hospital Organization, Osaka, Japan, who provided expert consultation. There was no source of support for this study.

## DISCLOSURE

Approval of the research protocol: N/A.

Informed consent: Written informed consent was obtained from the patient for publication of this case report and accompanying images.

Registry and registration no. of the study/trial: N/A.

Animal studies: N/A.

Conflict of interest: None.

## REFERENCES

- 1 Kochanek KD, Murphy SL, Xu J, Arias E. Deaths: final data for 2015. *Natl Vital Stat. Rep.* 2019; 68: 1–77.
- 2 Gunnell D, Bennewith O, Hawton K, Simkin S, Kapur N. The epidemiology and prevention of suicide by hanging: a systematic review. *Int. J. Epidemiol.* 2005; 34: 433–42.
- 3 Zatopkova L, Janik M, Urbanova P, Mottlova J, Hejna P. Laryngo-hyoid fractures in suicidal hanging: a prospective autopsy study with an updated review and critical appraisal. *Forensic Sci. Int.* 2018; 290: 70–84.
- 4 Uzun I, Buyuk Y, Gurpinar K. Laryngo-hyoid fractures in suicidal hanging: a prospective autopsy study with an updated review and critical appraisal. *J. Forensic Leg. Med.* 2017; 14: 406–9.
- 5 Boots RJ, Joyce C, Mullany DV *et al.* Near-hanging as presenting to hospitals in Queensland: recommendations for practice. *Anaesth. Intensive Care* 2006; 34: 736–45.
- 6 Maisel RH, Ogura JH. Evaluation and treatment of vocal cord paralysis. *Laryngoscope* 1974; 84: 302–16.
- 7 Levine RJ, Sanders AB, LaMear WR. Bilateral vocal cord paralysis following blunt trauma to the neck. *Ann. Emerg. Med.* 1995; 25: 253–5.

- 8 Lato M, Lateef M, Nawaz I, Ali I. Bilateral recurrent laryngeal nerve palsy following blunt neck trauma. *Indian J. Otolaryngol. Head Neck Surg.* 2007; 59: 298–9.
- 9 Ramchand T, Choudhry OJ, Shukla PA, Tomovic S, Kuperan AB, Eloy JA. Management of hyoid bone fractures: a systematic review. *Otolaryngol. Head Neck Surg.* 2012; 147: 204–8.
- 10 Porr J, Laframboise M, Kazemi M. Traumatic hyoid bone fracture – a case report and review of the literature. *J. Can. Chiropr. Assoc.* 2012; 56: 269–74.