



FDG-PET findings and alcohol-responsive myoclonus in a patient with Unverricht-Lundborg disease



Lorenzo Muccioli ^a, Andrea Farolfi ^b, Federica Pondrelli ^a, Eleonora Matteo ^a, Lorenzo Ferri ^a, Laura Licchetta ^c, Lara Alvisi ^c, Paolo Tinuper ^{a,c}, Francesca Bisulli ^{a,c,*}

^a Department of Biomedical and Neuromotor Sciences, University of Bologna, Bologna, Italy

^b Nuclear Medicine Unit, IRCCS Azienda Ospedaliero-Universitaria di Bologna, Bologna, Italy

^c IRCCS Istituto delle Scienze Neurologiche di Bologna, Bologna, Italy¹

ARTICLE INFO

Article history:

Received 30 December 2021

Revised 28 April 2022

Accepted 5 May 2022

Available online 13 May 2022

ABSTRACT

The aim of this report is to describe clinical, EEG, and neuroimaging findings in a patient with Unverricht-Lundborg disease (ULD), the most common form of progressive myoclonus epilepsy (PME). A 23-year-old male with genetically confirmed ULD had a phenotype consisting of myoclonus, generalized seizures, intellectual disability, ataxia, and dysarthria. Myoclonus and gait disturbance were strongly ameliorated by alcohol consumption. EEG revealed a posterior dominant rhythm with alpha variant, mild bilateral slowing, and anterior-predominant epileptiform abnormalities. Brain MRI showed mild cerebellar atrophy. FDG-PET revealed hypometabolism more prominent in the posterior brainstem, thalami, frontal and parietal lobes.

This report confirms that alcohol may ameliorate myoclonus in a subset of patients with PME, including genetically confirmed ULD. In addition, the presence of FDG-PET hypometabolism predominant in the frontoparietal region and thalami has not been previously described in ULD, yet is consistent with previous brain morphometry studies showing motor cortex and thalamic atrophy in ULD, and brings into question the possibility of a shared metabolic pattern with other PMEs, notably Lafora disease.

© 2022 The Authors. Published by Elsevier Inc. This is an open access article under the CC BY-NC-ND license (<http://creativecommons.org/licenses/by-nc-nd/4.0/>).

1. Introduction

Unverricht-Lundborg disease (ULD) is the most frequent progressive myoclonus epilepsy (PME) worldwide, with a higher incidence in Scandinavia and around the Mediterranean area [1]. It is an autosomal recessively inherited disorder caused by mutations in the cystatin B gene (*CSTB*), most commonly promoter expansions, leading to reduced *CSTB* mRNA expression [1]. Onset occurs in late childhood and early adolescence with tonic-clonic seizures and myoclonus (often stimulus-sensitive and movement-activated), which usually progress in adolescence and may be associated with ataxia and mild cognitive decline [1]. The condition tends to stabilize in early adulthood, yet the outcome in adults is highly variable, ranging from independent active life with minimal impairment to severe disability [1]. EEG typically shows interictal generalized epileptiform discharges, and photosensitivity is detected in most cases [2]. Conventional magnetic resonance imag-

ing (MRI) of the brain is usually normal at the time of diagnosis and may subsequently show cerebral and cerebellar atrophy [1]. Few case reports describing ¹⁸F-fluorodeoxyglucose positron emission tomography (FDG-PET) in ULD shows heterogeneous findings [3,4].

Herein, we describe a patient with ULD focusing on: (i) clinical features, notably the remarkably alcohol-responsive myoclonus, and (ii) the cerebral glucose metabolic pattern and its pathophysiological implications.

2. Case report

A 23-year-old male with no family history of epilepsy presented with postural and action limb myoclonus at 11 years of age, with a slowly progressive course, experiencing up to multiple myoclonic jerks per day. The patient had had minor myoclonus-related traumas but no falls. At 12 years of age, the patient had a first generalized tonic-clonic seizure (GTCS) and was started on valproate. Since then, he has had 3 further GTCS between 19 and 23 years of age. At 14 years of age, he dropped out of school due to concentration difficulties started at the end of primary school. At 19 years of age, the patient developed gait instability and, at 21 years, speech disturbances. During adolescence, valproate was associated

* Corresponding author at: IRCCS Istituto delle Scienze Neurologiche di Bologna, Department of Biomedical and Neuromotor Sciences, University of Bologna, Via Altura 3, Ospedale Bellaria, Bologna, Italy.

E-mail address: francesca.bisulli@unibo.it (F. Bisulli).

¹ Reference Centre for Rare and Complex Epilepsies (EpiCARE).

with levetiracetam and clonazepam to achieve adequate control of myoclonus. Notably, both the patient and his girlfriend reported a remarkable amelioration of myoclonus and gait disturbance after drinking a moderate quantity of alcohol, such as 1–2 standard drinks, and was demonstrated on home-videos (not shown). The time to onset of symptom release was approximately 20 min, with a duration of a few hours, yet depending on the amount of alcohol and food intake. Despite this alcohol-related motor benefit, the patient did not show any sign of alcohol addiction and drank moderately only on social occasions.

The patient was diagnosed with ULD based on genetic testing, which revealed a compound heterozygous amplification in the promoter of *CSTB*.

The patient was hospitalized at our institution at 23 years of age. At that time, neurological examination revealed dysarthria, mild axial and limb ataxia, and postural and action limb myoclonus, both contributing to gait instability. Neuropsychological evaluation with WAIS-IV (Wechsler Adult Intelligence Scale – Fourth Edition) detected pathologic scores in all indexes (verbal comprehension: 61; perceptual reasoning: 67; working memory: 63; processing speed: 58), with an intellectual quotient of 47. EEG revealed a posterior dominant rhythm with alpha variant (two dominant frequencies: 9.5 Hz and 4.8 Hz), mild bilateral slowing predominant in the temporal regions, anterior-predominant generalized epileptiform discharges, and a driving response during intermittent photic stimulation, with no photoparoxysmal response (Fig. 1). EEG jerk-locked back-averaging confirmed the cortical origin of myoclonus. Brain MRI showed mild cerebellar atrophy and was otherwise unremarkable. FDG-PET revealed diffuse hypometabolism more prominent in the posterior brainstem, thalami, frontal and parietal lobes (Fig. 2).

The patient is currently taking valproate 1000 mg/day, levetiracetam 2000 mg/day and clonazepam 3 mg/day and has no limitation in the activities of daily living.

3. Discussion

We described a patient with ULD who presented with typical clinical manifestations of this disorder, namely myoclonus, GTCS, and ataxia, and alcohol-responsiveness of his myoclonus associated with peculiar FDG-PET findings.

3.1. Alcohol-responsive myoclonus

Our patient showed a remarkable improvement in myoclonus and related gait imbalance following the consumption of moderate quantities of alcohol. Even though the response may, at least in part, be subjective, this was demonstrated by home videos. The finding that ethanol may ameliorate myoclonus in PME has been reported since the original description of dyssynergia cerebellaris myoclonica by Ramsay Hunt in 1921 [5]. This has been supported by further works, which, however, were published before the availability of genetic diagnoses of most PMEs, and ULD specifically [6,7]. Thus, our report confirms that alcohol may have antimyoclonic effects in genetically confirmed ULD. It must be kept in mind that this alcohol-related benefit may potentially lead to addiction, and patients should therefore be adequately counselled [8]. The mechanisms underlying the antimyoclonic properties of ethanol have not been fully elucidated, yet it is likely that GABA pathways, low-voltage-activated calcium channels, and glutamatergic system play key roles [9]. A better understanding of these mechanisms may allow identifying drugs with therapeutic potential for PMEs.

In this subject specifically, myoclonus was relatively well-controlled (i.e., had a contributing role in determining gait imbalance

together with ataxia but caused no restriction in the activities of daily living) with conventional antiseizure medications with intrinsic antimyoclonic action, i.e., valproate, levetiracetam and clonazepam, and the patient did not exhibit excessive alcohol use.

3.2. EEG

EEG in our patient showed a preserved posterior dominant rhythm characterized by alpha variant, which was previously interpreted as epileptiform activity due to its spiky appearance. Posterior spikes are typical of Lafora disease (LD) [10], another form of PME, while they are rarely reported in ULD [11]. The presence of occasional slow and epileptiform abnormalities is consistent with ULD diagnosis, 12 years after disease onset [2]. Indeed, background posterior activity is normal in the majority of patients at the beginning of the disease and usually remains stable over the years, while generalized spike-wave discharges gradually disappear during the follow-up [2]. Our patient did not exhibit a photoparoxysmal response; this is frequently encountered at the disease onset and is known to progressively disappear after 10 years of follow-up [2].

3.3. FDG-PET findings

FDG-PET performed 12 years after disease onset revealed cerebral glucose hypometabolism predominant in the posterior brainstem, thalami, frontal and parietal lobes. This metabolic pattern has not been previously described in patients with ULD, yet there are only a couple of case reports describing FDG-PET findings in this condition. Specifically, Kondo et al. described a patient with mild hypometabolism in the cerebellar hemispheres with concomitant mild cerebellar atrophy on brain MRI [3], while Tanaka et al. reported a patient with regional hypometabolism in the left part of the pons [4]. Patients with ULD were previously studied also using other PET tracers, notably the D2 receptor-selective ¹¹C-raclopride tracer, showing a dopamine depletion in the thalamostriatal area [12]. The authors suggested that the observed dopaminergic dysfunction may be associated with myoclonus, yet the relationship with the thalamic glucose hypometabolism observed in our patient remains unclear and should be studied by comparing both imaging modalities in the same subjects. FDG-PET findings in our patient are consistent with a previous voxel-based morphometric study, showing atrophy of the cortical motor areas (bilateral primary, premotor, and supplementary motor cortex) and thalami in ULD, correlating with motor symptoms [13]. The mechanism that causes the observed metabolic pattern remains unknown thus far. Still, this finding, together with other neuroimaging techniques and neurophysiologic studies, may help to shed light on the still unclear pathogenesis of ULD. Unfortunately, we were not able to perform a PET scanning during the beneficial effect of alcohol, which might have provided additional information on the pathophysiological mechanisms underlying myoclonus in ULD.

We recently described FDG-PET findings in a series of patients with LD [14]: notably, involvement of bilateral thalami was a recurrent finding also in this population, bringing into question the possibility of a shared metabolic pattern between PMEs, which may underlie shared clinical features. In both ULD and LD, conventional MRI investigations usually do not show significant abnormalities, possibly reflecting an impairment at the functional level [14].

Interestingly, in juvenile myoclonic epilepsy, a type of idiopathic generalized epilepsy that can mimic PME at early disease stages, FDG-PET has shown increased glucose metabolism in bilateral thalami, potentially providing a clue to the differential diagnosis among the myoclonic epilepsies [15].

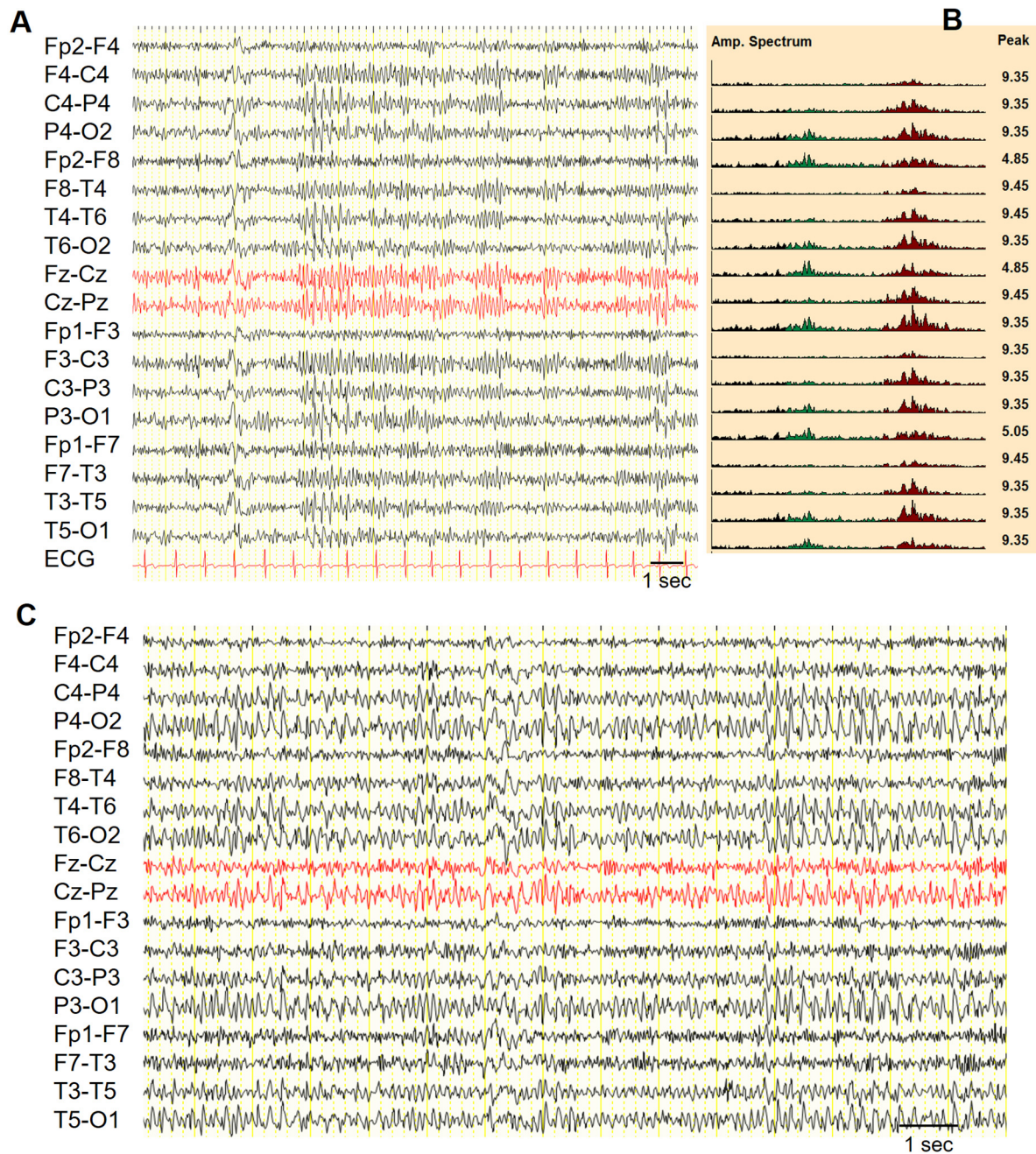


Fig. 1. EEG findings (A) EEG showed a posterior alpha dominant rhythm at 9.5 Hz, mixed with a slow alpha harmonic. A posteriorly-predominant diffuse sharp wave was present in the first part of the EEG. (B) Amplitude spectrum map demonstrating the presence of alpha variant. (C) This activity tends to organize in long sequences, appearing spiky in some occasions (interpreted as epileptiform in previous EEGs performed in other centers). Theta-delta activity without clear-cut asymmetries within hemispheres can also be appreciated. No clinical manifestation was evident in the showed EEG epochs. Sensitivity: 7 μ V/mm.

To validate our results and to relate FDG-PET findings with clinical symptoms and disease progression in ULD, prospective longitudinal studies in larger cohorts of patients are needed.

3.4. Conclusions

This case report supports alcohol may ameliorate myoclonus in a subset of patients with PME, demonstrating this finding in a patient with genetically confirmed ULD. The presence of FDG-PET hypometabolism predominantly in the frontoparietal region and thalami is consistent with a previous brain morphometry reports in ULD. However, this should be validated by future studies to

investigate the possibility of a shared metabolic pattern such as thalamic hypometabolism with other PME that might be helpful in the differential diagnosis of the myoclonic epilepsies. Even if our considerations are limited to a single patient's description, these may contribute to a better understanding of the still unclear pathogenesis of ULD.

Ethical statement

The author take full responsibility for the data and the conduct of the research. The author have full access to all of the data and

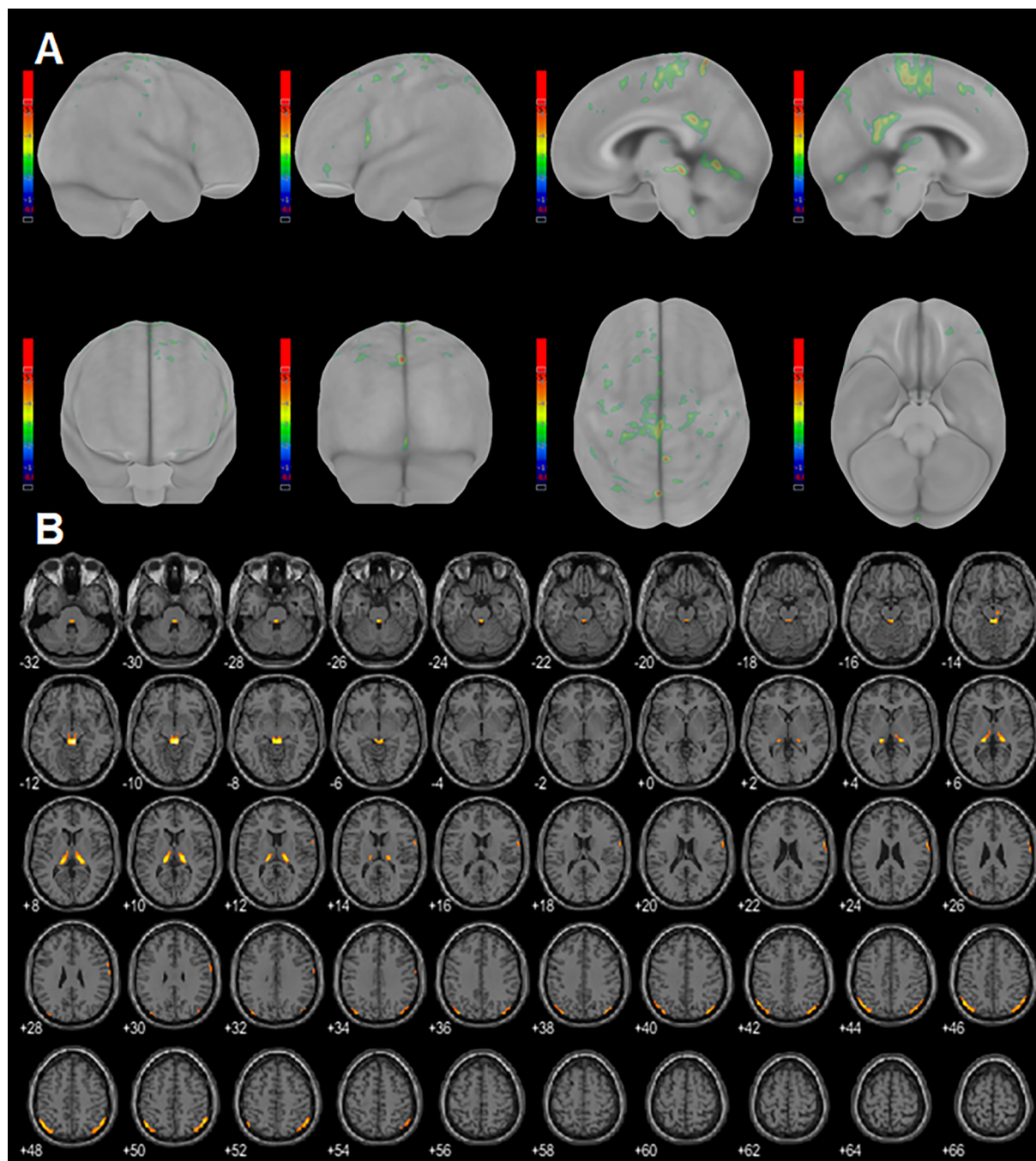


Fig. 2. FDG-PET findings (A) Z-score maps, i.e. number of standard deviations from the normal mean of a control group, calculated from FDG-PET showing predominant bilateral frontal and parietal hypometabolism (CortexID Suite, GE Healthcare); (B) FDG-PET hypometabolism SPM t-map with MRI template on axial view. SPM results show bilateral reduced metabolism in the thalamus and parietal lobe as well as the posterior brainstem ($p < 0.05$) (SPM 12, Wellcome Department of Imaging Neuroscience, Institute of Neurology, London). All FDG-PET semiquantitative analysis were performed comparing the subject with a reference control group of 155 subjects (median age 63 years, range 12–84 years).

have the right to publish any and all data separate and apart from any sponsor.

All co-authors comply with all relevant ethical regulations.

There are no ghost-writers and all co-authors have seen and approved the submitted version of the paper and accept responsibility for its content. The publication is not redundant or duplicate.

References

- [1] Crespel A, Ferlazzo E, Franceschetti S, Genton P, Gouider R, Kälviäinen R, et al. Unverricht-Lundborg disease. *Epileptic Disord* 2016;18(S2):28–37.
- [2] Ferlazzo E, Magaudda A, Striano P, Vi-Hong N, Serra S, Genton P. Long-term evolution of EEG in Unverricht-Lundborg disease. *Epilepsy Res* 2007;73(3):219–27.
- [3] Kondo T, Yamakado H, Kawamata J, Tomimoto H, Hitomi T, Takahashi R, et al. Unverricht-Lundborg disease manifesting tremulous myoclonus with rare convulsive seizures: a case report. *Rinsho Shinkeigaku* 2009;49(1):43–7.
- [4] Tanaka N et al. Multimodal imaging finding in Unverricht-Lundborg disease. *The Internet. J Neurol* 2004;5(1).
- [5] Ramsay HJ. Dyssynergia cerebellaris myoclonica—primary atrophy of the dentate system: a contribution to the pathology and symptomatology of the cerebellum. *Brain* 1922;44:490–538. <https://doi.org/10.1093/brain/44.4.490>.
- [6] Genton P, Guerrini R. Antimyoclonic effects of alcohol in progressive myoclonus epilepsy. *Neurology* 1990;40(9).

- [7] Lu CS, Chu NS. Effects of alcohol on myoclonus and somatosensory evoked potentials in dyssynergia cerebellaris myoclonica. *J Neurol Neurosurg Psychiatry* 1991;54(10):905–8.
- [8] Hsiao MC, Liu CY, Yang YY, Lu CS, Yeh EK. Progressive myoclonic epilepsies syndrome (Ramsay Hunt syndrome) with mental disorder: report of two cases. *Psychiatry Clin Neurosci* 1999;53(5):575–8. <https://doi.org/10.1046/j.1440-1819.1999.00608.x>.
- [9] Wu J, Tang H, Chen S, Cao L. Mechanisms and pharmacotherapy for ethanol-responsive movement disorders. *Front Neurol*. 2020;11:892. Published 2020 Aug 25. doi:10.3389/fneur.2020.00892.
- [10] Tassinari C, Bureau-paillais M, Dallabernardina B, Picornelldarder I, Mouren M, Dravet C, et al. La maladie de Lafora. *Rev Electroencephalogr Neurophysiol Clin* 1978;8(1):107–22.
- [11] Chew NK, Mir P, Edwards MJ, Cordivari C, Martino D, Schneider SA, et al. The natural history of Unverricht-Lundborg disease: a report of eight genetically proven cases. *Mov Disord* 2008;23(1):107–13.
- [12] Korja M, Kaasinen V, Lamusuo S, Parkkola R, Nägren K, Marttila RJ. Substantial thalamostriatal dopaminergic defect in Unverricht-Lundborg disease. *Epilepsia* 2007;48(9):1768–73.
- [13] Koskenkorva P, Khyuppenen J, Niskanen E, Kononen M, Bendel P, Mervaala E, et al. Motor cortex and thalamic atrophy in Unverricht-Lundborg disease: voxel-based morphometric study. *Neurology* 2009;73(8):606–11. <https://doi.org/10.1212/WNL.0b013e3181b3888b>.
- [14] Muccioli L, Farolfi A, Pondrelli F, d'Orsi G, Michelucci R, Freri E, et al. FDG-PET assessment and metabolic patterns in Lafora disease. *Eur J Nucl Med Mol Imaging* 2020;47(6):1576–84. <https://doi.org/10.1007/s00259-019-04647-3>.
- [15] Kim JH, Im KC, Kim JS, Lee S-A, Kang JK. Correlation of interictal spike-wave with thalamic glucose metabolism in juvenile myoclonic epilepsy. *NeuroReport* 2005;16(11):1151–5.