


Clinical characteristics and course of sporadic non-ampullary duodenal adenomas

A multicenter retrospective study

Hiromitsu Kanzaki, MD, PhD^{a,*} , Kazuhiro Matsueda, MD, PhD^b, Masahiro Nakagawa, MD, PhD^c, Tomoki Inaba, MD, PhD^d, Masahiro Takatani, MD, PhD^e, Ryuta Takenaka, MD, PhD^f, Masao Yoshioka, MD, PhD^g, Atsushi Imagawa, MD, PhD^h, Masafumi Inoue, MD, PhDⁱ, Seiyuu Suzuki, MD, PhD^j, Jun Tomoda, MD, PhD^k, Masaya Iwamuro, MD, PhD^a, Seiji Kawano, MD, PhD^a, Yoshiro Kawahara, MD, PhD^l, Takehiro Tanaka, MD, PhD^m, Hiroyuki Okada, MD, PhD^{a,n}

Abstract

Sporadic non-ampullary duodenal adenoma (SNADA) is a rare disease, and therefore, its clinical characteristics have not been comprehensively investigated. Furthermore, owing to the high complication rates and severity of endoscopic resection, treatment strategies vary among facilities. In the present study, we aimed to clarify the clinical characteristics and course of SNADA.

We extracted clinical and histological records of SNADA cases diagnosed in 11 hospitals between September 1999 and August 2014. The patients were divided into “no-resection” and “resection” groups based on the initial treatment approach. We investigated the long-term outcome of the “no-resection” group and treatment results of the “resection” group, with particular interest in endoscopic resection.

Overall, 299 patients were diagnosed with SNADA. The median age at diagnosis was 67 years (range, 31–88 years), with approximately twice as many men as women. The median tumor size was 8.0 mm (2–60 mm). In total, 161 patients were initially selected for no-resection and 138 underwent resection. Age >70 years and the presence of either severe illness or poor performance status were significantly related to opting for no-resection. In the no-resection group, 101 patients underwent endoscopic follow-up for at least 1 year. During the observational period (2.5 ± 2.2 years), 27 lesions (27%) disappeared following cold forceps biopsy, and 13 lesions (14%) presented lateral growth. Four lesions (4%) changed to mucosal carcinoma, 3 were treated endoscopically, and 1 was surgically resected. Nineteen patients died; however, no one died of duodenal carcinoma. In the endoscopic resection group, en bloc resection was achieved in 78% of patients. However, the complication rate for perforation was 7%, and endoscopic submucosal dissection was associated with a 36% perforation rate.

With the low incidence of cancer development and no disease specific death, the strategy of initially not performing resection could be considered especially for the older adults, poor-prognosis patients, or small lesions.

Editor: Xingshun Qi.

Participating facilities are Okayama University Hospital, Kurashiki Central Hospital, Hiroshima City Hiroshima Citizens Hospital, Kagawa Prefectural Hospital, Japanese Red Cross Society Himeji Hospital, Tsuyama Chuo Hospital, Okayama Saiseikai General Hospital, Japanese Red Cross Okayama Hospital, Mitoyo General Hospital, Sumitomo Besshi Hospital, and Akaiwa Medical Association Hospital.

The authors of this work have nothing to disclose.

The authors have no conflicts of interest to disclose.

Supplemental Digital Content is available for this article.

The datasets generated during and/or analyzed during the current study are available from the corresponding author on reasonable request.

^aDepartment of Gastroenterology and Hepatology, Okayama University Hospital, Okayama, Okayama, Japan, ^bDepartment of Gastroenterology and Hepatology, Kurashiki Central Hospital, Kurashiki, Okayama, Japan, ^cDepartment of Endoscopy, Hiroshima City Hiroshima Citizens Hospital, Hiroshima, Hiroshima, Japan, ^dDepartment of Gastroenterology, Kagawa Prefectural Central Hospital, Takamatsu, Kagawa, Japan, ^eDepartment of Internal Medicine, Japanese Red Cross Society Himeji Hospital, Himeji, Hyogo, Japan, ^fDepartment of Internal Medicine, Tsuyama Chuo Hospital, Tsuyama, Okayama, Japan, ^gDepartment of Internal Medicine, Okayama Saiseikai General Hospital, Okayama, Okayama, Japan, ^hDepartment of Gastroenterology, Mitoyo General Hospital, Kanonji, Kagawa, Japan, ⁱDepartment of Gastroenterology, Japanese Red Cross Okayama Hospital, Okayama, Okayama, Japan, ^jDepartment of Internal Medicine, Sumitomo Besshi Hospital, Niihama, Ehime, Japan, ^kDepartment of Internal Medicine, Akaiwa Medical Association Hospital, Akaiwa, Okayama, Japan, ^lDepartment of Practical Gastrointestinal Endoscopy, Okayama University Graduate School of Medicine, Dentistry and Pharmaceutical Sciences, Okayama, Okayama, Japan, ^mDepartment of Pathology, Okayama University Graduate School of Medicine, Dentistry and Pharmaceutical Sciences, Okayama, Okayama, Japan, ⁿDepartment of Gastroenterology and Hepatology, Okayama University Graduate School of Medicine, Dentistry and Pharmaceutical Sciences, Okayama, Okayama, Japan.

* Correspondence: Hiromitsu Kanzaki, Department of Gastroenterology and Hepatology, Okayama University Hospital, 2-5-1 Shikata-cho, Kita-Ku, Okayama 700-8558, Japan (e-mail: kanzaki@qc4.so-net.ne.jp).

Copyright © 2021 the Author(s). Published by Wolters Kluwer Health, Inc.

This is an open access article distributed under the terms of the Creative Commons Attribution-Non Commercial License 4.0 (CCBY-NC), where it is permissible to download, share, remix, transform, and build upon the work provided it is properly cited. The work cannot be used commercially without permission from the journal.

How to cite this article: Kanzaki H, Matsueda K, Nakagawa M, Inaba T, Takatani M, Takenaka R, Yoshioka M, Imagawa A, Inoue M, Suzuki S, Tomoda J, Iwamuro M, Kawano S, Kawahara Y, Tanaka T, Okada H. Clinical characteristics and course of sporadic non-ampullary duodenal adenomas: a multicenter retrospective study. *Medicine* 2021;100:39(e27382).

Received: 10 July 2020 / Received in final form: 15 July 2021 / Accepted: 11 September 2021

<http://dx.doi.org/10.1097/MD.00000000000027382>

Abbreviations: EGD = esophagogastroduodenoscopy, EMR = endoscopic mucosal resection, ESD = endoscopic submucosal dissection, FAP = familial adenomatous polyposis, SNADA = sporadic non-ampullary duodenal adenoma.

Keywords: duodenal neoplasms, endoscopic mucosal resection, natural history

1. Introduction

Non-ampullary duodenal adenomas are rare tumors of the gastrointestinal tract.^[1] With growing opportunities to perform esophagogastroduodenoscopy (EGD), the rate at which non-ampullary duodenal adenoma is detected might be increasing. Although familial adenomatous polyposis (FAP) and MUTYH-associated polyposis are recognized as a condition that predisposes patients to this disease, several cases are sporadic and are incidentally detected.

It has been postulated that a duodenal adenoma follows the same adenoma-carcinoma sequence as colonic adenomas.^[2] Based on this hypothesis, it is crucial to resect the lesion before it progresses into carcinoma. Previously, some reports have elaborated on the natural history of duodenal adenoma in FAP.^[3,4] One study has investigated the natural history of sporadic non-ampullary duodenal adenoma (SNADA) and noted that it was associated with a low risk of cancerization^[5]; however, there have been little reports on the natural history of SNADA.

Furthermore, while some reports have focused on surgical resection, others have emphasized endoscopic resection techniques, including endoscopic mucosal resection (EMR) and endoscopic submucosal dissection (ESD).^[6–15] Although endoscopic resection is the method most commonly employed to treat SNADA, it is associated with a higher rate of complications and more severe complications than gastric and colonic treatment.^[10,12,13] Although ESD tends to be performed for larger lesions, the perforation rate reportedly ranges between 8% and 50%, even when performed at specialized institutions.^[8–13] Surgical treatment has been described as safe, and complete resection can be achieved^[14]; however, it is associated with a higher degree of surgical stress than endoscopic treatment. Furthermore, several previous reports were those from high-volume centers, and the complication rate in general hospitals is predicted to be higher than the rates described in previous studies.

As resection of lesions is associated with a non-negligible risk of complications, not all patients undergo resection, with some patients simply observed without performing resection in real-world clinical settings. In the present study, we performed a retrospective multicenter observational study to clarify the clinical characteristics and course of SNADA by following the course of patients who underwent observation without resection and those who underwent resection.

2. Methods

2.1. Study design

We enrolled patients with non-ampullary duodenal adenoma who were histologically diagnosed at 11 hospitals from November 1999 to April 2014. The inclusion criteria were as follows: histologically diagnosed as duodenal adenoma located in the duodenum. Patients with lesions located on or connected to the ampulla and those diagnosed with FAP or MUTYH-associated polyposis were excluded from the present study.

The included cases were collected from the clinical database of pathology departments at each facility. Although only consecutive cases were enrolled, the inclusion period differed among participating facilities. The study protocol was approved by the ethics committees of Okayama University Hospital and affiliated hospitals, and informed consent was obtained using an opt-out method.

2.2. Data collection

The following clinicopathological data were collected from patients' medical records: age, sex, medical history, comorbidity of malignant tumor, Eastern Cooperative Oncology Group Performance Status, the reason for receiving endoscopy, lesion site, tumor size, morphological type, initial treatment method, treatment result, complications, survival outcome, and cause of death. In cases involving patients with multiple lesions, the lesion with the largest size or highest grade was adopted for the baseline characteristics and analysis of the long-term outcome. Histological grade was categorized based on the Vienna classification.^[16] We considered Vienna classification category 3 (low-grade adenoma), 4.1 (high-grade adenoma), and ≥ 4.2 as carcinoma.

The patients were divided into the no-resection and resection groups based on the initial treatment approach, which was decided at each facility after a discussion between patients and physicians. Patients who did not undergo resection within 1 year of the SNADA diagnosis were classified into the no-resection group; those who underwent resection within 1 year were classified into the resection group.

Survival outcome and cause of death were investigated in all patients in the no-resection group. Moreover, to investigate the long-term outcomes of endoscopic findings of the lesions, we examined changes in lesion size and performed a histological assessment during the observational period. In the no-resection group with endoscopic follow-up analysis, cases in which the endoscopic follow-up period was less than 1 year (except for patients in whom the lesion disappeared within 1 year) were excluded.

The analysis of endoscopic treatment outcomes included cases in which endoscopic resection was performed by any method and at any time. The analysis of factors associated with endoscopic treatment outcomes included the endoscopic procedure, en bloc resection rate, and complications.

2.3. Statistical analyses

Wilcoxon rank-sum test was used to compare continuous variables. The χ^2 test or Fisher exact test was used to compare categorical variables. The cutoff points of lesion size for lesions that disappeared or grew were determined by receiver operator characteristics curve analysis. The Kaplan-Meier method was used to represent the survival outcome. Two-sided *P* values $< .05$ were considered to indicate statistical significance. All statistical analyses were performed using the JMP Pro software program (version 12; SAS Institute Inc., Cary, NC).

Table 1
The patient and lesion characteristics.

| Patients | 299 |
|-------------------------------|------------|
| Age (median, range) year | 67 (31–88) |
| Male/female | 185/114 |
| Comorbidity of malignancy | |
| All (%) | 75 (25) |
| Colorectal cancer (%) | 14 (5) |
| Gastric cancer (%) | 28 (10) |
| Others (%) | 39 (16) |
| Reason of receiving endoscopy | |
| Symptomatic/screening | 51/248 |
| Initial treatment | |
| No-resection/resection | 161/138 |
| Lesions | 303 |
| Location | |
| Oral-Vater/anal-Vater | 142/161 |
| Size (median, range) mm | 8 (2–60) |
| Histological grade | |
| LGA/HGA | 278/25 |
| Morphology | |
| Protruded/superficial | 106/197 |
| Initial treatment | |
| No-resection/resection | 161/142 |

Anal-Vater = anal side of the Vater, LGA = low-grade adenoma, HGA = high-grade adenoma, oral-Vater = oral side of the Vater.

3. Results

3.1. Patient and lesion characteristics

This multicenter retrospective study included 303 lesions in 299 patients. Table 1 shows the characteristics of all patients and lesions. The male:female ratio was approximately 2:1. EGD was mainly performed for screening purposes. The lesion locations

were almost evenly distributed between the oral side of the Vater and the anal side of the Vater. Moreover, superficial-type lesions were approximately twice as frequent as protruded-type lesions.

3.2. Analysis of factors associated with the selection of the initial treatment strategy

The patient flow is shown in Figure 1. In total, 161 patients were initially selected for no-resection. Overall, 142 lesions in 138 patients were initially treated by endoscopic or surgical resection. Table 2 shows the initial treatment strategy according to patient and lesion characteristics. The option of no-resection was more significantly and frequently selected in patients >70 years of age and those with severe illness or Eastern Cooperative Oncology Group Performance Status >2. In contrast, resection was significantly more frequently selected in cases involving lesions >10 mm in size and protruded-type lesions.

3.3. Long-term outcomes of no-resection group

During the median observation period of 2.3 years (0–11.4), 19 patients died (see Figure S1, Supplemental Digital Content, <http://links.lww.com/MD2/A505> which shows the Kaplan-Meier plots for survival of no-resection group). Ten patients died owing to malignant neoplasia; of the remaining 9 patients, 1 patient each died of the following causes: alcoholic liver dysfunction, renal dysfunction, rupture of aortic aneurysm, CREST (calcinosis, Raynaud phenomenon, esophageal dysmotility, sclerodactyly, and telangiectasia) syndrome, thromboangiitis obliterans, old age, suicide, sudden death, and unknown cause. No patient died of duodenal carcinoma.

After excluding 60 patients who did not receive follow-up endoscopy or who underwent endoscopic follow-up for less than 1 year, 101 patients were investigated in the no-resection with

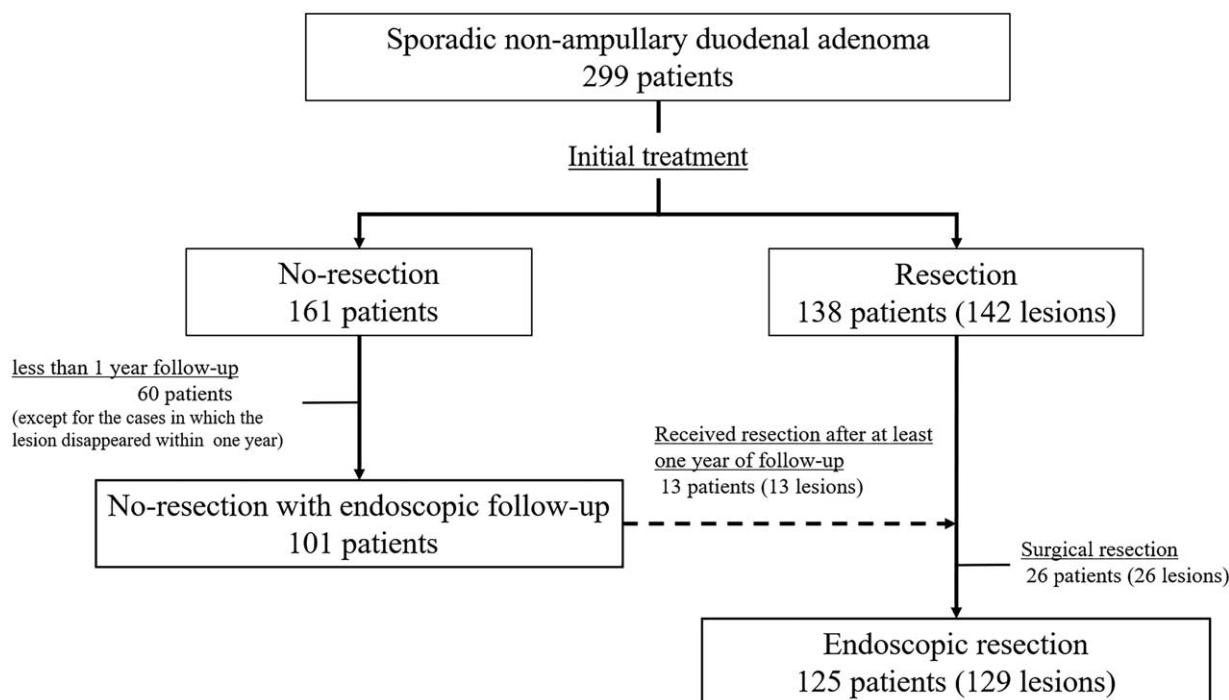


Figure 1. Patient flow.

Table 2
Background factors related to the initial treatment strategy.

| Patients | No-resection (n = 161) | Resection (n = 138) | P |
|--|---------------------------|------------------------|-------|
| Over 70 years of age | 77 (48%) | 43 (31%) | .004 |
| Comorbidity of severe illness or ECOG-PS > 2 | 21 (13%) | 4 (3%) | .003 |
| Lesions | No-resection (n = 161) | Resection (n = 142) | |
| Size (over 10 mm) | 32 (20%) | 68 (48%) | <.001 |
| Histology (HGA) | 9 (6%) | 16 (11%) | n.s |
| Morphology (protruded) | 45 (28%) | 61 (43%) | .007 |
| Location (oral-Vater) | 67 (42%) | 78 (55%) | n.s |

ECOG-PS = Eastern Cooperative Oncology Group Performance Status, HGA = high-grade adenoma, n.s = not significant, oral-Vater = oral side of the Vater.

endoscopic follow-up group. During the median observation period of 2.7 years (0.2–11.4), several patients showed no marked change in lesion size (51/101, 50%); in 27 (27%) cases, the lesions disappeared, while the lesions shrank in 10 (10%) cases and grew in 13 (13%) cases (Fig. 2). Thirteen of these lesions were ultimately resected during follow-up owing to the following reasons: lesion growth (n=6), a change into carcinoma (n=2) as assessed by biopsy specimens, or because the patient indicated that they wished to undergo resection (n=5). The histological diagnosis was altered to carcinoma in 4 cases (4%). Three lesions were treated endoscopically and 1 was surgically resected. All lesions were finally diagnosed as mucosal carcinoma. These lesions had been followed for 608, 652, 1353, and 1554 days before resection, with 3 lesions found to be enlarged during follow-up. The morphology was superficial elevated type in 3 cases and protruded-type in 1 case, with no lesion presenting morphological change.

Univariable analyses were performed to determine the factors associated with the disappearance and enlargement of lesions (Table 3). The cutoff values of lesion sizes for disappearance and enlargement were <6 mm and >10 mm, respectively, and were

determined by receiver operator characteristics curve analysis. Using these cutoff values, the sensitivity, specificity, and area under the curve for lesion disappearance were 92.6%, 71.6%, and 0.879, respectively, and were 76.9%, 72.7%, and 0.762, for lesion enlargement, respectively. Univariate analyses revealed that a lesion size <6 mm was significantly associated with lesion disappearance (odds ratio, 31.54 [95% confidence interval (CI): 8.40–207.21], $P < .001$), and a lesion size >10 mm was significantly associated with lesion enlargement (odds ratio 8.89 [95% CI: 2.48–42.22], $P < .001$).

3.4. Short-term outcome of resection group

In the no-resection group, 13 lesions underwent resection after at least 1 year of follow-up, and the data related to resection were included in the endoscopic resection analysis (Table 4). Overall, 129 lesions underwent endoscopic resection, while 26 lesions were surgically treated. There were no cases of additional surgery following endoscopic resection because of the recurrence risk of cancer. Surgical treatment was selected because of a large tumor size, diagnosis of cancer, or difficulty of endoscopic resection in each hospital. The en bloc resection rate of the endoscopic treatment was 78% (101/129). The complication rate was 9% (11/129), with perforation observed in 9 cases and post-intervention bleeding in 2 cases. There were 2 treatment strategies: EMR and ESD (EMR, n=118; ESD, n=11). The patients who received ESD were significantly younger than that of those who underwent EMR. Although the en bloc resection rates of EMR and ESD were 78% and 82%, respectively, the perforation rate following ESD was significantly higher than that observed with EMR (36% and 4%, respectively). The univariate analysis of factors associated with perforation showed that the treatment strategy of ESD, when compared with EMR, was significantly associated with perforation (odds ratio 12.91 [95% CI: 2.71–60.91], $P = .002$) (see Table S1, Supplemental Digital Content, <http://links.lww.com/MD2/A506> which shows the univariable analysis of factors associated with perforation). Three lesions were not subjected to a histological evaluation after

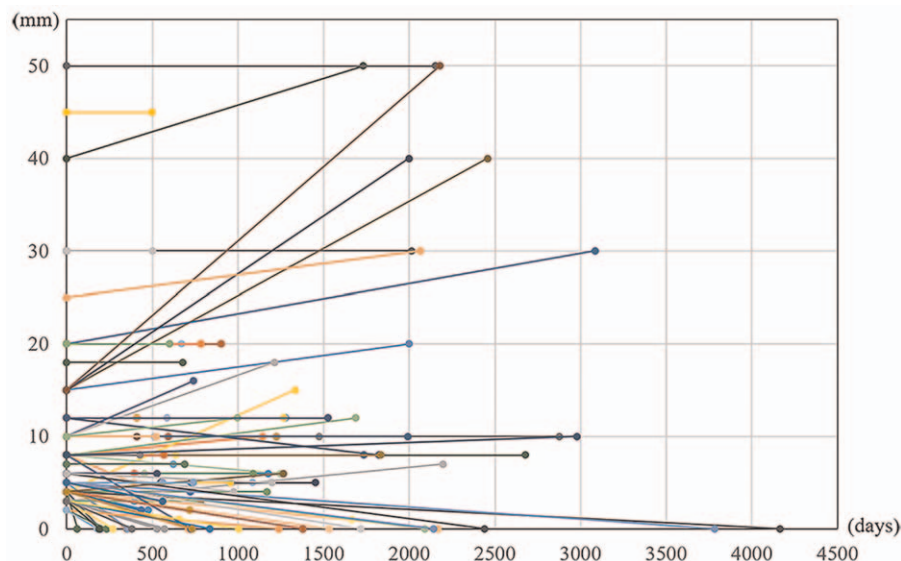


Figure 2. The change in the tumor size between the initial endoscopic examination and the final examination in the no-resection group.

Table 3**The results of a univariable analysis of the characteristics associated with lesion disappearance and enlargement.**

| | | n | Odds ratio (95% confidence interval) | P |
|-------------------------------------|-------------------------------------|-------------------|--------------------------------------|-------|
| Disappearance | Tumor size | ≥6 mm | 1 | <.001 |
| | | <6 mm | 31.54 (6.86–145.16) | |
| | Location | Oral-Vater | 1 | n.s |
| | | Anal-Vater | 1.08 (0.43–2.75) | |
| | Morphology | Protruded | 1 | n.s |
| Superficial | | 1.58 (0.56–4.43) | | |
| Histological grade at the diagnosis | HGA | 1 | n.s | |
| | LGA | 2.72 (0.32–23.27) | | |
| Enlargement | Tumor size | <10 mm | 1 | <.001 |
| | | ≥10 mm | 8.89 (2.25–35.08) | |
| | Location | Anal-Vater | 1 | n.s |
| | | Oral-Vater | 1.22 (0.35–4.30) | |
| | Morphology | Protruded | 1 | n.s |
| | | Superficial | 5.6 (0.69–45.2) | |
| | Histological grade at the diagnosis | HGA | 1 | n.s |
| | | LGA | 1.04 (0.12–9.19) | |

Anal-Vater = anal side of the Vater, HGA = high-grade adenoma, LGA = low-grade adenoma, n.s = not significant, oral-Vater = oral side of the Vater.

resection, while 126 lesions underwent histological examination after resection. Although all lesions were diagnosed as adenoma using a biopsy specimen, the histological diagnosis of 22 lesions (18%) was altered to carcinoma after resection. Univariate analysis showed that the only factor associated with a diagnostic change to carcinoma was a histological diagnosis of high-grade adenoma before resection (see Table S2, Supplemental Digital Content, <http://links.lww.com/MD2/A507> which shows the univariable analysis of characteristics associated with lesion diagnosed as carcinoma after endoscopic resection).

4. Discussion

The present study included 299 SNADA patients who were managed at 11 institutions. As in previous reports,^[10,12] patients were predominantly male, with a median age of 67 years. In several cases, the lesion was detected incidentally by EGD screening, and 25% of patients had malignant comorbidities. A previous report has described gastric cancer and colorectal cancer as comorbidities of SNADA.^[17] The same tendency was

observed; however, this relationship could be attributed to gastrointestinal malignant tumor patients tending to undergo EGD, resulting in the incidental detection of these lesions.

Regarding the treatment strategy, approximately 50% of the patients underwent treatment, while the remainder were initially observed without resection. Although endoscopic treatment of gastrointestinal superficial tumors is the standard practice in Japan, the risk of complications, particularly perforation, is well known in clinical settings.^[18] In the present study, a no-resection treatment strategy was generally applied in selected patients predicted to have a poor prognosis or smaller lesions. None of the patients in the no-resection group died because of duodenal cancer. Furthermore, 19 deaths were recorded because of other causes. Although a short observation period must be considered, our findings suggest that observation without resection may be a viable strategy for cases with a poor performance status and those expected to have a poor prognosis.

Four lesions (4%) in the no-resection group were diagnosed with carcinoma during the observational period. All cases were ultimately diagnosed as mucosal carcinoma and were cured by

Table 4**The en bloc resection and complication rates of EMR and ESD. There was no significant difference in the en bloc resection rates; however, the perforation rate was significantly higher in the ESD group. P value shows the difference between EMR and ESD.**

| | All (n = 129) | EMR (n = 118) | ESD (n = 11) | P |
|---------------------------------|----------------------------------|----------------------------------|-------------------------------|-------|
| Age (median, range, year) | 66 (34–85) | 67 (34–85) | 57 (45–66) | .002 |
| Male/female | 77 / 52 | 71 / 47 | 6 / 5 | n.s |
| Size (median, range, mm) | 10 (2–25) | 10 (2–40) | 10 (5–25) | n.s |
| Location (anal-Vater) | 72 (56%) | 66 (56%) | 6 (55%) | n.s |
| Morphology (superficial) | 74 (57%) | 64 (54%) | 10 (91%) | .04 |
| Histology after resection | | | | |
| LGA/HGA/carcinoma/not evaluated | 94 (73%)/10 (8%)/22 (17%)/3 (2%) | 86 (73%)/10 (8%)/19 (16%)/3 (2%) | 8 (73%)/0 (0%)/3 (27%)/0 (0%) | n.s |
| En bloc resection | 101 (78%) | 92 (78%) | 9 (82%) | n.s |
| Complication | 11 (9%) | 7 (6%) | 4 (36%) | <.001 |
| Perforation | 9 (7%) | 5 (4%) | 4 (36%) | <.001 |
| Postbleeding | 2 (2%) | 2 (2%) | 0 (0%) | n.s |

Anal-Vater = anal side of the Vater, EMR = endoscopic mucosal resection, ESD = endoscopic submucosal dissection, HGA = high-grade adenoma, LGA = low-grade adenoma, n.s = not significant.

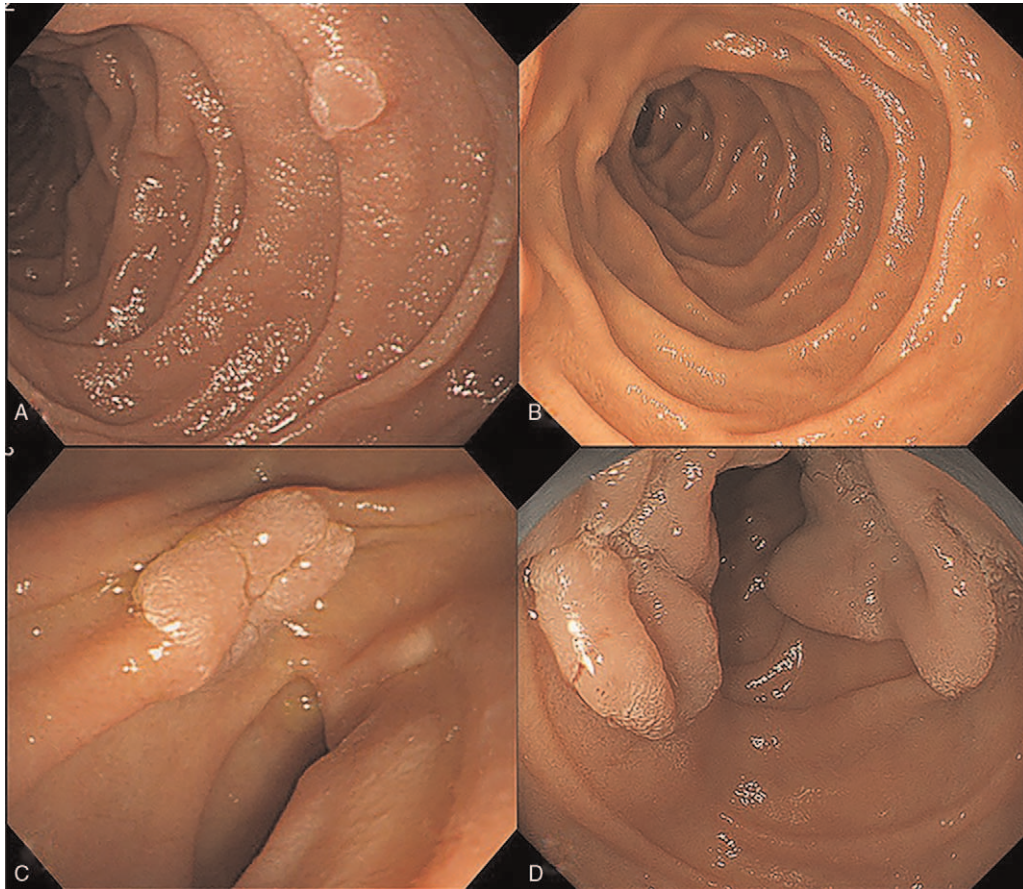


Figure 3. The disappearance and growth of lesions in the no-resection group. (A) A 4-mm superficial elevated lesion can be observed in the descending part of the duodenum. A cold forceps biopsy was performed, and the histological diagnosis is low-grade adenoma. (B) No residual tumor can be observed after 16 years. (C) A 12-mm superficial elevated lesion can be observed at the inferior duodenal flexure. The histological diagnosis of a biopsy specimen is low-grade adenoma. (D) The lesion grew to over 60mm over a 7-year period; however, the histological diagnosis remains low-grade adenoma.

local resection. In FAP cases, the incidence of duodenal carcinoma is 3%, despite the occurrence of duodenal adenomas in most patients.^[19] Numerous small duodenal adenomas are followed up for several years.^[20,21] Careful monitoring is required for carcinogenesis; however, observation without resection could be considered for SNADA as similar to FAP.

Lesions <6 mm in size were predicted to disappear during follow-up; this was predicted with high sensitivity and area under the curve. This phenomenon could be attributed to the performance of cold forceps biopsy. Generally, a pre-treatment biopsy should be avoided owing to the risk of biopsy-induced fibrosis, which can hamper endoscopic resection.^[15] However, in the present study, small lesions could be resolved by cold forceps biopsy, which might be a feasible approach for performing cold forceps polypectomy for small lesions. Based on this finding, we are conducting a prospective study on the efficacy of cold forceps polypectomy for <6 mm which was registered at the University Hospital Medical Information Network 000025913. In contrast, a 12 mm lesion, initially diagnosed in 1 patient had grown over 60 mm in size by the 7-year follow-up (Fig. 3). On histological examination, the final biopsy specimen was revealed as a low-grade adenoma, and hence, follow-up continued; however, endoscopic resection might be increasingly difficult and riskier than before owing to the size and biopsy-induced fibrosis.

Although the sensitivity and specificity were not substantially high, certain lesions >10 mm may increase in size. These lesions should be considered for the resection at the initial diagnosis.

ESD tended to be performed in younger patients or those presenting superficial-type lesions, and the lesion size, location, and en bloc resection rate were approximately the same as that of patients who underwent EMR. The target lesions undergoing ESD were not exceedingly large, and hence, a 36% perforation rate is unacceptable for clinical application at a general hospital. Certain reports have described the clear benefits of ESD over EMR in terms of achieving complete resection of large tumors.^[8–11,13–15] However, considering the high perforation rate, ESD should only be performed for SNADA at specialized institutions and not at general hospitals. Several studies have highlighted strategies for the prevention of perforation after duodenal ESD.^[22,23] The endoscopic closure method is one such promising technique, with the widespread clinical use of this method being highly desired. There have been several reports on piecemeal EMR for SNADA.^[24–26] Although the local recurrence rate in these reports was non-negligible, many such cases were safely and completely managed by re-endoscopic treatment. Given the perforation risk, piecemeal EMR might be an acceptable strategy for treating large lesions in general hospitals. Furthermore, underwater EMR has been reported as a safe and effective

SNADA treatment method.^[27,28] Cold polypectomy is a safe and effective treatment strategy for small SNADA lesions.^[29] With the development of safety treatment methods, the selection of no-resection may be decreased. However, for patients who expected to have a poor prognosis, the necessity of resection for the patient should be fully considered.

Our study had several limitations. First, this was a retrospective, multicenter study. Differences in treatment strategies and follow-up methods among institutions and time points may cause selection bias and compromise data quality. However, considering the rarity of SNADA, a retrospective analysis may be acceptable. Furthermore, to avoid selection bias, we collected data on both non-resected and resected cases as a multifacility trial. Second, histological assessments were performed in each hospital. The histological diagnosis of duodenal epithelial tumors is challenging even when performed by an expert pathologist. Although we confirmed that there were qualified pathologists with expertise in gastroenterology at all institutions, differences among the pathologists might have resulted in uncertainty in the histological grade, or whether neoplastic or non-neoplastic. However, we believe that the analysis of the clinical course of cases diagnosed with SNADA at each institution provided clinically useful data. Finally, the observation period to investigate adenoma prognosis was relatively short to adenomas. In this study, only certain cases were followed up for 1 year. However, 40 of 101 cases were followed up for at least 3 years, and 13 of 101 cases were followed up for more than 5 years. We believe that this was a sufficient period to discuss the safety of no-resection as a treatment strategy.

In conclusion, SNADA tends to occur as small lesions in older men. The low incidence of cancer development and no disease-specific death demonstrate that the strategy of initially not performing resection could be one of the considered treatment method especially for the older adults, poor-prognosis patients, or small lesions.

Author contributions

Conceptualization: Hiromitsu Kanzaki.

Data curation: Hiromitsu Kanzaki, Kazuhiro Matsueda, Masahiro Nakagawa, Tomoki Inaba, Masahiro Takatani, Ryuta Takenaka, Masao Yoshioka, Atsushi Imagawa, Masafumi Inoue, Seiyuu Suzuki, Jun Tomoda.

Formal analysis: Hiromitsu Kanzaki.

Supervision: Jun Tomoda, Masaya Iwamuro, Seiji Kawano, Yoshiro Kawahara, Takehiro Tanaka, Hiroyuki Okada.

Writing – original draft: Hiromitsu Kanzaki.

Writing – review & editing: Hiromitsu Kanzaki.

References

- Culver EL, McIntyre AS. Sporadic duodenal polyps: classification, investigation, and management. *Endoscopy* 2011;43:144–55.
- Van Heumen BW, Mul K, Nagtegaal ID, van Kouwen MC, Nagengast FM. Management of sporadic duodenal adenomas and the association with colorectal neoplasms: a retrospective cohort study. *J Clin Gastroenterol* 2012;46:390–6.
- Matsumoto T, Iida M, Nakamura S, et al. Natural history of ampullary adenoma in familial adenomatous polyposis: reconfirmation of benign nature during extended surveillance. *Am J Gastroenterol* 2000;95:1557–62.
- Burke CA, Beck GJ, Church JM, van Stolk RU. The natural history of untreated duodenal and ampullary adenomas in patients with familial adenomatous polyposis followed in an endoscopic surveillance program. *Gastrointest Endosc* 1999;49(3 Pt 1):358–64.
- Okada K, Fujisaki J, Kasuga A, et al. Sporadic nonampullary duodenal adenoma in the natural history of duodenal cancer: a study of follow-up surveillance. *Am J Gastroenterol* 2011;106:357–64.
- Singh A, Siddiqui UD, Konda VJ, et al. Safety and efficacy of EMR for sporadic, nonampullary duodenal adenomas: a single U.S. center experience (with video). *Gastrointest Endosc* 2016;84:700–8.
- Tomizawa Y, Ginsberg GG. Clinical outcome of EMR of sporadic, nonampullary, duodenal adenomas: a 10-year retrospective. *Gastrointest Endosc* 2018;87:1270–8.
- Nonaka S, Oda I, Tada K, et al. Clinical outcome of endoscopic resection for nonampullary duodenal tumors. *Endoscopy* 2015;47:129–35.
- Yamamoto Y, Yoshizawa N, Tomida H, Fujisaki J, Igarashi M. Therapeutic outcomes of endoscopic resection for superficial nonampullary duodenal tumor. *Dig Endosc* 2014;26(Suppl 2):50–6.
- Kakushima N, Ono H, Takao T, Kanemoto H, Sasaki K. Method and timing of resection of superficial non-ampullary duodenal epithelial tumors. *Dig Endosc* 2014;26(Suppl 2):35–40.
- Yahagi N, Kato M, Ochiai Y, et al. Outcomes of endoscopic resection for superficial duodenal epithelial neoplasia. *Gastrointest Endosc* 2018;88:676–82.
- Goda K, Kikuchi D, Yamamoto Y, et al. Endoscopic diagnosis of superficial non-ampullary duodenal epithelial tumors in Japan: multicenter case series. *Dig Endosc* 2014;26(Suppl 2):23–9.
- Inoue T, Uedo N, Yamashina T, et al. Delayed perforation: a hazardous complication of endoscopic resection for non-ampullary duodenal neoplasm. *Dig Endosc* 2014;26:220–7.
- Abe N, Suzuki Y, Masaki T, Mori T, Sugiyama M. Surgical management of superficial non-ampullary duodenal tumors. *Dig Endosc* 2014;26(Suppl 2):57–63.
- Ochiai Y, Kato M, Kiguchi Y, et al. Current status and challenges of endoscopic treatments for duodenal tumors. *Digestion* 2019;99:21–6.
- Dixon MF. Gastrointestinal epithelial neoplasia: Vienna revisited. *Gut* 2002;51:130–1.
- Maruoka D, Arai M, Ishigami H, et al. Sporadic nonampullary duodenal adenoma/carcinoma is associated with not only colon adenoma/carcinoma but also gastric cancer: association of location of duodenal lesions with comorbid diseases. *Scand J Gastroenterol* 2015;50:333–40.
- Kakushima N, Kanemoto H, Tanaka M, Takizawa K, Ono H. Treatment for superficial non-ampullary duodenal epithelial tumors. *World J Gastroenterol* 2014;20:12501–8.
- Spigelman AD, Talbot IC, Penna C, et al. Evidence for adenoma-carcinoma sequence in the duodenum of patients with familial adenomatous polyposis. The Leeds Castle Polyposis Group (Upper Gastrointestinal Committee). *J Clin Pathol* 1994;47:709–10.
- Campos FG, Sulbaran M, Safatle-Ribeiro AV, Martinez CA. Duodenal adenoma surveillance in patients with familial adenomatous polyposis. *World J Gastrointest Endosc* 2015;7:950–9.
- Vasen HF, Möslein G, Alonso A, et al. Guidelines for the clinical management of familial adenomatous polyposis (FAP). *Gut* 2008;57:704–13.
- Yamasaki Y, Uedo N, Takeuchi Y, Ishihara R, Okada H, Iishi H. Current status of endoscopic resection for superficial nonampullary duodenal epithelial tumors. *Digestion* 2018;97:45–51.
- Takimoto K, Imai Y, Matsuyama K. Endoscopic tissue shielding method with polyglycolic acid sheets and fibrin glue to prevent delayed perforation after duodenal endoscopic submucosal dissection. *Dig Endosc* 2014;26(Suppl 2):46–9.
- Klein A, Nayyar D, Bahin FF, et al. Endoscopic mucosal resection of large and giant lateral spreading lesions of the duodenum: success, adverse events, and long-term outcomes. *Gastrointest Endosc* 2016;84:688–96.
- Valerii G, Tringali A, Landi R, et al. Endoscopic mucosal resection of non-ampullary sporadic duodenal adenomas: a retrospective analysis with long-term follow-up. *Scand J Gastroenterol* 2018;53:490–4.
- Alexander S, Bourke MJ, Williams SJ, Bailey A, Co J. EMR of large, sessile, sporadic nonampullary duodenal adenomas: technical aspects and long-term outcome (with videos). *Gastrointest Endosc* 2009;69:66–73.
- Binmoeller KF, Shah JN, Bhat YM, Kane SD. ‘Underwater’ EMR of sporadic laterally spreading nonampullary duodenal adenomas (with video). *Gastrointest Endosc* 2013;78:496–502.
- Yamasaki Y, Uedo N, Takeuchi Y, et al. Underwater endoscopic mucosal resection for superficial nonampullary duodenal adenomas. *Endoscopy* 2018;50:154–8.
- Maruoka D, Matsumura T, Kasamatsu S, et al. Cold polypectomy for duodenal adenomas: a prospective clinical trial. *Endoscopy* 2017;49:776–83.