



## Case Report

# Drainage of Periappendiceal Abscess and Removal of Free Fecalith—Extraperitoneal Approach

Chian-Ro Chang<sup>1</sup>, Che-Yu Cheng<sup>2</sup>

<sup>1</sup>Department of Surgery and <sup>2</sup>Department of Radiology, West-Garden Hospital, Taipei, Taiwan, Republic of China

Treatment of complicated acute appendicitis is controversial. The dilemma is further complicated by presence of free fecalith in a well-circumscribed abscess, which has been repeatedly demonstrated to be a major predicting factor of treatment failure of nonoperative treatment of acute appendicitis complicated with appendiceal abscess. If left behind after drainage of the abscess, further operations for removal of retained fecalith or recurrence of abscess might be required. However, little had been stressed over the significance of removal of the free fecalith when it was first encountered. We report our experience of drainage of appendiceal abscess and removal of free fecalith by taking an extraperitoneal approach. Both of our cases made a smooth recovery without any complication or recurrence after a 2-year follow-up. Treatment with this approach avoids many of the complications associated with formal laparotomy. Unlike image-guided drainage or laparoscopic drainage, this procedure is relatively simple and straightforward and can be performed in any level of hospital, including private practitioners and in less well-developed areas and countries. With proper case selection, we recommend this approach as one of the alternatives in the treatment of late-presenting appendiceal abscess with free fecalith.

*Key words:* Acute appendicitis – Extra-peritoneal drainage – Periappendiceal abscess – Free fecalith

**M**anagement of acute appendicitis complicated with peri-appendiceal abscess is controversial. Immediate surgery provides definitive treatment, but is associated with high intra-abdominal and wound complication rates. Nonsurgical treat-

ments, such as the administration of parenteral antibiotics and close observation, with or without image-guided drainage, had been shown to achieved a 90% success rate in reported series, and is therefore the preferred method in most institutes.<sup>1</sup>

---

Reprint requests: Chian-Ro Chang, Department of Surgery, West-Garden Hospital, 276 Sec. 2 Hsi-Yuan Rd. Taipei, Taiwan, Republic of China.  
Tel: +886-2-23076968; Fax: +886-2-2303-3163; E-mail: [www.bookgolfer@yahoo.com.tw](mailto:www.bookgolfer@yahoo.com.tw)

However, treatment failure and recurrent acute appendicitis occurred in 7%-10% of patients who are managed nonoperatively. The dilemma is further complicated by presence of free fecalith in the abscess, which has been repeatedly demonstrated to be a major predicting factor leading to recurrence of acute appendicitis or abscess.<sup>2-6</sup> Further operation might be required for drainage of recurrent abscess or removal of the retained fecalith. However, little had been stressed over the significance of removal of free fecaliths when they were first encountered. Herein we report our experience of extraperitoneal drainage and removal of free fecalith from the abscess at their first presentation.

### Patients and Methods

Two patients with acute appendicitis complicated by abscess formation were treated with extraperitoneal drainage and removal of the fecaliths at West-Garden Hospital in Taipei, Taiwan in October 2010 and February 2011, respectively.

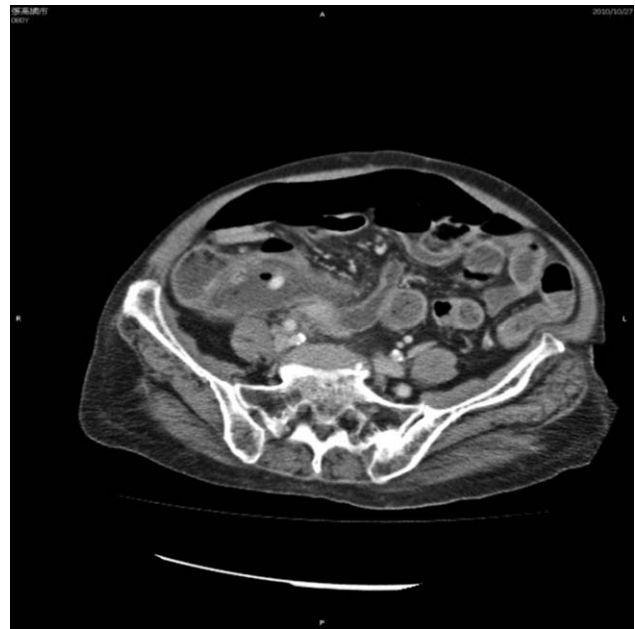#### Case 1

A 75-year-old bedridden woman with senile dementia presented to the emergency room with fever and a 1-week history of abdominal pain. Physical examination revealed a distended abdomen, thin abdominal wall and tenderness in the right lower abdomen. Laboratory tests revealed leukocytosis and hypokalemia. Abdominal computed tomography (CT) scan showed a 10 cm × 6.3 cm × 4.6 cm abscess medial to the cecum, a free fecalith in the abscess, while the appendix could not be identified (Fig.1). Due to extensive ileus, there was no route for safe percutaneous drainage. However, we noticed that the retroperitoneal space beneath the abscess was uninvolved by the inflammation. An oblique 10-cm incision was made, parallel and lateral to the traditional placement of the McBurney's incision. By staying in the extraperitoneal space, the cecum and proximal ascending colon were mobilized, thus allowing us to reach the retroperitoneal space beneath the abscess. With gentle digital dissection, the abscess cavity was entered. Pus was suctioned out through the opening. Further digital exploration identified and removed the free fecalith. A 20-French Foley sump drain tube was placed in the abscess cavity. Intravenous Flomoxef (Flumarin, Shionogi & Co., Ltd. Osaka, Japan) and metronidazole (SABS, Taiwan Biotech Co., Ltd., Taoyuan, Taiwan) were administered. Follow-up CT scan (Fig.

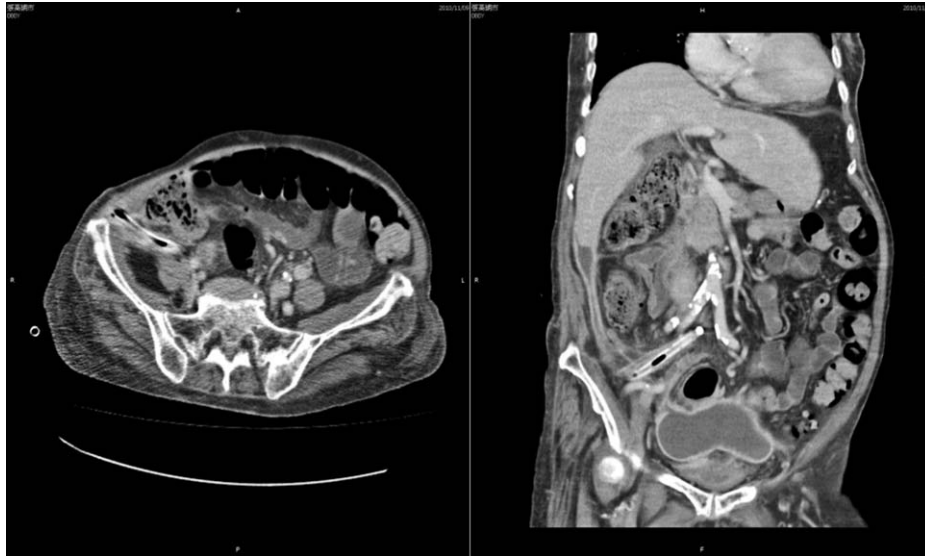
2) 1 week later showed complete resolution of the abscess. The drainage tube was sequentially shortened, and removed on the 10th postoperative day. The whole hospital course was uneventful.

#### Case 2

A 15-year-old boy came to our gastroenterology clinic with fever (39°C) and a 10-day history of right lower abdominal pain. Physical examination revealed local tenderness and guarding. Laboratory tests revealed marked leukocytosis (WBC count 26,780). Abdominal CT scan showed a 7.25 cm × 7 cm × 5 cm abscess containing a free radio-opaque fecalith medial to the cecum, whereas the appendix could not be identified (Figs. 3, 4). Under general anesthesia, the same operative procedure was performed. More than 100 mL of pus was evacuated, and the fecalith was removed. An 18-French Foley sump was left in the abscess cavity. Follow-up CT showed complete resolution of the abscess (Fig. 4). After antibiotic treatment with Flomoxef and metronidazole for 10 days, and removal of the drainage tube on the eighth postoperative day, the patient was discharged without any complications.



**Fig. 1** CT image shows marked ileus, an abscess with a fecalith medial to the cecum, whereas the appendix cannot be identified. The retroperitoneal space under the abscess is uninvolved by the inflammation.

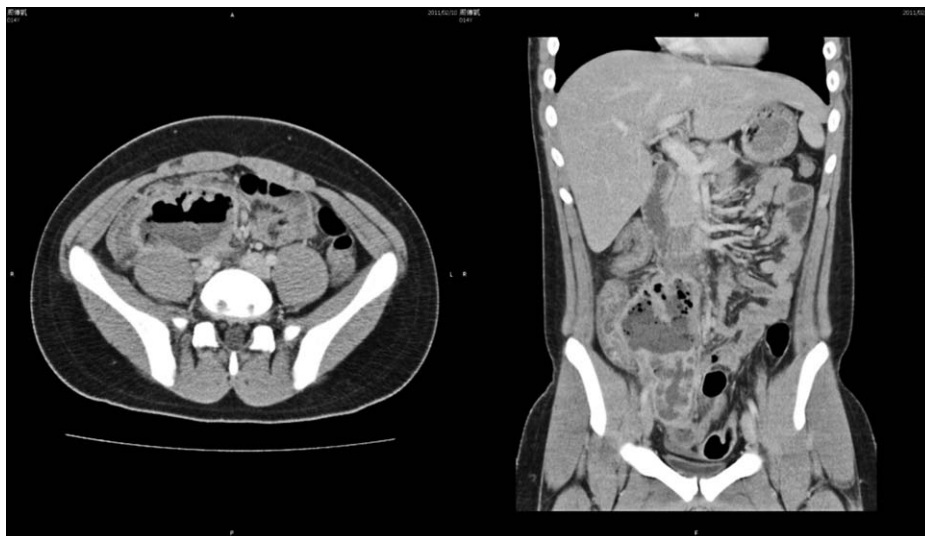

**Fig. 2** Follow-up CT images 1 week after surgery shows the drain tube in the extraperitoneal route and previous abscess cavity, and complete resolution of the abscess.

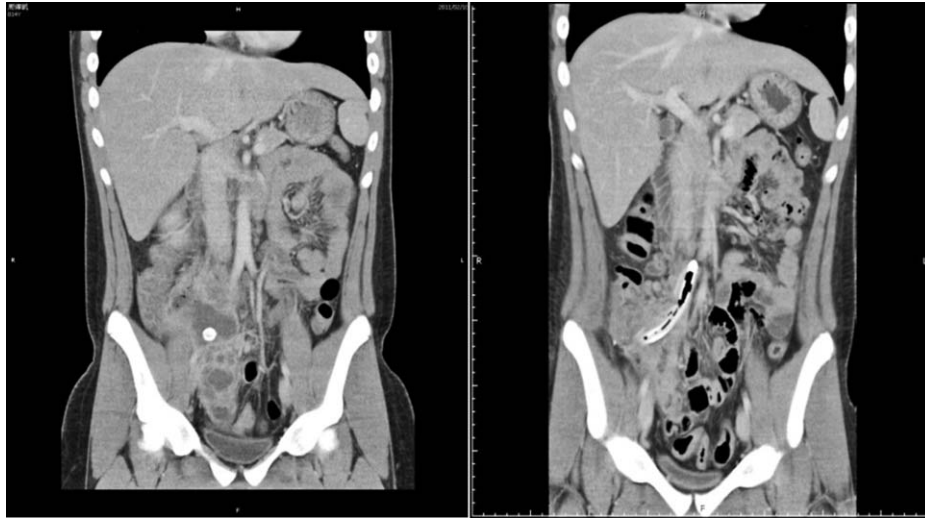
## Discussion

Although acute appendicitis complicated with well-circumscribed abscess and free fecalith occurred infrequently, it is a challenging situation that could present to every surgeon in general surgery. Optimal selection of treatment is crucial for a patient's outcome, as inadequate management may lead to complications. However, not all hospitals are properly staffed or equipped with all the alternatives for management of these cases.

The appendix in both of our cases could not be identified by CT scans, both pre- and postoperatively. It has been postulated that the more florid inflammatory process might precipitate spontaneous destruction of the appendix,<sup>7</sup> and indeed had been pointed out that those patients from whom a free fecalith had been removed at the time of drainage had the greatest degree of appendiceal destruction.<sup>8</sup> It was suggested that interval appendectomy was not required for these cases.



**Fig. 3** CT images show a well-circumscribed abscess medial to the cecum.



**Fig. 4** Preoperative CT scan (left) shows a fecalith in the abscess, and postoperative scan (right) exhibits proper placement of the drainage tube and complete resolution of the abscess.

Controversies remain, however, regarding the primary management of these cases. As formal laparotomy is generally deemed arduous and fraught with complications, image-guided percutaneous drainage has become the preferred approach in most institutes.

The abscess of our second case looked drainable with percutaneous drainage, but the fecalith would still be there, which had been repeatedly demonstrated to be a major factor in failure of nonoperative treatments.<sup>2-6</sup> Fecalith, being an infectious nidus, could lead to recurrent abscess formation, as was well attested by the 30 cases of intra-abdominal abscess caused by dropped or retained fecalith reported in the literature.<sup>9</sup> Drainage of the abscess without removal of the free fecalith provided only partial treatment of such cases. In the series reported by Buckley *et al*, although the abscesses caused by the retained fecalith were successfully treated by CT-guided drainage, all 5 cases had re-recurrent abscesses that required further drainage and formal surgical intervention for drainage and removal of the fecalith.<sup>3</sup> Furthermore, removal of an imbedded fecalith could be difficult, sometimes requiring novel methods for its localization, such as CT-guided Kopans Hookwire placement or laparoscopic ultrasonography.<sup>10,11</sup> The best policy is removal of the fecaliths when they are first encountered, ideally at the time of drainage of the abscess. The question is how this can be accomplished effectively and safely.

Extraperitoneal drainage is an established method for treatment of intra-abdominal abscess. While it may appear to be unorthodox in this era of image-guided percutaneous drainage and laparoscopic surgery, extraperitoneal approach provides optimal treatment for selected cases like our cases.

The extraperitoneal approach avoids intra-abdominal complications related to exploratory laparotomy, including dissemination of infection, bowel injuries and adhesion because the approach leaves the peritoneal cavity intact. With only minimal dissection, the inflammatory cascade related to laparotomy manipulation is not elicited.<sup>12</sup> Therefore bowel function and patients' general condition are expected to recover sooner, along with a shorter hospital stay and less medical expenditure.

When drainage of an abscess was indicated, a safe percutaneous route or an experienced radiologist may not always be available. The procedure is associated with risk of injury to the bowel or other organ, as had been noted in 4 of 52 cases in a reported series.<sup>13</sup> With careful surgical planning and digital dissection, inadvertent injury was avoidable via an extraperitoneal approach. Furthermore, unlike percutaneous drainage, extra-peritoneal approach drainage could be performed in any level of hospital, including primary practitioner and in less well-developed areas and countries.

Laparoscopic surgery is now applied to the treatment of complicated appendicitis, including the drainage of peri-appendiceal abscess.<sup>14-16</sup> It offers the advantage of exploration of the peritoneal

cavity and drainage of abscess that are not amenable to a percutaneous approach. However, adhesion and combined phlegmonous change around the abscess make laparoscopic dissection a challenging, if not risky, procedure. In addition, since copious irrigation is required, laparoscopic drainage still carries the risk of a certain percentage of recurrent abscess,<sup>17</sup> and uncertain fate of the fecalith.

The abscesses in our cases were located medial to the cecum, and were drained from their undersides. By presenting our cases, we hoped to demonstrate that drainage of these abscess via an extraperitoneal approach is feasible, provided that there is a proper route.

### Conclusion

- (1) Free fecalith, as the nidus of infection, should be removed at the time of drainage of the appendiceal abscess.
- (2) With proper case selection, we recommend extraperitoneal approach be considered as one of the alternatives in the treatment of late presenting acute appendicitis with well-circumscribed abscess containing free fecalith, including those abscesses locating medial to the cecum.

### Acknowledgments

The authors had no conflict of interest.

### References

1. Andersson RE, Petzold MG. Nonsurgical treatment of appendiceal abscess or phlegmon: a systematic review and meta-analysis. *Ann Surg* 2007;**246**(5):741–748
2. Ein SH, Langer JC, Daneman A, Ein SH, Langer JC, Daneman A. Nonoperative management of pediatric ruptured appendix with inflammatory mass or abscess: presence of an appendicolith predicts recurrent appendicitis. *J Pediatr Surg* 2005;**40**(10):1612–1615
3. Buckley O, Geoghegan T, Ridgeway P, Ridgeway P, Colhoun E, Snow A *et al.* The usefulness of CT guided drainage of abscesses caused by retained appendicoliths. *Eur J Radiol* 2006;**60**(1):80–83
4. Tsai H-M, Shan Y-S, Lin P-W, Lin X-Z, Chen C-Y. Clinical analysis of the predictive factors for recurrent appendicitis after initial nonoperative treatment of perforated appendicitis. *Am J Surg* 2006;**192**(3):311–316
5. Aprahamian CJ, Barnhart DC, Bledsoe SE, Bledsoe SE, Vaid Y, Harmon CM. Failure in the nonoperative management of pediatric ruptured appendicitis: predictors and consequences. *J Pediatr Surg* 2007;**42**(6):934–938
6. Marin D, Lisa Lisa M. Ho, Barnhart H, Neville AM, White RR, Paulson EK. Percutaneous abscess drainage in patients with perforated acute appendicitis: effectiveness, safety, and prediction of outcome. *AJR* 2010;**194**(2):422–429
7. Hoffmann J, Lindhard A, Jensen H. Appendix mass: conservative management without interval appendectomy. *Am J Surg* 1984;**148**(3):379–382
8. Daniel L. Paull, G. Peter Bloom. Appendiceal abscess. *Arch Surg* 1982;**117**(8):1017–1019
9. Sarkar S, Douglas L, Egun AA. A complication of a dropped appendicolith misdiagnosed as Crohn's disease. *Ann R Coll Surg Engl* 2011;**93**(6):117–118
10. Lossef SV. CT-guided Kopans hookwire placement for preoperative localization of an appendicolith. *AJR* 2005;**185**(1):81–83
11. Lee SW, Lim JS, Hyung WJ, Park MS, Kim MJ, Cha SW *et al.* Laparoscopic ultrasonography for localization of a retained appendicolith after appendectomy. *J Ultrasound Med* 2006;**25**(10):1361–1363
12. Sido B, Teklote JR, Hartel M, Friess H, Buchler MW. Inflammatory response after abdominal surgery. *Best Pract Res Clin Anaesthesiol* 2004;**18**(3):439–454
13. Keckler S, Tsao K, Sharp S, Ostlie D, Holcomb G, Peter S. Resource utilization and outcomes from percutaneous drainage and interval appendectomy for perforated appendicitis with abscess. *J Pediatr Surg* 2008;**43**(6):977–980
14. Kimura T, Shibata M, Ohhara M. Effective laparoscopic drainage for intra-abdominal abscess not amenable to percutaneous approach: report of two cases. *Dis Colon Rectum* 2005;**48**(2):397–399
15. Marusasa T, Miyano G, Kato Y, Yanai T, Okazaki T, Ichikawa S *et al.* New primary management for appendiceal masses in children: laparoscopic drainage. *J Laparoendosc Adv Surg Tech* 2007;**17**(4):497–500
16. Goh BKP, Chui CH, Yap TL, Low Y, Lama TK, Alkouder G *et al.* Is early laparoscopic appendectomy feasible in children with acute appendicitis presenting with an appendiceal mass? A prospective study. *J Pediatr Surg* 2005;**40**(7):1134–1137
17. St. Peter SD, Aguayo P, Fraser JD, Keckler SJ, Sharp SW, Leys CM *et al.* Initial laparoscopic appendectomy versus initial nonoperative management and interval appendectomy for perforated appendicitis with abscess: a prospective, randomized trial. *J Pediatr Surg* 2009;**45**(1):236–240

© 2014 Chang *et al.*; licensee The International College of Surgeons. This is an Open Access article distributed under the terms of the Creative Commons Attribution Non-commercial License which permits use, distribution, and reproduction in any medium, provided the original work is properly cited, the use is non-commercial and is otherwise in compliance with the license. See: <http://creativecommons.org/licenses/by-nc/3.0>