




Original Article

Correlation of cerebral microvascular circulation with vital signs in cerebral compression and the validity of three concepts: vasodilation, autoregulation, and terminal rise in arterial pressure

Javad Hekmatpanah

Department of Surgical Neurology, University of Chicago Medicine, Chicago, United States.

E-mail: *Javad Hekmatpanah - hekmat@surgery.bsd.uchicago.edu



***Corresponding author:**

Javad Hekmatpanah,
Department of Surgical
Neurology, University of
Chicago Medicine, Chicago,
United States.

hekmat@surgery.bsd.uchicago.
edu

Received: 20 December 2023

Accepted: 14 February 2024

Published: 22 March 2024

DOI

10.25259/SNI_998_2023

Quick Response Code:



ABSTRACT

Background: Vasodilation, autoregulation, and rising arterial pressure are three common concepts in cerebral compression, believed to improve cerebral blood flow to maintain the brain's nutrition. However, these concepts are unclear, unproven, and based on assumptions. This study aimed to correlate cerebral circulation with alterations of vital signs and to evaluate the above concepts based on physics and hemodynamics.

Methods: Without new animal experiments, a large amount of data: recording of vital signs, long movies of cerebral circulation, and numerous photos of histological examination and microvessels obstruction in cerebral compression in cats was studied, and only partial and preliminary results were reported in 1970. The experiments were supported by an NIH grant for head injury, done before the 1985 Institutional Animal Care and Use Committee requirement. The advent of digital technology facilitated digitizing and stepwise correlating them and evaluating the validity of the above concepts.

Results: As cerebral compression increased intracranial pressure (ICP), veins dilated, not arteries, and arterial microvessels obstructed, diminished, and stopped cerebral circulation. Simultaneously, vital signs deteriorated, and pupils became fixed and dilated. There was no evidence for what is believed as autoregulation.

Conclusion: In cerebral compression, rising ICP obstructs cerebral arterial microvessels while simultaneously deteriorating vital signs. There is no evidence for dilatation of the arteries; only veins dilate, best-called venodilation. There is no evidence of autoregulation; what occurs is a cerebral compartmental syndrome. The terminal rise of arterial pressure is the hemodynamic result of cerebral circulation cessation, overloading the aorta. None of the concepts benefit the brain's nutrition.

Keywords: Autoregulation, Cerebral compression, Intracranial pressure, Vasodilation, Venodilation

INTRODUCTION

Vasodilation, autoregulation, and the terminal rise of intracranial pressure (ICP) are concepts commonly believed to improve cerebral circulation in cerebral compression. However, their concepts stem from assumptions and do not convey the actual dynamics of cerebral circulation in cerebral compression; their belief causes erroneous interpretations of clinical and laboratory

This is an open-access article distributed under the terms of the Creative Commons Attribution-Non Commercial-Share Alike 4.0 License, which allows others to remix, transform, and build upon the work non-commercially, as long as the author is credited and the new creations are licensed under the identical terms.

©2024 Published by Scientific Scholar on behalf of Surgical Neurology International

findings. This study aimed to correlate cerebral-microvessels-circulation with the alteration of vital signs and pupils and to evaluate the above concepts based on hemodynamics and physics formulas.

MATERIALS AND METHODS

Without new animal experiments, a large amount of data: vital signs records, cerebral circulation movies, and numerous histology and microvessels' obstruction photos in cerebral compression in cats were studied, of which only partial and preliminary results were reported in 1970. The experiments were supported by an NIH grant to study head injury, which was done more than a decade before the 1985 Institutional Animal Care and Use Committee requirement. The advent of digital technology facilitated digitizing, correlating the data, and evaluating the validity of the above concepts.

The experiments were done under general anesthesia, with intraperitoneal injections of Sodium Pentobarbital, 20 mg/kg. The cerebral compression was through gradual inflation of a small balloon, inserted in the epidural region through a small bur hole, in which an increment of 0.2 mL saline was injected every 5 min. ICP was measured through a similar small balloon inserted through a bur hole on the opposite side. Central arterial blood pressure (BP) was recorded through a polyethylene tube inserted in the aorta through the femoral artery. A bellow was applied around the chest to record respiration. The dilation of pupils was photographed, and their outlines were drawn. All were connected to a Beckman dynograph via strain gauges for recording, and electroencephalogram (EEG) electrode wires were attached to the skull.

In 15 animals, circulation of the cortical vessel was observed and recorded through another bur hole behind the one for the ICP recording, in which the dura was opened, and the arachnoid was covered with fitted sealed glass. Through this bur hole, cerebral circulation was observed and recorded using still and movie cameras with magnifications of up to $\times 100$. Because of motion artifacts by pulsation and respiration, most recordings were done at $\times 25$ magnification. At each conspicuous change in vital signs in an experiment, Evans Blue, India Ink, or Micro Barium was injected *in vivo* into the heart through the central catheter to evaluate the patency of cerebral arterial microvessels or to inject glutaraldehyde for fixation of tissues; each dye was used for one animal. At the end of the experiment, the animal died in a coma without discomfort.

RESULTS

As cerebral compression gradually increased and ICP rose, venules' circulation slowed first, and veins dilated, followed by gradual narrowing and obstruction of arterial capillaries with final cessation of their circulation. Simultaneously,

vital signs altered, starting with slowing and diminishing the amplitude of ipsilateral EEG, slowing respiration and pulse, dilating the ipsilateral pupil followed by the contralateral pupil, ending in the arrest of all vital signs; the alterations were compared with those of normal, Figures 1-4. The photos of the cerebral cortex are from a movie, through a microscope using 25 times magnification. Figure 1 shows the normal pink color of the cerebral cortex, three veins (Ve) draining to the sagittal sinus (SS), and an artery (Ar) crossing. The intense blue color of the brain in C indicates the infiltration of Evans blue dye in open capillaries.

After each increment of 0.2 mL saline in the balloon, the ICP rose around ten mmHg and declined partially, Figure 1. During the first three increments of the rise and fall of ICP, no change in vital signs occurred. After each additional increment, despite its partial fall, the ICP rose higher than before, Figures 2-4.

As cerebral compression and ICP increased, the output of veins to the SS was blocked, and veins dilated. In some veins, circulation reversed, Figure 2, Arrow. Gradually, the arterial capillaries narrowed, their circulation diminished, and the cortex became pale, Figures 2-4. The diminishing infiltration of dyes in the capillaries represented their gradual obstruction [Figures 2-4].

Simultaneously, the ipsilateral EEG slowed, and its amplitude declined when the ICP approached about 25 mmHg, Figure 2, followed by slowing respiration and pulse. The ipsilateral pupil to the compression side began to dilate when the ICP approached 40 mmHg, Figure 2.

From there on, arterial capillaries obstructed rapidly. When ICP approached diastolic BP, marked slowness of respiration and pulse occurred with both pupils dilating; sometimes, respiration became in Cheyne Stoke form, Figure 3.

Finally, a sharp rise in both ICP and BP occurred simultaneously with the obstruction of all arterial microvessels and dilated fixed pupils, Figure 4. Dilatation of veins without dilatation of arteries occurred in every experiment. Figure 5 is an example of the same vascular alteration in another experiment.

The electron microscopy of the cerebral cortex revealed marked evidence of ischemic changes and perivascular swelling, as compared with normal Figure 6.

Figure 7 is a montage showing the stepwise correlation of the alteration of cerebral circulation, vital signs, pupils, and obstruction of microvessels. Furthermore, showing rapid alterations of vital signs when cerebral perfusion pressure (CPP) reached 45 mmHg and dilation only in veins. The arterial system gradually narrows and obstructs without dilating.

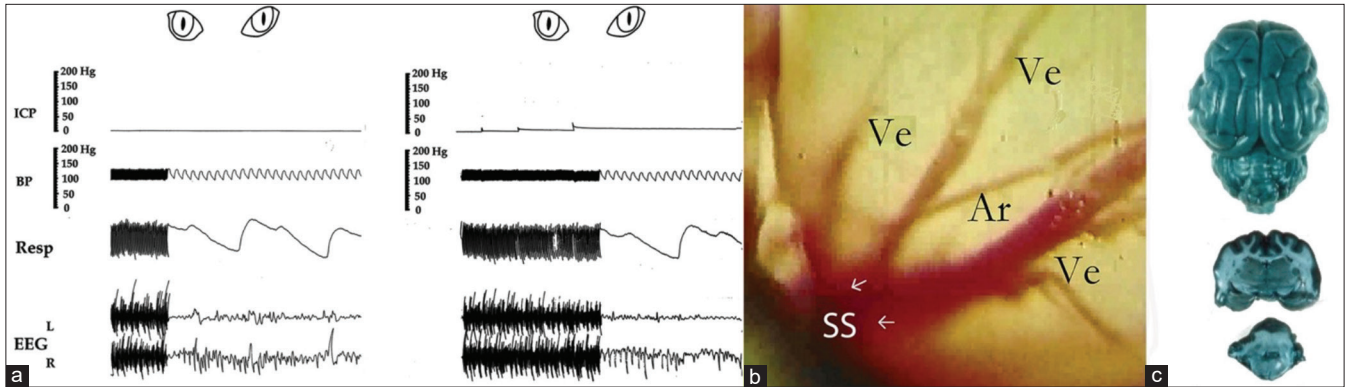


Figure 1: (a-c) shows normal vital signs, a photo of the cerebral cortex, and a photo of the normal brain perfused with Evans Blue dye injected *in vivo*, used as controls. Note 10–20 mmHg rises in intracranial pressure after each injection of 0.2 mL saline in the compression balloon and partially falls after with no change in vital signs during the first three increments in photo a. Photo b is from a movie of the cerebral cortex through the microscope with 25 times magnification; note three veins (Ve) entering the sagittal sinus (SS), an artery (Ar) crossing, and the normal pink color of the cortex. The dark blue color of the brain in photo c represents infiltration of Evans Blue dye (0.2 mL/kg body weight) in open capillaries of a normal cat’s brain. Vital signs records are partly from this author’s preliminary publication with permission from the Journal of Neurosurgery.^[11,13] ICP: Intracranial pressure; BP: Blood pressure, Resp: Respiration, EEG: Electroencephalogram.

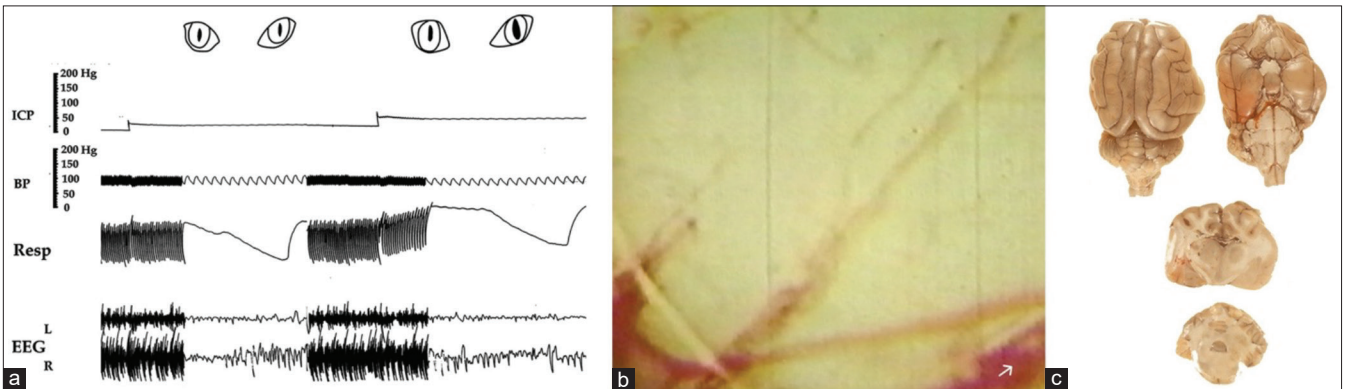


Figure 2: (a) Slowing respiration and suppression of ipsilateral EEG as intracranial pressure approaches 25 mm Hg and dilating the ipsilateral pupil as it reaches 40 mm Hg. The slowness of circulation is manifested by the blurred appearance of individual red cells as they pass through. The pallor of the cortex in (b) and significantly diminished infiltration of Evans Blue dye in (c) represent obstruction of a large proportion of arterial microvessels. Note partial dilatation of the lower vein in which the flow is reversed and no dilatation of the artery. ICP: Intracranial pressure; BP: Blood pressure, Resp: Respiration, EEG: Electroencephalogram.

DISCUSSION

The concepts of vasodilation, autoregulation, and the benefit of the terminal rise of ICP in cerebral compression have dominated the literature for over half a century. Therefore, new and contrary interpretations of the dynamics require more detailed discussion and explanation; the following is an attempt to do that.

Concept of vasodilation

In 1902, Cushing^[5] reported the results of his pioneering laboratory experiment on cerebral blood vessels and his clinical observation of cerebral compression. He gradually poured mercury into an expandable bag, inserted it in the skull over the animal’s brain, and using a “low-power lens,”

he observed the pial vessels through a cranial window. As compression increased, he noticed “a distinct widening of the smaller venous radicals,” and when the ICP reached that of the capillary pressure, the convolution of the brain, even in remote parts of the hemisphere, abruptly and lost its “rosy color” became blanched and arteries became mere threads and barely distinguishable; a condition he called anemia of the brain. Dr. Cushing believed that the alterations of the vessels and circulation resulted from a vasomotor response and were caused by stimulation of the vasomotor center.

Others followed the notion of vasomotor. Forbes and Wolff^[8] studied the circulation of pial vessels in ICP. They concluded, “It seems justifiable to state that evidence of a quantitative nature has been obtained that the circulation of the mammalian brain is controlled in part by cerebral

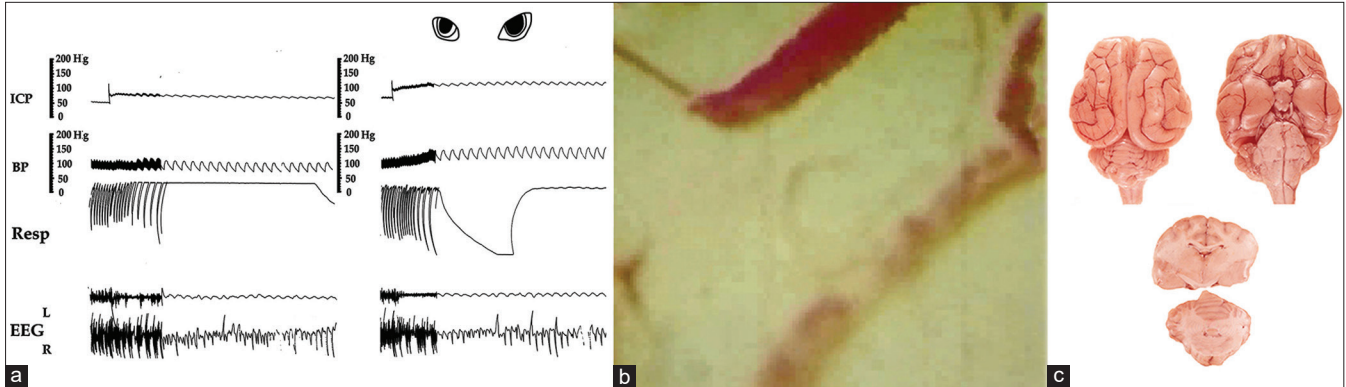


Figure 3: (a) Marked slowing respiration with periodic Cheyne Stokes pattern, EEG with flattened amplitude on the ipsilateral side showing just pulse artifact and dilating both pupils when intracranial pressure approaches diastolic arterial pressure. Note also markedly dilated veins and slowed circulation manifested by separated red cells, some of which are adhered together, almost no circulation in the artery and pallor of the cortex, (b) and little infiltration of dye in the brain, (c), repressing obstruction of microvessels. ICP: Intracranial pressure; BP: Blood pressure, Resp: Respiration, EEG: Electroencephalogram.

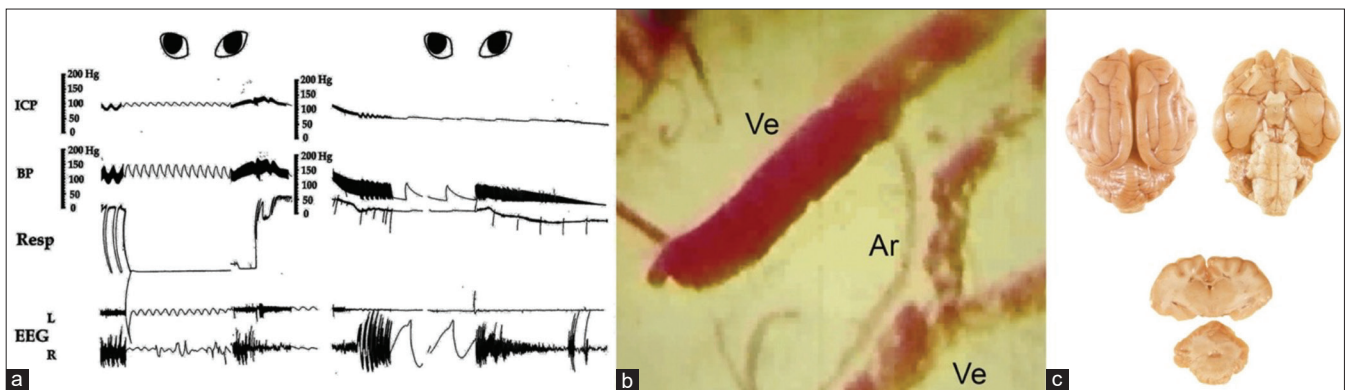


Figure 4: The rapid rise of both blood pressure (BP) and intracranial pressure (ICP) followed by their simultaneous fall without balloon deflation. Markedly slowed respiration, slowed irregular pulse, flattened EEG on both sides showing mainly pulse artifacts, and dilated-fixed pupils, (a) The circulation is stopped, the cortex becomes pale, and veins become markedly dilated with no dilatation of the arteries, (b) There is no infiltration of the dye in the brain (c) indicating complete blockage of arterial microvessels and simultaneously dilated and fixed pupils., Note that at the end, when vital signs collapsed and BP declined to zero, the ICP also declined to around 25 mmHg. This occurred without the deflation of the balloon, which has an important clinical significance (see the explanation in the text). ICP: Intracranial pressure; BP: Blood pressure, Resp: Respiration, EEG: Electroencephalogram, Ve: Vein, Ar: Artery.

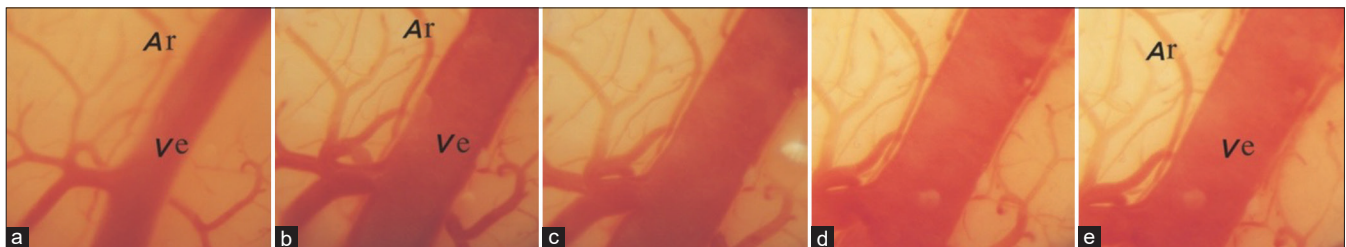


Figure 5: (a-e) Marked dilating veins and pallor of the cortex in another animal as intracranial pressure increased. Note no dilatation of the artery running along the side of the vein. The photo is from a movie, taken through a microscope with $\times 25$ magnification. Ve: Vein, Ar: Artery.

vasomotor nerves.” Wolff and Forbes^[33] raised ICP by injecting Ringer’s solution in cisterna magna in cats; their experiment revealed essentially the same as Dr. Cushing’s. Scheinker^[27] used the term “vasoparalysis” for dilating vessels

in trauma. Lassen^[17] advanced the term vasodilation and autoregulation to maintain cerebral blood flow (CBF). Later Langfitt *et al.*^[16] used the terms vasoparalysis, vasodilation, and autoregulation.

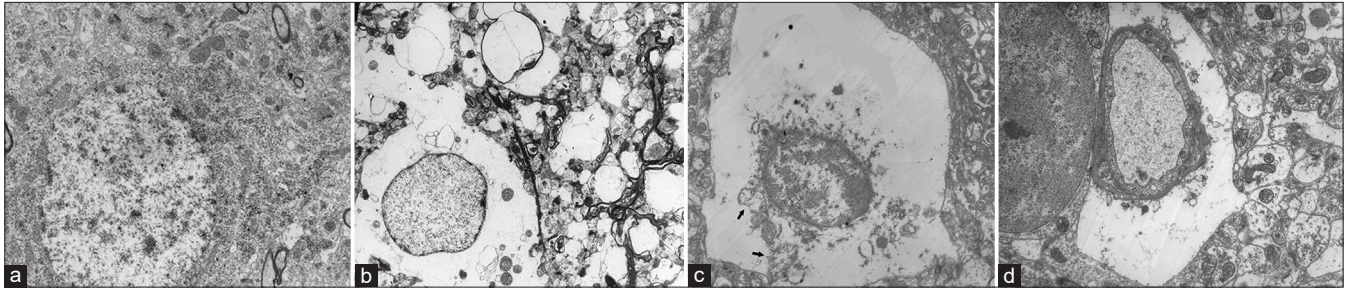


Figure 6: (a-d) Electron micrographs of cerebral cortex showing normal (a) compared to when pupils are dilated (b-d). Note marked perivascular swelling (c and d). Mitochondria with destroyed cristae (c) and their torn membranes.

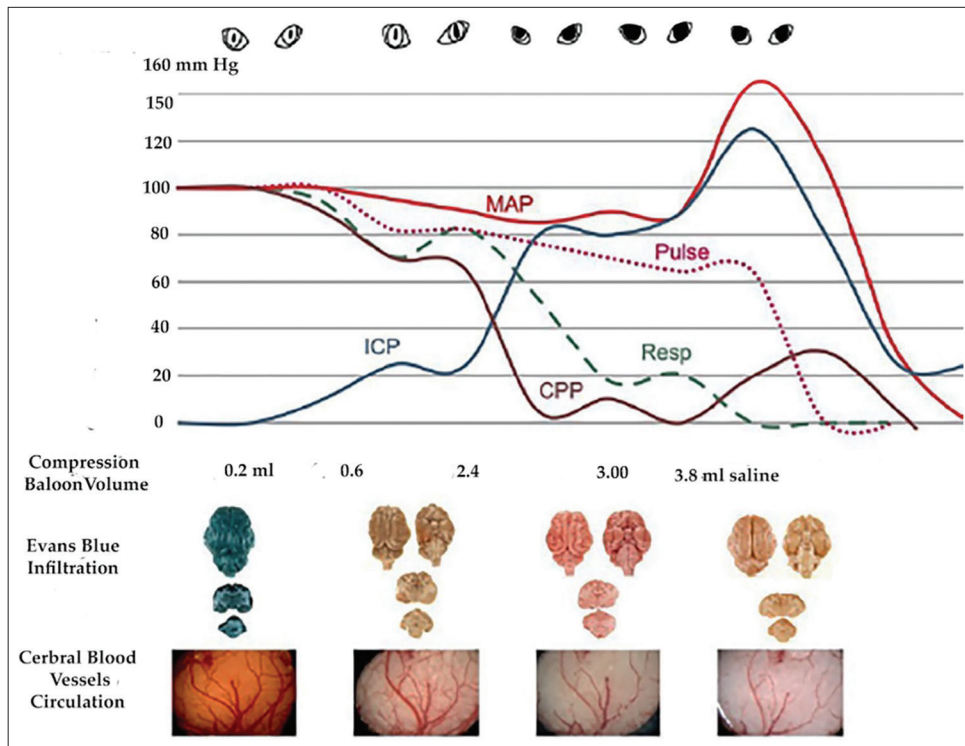


Figure 7: In vertical arrangement shows the correlation of each stage of significant change in cerebral circulation with vital signs. The highest levels of mean arterial pressure, respiration, and pulse were each taken as 100, and their changes were calculated. Note that when the intracranial pressure reached 25 mm Hg, there was already diminished perfusion of dye in the capillaries and pallor of the cortex. Note progressive obstruction of microvessels, manifested by diminished Evans blue perfusion in the brain's arterial capillaries, compared to the dense blue color in the normal brain, simultaneous with dilated-fixed pupils coinciding with arrested circulation. ICP: Intracranial pressure, MAP: Mean arterial pressure, CPP: Cerebral perfusion pressure.

However, our studies found dilation occurred only in the veins, not in the arteries. To investigate if similar dynamics took place in chronic cerebral compression in another experiment,^[12] the capillary circulation in viral-induced brain tumors in rats was studied using injections of Micro Barium or liquid plastic in the brains through the ascending aorta. As tumors grew and animals became drowsy and comatose, similar progressive obstruction of arterial microvessels was observed without

arterial dilatation as compared with normal, Figure 8. Photos are reproduced from this author's paper in *Surgical Neurology International* (SNI) with the journal's permission.^[12]

In addition, in reviewing numerous cerebral angiograms in patients with significant cerebral compression caused by tumors or other conditions, I did not find dilatation of cerebral arteries, except for an artery that supplied a tumor, like in meningiomas, where the arteries were narrowed or

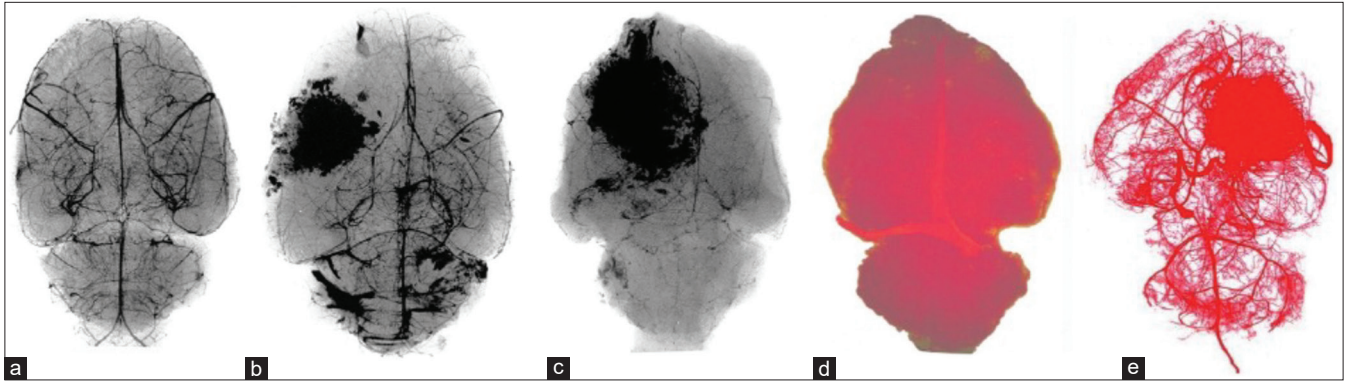


Figure 8: (a-e) A gradual arterial capillary obstruction in viral-induced tumors in rats by injecting Microbarium (a-c) followed by high magnification X-ray and (d and e) by injecting liquid plastic in ascending aorta. Note obstruction of capillaries in (b and c) as the tumors grew, compared with normal, (a), and in a brain with a tumor in (e) as compared with normal (d).

obstructed. Mitchell *et al.*^[23] and Langfitt^[15] report similar clinical observations.

Thus, based on this study, the experiment in rats' brain tumors, and clinical observations, this author concludes that the notion of vasodilation in cerebral compression erroneously conveys arterial dilatation and erroneous interpretation of clinical findings. As cerebral compression and ICP increased, we found continuous arterial capillary obstruction, narrowing of arteries, and decline of cerebral circulation; therefore, we concluded that it is best to name the phenomenon as venodilation.

Concept of autoregulation

The term cerebral autoregulation (CA) has also been linked to cerebral compression, with the notion that it regulates CBF across ranges of 50–150 mean arterial pressure (MAP), and its "failure" is linked to high ICP. However, in cerebral compression, this concept is also based on assumption. In 1976, Lassen and Christensen^[18] wrote, "It is most probable then that autoregulation results from myogenic responses of the smooth muscle cells of the arteriolar wall to stretch-induced by variations in transmural pressure" and proposed a schematic representation curve for blood flow; the curve will be discussed later. Miller *et al.*,^[21] called autoregulation "the ability of the brain to maintain a constant blood flow despite changes in perfusion pressure." Paulson *et al.*^[25] defined it as the "intrinsic ability of an organ or a vascular bed to maintain constant perfusion in the face of BP changes, and alternatively, autoregulation can be defined in terms of vascular resistance changes or simply arteriolar caliber changes as BP or perfusion pressure varies."

The term autoregulation in cerebral compression is used in numerous other citations in the literature and is taught to neuroscience students despite the vague doubtful mechanisms. Paulson further suggested, "The basic mechanism of autoregulation of CBF is controversial. Most likely, the autoregulatory vessel caliber changes are mediated by an interplay between myogenic and metabolic mechanisms."

Miller *et al.*,^[22] in another paper, wrote, "This term involves an assumption which is yet to be proven, namely, that CBF adapts to changing of CPP by mechanisms which are entirely independent of systemic influence." Rangel-Castilla *et al.*^[26] wrote that it is a complex process, a concept rather than a physically measurable entity possibly acting in a combination of myogenic, neurogenic, and metabolic mechanisms.

Even Cushing^[5] was uncertain about his notion of vasomotor. He wrote, "Whatever part, however, the cerebral vasomotor system may play, if such a-system there be, it certainly is controlled from centers and by influences other than those which call interplay the vasoconstriction in the peripheral and intra-abdominal field." Brassard *et al.*^[3] wrote, "it is now time for the medical community to move away from the commonly touted view of CA."

In a study to find the current knowledge of CA in relation to aspects that could be implemented in the management of traumatic brain injury and its research priority in 2021, Depreitere *et al.*^[6] used the Delphi method, seeking the views of 25 international academic experts. Among 25 items of consensus, the one with a score of 100 was "Because of potential dynamic CA impairment, absolute and universal CPP targets do not exist. The safe CPP zone can differ between individuals and can change within individuals," and among 5 with the score of 100 for no consensus was "There is no consensus on the manner how information on CA status should be used in clinical practice."

This author, therefore, proposes that the dynamics of the vascular changes in cerebral compression can be explained by the physical elasticity-plasticity of the brain, stress-strain phenomenon, and Hooke's law as follows.

Explanation 1

Force (F) can stress substances in nature, strain and deform them. For example, a metal rod, rubber, muscle, and collagen

fiber with a length of L can be stretched in an amount of ΔL or compressed in an amount of $-\Delta L$ and a substance with a volume of V can be compressed in an amount of $-\Delta V$. Stress designated by sigma (σ) is the amount of force over the area ($\sigma = F/A$) of the substance, and strain designated by epsilon (ϵ) is the ratio of change over the length ($\epsilon = \Delta L/L$). Young's Modulus (Y) is the ratio of stress over strain, $Y = \sigma/\epsilon$, or $F/A \div \Delta L/L$, or $Y = FL/A\Delta L$. The Modulus for objects with volume is designated by bulk B or K , which is Stress/Strain or $Y = \sigma/\epsilon = \Delta P \div -\Delta V/V =$ or $-V\Delta P/\Delta V$ in which ΔP represents the pressure.

Based on Hooke's law, each substance has a K -constant for x amount of change under (F), or $F = Kx$, and each substance has a certain degree of elasticity within which it regains its original shape when the stress is removed, but beyond which hardens, deforms, or breaks, not regaining its original shape despite the removal of the stress. Stiffer substances have higher Young's modulus numbers, requiring more force to deform them.

The brain is also a substance, a heterogeneous one, consisting of elements with elasticity, like fat, as reported by Schoemaker *et al.*,^[28] collagen by Dutov *et al.*,^[7] and smooth muscle, by Tuna *et al.*^[30] In addition, the brain contains and floats in CSF and contains blood, both of which are hardly comparable. However, under cerebral compression, blood, while liquid, can squeeze out of vessels, and some CSF can escape into the spinal canal. The combination of these makes the brain elastic, and contrary to the doctrine of Monro^[24] and Kellie^[14] it is compressible *in vivo*. That can easily be observed during a craniotomy. Furthermore, the brain is retained in the skull and cannot expand beyond a certain limit, which influences the hemodynamics of cerebral compression. Furthermore, as with other substances, the brain, under compression, creates a stress-strain curve, as shown in Figure 7.

A glance over the internet shows that the elasticity-plasticity graphs of varied substances are similar, varied somewhat by their molecular structure or rigidity. It consists of a rising part representing elasticity, during which, according to Hooke's law, regains its original shape when the pressure is removed; a flattening part still plastic during which the substance deforms or hardens; and a rising part during which it shears, breaks or declines. Brittle materials have a sharp initial rising curve and break sooner, while ductile materials have a gradual and longer one.

Figure 9 is an example of a strain-stress graph this author produced in the lab by compressing pieces of foam in a bottle filled with water and sealed. The curve resulted from injecting additional water forced into the bottle through a connecting tube, and a Camino ICP monitoring apparatus recorded the pressure through another tube exiting from the bottle.

The curve is like the ICP curve in Figure 7 in this study and that of the ICP curve in Dr. Cushing's study, both caused by cerebral compression. It is also like the curve suggested by

Lassen and Christensen^[18] for autoregulation to represent blood flow and perfusion pressure; the curve that, according to Brassard *et al.*,^[3] "each data point on the autoregulatory curve originated from independent samples of participants and patients."

Throughout these experiments, this author never found any evidence for what is expressed as autoregulation and concludes that the alteration of the cerebral circulation in cerebral compression is essentially a dynamic phenomenon based on physics laws and hemodynamics, as discussed below.

In the early stage of cerebral compression and before many veins are obstructed, when the compression raises ICP, the blood squeezes out of the capillaries, making the color of the cortex pale. However, because some blood can still escape into the SS, and some CSF escapes in the spinal canal, the partial drop of ICP allows the blood to return, making the color of the cortex pink again. A similar pallor occurs on the fingernail when it is compressed or in the cortex when the brain is retracted during an operation. The return is not an arterial dilatation or autoregulation; it is caused by the elasticity of the brain tissues, regaining their shape (Hooke's law) and allowing the blood to return. This is likely what has been interpreted as autoregulation.

However, when ICP rises beyond the capillary pressure and blocks them, the blood would not return despite the partial drop in ICP pressure. That phenomenon is likely what is interpreted as the "failure of autoregulation." The systolic pressure in the arterioles is reported by Blanco *et al.*^[1] and Shulman^[29] to be about 60 mmHg. Our experiments indicate that when ICP reaches that pressure, many capillaries are already blocked, Figure 7.

Thus, based on this experiment, during which the cerebral circulation was personally observed through the microscope for many hours, a detailed review of their videos, and their correlation with microvessel obstruction, this author concludes that in cerebral compression, there is no evidence of what is called autoregulation. Its concept is assumed and causes erroneous interpretations of laboratory and clinical findings. What takes place is basically caused by the stress-strain phenomenon, and it is more appropriate to call it Cerebral Compartment Syndrome, as it also occurs in muscles by Hargens *et al.*^[10] and the abdomen by Cheatham.^[4]

Concept of rising arterial pressure

Dr. Cushing also thought that the rise of systemic arterial pressure was to "overcome the high intracranial tension" to maintain "a proper nutritional supply to the vital centers," a concept that some still hold. However, based on Poiseuille's law, we can deduce that the rise is also a dynamic phenomenon: with 2% of body weight, according to Williams

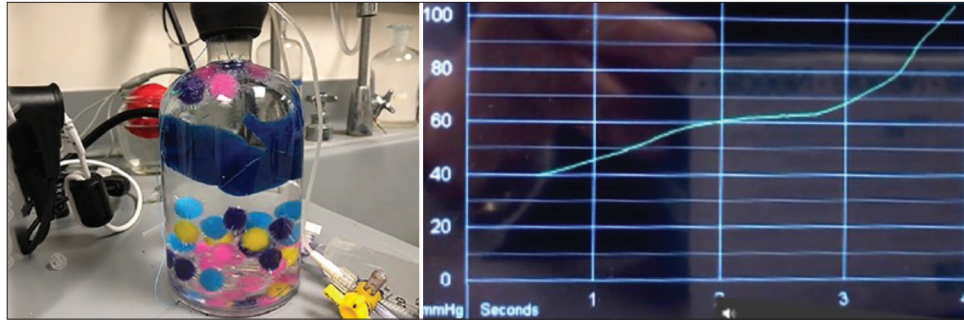


Figure 9: The graph from the compression of foam pieces in a bottle produced in the lab by this author, using the Camino intracranial pressure monitoring apparatus. Additional water was forced into the bottle, which was already filled with water and sealed. The graph on the right side of the image represents the stress-strain curve found in the compression of substances. It resembles the curve in cerebral compression and “autoregulation.”

and Leggett^[32], the brain receives an average of 12–15% of the cardiac output. As the flow to the brain diminishes and stops, this amount (about 750 mL/min) gradually backs up in the aorta and raises the systemic and MAPs. This can be explained based on Poiseuille’s law as follows.

The blood flow Q in vessels correlates directly with the pressure P and conversely with the resistance R , or $Q = P/R$. That is like Ohm’s law for electric current in wires in which I correlates with current Q , P with voltage V , and conversely with resistant R , or $I = V/R$. According to Poiseuille’s law, in more detail, the flow Q correlates directly with pressure P and the 4th power of radius r of vessels and conversely with resistant R made up of the osmolarity η of blood and length L of vessels, or $Q = P\pi r^4/8\eta L$. The P is the pressure difference across the segment of a vessel or $P_1 - P_2$ or (ΔP) . Thus, the rise and fall of the pressure increases and decreases the flow.

The brain’s blood vessels, while they divide, function as a parallel arrangement in wires, and the r is the sum of arterial microvessels radii, and the π (π) is 3.14. In the brain, P_1 is MAP and P_2 is ICP, and their difference $P_1 - P_2$ is CPP. By replacing the P in the formula with $P_1 - P_2$, we have $Q = (P_1 - P_2) \pi r^4/8\eta L$. As the ICP (P_2) increases, the $P_1 - P_2$ decreases the flow Q to the brain [Figure 7]. In addition, because the r is to the power of 4 and the continuing rise of ICP increases arterial microvessels’ blockage, the r rapidly becomes smaller, causing the flow Q to the brain to go toward zero.

As a result, the volume of blood (about 750 mL/min) going to the brain gradually backs up in the aorta, raising its volume, raising P_1 (the systemic BP) and MAP. Similar phenomena occur elsewhere in the body: the rise of BP in cross-clamping of the aorta in the thoracic region, according to Gelman^[9] and Wahr *et al.*,^[31] the rise of BP after common carotid artery blockage, according to Borgdorff and van den Horn,^[2] and leg amputation, according to Li *et al.*^[19] Furthermore, because the terminal rise of BP is associated with obstruction of the

arterial microvessels, the brain would receive no nutritional benefit.

This experiment also shows that in the end, when the BP declined to zero, ICP also dropped to around 25 mmHg without decompressing the pressure balloon, Figure 4a. This would indicate that the volume of the compressing mass (here, the balloon) is not the only cause for the ICP rise: the pressure from dilation of veins, obstruction of arterial microvessels diverting the blood to aorta, containment of the brain in the skull, and swelling each create specific dynamics that are important for interpreting related physiologic changes in patient care.

As an example, in patients with mass lesions, Miller *et al.*^[20] found “only very high ICP (>40 mmHg) on admission was significantly associated with a poor neurological picture and outcome from injury, while in patients with diffuse brain injury, any increase in ICP above ten mmHg was associated with a poorer neurological status and a worse outcome.”

Comments

In this paper, the author’s view is about autoregulation in relation to cerebral compression, with no attempt to confirm or refute the presence or absence of autoregulation in general or in biology, nor to cast any doubt on the scientific merit of the outstanding papers mentioned above. It is just a different interpretation of the dynamics of cerebral circulation about concepts of vasodilation, autoregulation, and terminal rise of arterial pressure in cerebral compression.

CONCLUSION

Cerebral compression and rising ICP cause progressive cerebral arterial obstruction that, in turn, causes progressive deterioration of vital signs. When ICP approaches 20 mmHg, it is a warning sign; by approaching 25 mmHg, ipsilateral

EEG amplitude declines; and by approaching 40 mmHg, ipsilateral pupils dilate. From there on, with small additional compression, the circulation diminishes rapidly and stops. Simultaneously, vital signs decline, EEG amplitudes become flat, and both pupils become dilated and fixed.

The terms vasodilation and autoregulation convey the wrong dynamics of cerebral circulation: the veins, not the arteries, dilate. Thus, venodilation is the appropriate term. There is no evidence for what is commonly called autoregulation; what occurs is a Cerebral Compartment Syndrome. The terminal rise of arterial pressure is a hemodynamic effect caused by cessations of cerebral circulation overloading the systemic circulation, which raises arterial pressure. None of the above common concepts has any nutritional benefit for the brain; on the contrary, they are associated with ischemia of the brain and deterioration of vital signs.

The volume of a mass that compresses the brain is not the only cause for rising ICP: dilation of veins causing cerebral stagnant, non-circulating blood volume, obstruction of arterial microvessels, and the confined brain in the skull each create specific hemodynamic and pathologic alterations.

Acknowledgments

USPHS Grant NO supported the experiments. NB-07376-01

The author is aware of the ethical concern for experiments on animals and respects that. The actual animal experiments were done around 1970, before the 1985 Institutional Animal Care and Use Committee (IACUC) requirement. Nevertheless, the animals were purchased by the institutionally established laboratory (Carlson Animal Laboratory) and cared for humanely. Except for the small needle to give intraperitoneal anesthetic, no animal suffered pain.

The author appreciates the contribution of Mr. Joseph Zientarski, a histology technician, to the preparation of the histology study.

The author appreciates the philanthropic nonrestricted contribution to his academic research activities by Mr. Frank Linden and Mr. and Mrs. Samuel Krauss Jr., none of whom had any financial connection to this research.

Ethical approval

Institutional Review Board approval is not required. No new animal experiments were performed as part of this study. Rather, prior animal studies were performed in the late 1960's to early 1970's in the Carlson laboratory facility at the University of Chicago, before the 1985 Institutional Animal Care and Use Committee Requirement (IACUC). Preliminary results from the studies were published in references 11 and 13 of this manuscript.

Declaration of patient consent

Patient's consent is not required as there are no patients in this study.

Financial support and sponsorship

NIH and nonrestricted philanthropic donation with no attachment to the paper.

Conflicts of interest

There are no conflicts of interest.

Use of artificial intelligence (AI)-assisted technology for manuscript preparation

The authors confirm that there was no use of artificial intelligence (AI)-assisted technology for assisting in the writing or editing of the manuscript and no images were manipulated using AI.

REFERENCES

1. Blanco PJ, Muller LO, Spence JD. Blood pressure gradients in cerebral arteries: A clue to pathogenesis of cerebral small vessel disease. *Stroke Vasc Neurol* 2017;2:108-17.
2. Borgdorff P, van den Horn GJ. The effect of common carotid artery occlusion on blood pressure in the barodenervated cat. *Pflugers Arch* 1980;386:193-7.
3. Brassard P, Labrecque L, Smirl JD, Tymko MM, Caldwell HG, Hoiland RL, *et al.* Losing the dogmatic view of cerebral autoregulation. *Physiol Rep* 2021;9:e14982.
4. Cheatham ML. Abdominal compartment syndrome: Pathophysiology and definitions. *Scand J Trauma Resusc Emerg Med* 2009;17:10.
5. Cushing H. Some experimental and clinical observations concerning states of increased intracranial tension. The Mütter lecture for 1901. *Am J Med Sci* 1902;124:375-400.
6. Depreitere B, Citerio G, Smith M, Adelson PD, Aries MJ, Bleck TP, *et al.* Cerebrovascular autoregulation monitoring in the management of adult severe traumatic brain injury: A Delphi consensus of clinicians. *Neurocrit Care* 2021;34:731-8.
7. Dutov P, Antipova O, Varma S, Orgel JP, Schieber JD. Measurement of elastic modulus of collagen type I single fiber. *PLoS One* 2016;11:e0145711.
8. Forbes HS, Wolff HG. Cerebral circulation: III. The vasomotor control of cerebral vessels. *Arch Neurol Psychiatry* 1928;19:1057-86.
9. Gelman S. The pathophysiology of aortic cross-clamping and unclamping. *Anesthesiology* 1995;82:1026-57.
10. Hargens AR, Schmidt DA, Evans KL, Gonsalves MR, Cologne JB, Garfin SR, *et al.* Quantitation of skeletal-muscle necrosis in a model compartment syndrome. *J Bone Joint Surg Am* 1981;63:631-6.
11. Hekmatpanah J. Cerebral circulation and perfusion in experimental increased intracranial pressure. *J Neurosurg* 1970;32:21-9.

12. Hekmatpanah J. Cerebral microvessel perfusion and pathologic alteration of the brain during drowsiness and coma caused by brain tumor: A laboratory study on rats. *Surg Neurol* 2007;67:564-71; discussion 571.
13. Hekmatpanah J. The sequence of alterations in the vital signs during acute experimental increased intracranial pressure. *J Neurosurg* 1970;32:16-20.
14. Kellie G. Transactions of the medico-chirurgical society of Edinburgh. 1824;84-169.
15. Langfitt TW, Kassell NF. Non-filling of cerebral vessels during angiography: Correlation with intracranial pressure. *Acta Neurochir (Wien)* 1966;14:96-104.
16. Langfitt TW, Weinstein JD, Kassell NF. Cerebral vasomotor paralysis produced by intracranial hypertension. *Neurology* 1965;15:622-41.
17. Lassen NA. Cerebral blood flow and oxygen consumption in man. *Physiol Rev* 1959;39:183-238.
18. Lassen NA, Christensen MS. Physiology of cerebral blood flow. *Br J Anaesth* 1976;48:719-34.
19. Li X, Li Z, Jiang W, Wei J, Xu K, Bai T. Effect of lower extremity amputation on cardiovascular hemodynamic environment: An *in vitro* study. *J Biomech* 2022;145:111368.
20. Miller JD, Becker DP, Ward JD, Sullivan HG, Adams WE, Rosner MJ. Significance of intracranial hypertension in severe head injury. *J Neurosurg* 1977;47:503-16.
21. Miller JD, Stanek AE, Langfitt TW. A comparison of autoregulation to changes in intracranial and arterial pressure in the same preparation. *Eur Neurol* 1971;6:34-8.
22. Miller JD, Stanek A, Langfitt TW. Concepts of cerebral perfusion pressure and vascular compression during intracranial hypertension. *Prog Brain Res* 1972;35:411-32.
23. Mitchell OC, De La Torre E, Alexander E Jr., Davis CH Jr. The nonfilling phenomenon during angiography in acute intracranial hypertension. Report of 5 cases and experimental study. *J Neurosurg* 1962;19:766-74.
24. Monro A. Observations on the structure and functions of the nervous system. Edinburgh: William Creech; 1783.
25. Paulson OB, Strandgaard S, Edvinsson L. Cerebral autoregulation. *Cerebrovasc Brain Metab Rev* 1990 Summer;2:161-92.
26. Rangel-Castilla L, Gasco J, Nauta HJ, Okonkwo DO, Robertson CS. Cerebral pressure autoregulation in traumatic brain injury. *Neurosurg Focus* 2008;25:E7.
27. Scheinker IM. Changes in cerebral veins in hypertensive brain disease and their relation to cerebral hemorrhage: Clinical pathologic study. *Arch Neurol Psychiatry* 1945;54:395-408.
28. Schoemaker I, Hoefnagel PP, Mastenbroek TJ, Kolff CF, Schutte S, van der Helm FC, *et al*. Elasticity, viscosity, and deformation of orbital fat. *Invest Ophthalmol Vis Sci* 2006;47:4819-26.
29. Shulman K. Small artery and vein pressures in the subarachnoid space of the dog. *J Surg Res* 1965;5:56-61.
30. Tuna BG, Bakker EN, vanbavel E. Smooth muscle biomechanics and plasticity: Relevance for vascular calibre and remodelling. *Basic Clin Pharmacol Toxicol* 2012;110:35-41.
31. Wahr JA, Gallagher KP, Tait AR, Hantler CB, Knight PR. Hemodynamic alterations and regional myocardial blood flow during supraceliac aortic occlusion in dogs with a critical coronary stenosis. *J Cardiothorac Vasc Anesth* 1991;5:3-9.
32. Williams LR, Leggett RW. Reference values for resting blood flow to organs of man. *Clin Phys Physiol Meas* 1989;10:187-217.
33. Wolff HG, Forbes HS. The cerebral circulation: V. Observations of the pial circulation during changes in intracranial pressure. *Arch Neurol Psychiatry* 1928;20:1035-47.

How to cite this article: Hekmatpanah J. Correlation of cerebral microvascular circulation with vital signs in cerebral compression and the validity of three concepts: vasodilation, autoregulation, and terminal rise in arterial pressure. *Surg Neurol Int.* 2024;15:95. doi: 10.25259/SNI_998_2023

Disclaimer

The views and opinions expressed in this article are those of the authors and do not necessarily reflect the official policy or position of the Journal or its management. The information contained in this article should not be considered to be medical advice; patients should consult their own physicians for advice as to their specific medical needs.