



Oncology

Juxtaglomerular cell tumor in a young male presenting with new onset congestive heart failure

Arvind Krishnan^a, Jeffy Jacob^b, Trushar Patel^{a,*}

^a Department of Urology, University of South Florida Health, Tampa, FL, USA

^b Touro College of Osteopathic Medicine, New York, NY, USA



ARTICLE INFO

Keywords:

Juxtaglomerular cell tumor
Renal mass
Urologic oncology
Hypertension

ABSTRACT

Renin secreting juxtaglomerular cell tumors are extremely rare benign tumors of the kidney. In this case, we highlight the atypical presentation of a young male patient presenting with vague complaints of worsening dyspnea, shortness of breath and anxiety. Initial workup of troponinemia and elevated BNP was initially most suggestive of a major cardiac event. An ejection fraction of 20% confirmed that this patient presented with heart failure. However, only further workup with imaging and renin and aldosterone labs revealed a functional renal mass as the cause. Timely intervention was pursued and pathology of the tumor was consistent with a juxtaglomerular cell tumor.

Introduction

Renin secreting juxtaglomerular cell tumors are extremely rare benign tumors of the kidney, which typically affect women in the third and fourth decades are most commonly affected.¹ Clinical presentation typically consists of hypertension in combination with hypokalemia due to the hypersecretion of renin. Associated symptoms may include polydipsia, polyuria, myalgia, and headaches.² Surgical removal of juxtaglomerular tumors acts as the definitive treatment option and is curative for hypertension related complications.

We detail an unusual case of a young male patient presenting with acute onset congestive heart failure, who was found to have an incidental renal mass. After medical workup and surgical resection, pathology revealed a juxtaglomerular cell tumor. We aim to shed light on the unique clinical presentation of our patient and report on the pathological features of the tumor.

Case presentation

A 41-year-old-male Hispanic male initially presented to the emergency department with complaints of intermittent episodes of dyspnea on exertion, anxiety, and associated diaphoresis.

Initial workup revealed severe hypertension with systolic pressures above 200 mmHg, hypokalemia (3.2 mmol/L) as well as elevated BNP and troponin. Due to concern for an acute cardiac event, patient was sent

urgently for cardiac catheterization.

Cardiac catheterization revealed bilaterally patent renal arteries and non-obstructive coronary artery disease. Patient was noted to have severe systolic dysfunction with a left ventricular ejection fraction of 20%, suggestive of acute onset congestive heart failure. Moderate pulmonary hypertension was also noted.

Further workup including imaging was then performed. A chest X-Ray revealed an enlarged cardiac silhouette and ruled out any consolidation in patient's lungs. Renal artery doppler studies were non-diagnostic as the proximal and mid renal arteries were obscured bilaterally but reported a 2.3cm loculated mass in the mid to lower pole of the left kidney. An MRI of the abdomen confirmed this finding of a cystic mass measuring 2.1 × 1.8 cm with multiple thick enhancing septations and an enhancing nodular component at the inferior pole of the left kidney, concerning for malignancy (Fig. 1). At this point, clinical suspicion for a functional renal tumor as the cause of the patient's clinical presentation was high. Further laboratory workup including plasma renin and aldosterone levels were obtained, both of which were elevated at 7.69H ng/mL/h and 9 ng/dL, respectively. Additionally, the aldosterone to plasma renin activity ratio was noted to be 1.2 (Reference range of 0.9–28.9). Of note, the serum creatinine remained normal at 1.1 throughout, indicating normal renal function.

Decision was then made to pursue surgical intervention to remove the lesion in question. Patient was cleared for surgery by cardiology, who performed a repeat echocardiogram which revealed an improved

* Corresponding author. Department of Urology, University of South Florida, USA.

E-mail address: tpatel7@usf.edu (T. Patel).

<https://doi.org/10.1016/j.eucr.2020.101189>

Received 26 February 2020; Received in revised form 31 March 2020; Accepted 1 April 2020

Available online 5 April 2020

2214-4420/© 2020 Published by Elsevier Inc. This is an open access article under the CC BY-NC-ND license (<http://creativecommons.org/licenses/by-nc-nd/4.0/>).

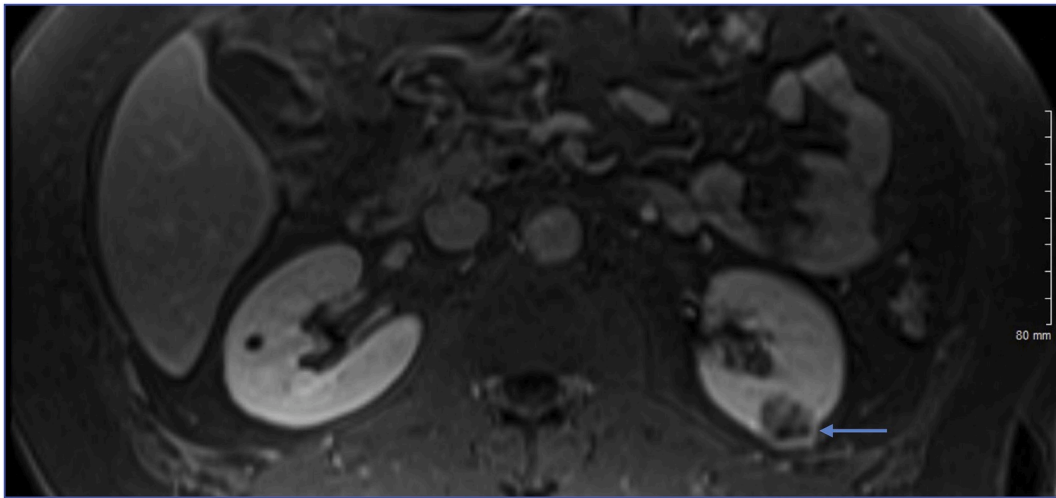


Fig. 1. T1 MR image with arrow demonstrating a left lower pole mass with nodular component concerning for malignancy.

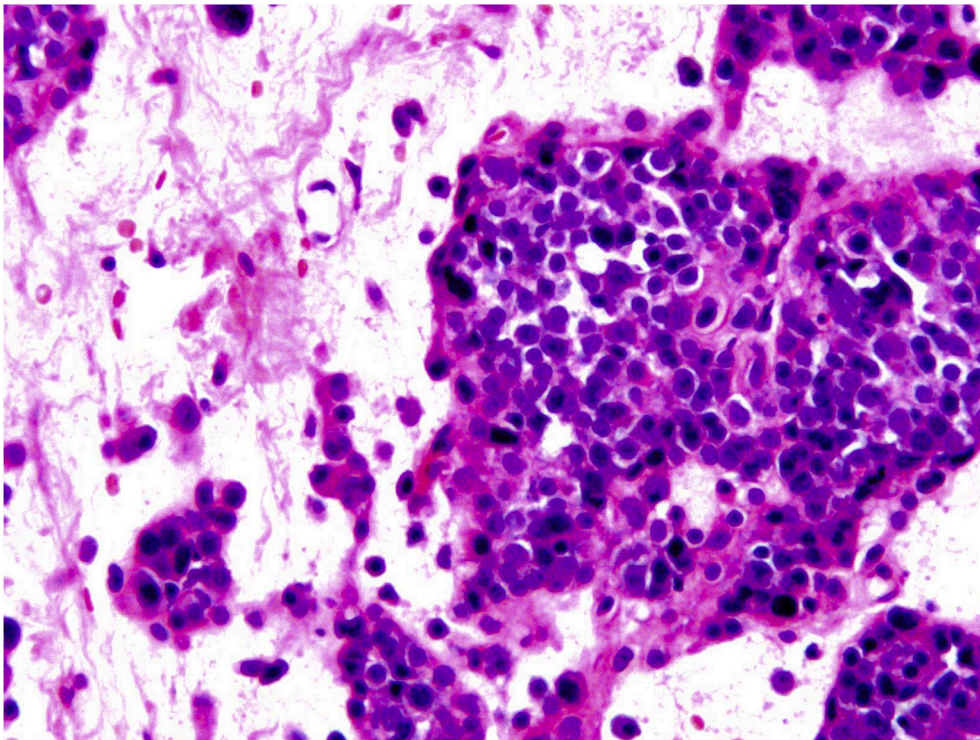


Fig. 2. Tumor cells demonstrating high mitotic activity with abundant eosinophilic cytoplasm and rounded nuclei with frequent intranuclear inclusions.

Ejection Fraction of 45%. A robotic assisted laparoscopic left partial nephrectomy was performed uneventfully. Postoperatively, the patient's blood pressure and hypokalemia resolved. Repeat echocardiogram revealed maintained normal ejection fraction.

Pathology revealed a 1.5 cm, well circumscribed, centrally hemorrhagic intraparenchymal renal mass composed of sheets and cords of tumor cells with many hyalinized blood vessels, dilated capillaries and myxoid stroma. Margins were negative. Tumor cells stained positive for abundant eosinophilic cytoplasm and rounded nuclei with frequent intranuclear inclusions (Fig. 2). Immunohistochemical staining performed on the tumor cell revealed a tumor positive for vimentin, CD34, GATA3 nuclear expression, and scattered CD 117 positive cells (Fig. 3). Negative for synaptophysin, CD 31, SMA, S100, PanCK, Myogenin, Factor-8, desmin, CK7, and CD-10. Together, these findings were most consistent with a juxtaglomerular cell tumor.

Discussion

Juxtaglomerular tumors are rare, benign tumors of the kidney, arising from specialized smooth muscle cells that are part of the normal vasculature of the juxtaglomerular apparatus.

Prompt diagnosis and timely intervention are imperative in order to prevent major cardiovascular or cerebrovascular events in the setting of a metabolically active juxtaglomerular tumor. Patients typically present with hypertension, hypokalemia, and complaints of polydipsia, myalgia, and headaches. The variation of elevation in blood pressure reported in patients is independent of tumor size. In some rare instances a metabolically inactive renin produced by the tumor would show no signs of elevated blood pressures.³

In young patients presenting with medication resistant hypertension, workup typically involves routine laboratory testing including complete

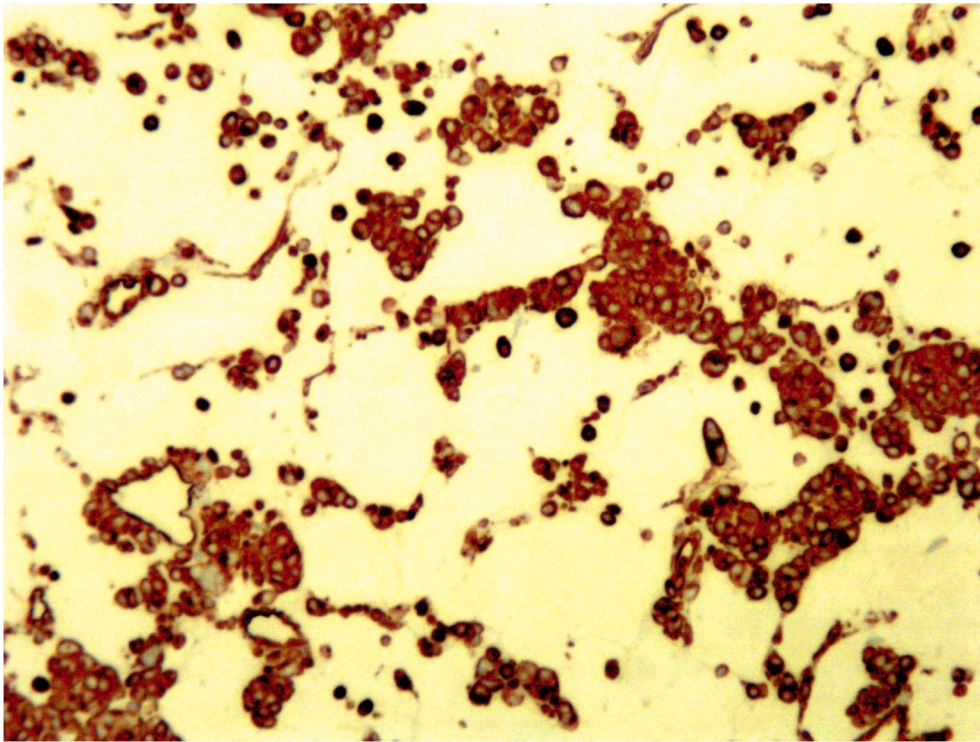


Fig. 3. Tumor cells staining positive for Vimentin.

blood count, basic metabolic panel, and cardiac enzymes. Additionally, plasma metanephrines, cortisol, renin and aldosterone levels should be obtained. Imaging in the form of a renal artery doppler will rule out arterial stenosis. A CT or MRI is also considered if there is clinical suspicion for a renal mass. If a renal mass is identified, surgical resection via a nephron sparing approach, is preferable. In the setting of a metabolically active mass such as a JG cell tumor, resolution of hypertension and associated symptoms is seen in most patients.⁴

On gross examination juxtaglomerular cell tumors usually appear enveloped in a fibrous capsule with tumor sizes ranging between 2 and 4 cm. Histologically, tumors are composed of polygonal to round to elongated, spindle-shaped cells. Most cases of juxtaglomerular cell tumors appear to show some degree of nuclear atypia and absent mitotic figures. The cells of juxtaglomerular cell tumors have been reported to be arranged in patterns such as: irregular trabeculated, papilla, organoid patterns, or solid compact sheets. Multiple thin and thick-walled vessels may also be present on histologic examination of juxtaglomerular tumors.⁵

JG tumors typically stain positive for actin and CD34 and negative for cytokeratins, desmin, S-100 protein, HMB-45, chromogranin and synaptophysin. Immunohistochemical staining helps distinguish the tumor from renal cell carcinoma and angiomyolipoma which stain positive for cytokeratins and HMB-45, respectively.

Conclusion

In this case, we highlight the atypical presentation of a young male patient presenting with vague complaints of worsening dyspnea, shortness of breath and anxiety. Initial workup of troponinemia and elevated

BNP was initially most suggestive of a major cardiac event. An ejection fraction of 20% confirmed that this patient presented with heart failure. However, only further workup with imaging and renin and aldosterone labs revealed a functional renal mass as the cause. Timely intervention was pursued and pathology of the tumor was consistent with a juxtaglomerular cell tumor.

This case emphasizes the variability in presentation of metabolically active renal tumors. Although the typical presentation of JG cell tumors is known, a low threshold to pursue further endocrinologic workup for functional renal masses should be maintained even in the setting of atypical clinical presentations such as this one. Additionally, we illustrate that prompt intervention will ultimately result in resolution of symptoms, which in young patients is critical.

Declaration of competing interest

None.

References

1. Markey Rachel B, Gregory T. MacLennan. "Juxtaglomerular cell tumor of the kidney. *J Urol.* 2006;175(2):730. [https://doi.org/10.1016/s0022-5347\(05\)00544-6](https://doi.org/10.1016/s0022-5347(05)00544-6), 730.
2. Nunes Igor, et al. Secondary hypertension due to a juxtaglomerular cell tumor. *J Am Soc Hypertens.* 2018;12(9):637–640. <https://doi.org/10.1016/j.jash.2018.05.005>.
3. Wein Alan J, ed. *Campbell-walsh Urology.* eleventh ed. Philadelphia: Saunders/Elsevier; 2016 (Print).
4. Trnka Peter, et al. Reninoma: an uncommon cause of renin-mediated hypertension. *Front Pediatrics.* 2014;2. <https://doi.org/10.3389/fped.2014.00089>.
5. Wong Lara, et al. Reninoma: case report and literature review. *J Hypertens.* 2008;26(2):368–373. <https://doi.org/10.1097/hjh.0b013e3282f283f3>.