

Case Report

Anterior Dislodgement of a Fusion Cage after Transforaminal Lumbar Interbody Fusion for the Treatment of Isthmic Spondylolisthesis

Hyeong Seok Oh, M.D.,¹ Sang-Ho Lee, M.D., Ph.D.,² Soon-Woo Hong, M.D., Ph.D.³

Department of Neurosurgery,¹ Busan Wooridul Spine Hospital, Busan, Korea

Department of Neurosurgery,² Seoul Wooridul Spine Hospital, Seoul, Korea

Department of Orthopaedic Surgery,³ Spine Love Hospital, Goyang, Korea

Transforaminal lumbar interbody fusion (TLIF) is commonly used procedure for spinal fusion. However, there are no reports describing anterior cage dislodgement after surgery. This report is a rare case of anterior dislodgement of fusion cage after TLIF for the treatment of isthmic spondylolisthesis with lumbosacral transitional vertebra (LSTV). A 51-year-old man underwent TLIF at L4-5 with posterior instrumentation for the treatment of grade 1 isthmic spondylolisthesis with LSTV. At 7 weeks postoperatively, imaging studies demonstrated that banana-shaped cage migrated anteriorly and anterolisthesis recurred at the index level with pseudoarthrosis. The cage was removed and exchanged by new cage through anterior approach, and screws were replaced with larger size ones and cement augmentation was added. At postoperative 2 days of revision surgery, computed tomography (CT) showed fracture on lateral pedicle and body wall of L5 vertebra. He underwent surgery again for paraspinous decompression at L4-5 and extension of instrumentation to S1 vertebra. His back and leg pains improved significantly after final revision surgery and symptom relief was maintained during follow-up period. At 6 months follow-up, CT images showed solid fusion at L4-5 level. Careful cage selection for TLIF must be done for treatment of spondylolisthesis accompanied with deformed LSTV, especially when reduction will be attempted. Banana-shaped cage should be positioned anteriorly, but anterior dislodgement of cage and reduction failure may occur in case of a highly unstable spine. Revision surgery for the treatment of an anteriorly dislodged cage may be effectively performed using an anterior approach.

Key Words : Cage · Transforaminal lumbar interbody fusion · Spondylolisthesis · Lumbosacral spine · Transitional vertebra.

INTRODUCTION

Transforaminal lumbar interbody fusion (TLIF) has become a common surgical method of spinal fusion. Compared with posterior lumbar interbody fusion (PLIF), TLIF is safer in insertion of a fusion cage into the intervertebral disc space. It has been used as an effective treatment for patients who have unstable low-grade isthmic spondylolisthesis that is unresponsive to nonsurgical treatment⁴. Also, several types of fusion cages have been developed for TLIF and some are almost the same as PLIF cages. Regardless of cage shape and number, complications associated with fusion cages have been reported in patients under TLIF^{7,19,22}. However, anterior cage migration during the follow-up period after PLIF or TLIF has not been reported to date.

We present a case of delayed anterior dislodgement of a banana-shaped polyetheretherketone (PEEK) cage following TLIF for the treatment of grade I isthmic spondylolisthesis with a lumbosacral transitional vertebra (LSTV) and dystrophic change of the L5 vertebra.

CASE REPORT

A 51-year-old man presented with lower back and radiating pain to both legs. His symptoms had developed 5 years ago, but conservative treatments had failed. On admission, he had a limping gait and his pain was aggravated by posture. Neurological examinations showed grade 4/5 strength in extension of his left big toe. Plain radiographs and CT images showed L4-5 grade

• Received : March 28, 2013 • Revised : June 24, 2013 • Accepted : August 5, 2013

• Address for reprints : Soon-Woo Hong, M.D., Ph.D.

Department of Orthopaedic Surgery, Spine Love Hospital, 1456 Jungsang-ro, Ilsanseo-gu, Goyang 411-838, Korea
Tel : +82-31-922-5555, Fax : +82-31-922-5555, E-mail : busan@wooridul.co.kr

• This is an Open Access article distributed under the terms of the Creative Commons Attribution Non-Commercial License (<http://creativecommons.org/licenses/by-nc/3.0>) which permits unrestricted non-commercial use, distribution, and reproduction in any medium, provided the original work is properly cited.

I isthmic spondylolisthesis with instability, a LSTV (Castellvi IIIa), and a dysplastic L5 vertebral body (Fig. 1)³⁾. The anteroposterior length of the cranial endplate of the L5 body was relatively shorter than that of the L4 body, even though the surface was flat. Magnetic resonance images showed canal and foraminal stenosis and L4-5 disc degeneration. The bone mineral density measured by Dual-emission X-ray absorptiometry showed a T score of -2.1 for the lumbar spines.

L4-5 decompression via bilateral paraspinous approaches was performed and a banana-shaped PEEK cage (WSH T-cage, WINNOVA CO., Ltd., Seoul, Korea) was inserted through an opening in the intervertebral disc on the left side, followed by bilateral pedicle screw fixation with reduction (VIPER™, DePuy Spine, Inc., Raynham, MA, USA). Local autograft and allograft cancellous bone chips were packed into the fusion cage and into the remaining intervertebral disc space posteriorly after the cage insertion. After surgery, the presenting symptoms significantly improved and the radiographs showed a good reduction (Fig. 2). The patient's pain was assessed on visual analogue scale and improved dramatically after surgery (before surgery; 8 for low back pain, 10 for leg pain : 1 week after surgery; 2 for low back pain, 2 for leg pain). The patient was discharged at postoperative 7 days and returned to daily living activities while wearing a corset.

Seven weeks after surgery, he visited to our outpatient clinic with severe low back and left leg pain for 7 days without any neurological deficit. He denied any history of trauma. Plain radiographs showed anterior dislodgement of the fusion cage as well as a reduction loss of the spondylolisthesis at the L4-5 level (Fig. 3A). Sagittal images on a CT scan demonstrated that the intervertebral space was not fused and the screws were loos-

ened with halo change (Fig. 3B). Physical signs and laboratory findings on admission did not support infection. Revision surgery using an anterior approach was performed to remove the displaced cage. A 5-cm-long midline incision was made and a retroperitoneal approach to the affected level was done using a robotic arm retractor. The anterior longitudinal ligament and annulus were not perforated. The cage had slipped down and was positioned anterior to the L5. After removal of the cage and previously grafted bones in the disc space, the endplates were carefully prepared. A wedge-shaped, lordotic titanium cage (WSH cage, WINNOVA CO., Ltd., Seoul, Korea) filled with allograft chips was inserted a little laterally to the left to avoid a collapsed portion of the inferior endplate of the L4 body. After the closure of the anterior surgical wound, the patient was positioned prone for pedicle screw replacement. The pedicle screws found unstable and in spite of being with thicker and longer ones, two L4 screws still remained loose. Therefore, cement augmentation was added to the L4 screws (Fig. 4A). Postoperatively, however, the patient complained of persistent pain on the

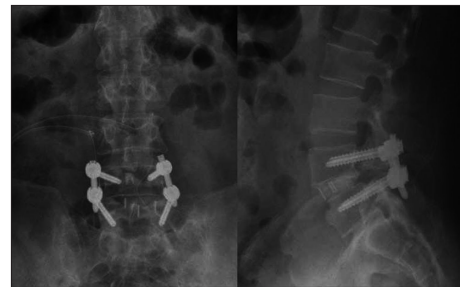

Fig. 2. Immediate postoperative radiographs showing a good reduction of the spondylolisthesis and a well-positioned fusion cage.

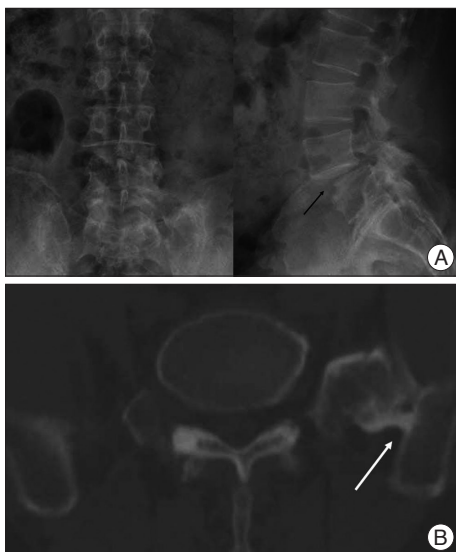

Fig. 1. Preoperative plain radiographs (A) and CT (B) showing a L4-5 grade I isthmus spondylolisthesis, dysplastic L5 body (back arrow) and lumbosacral transitional vertebra which consists of a bony union between an L5 transverse process and the sacrum on the left side (white arrow).

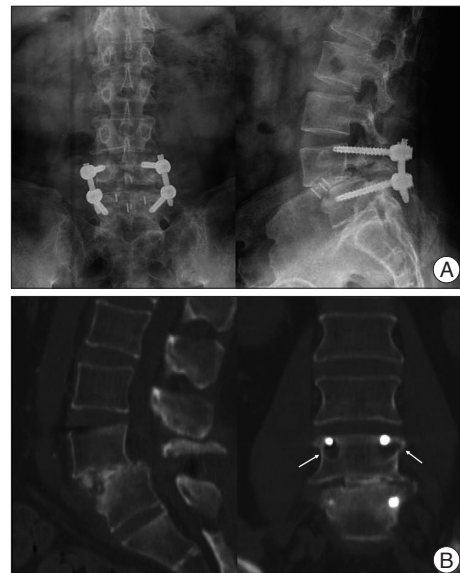

Fig. 3. Plain radiographs (A) and CT sagittal and coronal reconstruction images (B) at postoperative 7 weeks. A : Anterior dislodgement of the fusion cage as well as reduction loss of the spondylolisthesis at the L4-5 level. B : CT images showing that the intervertebral space was not fused and the L4 pedicle screws were loose with osteolysis (white arrows).

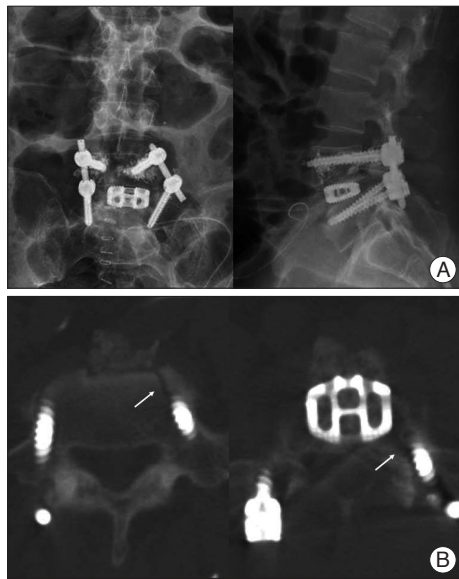


Fig. 4. Plain radiographs (A) and CT images (B) after the first revision surgery. A : The pedicle screws were unstable and replaced with thicker and longer ones, but two L4 screws remained loose. Therefore, cement was used to augment the L4 screws. B : CT images showing the pedicle and lateral body wall fracture in the L5 vertebra (white arrows).

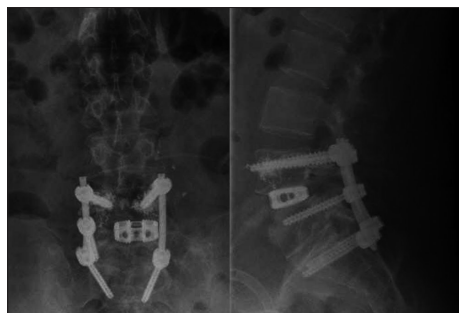

Fig. 5. Plain radiographs after the second revision surgery showing the removal of the left L5 screw and bilateral extension of the pedicle screw fixation to S1.

anterolateral side of the left leg and difficulty in walking. CT images showed a fracture on the pedicle and anterolateral lateral body wall of the L5 vertebra (Fig. 4B). As a result, he had additional surgery for paraspinal decompression on the left side at the L4-5 level. Removal of the left L5 screw followed by bilateral extensions of the pedicle screw fixation to S1 was performed (Fig. 5). Because the L5-S1 level was congenitally fused due to the LSTV, we considered that extension of the screw fixation made no additional motion limitation of the lumbosacral spine but increased stability.

After the second revision surgery, the patient showed significant improvement of his symptom except mild left leg discomfort. His gait was improved and the lumbar corset was applied for 3 months. At 6 months follow-up, his left leg discomfort was completely resolved. Radiographs and a 3-dimensional CT scan obtained at 6 months postoperatively revealed a solid fusion at the L4-5 level.

DISCUSSION

Fusion rates after the TLIF procedure using cages and bilateral pedicle screws instrumentation are reported to be more than 90%^{6,14,15}. Humphreys et al.⁹ evaluated patients receiving TLIF in comparison with PLIF and demonstrated that fewer complications occurred after TLIF than after PLIF. Several recent studies have described cases of posterior cage migration after TLIF procedures that were mostly associated with pseudoarthrosis^{19,22}. However, there are few case reports about anterior migration or dislodgement, and the causes included perforation of the annulus fibrosus during the removal of the disc or a feeble condition by spondylodiscitis^{20,21}. In which reports, migration was confirmed intraoperatively. Unlike these reports, our case had completed the initial surgery with good placement of the cage with satisfactory reduction. The authors have inferred that anterior dislodgement of the cage during the follow-up period seemed to result from the high stress at the index level and the abnormal shape of the L5 body.

The patient had a LSTV (Castellvi type IIIa) with a bony union between the transverse process and the sacrum on the left side. Usually, the increased stability between the transitional vertebra and the sacrum can potentially lead to hypermobility above the transitional vertebra⁵. Hypermobility and abnormal torque momentum at the intervertebral disc are believed to place the disk and facet joints at increased risk of degeneration^{2,13}. It has been postulated that patients with L5 transitional vertebra and isthmic defects in the L4 vertebra have greater risk of anterior slips than patients with L4-5 isthmic spondylolisthesis without transitional vertebra¹¹. Therefore, in our case, isthmic spondylolisthesis combined with a LSTV is considered to have contributed to the reduction loss at the index level during the follow-up.

Commonly, the shape of the vertebral body and the cage could affect cage migration. A recent study showed that banana-shaped cages should be placed anteriorly to avoid cage subsidence, considering regional strength variations of the vertebral endplates^{7,8}. This is supported by a biomechanical study demonstrating that central portions of the vertebral endplates from L3 to L5 are relatively weaker than anterior or posterior portions⁸. In our case, the cage was positioned ideally on the anterior portion of the intervertebral disc space at the time of the initial surgery. However, the high stress above the transitional vertebra was postulated to make the anterolisthesis recur. In addition, the relatively smaller contact area between the defective superior endplate of the L5 vertebra and the banana-shaped cage might influence the anterior dislodgement of the cage. Even though there have been some experimental studies that the cage shapes do not affect construct stability^{4,10,16}, cage migration could be affected by cage type and positioning¹. Therefore, a different type of cage from the banana-shaped ones could have been better for the patient in this particular case. In addition, as appears by this case, a more central location and longer length of a cage is con-

sidered to have been safer.

For the removal of the dislodged cage and the treatment of the pseudoarthrosis, the anterior approach was successful, because the revision surgery was not delayed and adhesion around the L4-5 disc was absent. Additional surgery via an anterior approach is a higher risk of complications, but it provides an easier preparation of the endplates, which have been already injured, and enables a larger cage insertion with a greater contact surface¹⁹). Several biomechanical studies reported that polymethylmethacrylate augmentation of pedicle screws, bicortical purchase, and replacement of screws with larger diameter are helpful in the setting of screw loosening^{12,17,18}). In our case, all these methods were eventually used to enhance the stability of the pedicle screw fixation during the revision surgery.

CONCLUSION

This is a case of anterior dislodgement of a fusion cage after TLIF. In the case of unstable isthmic spondylolisthesis accompanied with a LSTV, the surgeon should be cautious of selecting a fusion cage to be used because especially in cases of the banana-shaped cages there can be a potential of the anterior dislodgement. Additional surgery via an anterior approach may be effectively performed for removal of the displaced cage and reinsertion. Stability at the index segment can be acquired through the anterior cage insertion and the extension of posterior pedicle screw fixation accompanied by the replacement with the larger bicortical screws with cement augmentation.

• Acknowledgements

This study was supported by a grant from the Wooridul Spine Hospital.

References

- Abbushi A, Cabraja M, Thomale UW, Woiciechowsky C, Kroppenstedt SN : The influence of cage positioning and cage type on cage migration and fusion rates in patients with monosegmental posterior lumbar interbody fusion and posterior fixation. *Eur Spine J* 18 : 1621-1628, 2009
- Aihara T, Takahashi K, Ogasawara A, Itadera E, Ono Y, Moriya H : Intervertebral disc degeneration associated with lumbosacral transitional vertebrae : a clinical and anatomical study. *J Bone Joint Surg Br* 87 : 687-691, 2005
- Castellvi AE, Goldstein LA, Chan DP : Lumbosacral transitional vertebrae and their relationship with lumbar extradural defects. *Spine (Phila Pa 1976)* 9 : 493-495, 1984
- Cho W, Wu C, Mehbod AA, Transfeldt EE : Comparison of cage designs for transforaminal lumbar interbody fusion : a biomechanical study. *Clin Biomech (Bristol, Avon)* 23 : 979-985, 2008
- Elster AD : Bertolotti's syndrome revisited. Transitional vertebrae of the lumbar spine. *Spine (Phila Pa 1976)* 14 : 1373-1377, 1989
- Foley KT, Holly LT, Schwender JD : Minimally invasive lumbar fusion. *Spine (Phila Pa 1976)* 28 (15 Suppl) : S26-S35, 2003
- Fukuta S, Miyamoto K, Hosoe H, Shimizu K : Kidney-type intervertebral spacers should be located anteriorly in cantilever transforaminal lumbar interbody fusion : analyses of risk factors for spacer subsidence for a minimum of 2 years. *J Spinal Disord Tech* 24 : 189-195, 2011
- Grant JP, Oxland TR, Dvorak MF : Mapping the structural properties of the lumbosacral vertebral endplates. *Spine (Phila Pa 1976)* 26 : 889-896, 2001
- Humphreys SC, Hodges SD, Patwardhan AG, Eck JC, Murphy RB, Covington LA : Comparison of posterior and transforaminal approaches to lumbar interbody fusion. *Spine (Phila Pa 1976)* 26 : 567-571, 2001
- Kettler A, Schmoelz W, Kast E, Gottwald M, Claes L, Wilke HJ : In vitro stabilizing effect of a transforaminal compared with two posterior lumbar interbody fusion cages. *Spine (Phila Pa 1976)* 30 : E665-E670, 2005
- Kim NH, Suk KS : The role of transitional vertebrae in spondylolysis and spondylolytic spondylolisthesis. *Bull Hosp Jt Dis* 56 : 161-166, 1997
- Kiner DW, Wybo CD, Sterba W, Yeni YN, Bartol SW, Vaidya R : Biomechanical analysis of different techniques in revision spinal instrumentation : larger diameter screws versus cement augmentation. *Spine (Phila Pa 1976)* 33 : 2618-2622, 2008
- Konin GP, Walz DM : Lumbosacral transitional vertebrae : classification, imaging findings, and clinical relevance. *AJNR Am J Neuroradiol* 31 : 1778-1786, 2010
- Lauber S, Schulte TL, Liljenqvist U, Halm H, Hackenberg L : Clinical and radiologic 2-4-year results of transforaminal lumbar interbody fusion in degenerative and isthmic spondylolisthesis grades 1 and 2. *Spine (Phila Pa 1976)* 31 : 1693-1698, 2006
- Lowe TG, Tahernia AD, O'Brien MF, Smith DA : Unilateral transforaminal posterior lumbar interbody fusion (TLIF) : indications, technique, and 2-year results. *J Spinal Disord Tech* 15 : 31-38, 2002
- Lund T, Oxland TR, Jost B, Cripton P, Grassmann S, Etter C, et al. Interbody cage stabilisation in the lumbar spine : biomechanical evaluation of cage design, posterior instrumentation and bone density. *J Bone Joint Surg Br* 80 : 351-359, 1998
- McCord DH, Cunningham BW, Shono Y, Myers JJ, McAfee PC : Biomechanical analysis of lumbosacral fixation. *Spine (Phila Pa 1976)* 17 (8 Suppl) : S235-S243, 1992
- Ngu BB, Belkoff SM, Gelb DE, Ludwig SC : A biomechanical comparison of sacral pedicle screw salvage techniques. *Spine (Phila Pa 1976)* 31 : E166-E168, 2006
- Nguyen HV, Akbarnia BA, van Dam BE, Raiszadeh K, Bagheri R, Canale S, et al. : Anterior exposure of the spine for removal of lumbar interbody devices and implants. *Spine (Phila Pa 1976)* 31 : 2449-2453, 2006
- Pawar UM, Kundnani V, Nene A : Major vessel injury with cage migration : surgical complication in a case of spondylodiscitis. *Spine (Phila Pa 1976)* 35 : E663-E666, 2010
- Proubasta IR, Vallvé EQ, Aguilar LF, Villanueva CL, Iglesias JJ : Intraoperative antepulsion of a fusion cage in posterior lumbar interbody fusion : a case report and review of the literature. *Spine (Phila Pa 1976)* 27 : E399-E402, 2002
- Taneichi H, Suda K, Kajino T, Matsumura A, Moridaira H, Kaneda K : Unilateral transforaminal lumbar interbody fusion and bilateral anterior-column fixation with two Brantigan I/F cages per level : clinical outcomes during a minimum 2-year follow-up period. *J Neurosurg Spine* 4 : 198-205, 2006