



Endoscopic Endonasal Transethmoidal-Transsphenoidal Approach to a Cavernous Sinus Chondrosarcoma

Gianluca Agresta¹ Alberto Campione¹ Fabio Pozzi¹ Pierlorenzo Veiceschi^{1,2} Martina Venturini¹
Edoardo Agosti¹ Sergio Balbi¹ Paolo Battaglia³ Davide Locatelli¹

¹ Department of Biotechnology and Life Sciences, Division of Neurosurgery; University of Insubria, Ospedale di Circolo e Fondazione Macchi, Varese, Italy

² Scuola di specializzazione in Neurochirurgia, Università degli studi di Pavia, Italia

³ Division of Otorhinolaryngology, Department of Biotechnology and Life Sciences, University of Insubria, Ospedale di Circolo e Fondazione Macchi, Varese, Italy

Address for correspondence Gianluca Agresta, MD, Department of Biotechnology and Life Sciences, Division of Neurosurgery; University of Insubria, Ospedale di Circolo e Fondazione Macchi, Via Guicciardini, 132–21100, Varese, Italy (e-mail: gianluca.agresta9@gmail.com).

J Neurol Surg B Skull Base 2022;83(suppl S3):e625–e626.

Abstract

Objective We illustrate a cavernous sinus chondrosarcoma treated with an endoscopic endonasal transethmoidal-transsphenoidal approach.

Design Case report of a 15-year-old girl with diplopia and esotropia due to complete abducens palsy. Preoperative images showed a right cavernous sinus lesion with multiple enhanced septa and intralesional calcified spots (→ **Fig. 1**). Considering tumor location and the lateral dislocation of the carotid artery, an endoscopic endonasal approach was performed to relieve symptoms and to optimize the target geometry for adjuvant conformal radiotherapy.

Setting The study was conducted at University of Insubria, Department of Neurosurgery, Varese, Italy.

Participants Skull base team was participated in the study.

Main Outcome Measures A transethmoidal-transsphenoidal approach was performed by using a four-hand technique. We used a route lateral to medial turbinate to access ethmoid and the sphenoid sinus. During the sphenoid phase, we exposed the medial wall of the cavernous sinus (→ **Fig. 2**) and the lesion was then removed using curette. Skull base reconstruction was performed with fibrin glue and nasoseptal flap.

Keywords

- ▶ cavernous sinus
- ▶ chondrosarcoma
- ▶ endoscopic endonasal approach
- ▶ proton therapy
- ▶ skull base

Conflict of Interest
None declared.



www.thieme.com/skullbasevideos

www.thieme.com/jnlsbvideos

received
July 28, 2020
accepted
November 3, 2020
published online
May 3, 2021

DOI <https://doi.org/10.1055/s-0041-1726018>.
ISSN 2193-6331.

© 2021. The Author(s).

This is an open access article published by Thieme under the terms of the Creative Commons Attribution-NonDerivative-NonCommercial-License, permitting copying and reproduction so long as the original work is given appropriate credit. Contents may not be used for commercial purposes, or adapted, remixed, transformed or built upon. (<https://creativecommons.org/licenses/by-nc-nd/4.0/>)

Georg Thieme Verlag KG, Rüdigerstraße 14, 70469 Stuttgart, Germany

Results No complications occurred after surgery, and the patient experienced a complete recovery of symptoms. A postoperative magnetic resonance imaging showed a small residual tumor inside the cavernous sinus (→**Fig. 1**). After percutaneous proton-beam therapy, patient experienced only temporary low-grade toxicity with local control within 2 years after treatment completion.

Conclusion Endoscopic endonasal extended approach is a safe and well-tolerated procedure that is indicated in selected cases (intracavernous tumors, soft tumors not infiltrating the vessels and/or the nerves). A tailored approach according to tumor extension is crucial for the best access to the compartments involved.

The link to the video can be found at: <https://youtu.be/TsqXjquOws>.

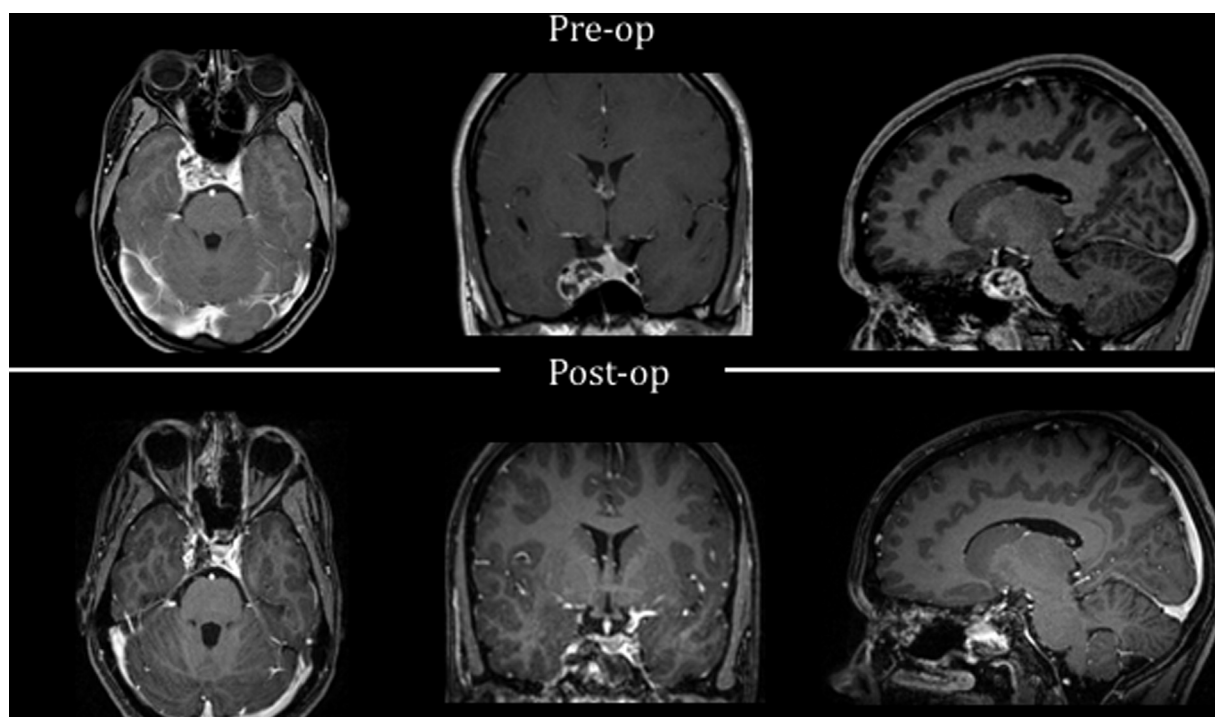


Fig. 1 Pre- and postoperative T1-weighted postgadolinium magnetic resonance imaging.

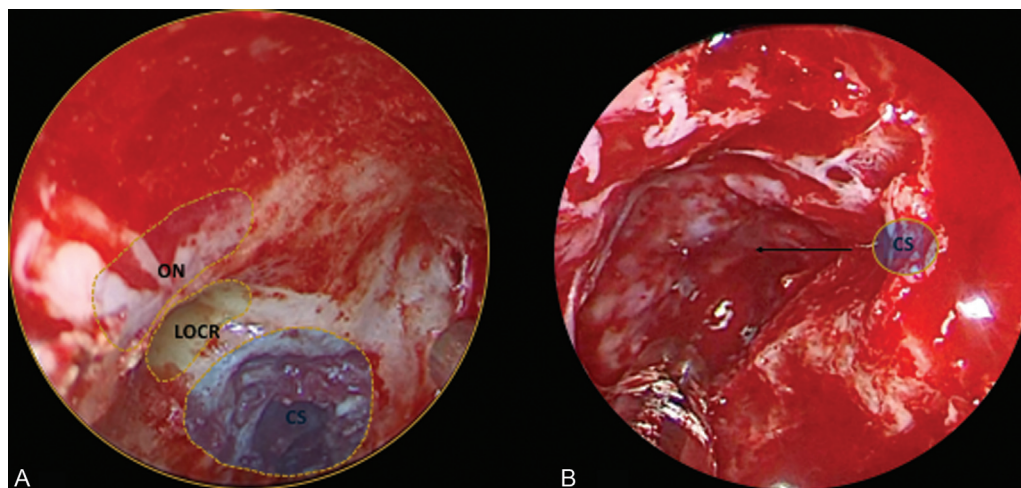


Fig. 2 Intraoperative images of the surgical field. (A) Anatomical landmarks. (B) The cavernous sinus after tumor removal. CS, cavernous sinus; LOCR, lateral opticocarotid recess; ON, optic nerve.