

MEETING ABSTRACT

Open Access

Optical Coherence Tomography: imaging of age related maculopathy

V Scordia*, M Rechichi

From de Senectute: Age and Health Forum
Catanzaro, Italy. 5-7 December 2009

Background

Age-related macular degeneration (AMD) is the leading cause of severe vision loss in the developed world in patients over 60 years. AMD is characterized by two distinct forms: dry and wet. Optical coherence tomography (OCT) is a non-invasive, useful and reproducible diagnostic tool that provides cross-sectional images of retina and has a primary role for diagnostic and therapeutic management of AMD. The spread of anti-VEGF intravitreal injection for therapy of wet AMD further emphasized the role of OCT for treatment algorithms allowing a precise characterization of lesions and strict non-invasive retinal monitoring in the follow-up.

Main indications and limits of OCT will be discussed as well as the various morphological presentations of dry and wet AMD underlying retinal changes before and after therapy.

Materials and methods

We analyzed 500 eyes of 270 patients affected by dry or wet AMD that underwent a complete ophthalmological examination and OCT scan with two different machines. A time domain OCT (TD-OCT, Stratus OCT3, Carl Zeiss Meditec, Dublin, CA) and a Fourier Domain OCT (FD-OCT, RTVue-100, Optovue, Fremont, CA).

We used a radial line pattern scan algorithm with TD-OCT (see Figure 1) and radial and raster scan with FD-OCT with additional tridimensional reconstruction (see Figure 2).

Results

B-scan analysis of two instruments allows detailed reproduction of anatomical retinal layers in AMD. FD-OCT images are more accurate and the computing process allows tridimensional reconstruction of sagittal and coronal plane.

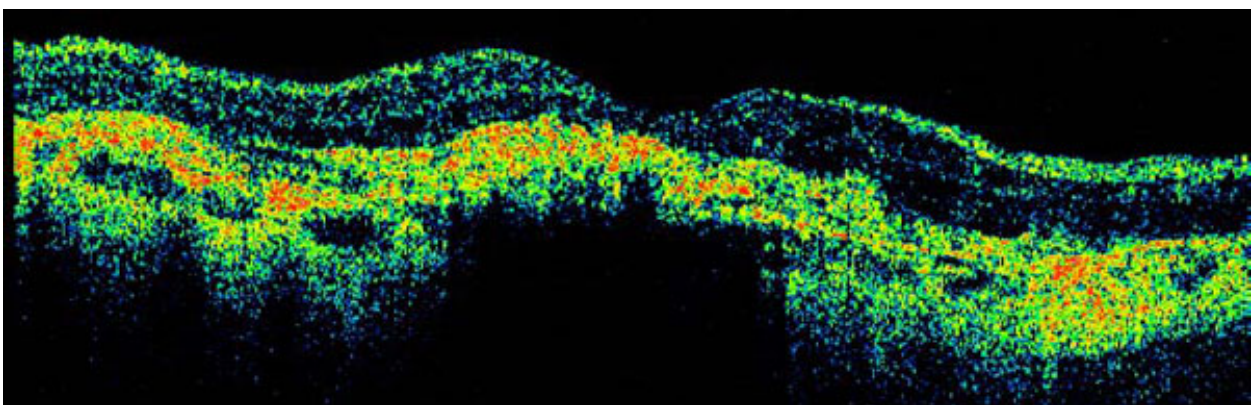


Figure 1 B-Scan image of TD-OCT with wet AMD

Department of Ophthalmology, Magna Græcia University, Catanzaro, 88100, Italy

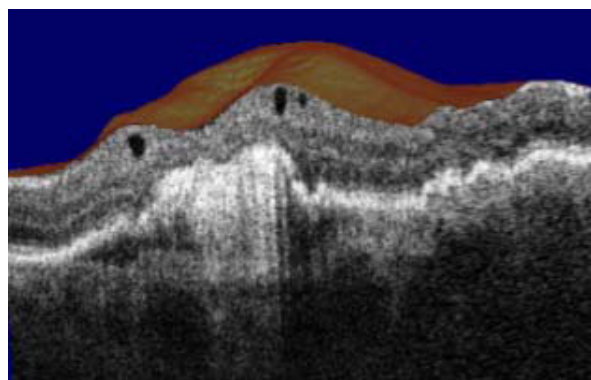


Figure 2 Tridimensional reconstruction of wet AMD (Fourier-Domain OCT).

Conclusions

Optical coherence tomography is a simply, non-invasive and reproducible technique for retinal imaging in patients with AMD. The spread of FD-OCT allows a precise characterization of AMD and accurate analysis of intraretinal layers. Tridimensional reconstruction tomography improves the visualization of photoreceptor morphology.

Published: 19 May 2010

doi:10.1186/1471-2318-10-S1-A78

Cite this article as: Scorcia and Rechichi: Optical Coherence Tomography: imaging of age related maculopathy. *BMC Geriatrics* 2010 10(Suppl 1):A78.

Submit your next manuscript to BioMed Central and take full advantage of:

- Convenient online submission
- Thorough peer review
- No space constraints or color figure charges
- Immediate publication on acceptance
- Inclusion in PubMed, CAS, Scopus and Google Scholar
- Research which is freely available for redistribution

Submit your manuscript at
www.biomedcentral.com/submit

 **BioMed Central**