

Incidence and Risk Factors of Ocular Hypertension/Glaucoma After Descemet Stripping Automated Endothelial Keratoplasty

Mohamed Elalfy^{1-3,*}

Sundas Maqsood^{1,*}

Shady Soliman³

Sherif Momtaz Hegazy³

Ahmed Abdou Hannon³

Zisis Gatzoufas^{1,4}

Damian Lake¹

Samer Hamada¹

¹Corneo Plastic Unit, Queen Victoria Hospital, East Grinstead, UK; ²Eye Department, Maidstone and Turnbridge Wells Hospital, Maidstone, UK;

³Research Institute of Ophthalmology, Giza, Egypt; ⁴Eye Department, University Hospital Basel, Basel, Switzerland

*These authors contributed equally to this work

Purpose: To evaluate the incidence, demographics, associated risk factors, management and clinical outcomes of ocular hypertension/glaucoma after Descemet stripping automated endothelial keratoplasty (DSAEK).

Methods: A cohort review of 81 DSAEK cases was performed at Queen Victoria Hospital, United Kingdom. Patients with pre-existing glaucoma, transient increased IOP within the first 48 hours post-graft, additional post-transplant surgery, or failed to complete one year follow-up were excluded from the study. Ocular hypertension was defined as intraocular pressure (IOP) elevation $>21\text{mmHg}$ or $\geq 6\text{mmHg}$ from baseline at any postoperative visit. The study looked at the incidence, risk factors, response to anti-glaucoma treatment, graft failure and best corrected visual acuity.

Results: The incidence of post-DSAEK ocular hypertension and glaucoma was 51.9% and 13.6%, respectively. Steroid-induced IOP elevation was the most frequent cause, with an incidence of 38.3%. Risk factors such as pseudophakia ($p=0.024$) and preoperative IOP >16 ($p=0.003$) were found to be associated with post-DSAEK ocular hypertension. Preoperative IOP >16 had 5.27 times risk of IOP elevation. Eyes with graft dislocation and/or detachment were significantly associated with post-DSAEK glaucoma ($p=0.038$). There was no negative effect of OHT on visual acuity and graft status.

Conclusion: Glaucoma and OHT are common postoperative complications of DSAEK. Although steroid-induced IOP elevation was the most frequent cause, there are other reasons associated with development of post-DSAEK glaucoma, including graft dislocation and detachment. Eyes with preoperative IOP >16 mm Hg may require a close monitoring of IOP. In addition, management by medical treatment results in good visual acuity and graft clarity.

Keywords: Descemet's stripping endothelial keratoplasty, DSAEK, glaucoma, ocular hypertension

Introduction

Corneal transplantation is one of the most frequently performed transplant surgeries in humans.¹ The 2019–2020 NHSBT report confirmed the number of total corneal transplants performed in the UK was 4504 (1486 DSAEK operations) compared to total organ transplants of 4140.² Despite its high success rate, there are several recognized complications. For example, poor graft centration and damage to surrounding ocular structures can occur intra-operatively; while complications such as infection, wound dehiscence, graft failure, graft rejection and ocular hypertension (OHT) can occur postoperatively.¹

Correspondence: Mohamed Elalfy
Queen Victoria Hospital, Holtye Road,
East Grinstead, West Sussex, RH19 3DZ,
UK
Tel +44 01342414560
Email m.elalfy@nhs.net

Over the past decade, partial thickness corneal transplant procedures have been developed, such as deep anterior lamellar keratoplasty (DALK), Descemet stripping automated endothelial keratoplasty (DSAEK) and Descemet membrane endothelial keratoplasty (DMEK).^{1,3} DSAEK has become a favorable procedure over traditional penetrating keratoplasty (PKP) due to its rapid healing, faster visual recovery, minimal refractive change, less risk of graft rejection and better corneal integrity.^{3,4} It is often chosen in patients with endothelial corneal disease to replace the damaged corneal endothelium and Descemet membrane.⁵ Compared to PKP, early reports showed less IOP changes after DSAEK,⁵ the incidence of post-DSAEK OHT was reported between 0% to 18%.⁵⁻⁸ Despite being the most frequent postoperative complication, the incidence rate of OHT after DSAEK has not been clearly established.

Ocular hypertension is the most significant risk factor following endothelial transplants that can lead to glaucoma. This can pose serious impact on patients due to its difficult diagnosis, monitoring for progression, complexity of management and the risk of compromising vision in the presence of other corneal comorbidities.^{9,10} It may lead to irreversible visual loss by damaging optic nerve¹¹ and donor corneal endothelium, leading to graft failure.¹²

Recent DSAEK studies have been largely focused on IOP elevation in eyes with pre-existing glaucoma and Fuch's endothelial dystrophy, with limited data on the risk factors in secondary glaucoma development, or pseudophakic bullous keratopathy.¹³ There is also lack of data in current literature on the efficacy of different treatment regimens,¹⁴ and this can often be due to the absence of postoperative management protocols and physicians' tailored treatment plans.³

Therefore, the aim of this work is to describe incidence, demographics, associated risk factors, management and clinical outcomes of OHT or glaucoma after DSAEK.

Methods

A review of case records of 120 DSAEK cases performed by two experienced surgeons using standardized surgical technique and postoperative regime. All DSAEK procedures were performed at the tertiary center Queen Victoria Hospital, United Kingdom. Cases were identified from eye bank records according to diagnosis codes. All patient notes reviewed had a minimum of one year follow up. The study was registered with local institutional review

board and adhered to the tenets of the Declaration of Helsinki.

Ocular hypertension was defined as raised IOP of ≥ 21 mmHg¹⁴ or an increase in IOP from preoperative value ≥ 6 mmHg at any post-operative examination. All eyes with postoperative elevated IOP were then categorized into: steroid responders defined as eyes in which the normalized IOP was ≤ 21 mmHg or back to preoperative levels (if was included due to raised IOP ≥ 6 mmHg) when the steroid treatment ended,¹⁴ and post-DSAEK glaucoma defined as documented increase in the cup-to-disc (CD) ratio of ≥ 0.7 compared to pre-operative appearance and/or glaucomatous visual field defect at any postoperative visits that was not present before surgery.

Patient who had prior history of glaucoma, transient increased IOP within the first 48 hours post-graft, additional post-transplant surgery, or failed to complete one year follow-up were excluded from the study.

The clinical data collected preoperatively for each patient included age, sex, ethnicity, other relevant past ocular history including family history, uncorrected distance visual acuity (UDVA), distance corrective visual acuity (CDVA), central corneal thickness (CCT), risk factors for glaucoma and indication for surgery. Details of surgery including additional procedures or intraoperative complication were also collected.

Post-operative complications and management, potency and dosage of steroid use and IOP measurements were reviewed and recorded. With regards to IOP elevation, the following data was also noted: the timing of postoperative ocular hypertensive events, IOP management including change in potency of steroid drops and additional glaucoma medication, development of characteristic glaucomatous optic disc and visual field changes, further surgery for glaucoma and date of controlled IOP. Last appointment details were also reviewed for each patient for last follow up date, post-operative UDVA, post-operative CDVA, episodes of graft rejection and failure, ongoing glaucoma medication, measurement of IOP, CCT, optic disc appearance and visual fields. Intraocular pressure measurements were obtained by Goldmann applanation tonometry.

Surgical Technique

All cases were performed under sub tenon blocks, with patients receiving additional sedation or general anesthesia according to patient indications. Descemet's membrane was stripped up to 9mm diameter with AC maintainer in

place. An 8.5mm pre-cut donor graft tissue of 80–100 microns thickness was transplanted through a 4.5mm wound using Busin glide and forceps and two paracentesis in place. The graft was secured firstly with a full air fill. The air was left in the AC for 10 mins while the dilating drops were instilled (tropicamide 1%, phenylephrine 2.5% and cyclopentolate 1%). After 10 mins the air was released down to 90% of anterior chamber filling by introducing intracameral cefuroxime (0.1mL/1mg). One 10/0 nylon suture was placed at the main incision. Subconjunctival dexamethasone (0.4mL - 4mg/mL) and cefuroxime (0.1mL/1mg) injected as the last step of the procedure. Patients were reviewed 60mins following procedure for further air release down to 60–70% if IOP of >25mmHg. All patients had oral acetazolamide 500mg stat, topical cyclopentolate 1% three times a day for a week and dexamethasone 1% for 3 months and chloramphenicol 0.5% four times a day for four weeks.

All data were entered into a spreadsheet, and statistical analysis was performed with SPSS 22.0 for Windows (SPSS, Chicago, IL). Descriptive statistics were expressed as range (mean \pm standard deviation). Snellen visual acuities were converted to the logarithm of the minimum angle of resolution (LogMar) for statistical analysis. Univariate analysis included Chi-square test or Fisher's exact test in categorical comparisons. Logistic regression was also performed to analyze the statistically significant variables in the univariate analysis. Differences were considered statistically significant when *P* values were less than 0.05.

Results

On the basis of the inclusion and exclusion criteria, 81 eyes qualified for the study. All participants were Caucasians, 32 (39.5%) were males and 49 (60.5%) were females. Age ranged between 41 to 94 years (77 \pm 10.365 years). The average follow-up period was 27 \pm 13.71 months, with a range of 12 to 66 months.

Table 1 summarizes the demographic data and baseline characteristics including the main indications for corneal transplantation, graft status and medical comorbidities. Other relevant history, such as family history of glaucoma was found in 3 patients (3.3%).

More than half of the cohort underwent DSAEK with additional surgical procedures: 38 eyes (86.3%) had cataract surgery, 3 eyes (6.8%) had anterior vitrectomies with IOL exchange, 2 eyes (4.5%) had IOL exchange and 1 eye (2.3%) had anterior chamber (AC) tap. The mean preoperative UDVA and CDVA were 1.0 \pm 0.58

Table 1 Results of Demographics and Baseline Characteristics

		Total No. of Patients (n=81) (%)
Eyes	Right	51 (63%)
	Left	30 (37%)
Indication for DSAEK	FED	59 (72.8%)
	PBK	10 (12.3%)
	ABK	1 (1.2%)
	Failed keratoplasty	10 (12.3%)
	ICE syndrome	1 (1.2%)
Eye status	Phakic	60 (75%)
	Pseudophakic	20 (24.7%)
	Aphakic	1 (1.2%)
Medical Comorbidities	Hypertension	36 (40%)
	Hypertension and Diabetes	5 (6.2%)
	Diabetes	8 (13.3%)
Surgical procedure	DSAEK only	37 (45.7%)
	Combined surgery	1 (54.3%)

Abbreviations: FED, Fuchs endothelial dystrophy; PBK, pseudophakic bullous keratopathy; ABK, aphakic bullous keratopathy; ICE syndrome, Iridocorneal endothelial syndrome; DSAEK, Descemet stripping automated endothelial keratoplasty.

logMAR units and 0.7 \pm 0.66 logMAR units respectively. The average preoperative IOP was 15.05 \pm 3.542 mmHg in a range of 6 to 26 mmHg. The mean pre-graft and post-graft CCT was 674.97 \pm 97.61 μ m and 667.97 \pm 85.76 μ m respectively.

None of the patients developed any intra-operative complications. Twenty patients (24.7%) developed post-operative complications: 13 (16%) eyes had DSAEK detachment (partial), 5 (6%) eyes had graft dislocation and 2 (2.5%) eyes developed microbial keratitis. Graft detachment and dislocation were successfully reattached and repositioned in all complicated cases.

Table 2 shows the incidence of OHT and post-DSAEK glaucoma. Forty-two patients (51.9%) developed post-DSAEK IOP elevation between one week and 32 months (6.5 \pm 6.83 months) postoperatively. The average IOP at time of diagnosis of OHT was 26 \pm 7.79 mmHg, ranging between 22 to 59 mmHg. All ocular hypertensive eyes were treated medically within one week to 40 months (5.61 \pm 7.13), and follow up was lost in 2 patients. The first step of OHT management was either tapering of Dexamethasone or switch to a less potent steroid; switch was made either to

Table 2 Management of Post-Operative Intraocular Pressure

		No. of Patients (%)
Incidence (n=81) Incidence of subgroup of raised IOP (n=81)	Raised IOP	42 (51.9%)
	Post-DSAEK	11 (13.6%)
	glaucoma	16 (19.8%)
	Steroid responder	15 (18.5%)
First step of IOP management (n=42)	OHT only*	15 (18.5%)
	Tapering of Dexamethasone	6 (14.3%)
	Switch to Loteprednol	28 (66.7%)
	Switch to Fluorometholone	8 (19%)
Respond to steroid switch or tapering (n=40)**	Yes	16 (40%)
	No	24 (60%)
Second step of IOP management (n=24): Maximum no. of anti-glaucoma medications at any time	1 agent	17 (70.8%)
	2 agents	5 (20.8%)
	3 agents	1 (4.2%)
	4 agents	1 (4.2%)
Surgical management	Glaucoma surgery	0

Notes: *OHT only = eyes with raised IOP which neither steroid responder nor post-DSAEK glaucoma, **Follow up was lost in 2 patients. Switch was made to Loteprednol in 28 eyes (66.7%), in which OHT was diagnosed from 1 week to 32.85 months (7.48 ± 6.39). Eight eyes (19%) were switched to Fluorometholone 1.0%, where OHT was diagnosed from 2.27 months to 25.36 months (11.64±7.95). The remaining 7 patients (14.3%) were treated with Dexamethasone tapering. There was no statistically significant difference between them in lowering IOP (chi-square test, p=0.54).

Abbreviations: OHT, ocular hypertension; DSAEK, Descemet stripping automated endothelial keratoplasty.

Loteprednol (if diagnosed before 6 months post-operative period) or Fluorometholone (if diagnosed after 6 months post-operative period). The incidence of steroid-induced raised IOP was 16 eyes (19.8%). The mean daily frequency of Dexamethasone 0.1% at the time of IOP elevation was four times per day. The time it took to develop steroid-induced OHT ranged from one week to 16.03 months (5.7 ± 4.04 months) postoperatively. The mean of steroid-induced IOP elevation was 28 ± 6.20 mmHg, (range of 22 to 52 mmHg). The incidence of OHT only where ocular hypertensive eyes neither grouped into steroid responders nor post-DSAEK glaucoma was 18.5%.

The incidence of post-DSAEK glaucoma was 11 (13.6%) eyes, occurring from 6.5 weeks to 32.85 months postoperatively (mean 9.37 ± 9.68 months). In this group, IOP ranged from 22 to 59 mmHg (31.09±11.21mmHg). In 11 eyes of post-DSAEK glaucoma, IOP were controlled medically from

one week to 20 months (5.19±5.38 months). None of the patients required glaucoma surgery to control IOP.

After the initial management, a total of 16 eyes (19.8%) were identified to be steroid responder where their IOP normalized with steroid change or tapering, meeting our inclusion criteria. IOP in steroid responders was controlled from 3 weeks to 20 months (6.56±5.47 months). The remaining 24 ocular hypertensive eyes (60%) that did not respond to steroid, required second stage of treatment by using anti-glaucoma medications to control IOP, and the maximum number of medications used were detailed in Table 2. As expected, there was a positive correlation between the amount of IOP drop and the number of anti-glaucoma medication used (P<0.0001, ANOVA). Among the whole cohort, 17 eyes (21%) were still using anti-glaucoma medications at the last follow up.

Table 3 Comparison of Demographic Characteristics, IOP and Graft Status Between Patients with and without IOP Elevation After DSAEK

Variables	With IOP Elevation (n=42) n%	Without IOP Elevation (n= 39) n%	P value
Gender			
Male (n=32)	18 (56.3%)	14 (43.7%)	0.52 ^b
Female (n=49)	24 (49%)	25 (52%)	0.89 ^b
Indication for surgery			
FED (n= 59)	30 (50.8%)	29 (49.2%)	0.77 ^b
PBK (n=10)	5 (50%)	5 (50%)	1.00 ^a
ABK (n=1)	1 (100%)	0	1.00 ^a
Failed keratoplasty (n=10)	6 (60%)	4 (40%)	0.74 ^a
ICE syndrome (n=1)	0	1 (100%)	1.00 ^a
Eye status			
Pseudophakic (n=20)	6 (30%)	14 (70%)	0.024 ^b
Exposure to risk			
Age ≤60 (n=4)	2 (50%)	2 (50%)	1.00 ^a
Hypertension (n=41)	21 (51.2%)	20 (48.8%)	0.91 ^b
T2DM (n=8)	3 (37.5%)	5 (62.5%)	0.47 ^a
Family history of glaucoma (n=3)	2 (66.7%)	1 (33.3%)	1.00 ^a
Preoperative IOP>16 (n=39)	27 (69.2%)	12 (30.8%)	0.003 ^b
Combined procedure	25 (56.8%)	19 (43.2%)	0.33 ^b
Postoperative complications developed	10 (50%)	10 (50%)	0.85 ^b

Notes: ^a Fishers exact test, ^bChi-square test.

Abbreviations: FED, Fuchs endothelial dystrophy; PBK, pseudophakic bullous keratopathy; ABK, aphakic bullous keratopathy; ICE syndrome, Iridocorneal endothelial syndrome; DSAEK, Descemet stripping automated endothelial keratoplasty.

Table 4 Comparison of CDVA Between Eyes with and without OHT

Visual Acuity (LogMAR)	Eyes without OHT (n=39)		Eyes with OHT (n=42)	
	Preoperative CDVA n(%)	Postoperative CDVA n(%)	Preoperative CDVA n(%)	Postoperative CDVA n(%)
≤ 1.00	12(30.8%)	7 (17.9%)	11 (26.2%)	4 (9.5%)
0.90	1 (2.6%)	3 (3.7%)	3 (7.1%)	1 (2.4%)
0.16	3 (7.7%)	3 (3.7%)	4 (9.5%)	0
0.20	1 (2.6%)	9 (10%)	8 (19%)	2 (2.8%)
0.25	5 (12.8%)	3 (7.7%)	1 (7.4%)	1 (2.4%)
0.32	8 (20.5%)	2 (5.1%)	4 (9.5%)	2 (4.8%)
0.40	3 (7.7%)	5 (12.8%)	6 (14.3%)	7 (16.7%)
0.50	4 (10.3%)	2 (5.1%)	4 (9.5%)	5 (11.9%)
0.63	2 (5.1%)	9 (23.1%)	1 (2.4%)	12 (28.6%)
0.80	0	9 (23.1%)	0	4 (9.5%)
0.0 or better	0	2(5.1%)	0	4 (9.5%)

Abbreviations: CDVA, corrected distance visual acuity; OHT, ocular hypertension.

Univariate analysis was performed to identify individual risk factors for post-DSAEK OHT, details as shown in Table 3, Table 4. In this analysis, age, sex, the indications for keratoplasty, combined surgery, medical comorbidities and family history of glaucoma were not found to be significant risk factors for post-operative OHT (chi-square test, p values 0.52 to 1.00). In contrast, the following factors were found to be significant risk factors for IOP elevation after DSAEK, preoperative IOP>16 mmHg (p=0.003) and pseudophakia (p=0.024).

Significant risk factors, ie, preoperative IOP>16 mmHg and pseudophakia were then subjected to logistic regression analysis, only preoperative IOP>16 [OR 5.27; 95% CI, 1.89–13.64; p=0.001] was found to be associated with postoperative OHT with 5.27 times risk. In contrast, the odds ratio for pseudophakia [OR 0.3; 95% CI, 0.1–0.88; p=0.028] was less than one, which had less risk of developing post-DSAEK OHT when compared to preoperative IOP>16 mmHg.

With regards to post-DSAEK glaucoma, eyes that developed postoperative complication such as graft dislocation and/or detachment were found to be statistically significant associated with post-DSAEK glaucoma (Fisher's exact test, p=0.038).

Preoperative UDVA ranged from less than 6/60 to 6/9.5, (1.07 ± 0.59 logMAR units) (Table 4). Paired sample t-test revealed that there was an improvement from preoperative (1.07 ± 0.59 logMAR units) to postoperative UDVA (0.63, ± 0.56 logMAR units) (p<0.0001). Details of UDVA and CDVA are presented in Figure 1 and comparison of CDVA in eyes with and without OHT is shown in Figure 2.

None of the patients developed any intra-operative complications. Twenty patients (24.7%) developed post-operative complications: 13 (16%) eyes had DSAEK detachment, 5 (6%) eyes had graft dislocation and 2 (2.5%) eyes developed microbial keratitis. Graft detachment and dislocation were successfully reattached and repositioned in all complicated cases.

We reported on graft status at the last follow up among the whole cohort and in ocular hypertensive eyes. Episodes of graft rejection occurred in 3 eyes (3.7%), and in 6 eyes (7.4%) corneal graft has failed. In eyes with IOP elevation, there were 2 (4.8%) graft failures and none developed graft rejection. All eyes diagnosed with post-DSAEK glaucoma achieved clinically significant better CDVA (p<0.001) and a clear graft at last follow up visit.

Discussion

To date, the incidence of OHT or glaucoma after DSAEK has been inconsistent in the literature, this is because of the heterogeneity in the definition of OHT, inclusion criteria, follow-up duration, and steroid regime. This study not only evaluate the incidence of elevated IOP after DSAEK but also the incidence of post-DSAEK glaucoma, the associated risk factors, management and clinical outcomes of OHT after DSAEK.

Elevated IOP and glaucoma are the most frequent post-operative complications after both PKP and DSAEK.^{10,15–18} Sharma and associates demonstrated that post procedure IOP control requiring treatment after PKP is significantly difficult compared to post DSAEK patients.¹⁹ Compared to the above mentioned studies, we

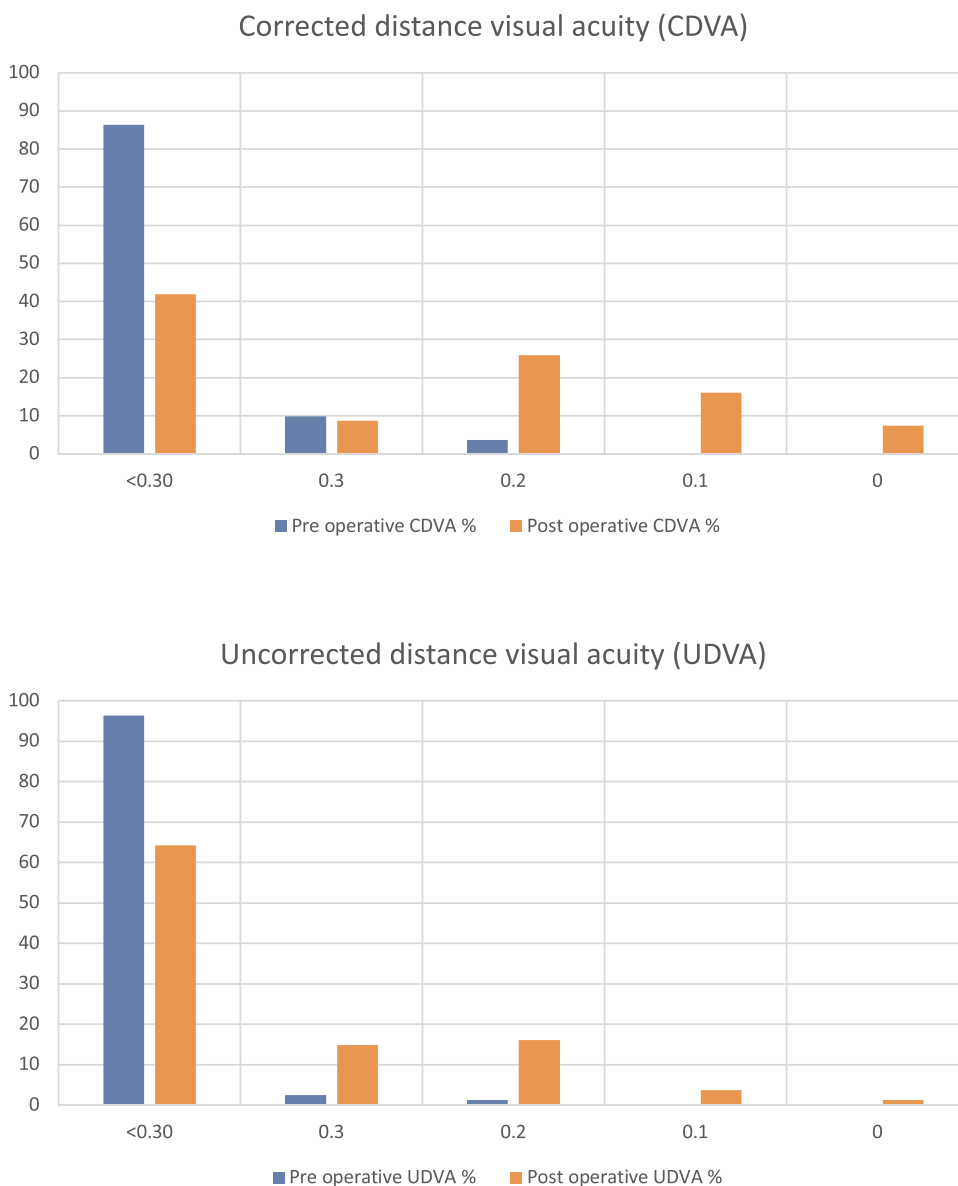


Figure 1 Percentage comparison of preoperative and post-operative distance corrected visual acuity (CDVA) and uncorrected distance visual acuity (UDVA).

found a higher percentage of IOP elevation after DSAEK of 51.9%; in addition, it was even higher than eyes with preexisting glaucoma after DSAEK, which is reported to be 43% to 45%.¹⁸ However, our finding is comparable to reported incidence of 51% OHT in the study including cases with and without preexisting glaucoma.¹⁷ The inconsistency of findings on incidence could be a result of the difference in definition of OHT; if we used IOP greater than or equal to 24mmHg as a cutoff value, as defined in Vajaranant and associates, the incidence would be 36 out of 81 eyes (44.4%).

For PKP, corneal disease,²⁰ BPK, and trauma have been reported as high risk factors for OHT.^{21,22} Our

study confirms that such surgical indications do not influence the risk of IOP elevation after DSAEK, which is in agreement with previous reported literature.^{21,23}

A majority of studies have been done to compare the incidence of OHT after DSAEK between non-preexisting and preexisting glaucoma eyes; consistent results supported that preexisting glaucoma predicts IOP elevation after DSAEK,^{3,14,17,18} which we eliminated in our study. The risk of OHT has been reported to be increased in eyes with goniosynechiolysis, postoperative procedures and complications, age<60 years and glaucoma in fellow eye with 3.3, 2.9, 2.4 and 3.2 times respectively.¹³ In this work, we excluded cases with additional postoperative

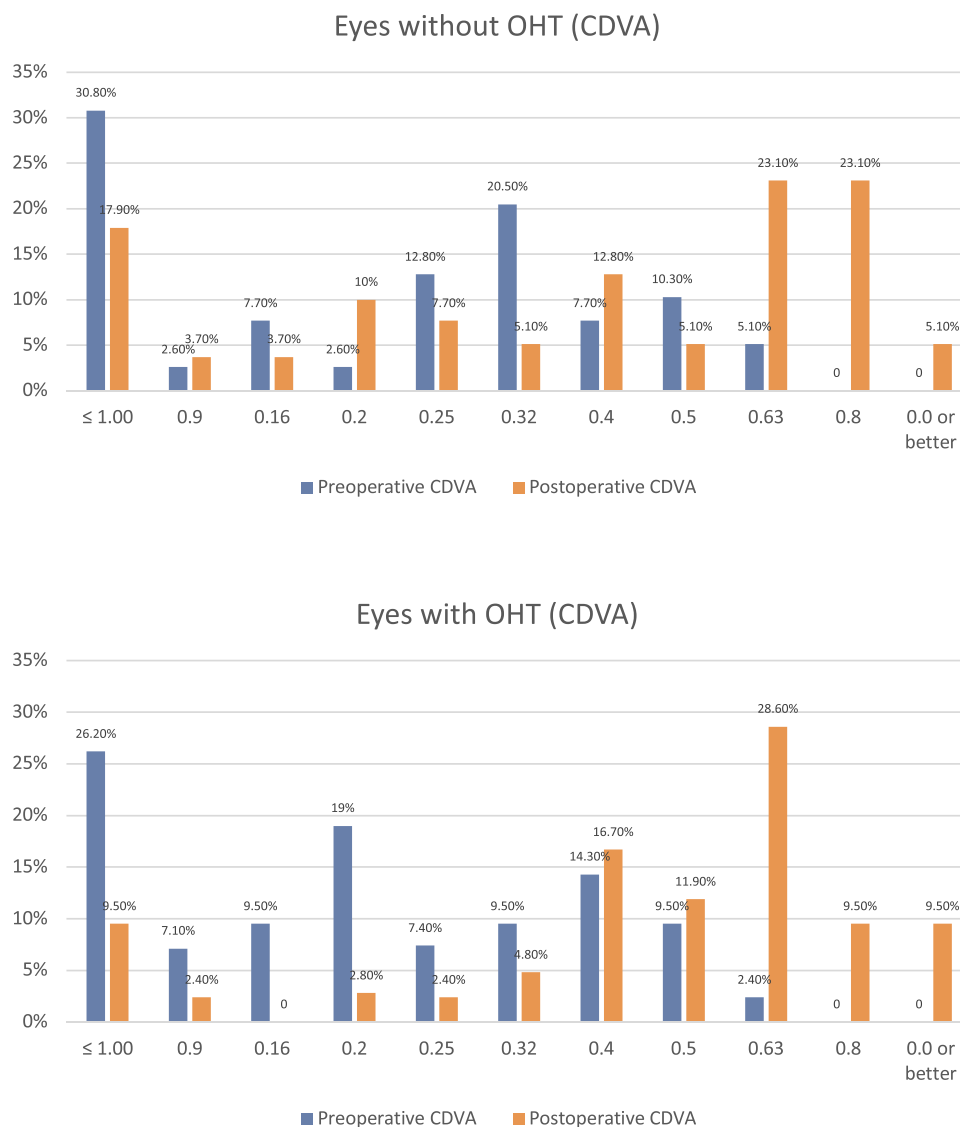


Figure 2 Comparison of distance corrected visual acuity (CDVA) between eyes with and without ocular hypertension (OHT).

procedures, and we did not find age < 60 to be a risk factor of postoperative IOP elevation.

Our results agreed with Ozeki et al²⁴ finding that combined surgery was not associated with OHT after DSAEK, although there was a significant difference between pseudophakic and phakic eyes in IOP elevation after DSAEK ($p=0.024$). On the other hand, another significant risk factor in this study was preoperative IOP > 16 mmHg ($p=0.003$), which had 5.27 times risk of developing OHT after DSAEK. With respect to the time of onset of OHT after DSAEK, we found the average time period of postoperative 6.5 months, comparable to reported literature.¹³

There are a few proposed causes of increased IOP after DSAEK, including the use of topical steroids, retained

viscoelastics, inflammation, peripheral anterior synechiae, iatrogenic damage to trabecular meshwork and distortion of the angle.^{10,23,25} These causes are responsible for IOP elevation at different postoperative time periods; and this study excluded any cases with immediate postoperative IOP elevation, such as pupillary block glaucoma after DSAEK.

In steroid-induced OHT, Francois reported the time of onset was dependent on the potency of corticosteroid drops.²⁶ We found that all eyes with steroid-induced IOP elevation were on the highest potency of steroid drop, Dexamethasone 0.1%, and the earliest onset of IOP elevation was seen within a week. Steroid-induced IOP elevation could normally be controlled by tapering steroids, changing steroids or glaucoma medication,¹⁴ where all

steroid-induced OHT eyes were controlled medically on average of 6.5 months in our work.

Recent studies reported that Loteprednol is less likely to cause IOP elevation than Prednisolone acetate in steroid responders.^{27,28}

The management of steroid-induced OHT can be complicated; it is vital to achieve a balance treatment between inflammation and the use of steroid drops in steroid responders, as inflammation itself is also a risk factor for corneal graft failure.²⁷ There is some evidence which shows that the cessation of steroid drops will help return IOP to normal or baseline level within four weeks' time.^{29,30} Loteprednol have been used as an alternative rather than tapering steroid to manage IOP elevation in steroid responders. It has also been suggested that Loteprednol possesses adequate anti-inflammatory effects when it is used as a second-line therapy for prophylaxis of graft rejection. However, the long-term effects of Loteprednol still remain unknown.²⁷

Uncontrolled IOP increases the risk of poor visual outcomes and is associated with graft failure after PKP and DSAEK.^{17,31} This study showed the overall rate of graft failure to be 7.4%, which is within range of reported rates of failure in other DSAEK studies (4–14% at 3 years).^{13,31} In addition, there was no significant difference in graft failure rates between eyes with or without post-DSAEK glaucoma ($p=0.42$)

Apart from the heterogeneity in cutoff value for IOP, there is a huge variability in the definition of OHT and glaucoma. In 2009, a report from the American Academy of Ophthalmology (AAO) summarized literatures on DSAEK in that year, concluded that incidence of glaucoma after DSAEK varied between 0% to 15% with 3 to 18 months of follow up in 23 studies.^{4,13} This study reports the incidence of post-DSAEK glaucoma to be 13.6%, which is slightly higher than the incidence of 11.9% reported previously.¹⁴

This is a non-randomized study; although we excluded eyes with preexisting glaucoma as a known risk factor for causing IOP elevation after DSAEK, it is possible that some patients with undiagnosed OHT were enrolled in the study. In addition, more participants would make the results more representative. In terms of measuring visual acuity outcome after DSAEK, postoperative UDVA and CDVA were not recorded at fixed time-points which could be useful to compare the trend of changes in visual acuity between eyes with and without postoperative OHT throughout postoperative period. Because of the added thickness of the donor graft, the central corneal thickness after DSAEK would increase

compromising the accuracy of IOP measurements. Clemmensen and associates have demonstrated that this increase in corneal thickness does not affect corneal rigidity and thus bear no relationship with IOP measurements in post DSAEK patients.³² A good correlation when measuring IOPs by three different devices (i Care, Pascal dynamic contour tonometer, GAT) in post DSAEK patients has also been reported.³³

Despite the above limitations, the study is one of the few study to presents both the incidence of OHT and glaucoma after DSAEK and the associated risk factors. Eyes with pre-existing glaucoma and OHT needs close monitoring post DSAEK as they are at higher risk of developing IOP elevation.

Abbreviations

ABK, aphakic bullous keratopathy; AC Tap, anterior chamber tap; CDVA, distance corrected visual acuity; CCT, central corneal thickness; CD ratio, cup-to-disc ratio; DSAEK, Descemet's stripping automated endothelial keratoplasty; FED, Fuchs endothelial dystrophy; IOP, intraocular pressure; OHT, ocular hypertension; PBK, pseudophakic bullous keratopathy; PKP, penetrating keratoplasty; UDVA, uncorrected distance visual acuity.

Ethics Approval and Informed Consent

The study was approved as prospective audit by local institutional review board at Queen Victoria Hospital, East Grinstead, UK and adhered to the Declaration of Helsinki.

All participants provided informed consent for participation in the study.

Author Contributions

All authors made a significant contribution to the work reported, whether that is in the conception, study design, execution, acquisition of data, analysis and interpretation, or in all these areas; took part in drafting, revising or critically reviewing the article; gave final approval of the version to be published; have agreed on the journal to which the article has been submitted; and agree to be accountable for all aspects of the work.

Disclosure

The authors report no conflicts of interest in this work.

References

- Boynton G, Woodward M. Evolving techniques in corneal transplantation. *Curr Surg Rep.* 2015;3(2):2. doi:10.1007/s40137-014-0079-5
- Activity report NHSBT UK. Organ donation and transplantation activity report 2019/2020; 2020. Available from: <https://nhsbt.dbe.blob.core.windows.net/umbraco-assets-corp/19220/activity-report-2019-2020.pdf>. Accessed March 28, 2021.
- Nguyen P, Khashabi S, Chopra V, et al. Descemet stripping with automated endothelial keratoplasty: a comparative study of outcome in patients with preexisting glaucoma. *Saudi J Ophthalmol.* 2013;27(2):73–78. doi:10.1016/j.sjopt.2013.02.002
- Lee WB, Jacobs DS, Musch DC, et al. Descemet's stripping endothelial keratoplasty: safety and outcomes: a report by the American Academy of Ophthalmology. *Ophthalmology.* 2009;116(9):1818–1830. doi:10.1016/j.ophtha.2009.06.021
- Espana EM, Robertson ZM, Huang B. Intraocular pressure changes following Descemet's stripping with endothelial keratoplasty. *Graefes Arch Clin Exp Ophthalmol.* 2010;248(2):237–242. doi:10.1007/s00417-009-1199-y
- Terry MA. Precut tissue for Descemet stripping automated endothelial keratoplasty: complications are from technique, not tissue. *Cornea.* 2008;27(6):627–629. doi:10.1097/01.icc.0000611356.66299.c1
- Terry MA, Shamie N, Chen ES, et al. Endothelial keratoplasty: a simplified technique to minimize graft dislocation, iatrogenic graft failure, and pupillary block. *Ophthalmology.* 2008;115(7):1179–1186. doi:10.1016/j.ophtha.2007.09.005
- Nieuwendaal CP, van der Meulen IJ, Lapid-Gortzak R, Mourits MP. Intraocular pressure after Descemet stripping endothelial keratoplasty (DSEK). *Int Ophthalmol.* 2013;33(2):147–151. doi:10.1007/s10792-012-9665-7
- Erdurmus M, Cohen EJ, Yildiz EH, et al. Steroid-induced intraocular pressure elevation or glaucoma after penetrating keratoplasty in patients with keratoconus or Fuchs dystrophy. *Cornea.* 2009;28(7):759–764. doi:10.1097/ICO.0b013e3181967318
- Huber KK, Maier AK, Klamann MK, et al. Glaucoma in penetrating keratoplasty: risk factors, management and outcome. *Graefes Arch Clin Exp Ophthalmol.* 2013;251(1):105–116. doi:10.1007/s00417-012-2065-x
- Dada T, Aggarwal A, Minudath K, et al. Post-penetrating keratoplasty glaucoma. *Indian J Ophthalmol.* 2008;56(4):269–277. doi:10.4103/0301-4738.41410
- Wilson SE, Kaufman HE. Graft failure after penetrating keratoplasty. *Surv Ophthalmol.* 1990;34:325–356.
- Chan EW, Wong TT, Htoon HM, et al. De novo ocular hypertension after Descemet stripping endothelial keratoplasty: comparative 3-year incidence, risk factors, and outcomes. *Clin Ophthalmol.* 2013;7:1829–1841. doi:10.2147/OPTH.S50584
- Maier AK, Klamann MK, Torun N, et al. Intraocular pressure elevation and post-DSEK glaucoma after Descemet's stripping endothelial keratoplasty. *Graefes Arch Clin Exp Ophthalmol.* 2013;251(4):1191–1198. doi:10.1007/s00417-012-2203-5
- Olson R, Kaufman H. A mathematical description of causative factors and prevention of elevated intraocular pressure after keratoplasty. *Invest Ophthalmol Vis Sci.* 1977;16(12):1085–1092.
- Chien AM, Schmidt CM, Cohen EJ, et al. Glaucoma in the immediate postoperative period after penetrating keratoplasty. *Am J Ophthalmol.* 1993;115(6):711–714. doi:10.1016/S0002-9394(14)73636-0
- Allen MB, Lieu P, Mootha VV, et al. Risk factors for intraocular pressure elevation after Descemet stripping automated endothelial keratoplasty. *Eye Contact Lens.* 2010;36(4):223–227. doi:10.1097/ICL.0b013e3181e6ae30
- Vajaranant TS, Price MO, Price FW, et al. Visual acuity and intraocular pressure after Descemet's stripping endothelial keratoplasty in eyes with and without preexisting glaucoma. *Ophthalmology.* 2009;116(9):1644–1650. doi:10.1016/j.ophtha.2009.05.034
- Sharma RA, Bursztyrn L, Golesic E, et al. Comparison of intra ocular pressures post penetrating keratoplasty vs Descemet's stripping endothelial keratoplasty. *Can J Ophthalmol.* 2016;51(1):19–24. doi:10.1016/j.jcjo.2015.09.014
- Goldberg DB, Schanzlin DJ, Brown SI. Incidence of increased intraocular pressure after keratoplasty. *Am J Ophthalmol.* 1981;92(3):372–377. doi:10.1016/0002-9394(81)90527-4
- Karadag O, Kugu S, Erdogan G, et al. Incidence of and risk factors for increased intraocular pressure after penetrating keratoplasty. *Cornea.* 2010;29(3):278–282. doi:10.1097/ICO.0b013e3181b6eb9e
- Kirkness CM, Ficker LA. Risk factors for the development of post-keratoplasty glaucoma. *Cornea.* 1992;11(5):427–432. doi:10.1097/00003226-199209000-00012
- Al-Mohaimeed M, Al-Shahwan S, Al-Torbak A, Wagoner MD. Escalation of glaucoma therapy after penetrating keratoplasty. *Ophthalmology.* 2007;114(12):2281–2286. doi:10.1016/j.ophtha.2007.08.043
- Ozeki N, Yuki K, Shiba D, et al. Intraocular pressure elevation after Descemet's stripping endothelial keratoplasty. *Jpn J Ophthalmol.* 2012;56(4):307–311. doi:10.1007/s10384-012-0149-0
- Sihota R, Sharma N, Panda A, Aggarwal HC, Singh R. Post-penetrating keratoplasty glaucoma: risk factors, management and visual outcome. *Aust N Z J Ophthalmol.* 1998;26(4):305–309. doi:10.1111/j.1442-9071.1998.tb01334.x
- Francois J. Corticosteroid glaucoma. *Ann Ophthalmol.* 1977;9(9):1075–1080.
- Holland EJ, Djalilian AR, Sanderson JP. Attenuation of ocular hypertension with the use of topical loteprednol etabonate 0.5% in steroid responders after corneal transplantation. *Cornea.* 2009;28(10):1139–1143. doi:10.1097/ICO.0b013e3181a3c52f
- Bartlett JD, Horwitz B, Laibovitz R, Howes JF. Intraocular pressure response to loteprednol etabonate in known steroid responders. *J Ocul Pharmacol.* 1993;9(2):157–165. doi:10.1089/jop.1993.9.157
- Kersey JP, Broadway DC. Corticosteroid-induced glaucoma: a review of the literature. *Eye (Lond).* 2006;20(4):407–416. doi:10.1038/sj.eye.6701895
- Weinreb RN, Polansky JR, Kramer SG, Baxter JD. Acute effects of dexamethasone on intraocular pressure in glaucoma. *Invest Ophthalmol Vis Sci.* 1985;26(2):170–175.
- Ang M, Mehta JS, Lim F, et al. Endothelial cell loss and graft survival after Descemet's stripping automated endothelial keratoplasty and penetrating keratoplasty. *Ophthalmology.* 2012;119(11):2239–2244. doi:10.1016/j.ophtha.2012.06.012
- Clemmensen K, Hjortdal J. Intraocular pressure and corneal biomechanics in Fuch's endothelial dystrophy and after posterior lamellar keratoplasty. *Acta Ophthalmol.* 2014;92(4):350–400. doi:10.1111/aos.12137
- Achiron A, Blumenfeld O, Avizemer H, et al. Intraocular pressure measurement after DSAEK by i care, Goldman applanation and dynamic contour tonometry: A comparative Study. *J Fr Ophthalmol.* 2016;39(10):822–828. doi:10.1016/j.jfo.2016.09.009

Clinical Ophthalmology

Dovepress

Publish your work in this journal

Clinical Ophthalmology is an international, peer-reviewed journal covering all subspecialties within ophthalmology. Key topics include: Optometry; Visual science; Pharmacology and drug therapy in eye diseases; Basic Sciences; Primary and Secondary eye care; Patient Safety and Quality of Care Improvements. This journal is indexed on PubMed

Central and CAS, and is the official journal of The Society of Clinical Ophthalmology (SCO). The manuscript management system is completely online and includes a very quick and fair peer-review system, which is all easy to use. Visit <http://www.dovepress.com/testimonials.php> to read real quotes from published authors.

Submit your manuscript here: <https://www.dovepress.com/clinical-ophthalmology-journal>