

# Proximal Femoral Non-unions with Implant In Situ Treated by Revision Osteosynthesis: A Real Challenge

Anoop Kalia<sup>1</sup>, Jagdeep Singh<sup>2</sup>, Sorabh Garg<sup>2</sup>, Rajdeep Singh<sup>2</sup>

## Learning Point of the Article:

Proximal femoral nonunion with implant failure needs to be managed judiciously and it also discerns the proficiency and skillfulness of operative hands.

## Abstract

**Introduction:** Proximal femur fractures non-union with implant failure creates a nightmare for both the surgeon and the patient. Meticulous surgical planning and the correct choice of the implant are essential to achieve success in the revision surgery.

**Materials and Methods:** Eleven patients with ununited proximal femur fractures including both intertrochanteric and subtrochanteric fractures who had a failed previous implant were included in the study. Femoral neck nonunions and infected nonunions were excluded from the study. One patient was lost to follow-up.

**Results:** One patient was lost to follow-up and out of the remaining ten patients, six were males and four were females. Mean age was 62.2 years (35–74). Union was achieved with mean union time of 10.1 months (9–14). Mean surgical time was 105 min (90–125) and mean blood loss during surgery was 600 ml (350–850). Mean time of revision surgery after the primary index surgery was 20 months (15–30). Mean duration of follow-up was 12.9 months (12–16).

**Conclusion:** Revision osteosynthesis in proximal femoral nonunions with implant failure is a real test of surgeons expertise because of the many factors going against like osteoporosis, distorted proximal femur anatomy due to the already present implant resulting in poor bone stock availability. Judicious and appropriate selection of implants is an impeccable factor for fracture union and positive outcome.

**Keywords:** Non-union, proximal femur, bone graft.

## Introduction

Both extramedullary implants such as dynamic hip screw (DHS), dynamic condylar screw (DCS), proximal femur locking compression plate (PFLCP), and intramedullary implants like proximal femoral nails (PFN) have been used to treat proximal femoral fractures. The proximal femur nail was introduced in 1997 by A.0 [1] to overcome the high complication rate seen when sliding hip screw system was used in unstable pertrochanteric fractures [2]. Enormous literature is available which favors the use of intramedullary device over extramedullary implants in pertrochanteric fractures [3, 4]. Non-union in a proximal femur fracture with associated implant failure creates a technically challenging situation due to the

problem of removal of previous implant, distorted proximal femur anatomy, and osteoporosis resulting in poor bone stock further adding to the surgeons ordeal.

The main objective of our study was to evaluate the clinical and radiological results of patients presenting with proximal femur including subtrochanteric non-unions treated by revision osteosynthesis with bone grafting.

## Materials and Methods

This is prospective cohort study was carried out at tertiary level hospital between January 2017 and June 2018, in which 11 patients were operated by revision osteosynthesis with bone grafting.

Access this article online

Website:  
www.jocr.co.in

DOI:  
10.13107/jocr.2020.v10.i09.1912

## Author's Photo Gallery



Dr. Anoop Kalia



Dr. Jagdeep Singh



Dr. Sorabh Garg



Dr. Rajdeep Singh

<sup>1</sup>Department of Orthopaedics, Max Super Speciality Hospital, Mohali, Punjab, India,

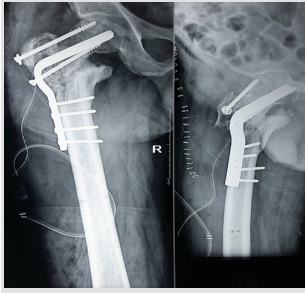
<sup>2</sup>Department of Orthopaedics, Guru Gobind Singh Medical College and Hospital, Faridkot, Punjab, India.

### Address of Correspondence:

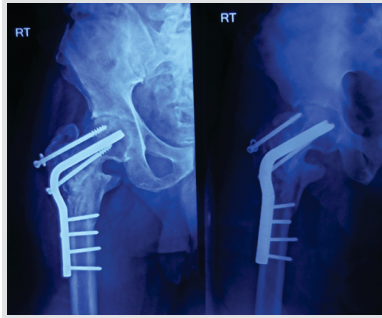Dr. Sorabh Garg,

Department of Orthopaedics, Guru Gobind Singh Medical College and Hospital, Faridkot, Punjab, India.

E-mail: sorgag@gmail.com



**Figure 1:** Immediate post-operative X-ray of case three showing reosteosynthesis by angled blade plate with valgus osteotomy.



**Figure 2:** 12 months follow-up of case three showing solid union.

Inclusion criteria were aseptic proximal femur non-union with implant failure.

Exclusion criteria were femoral neck non unions, peri-prosthetic fractures, and infected non-unions of proximal femur area.

In pre-operative evaluation of patients, infection was ruled out before any definitive procedure. White blood cell count, C-reactive protein, and Erythrocyte Sedimentation Rate were obtained in all cases. A complete metabolic and endocrine profile assessment was done. This included serum Vitamin D levels and serum calcium levels along with thyroid function tests as abnormalities in Vitamin D levels and abnormal thyroid function tests have been shown to delay fracture healing [5]. Pre-operative limb length discrepancy was documented.

After pre-anesthetic clearance, the surgery was carried out in either a supine position with or without fracture table or in lateral decubitus position. Previous broken or failed implants were removed first followed by assessment of proximal femur bone stock and depending on this revision osteosynthesis was performed with angled blade plate (ABP) with valgus osteotomy, reverse distal femur locking plate (DFLP), PFN, and PFLCP. One patient which was lost to follow-up after 4 months also had re-osteosynthesis with PFLCP. Bone graft harvested from iliac crest was done in all cases.

Post-operative radiographs (Fig. 1) were obtained on the 1st post-operative day. The patients were encouraged to do static quadriceps and active assisted/active straight leg raising

exercises once the patient feels comfortable. Patient was made to sit up on the bed side and non-weight bearing walking with the support of walker was started 24 h after the surgery. Patients were discharged from hospital 72–96 h after surgery and stitch removal was done 2 weeks from the day of surgery. Hip abductor strengthening exercises were gradually initiated after 6 weeks.

The patients were followed up for 6 weeks, 3 months, 6 months, and for a minimum period of 12 months. Partial weight bearing was allowed 6–8 weeks after surgery in all the cases when the first signs of union were evident on X-ray and full weight bearing was allowed once there was evidence of complete clinical and radiological union. Radiologically fracture union was defined as continuity of at least three cortices in AP and lateral views without any fracture gap (Fig. 2). Clinically fracture was considered as healed when there was no local tenderness and patient could do full weight bearing without any support.

Once the fracture was healed, patients were encouraged to sit on the floor cross legged and to do squatting as it is an essential part of the routine in Indian population.

## Results

All the patients with proximal femoral nonunions (A2.2–A3.3) including subtrochanteric nonunions were included in the study.

Out of the 11 patients, one patient was lost to follow-up (Fig. 3a, b and c) and out of the remaining ten patients, six were males and four were females.

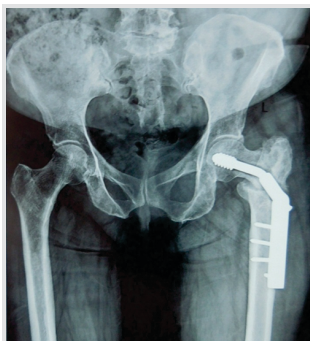Three patients out of the ten patients had associated comorbidities with diabetes mellitus present in two patients, while one patient had recent incident of myocardial ischemia mean age as 62.2 years (range 35–74). All patients had non-union of proximal femoral region with implant in situ.

Revision osteosynthesis was performed with ABP with valgus osteotomy in four cases {two of these patients had failed previous fixation with PFN while two patients had DHS as the previous implant}, reverse DFLP in two cases {one of the them had DHS as the previous implant while other patient had PFN},

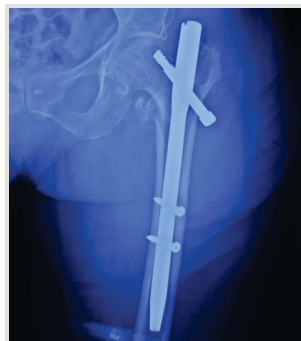
PFN in three cases {two of these patients had DHS as the initial implant while one patient had enders nails}, and PFLCP in one case (fixed initially with DHS).

Mean surgical time was 105 min (range 90–125) and mean blood loss during surgery was 600 ml (range 350–850). Mean time of revision surgery after the primary index surgery was 20 months (range 15–30). Mean duration of follow-up was 12.9 months (range 12–16).

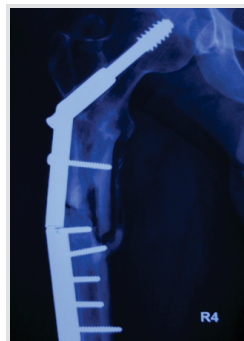Union was achieved with mean union time of



**Figure 3a:** Pre-operative X-ray of case nine demonstrating proximal femoral nonunion with implant failure.

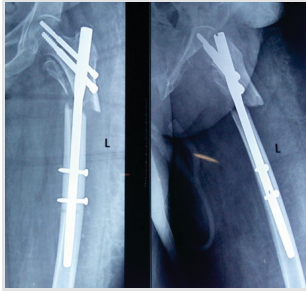


**Figure 3b:** Pre-operative X-ray of case seven showing proximal femoral nonunion with failed proximal femoral nails.

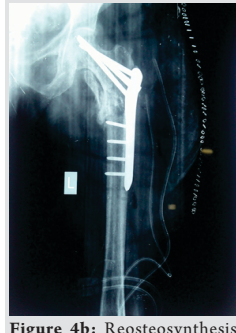

**Figure 3c:** Pre-operative X-ray of case two showing broken DHS with proximal femoral nonunion.

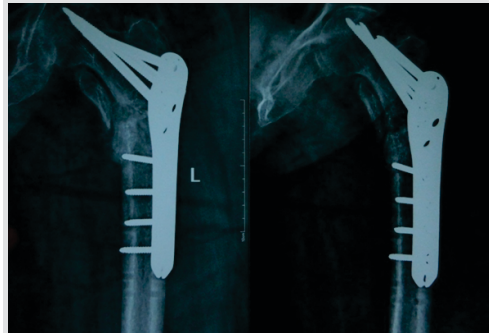




**Figure 4a:** Pre-operative X-ray of nonunion of proximal femoral region with implant in situ.



**Figure 4b:** Reosteosynthesis with PFLCP.



**Figure 4c:** 3 months follow-up with union in progress.

10.1 months (range 9–14) (Fig. 4a, b and c). None of the patients showed implant failure on follow-up X-rays (Fig. 5a, b, c, d).

Mean Harris Hip Score at the final follow-up was 87.8 at the final follow-up. Limb length discrepancy was improved from average 3.42 cm preoperatively to an average 1.32 cm postoperatively.

We did not encounter wound problems in any of our case.

The patient demographics and results are summarized in (Table 1).

**Discussion**

Bimodal presentation is a feature of Pertrochanteric and subtrochanteric fractures. Due to osteoporosis, even low energy impact result in these injuries in elderly patients. On the other hand, a high speed injury can be the cause of such fractures in younger patients [6].

Management of these fractures can be done by various means like:

- Extramedullary implants: DCS, DHS, and ABP.
- Intramedullary implants: PFN has been sued to treat these fractures [7].

There is a high percentage of delayed or non-union cases in subtrochanteric fractures (7–20%), irrespective of the treatment modality followed [8]. Multiple factors have been attributed for the same such as presence of highly osteoporotic

bone, scanty blood supply within the cortical bone and presence of high value of varus at the site of fracture due to weight bearing.

Overall, the intramedullary devices seem to be more advantageous than the extramedullary devices as far as pertrochanteric fractures are concerned. However, it has

certain limitations which can lead to delayed or non-union as well like:

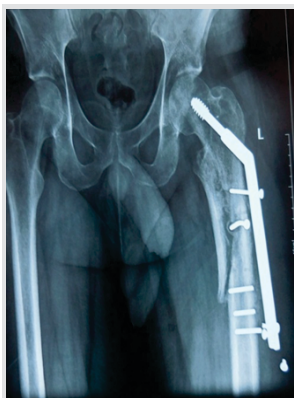- Highly technique sensitive,
- Requires high level of expertise of the surgeon,
- Need for precise reduction of fracture site,
- Need for correct entry and placement of screws.

Gamma nails have shown a failure percentage of 12.7–15% according to some studies [9]. In another study carried out by Uzun et al., it was found that the use of PFN resulted in non-union in 5.7% cases. Moreover, a reoperation had to be carried out in almost 14.3% cases [10]. Even with the use of PFN in cases of unstable femur fractures, a need for reoperation was seen in 4–28% cases by Zhou et al. [11].

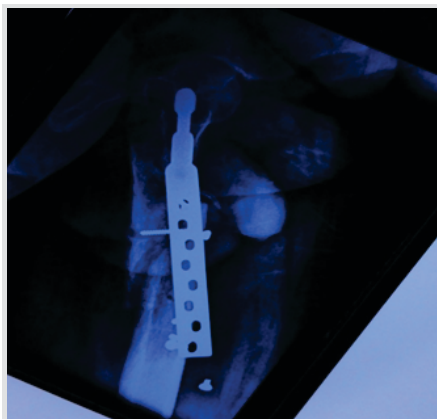
In our study, we encountered three cases of proximal femoral non-union which were initially treated with proximal femoral Such cases of revision osteosynthesis is a tough job due to the entry point and reamed canal track already created by previous intramedullary implant which makes it more challenging to insert a new intramedullary implant with better alignment.

ABP has shown successful results in treatment of non-union subtrochanteric fractures in which the intramedullary nails showed breakage. These observations were seen by Rollo et al. [12].

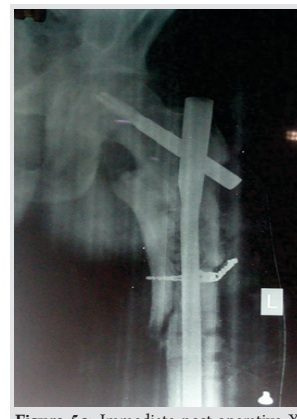A union rate of 93.33% was observed with the use of the double



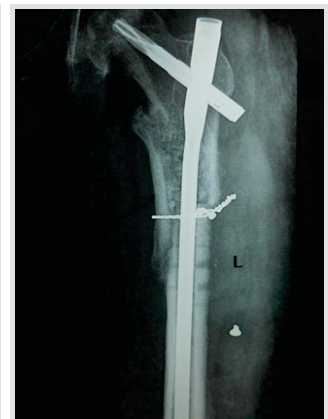**Figure 5a:** Pre-operative AP X-ray of case eight showing subtrochanteric nonunion with implant failure.



**Figure 5b:** Pre-operative lateral X-ray of case eight showing subtrochanteric nonunion with implant failure.



**Figure 5c:** Immediate post-operative X-ray of case eight showing reosteosynthesis long proximal femoral nail.



**Figure 5d:** 1-year follow-up X-ray of case eight showing union.



**Table 1:** Showing detail of all the cases

Case no	Age	Sex	Mean time for reosteosynthesis is (months)	Previous implant	Final implant used	Surgery duration (min)	Blood loss (ml)	Follow-up duration (months)	Union time (months)	Pre op lld (cm)	Post op lld (cm)	Comorbidities	HHS at final follow-up
1	50	M	15	DHS	ReversedFLP	90	600	16	11	3.4	1.2	Nil	92
2	68	F	24	DHS	Long PFN	100	500	14	14	1.5	NIL	Nil	89
3	58	M	30	PFN	ABP	115	850	12	9	4.2	1.8	Diabetes	82
4	72	F	18	ENDERS	Long PFN	105	450	12	9	4.5	2.2	Nil	87
5	74	M	18	DHS	ABP	110	650	14	10	3	1.5	Nil	88
6	70	F	24	PFN	ABP	125	800	12	12	4	1.5	Diabetes	94
7	66	F	16	PFN	Reverse DFLP	100	480	13	9	3.6	1.3	Nil	86
8	35	M	14	DHS	Long PFN	90	550	12	12	1.5	NIL	Nil	92
9	60	M	21	DHS	ABP	120	770	12	8	3.5	1.5	Nil	90
10	69	M	20	DHS	PFLCP	95	350	12	7	5	2.2	M.I	78
Mean	62.2		20			105	600	12.9	10.1	3.42	1.32		87.8

ABP combined with valgusosteotomy in a study conducted on 15 patients by Bartonincek et al. A repeat surgery was indicated in only one patient due to the incidence of a repeat fall which resulted in implant failure. There was an improvement in the average Harris hip score from a pre-operatively value of 73 to a score of 92 after the surgery [13].

Successful results have also been observed to treat proximal femur non-union with reverse DFLP [14, 15].

Raju et al. [14] concluded that cases of non-union due to failed PFN can also be safely managed with DF-LCP implant. Insertion of both the locking and the cortical screws is possible because of the presence of combi holes in its design. Multiple screw purchases can also be achieved on previously distorted proximal femur structure due to earlier failed. The only catch point is to take a lateral radiograph to ascertain the orientation of locking screws holes in accordance with the anatomy of distal femur for placing the screws in the neck.

Reverse DFLCP has been found to act as a savior option in cases of non-union due to failed proximal femur fractures in a study conducted by Sampat et al. [15].

Anatomic PFLCP has been used successfully to treat non-union subtrochanteric cases by Navin et al. [16]. The presence of three locking screws at angle of 95, 120, and 135 degrees in PFLCP has not only allowed increased stability but also reduced the risk of screw cut out to negligible.

We revised six cases of proximal femur fractures which were initially fixed with DHS but ultimately landed in failure and subsequent non-union. Saarenpää et al. reported a reoperation rate of 8.2% with the use of DHS [9].

Studies have found a greater incidence of complications and more revision rates associated with the use of sliding hip screw in petrochanteric fractures in comparison with the intramedullary devices [17].

Irrespective of the implant system used, the most logical treatment for success seems to be fracture reduction, because there is a very short time to a failure of fracture with varus

malalignment on anteroposterior image and more than 20 degrees of angulation on lateral image in contrast with fractures which have been adequately reduced [18].

Lack of a control group and small sample size is one of the limitations of our study so the success achieved using non-conventional implants like reverse distal femur locking compression plate cannot be generalized and further biomechanical studies are required to advocate its routine use in proximal femur non unions

**Conclusion**

Revision osteosynthesis in proximal femoral nonunions with implant failure is a real test of surgeons expertise because of the numerous factors going against like osteoporosis, distorted proximal femur anatomy due to the already present implant resulting in poor bone stock available. A complete infectious and metabolic workup should be carried out. The surgeon must be ready with all available armamentarium to carry out the definitive fixation

**Clinical Message**

Revision osteosynthesis with implant in situ is a tedious work of surgical proficiency and demands prudent and pertinent use of implant for the available bone stock so as to reach a considerate level of rehabilitation and better prognosis.



## References

1. Boldin C, Seibert FJ, Fankhauser F, Peicha G, Grechenig W, Szyszkowitz R. The proximal femoral nail (PFN)--a minimal invasive treatment of unstable proximal femoral fractures: A prospective study of 55 patients with a follow-up of 15 months. *Acta Orthop Scand* 2003;74:53-8.
2. Davis TR, Sher JL, Horsman A, Simpson M, Porter BB, Checketts RG. Intertrochanteric femoral fractures. Mechanical failure after internal fixation. *J Bone Joint Surg Br* 1990;72:26-31.
3. Forward DP, Doro CJ, O'Toole RV, Kim H, Floyd JC, Sciadini MF, et al. A biomechanical comparison of a locking plate, a nail, and a 95° angled blade plate for fixation of subtrochanteric femoral fractures. *J Orthop Trauma* 2012;26:334-40.
4. Parker MJ, Handoll HH. Gamma and other cephalocondylic intramedullary nails versus extramedullary implants for extracapsular hip fractures in adults. *Cochrane Database Syst Rev* 2008;3:CD000093.
5. Brinker MR, O'Connor DP, Monla YT, Earthman TP. Metabolic and endocrine abnormalities in patients with nonunions. *J Orthop Trauma* 2007;21:557-70.
6. Cummings SR, Melton LJ. Epidemiology and outcomes of osteoporotic fractures. *Lancet* 2002;359:1761-7.
7. Tencer AF, Johnson KD, Johnston DW, Gill K. A biomechanical comparison of various methods of stabilization of subtrochanteric fractures of the femur. *J Orthop Res* 1984;2:297-305.
8. De Vries JS, Kloen P, Borens O, Marti RK, Helfet DL. Treatment of subtrochanteric nonunions. *Injury* 2006;37:203-11.
9. Saarenpää I, Heikkinen T, Ristiniemi J, Hyvönen P, Leppilähti J, Jalovaara P. Functional comparison of the dynamic hip screw and the gamma locking nail in trochanteric hip fractures: A matched-pair study of 268 patients. *Int Orthop* 2009;33:255-60.
10. Sehat K, Baker RP, Pattison G, Price R, Harries WJ, Chesser TJ. The use of the long gamma nail in proximal femoral fractures. *Injury* 2005;36:1350-4.
11. Zhou F, Zhang ZS, Yang H, Tian Y, Ji HQ, Guo Y, Lv Y. Less invasive stabilization system (LISS) versus proximal femoral nail anti-rotation (PFNA) in treating proximal femoral fractures: A prospective randomized study. *J Orthop Trauma* 2012;26:155-62.
12. Rollo G, Tartaglia N, Falzarano G, Pichierri P, Stasi A, Medici A, et al. The challenge of non-union in subtrochanteric fractures with breakage of intramedullary nail: Evaluation of outcomes in surgery revision with angled blade plate and allograft bone strut. *Eur J Trauma Emerg Surg* 2017;43:853-61.
13. Bartoníček J, Skála-Rosenbaum J, Dousa P. Valgus intertrochanteric osteotomy for malunion and nonunion of trochanteric fractures. *J Orthop Trauma* 2003;17:606-12.
14. Vaishya R, Agarwal AK, Gupta N, Vijay V. Reversed distal femoral locking plate for failed proximal femoral nail with non-union of proximal femoral fractures. *Int Orthop* 2016;40:1709-15.
15. Dumbre Patil VS, Karkamkar SS, Patil VS, Patil SS, Ranaware AS. Reverse distal femoral locking compression plate a salvage option in nonunion of proximal femoral fractures. *Indian J Orthop* 2016;50:374-8.
16. Balasubramanian N, Babu G, Prakasam S. Treatment of non unions of subtrochanteric fractures using an anatomical proximal femur locked compression plate-a prospective study of 13 patients. *J Orthop Case Rep* 2016;6:65-8.
17. Bretherton CP, Parker MJ. Femoral medialization, fixation failures, and functional outcome in trochanteric hip fractures treated with either a sliding hip screw or an intramedullary nail from within a randomized trial. *J Orthop Trauma* 2016;30:642-6.
18. Tucker A, Warnock M, McDonald S, Cusick L, Foster AP. Fatigue failure of the cephalomedullary nail: Revision options, outcomes and review of the literature. *Eur J Orthop Surg Traumatol* 2018;28:511-20.

**Conflict of Interest:** Nil  
**Source of Support:** Nil

**Consent:** The authors confirm that informed consent was obtained from the patient for publication of this case report

## How to Cite this Article

Kalia A, Singh J, Garg S, Singh R. Proximal Femoral Non-unions with Implant in situ Treated by Revision Osteosynthesis: A Real Challenge. *Journal of Orthopaedic Case Reports* 2020 December;10(9):80-84.

