

CASE REPORT

# Successful surgical excision of a massive symptomatic partially obstructing Brunner's gland hamartoma: a case report

Khortnal Delvecchio\* and Susan Seman

Department of Surgery (Room M5H02), Sinai Grace Hospital, Detroit, MI, USA

\*Correspondence address. Department of Surgery (Room M5H02), Sinai Grace Hospital, 6071 W. Outer Drive, Detroit, MI 48235, USA. Tel: +1-248-790-6442; Fax: +1-313-966-4204; E-mail: khortnal@gmail.com

## Abstract

Brunner gland function within the duodenal epithelium is secretion of alkaline mucin to counteract acidic chyme. These glands may grow beyond the duodenal wall to become hamartomas. Rarely, they become large enough to cause obstructive symptoms in the upper gastrointestinal tract. We report a case of one of the largest lesions identified in the literature causing obstruction symptoms. A previously asymptomatic 65-year-old gentleman presented to the emergency department with a single-day history of colicky abdominal pain, cramping and vomiting. After initial imaging with computed tomography was inconclusive, a subsequent esophagogastroduodenoscopy with biopsy and small bowel series was performed indicating a pedunculated polypoid mass. Our patient underwent an uncomplicated exploratory laparotomy with duodenotomy and Heineke-Mikulicz pyloroplasty for resection of a massive Brunner's gland hamartoma. For similar presentations, we recommend this technique.

## INTRODUCTION

Initially described by Johann Brunner in 1688, the eponymous Brunner glands are branched acinotubular structures specific to the duodenal submucosa [1]. They secrete an alkaline fluid of mucin as well as pepsinogen and urogastrone protecting the epithelium from and inhibiting secretion of gastric chyme, respectively [1–3]. Rarely, these glands grow beyond the duodenal wall, becoming hamartomas, leading to obstruction, ulceration or intussusception [4]. The majority, however, are asymptomatic and incidentally discovered, thus do not require treatment [4]. In addition, a significant relationship has been established with these lesions and *Helicobacter pylori* in the literature, and consequently one prevailing hypothesis to their development reflects an inflammatory response from associated hyperchlorhydria [1, 5].

Brunner's gland hamartomas are relatively rare, found in <1 in 10 000 individuals and roughly 5% of all duodenal tumors [6].

They are most prevalent in the fifth and sixth decades and represent the genders and races equally [2, 3, 5]. Seventy percent are located in the duodenal bulb, and they become smaller and fewer distally [2, 6]. Due to their average size of 1–2 cm, the majority are asymptomatic and thus discovered on endoscopy or imaging; however, when over 2 cm they may obstruct [2, 3, 7, 8]. Since first reported, around 200 cases have been reported in the literature with only a handful measuring over 5 cm, the largest being 12 × 10 × 8 cm [7, 9]. The vast majority of these lesions are benign, with few reports citing malignant features, thus resection should be performed for definitive diagnosis [2, 10].

## CASE REPORT

A 65-year-old African-American male presented to the emergency department with a 1-day history of 10/10 colicky,

Received: September 29, 2016. Accepted: November 15, 2016

Published by Oxford University Press and JSCR Publishing Ltd. All rights reserved. © The Author 2016.

This is an Open Access article distributed under the terms of the Creative Commons Attribution Non-Commercial License (<http://creativecommons.org/licenses/by-nc/4.0/>), which permits non-commercial re-use, distribution, and reproduction in any medium, provided the original work is properly cited. For commercial re-use, please contact [journals.permissions@oup.com](mailto:journals.permissions@oup.com)

generalized upper abdominal pain and cramping that forced him into the fetal position after eating sausage and eggs. He admitted to nausea with dry-heaving and denied changes in bowel function or any alleviating factors. His examination consisted of stable vital signs and was devoid of abdominal pain or tenderness.

The patient's histories consist of suprapubic prostatectomy 12 years prior for cancer, tobacco abuse with cessation 40 years prior, social alcohol use and a family history of diabetes. He denied medications, allergies or previous esophagogastroduodenoscopy (EGD) or colonoscopy. Laboratory values indicated a leukocytosis of  $14.3 \times 10^9/l$  with a left shift and normal lipase and liver function studies. The patient had no signs or symptoms of anemia and his hemoglobin was 134 g/l and mean corpuscular volume was  $88.7 \mu m^3$ . Computed tomography (CT) showed dilation within the duodenal lumen described as the 'wind-sock' sign (Figs 1 and 2), possibly representing an intraluminal diverticulum with proximal duodenal and gastric dilation. There was also dilation of the common bile duct (CBD) to 1 cm, which tapered to 1 mm at the ampulla, as well as a 6 mm pancreatic ductal dilation.

Upon admission, he underwent an EGD showing a large, partially obstructing postpyloric mass, which the endoscope was able

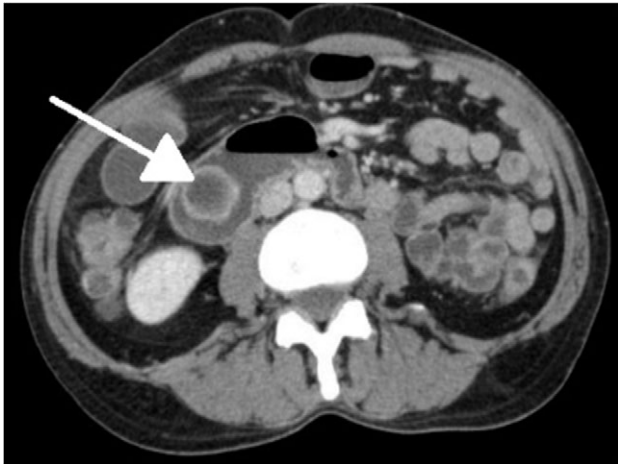


Figure 1: CT imaging showing 'wind-sock' sign (transverse cut).

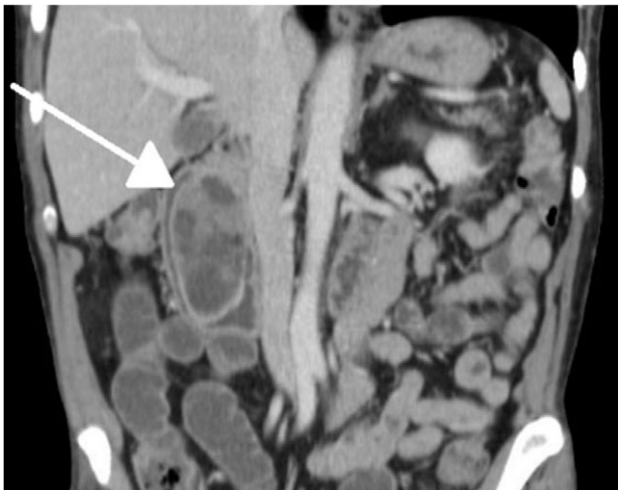

Figure 2: CT imaging showing 'wind-sock' sign (coronal cut).

to pass (Fig. 3). Biopsy results showed gastric mucosa with features consistent with a hyperplastic polyp. Subsequently, the patient underwent a small bowel series, which showed a  $10 \times 4$  cm smooth, pedunculated polypoid mass arising from the submucosa causing local dilatation without obstruction (Figs 4 and 5).

On hospital day 7, the patient underwent an exploratory laparotomy with duodenotomy and excision of the mass via 60 mm Endo GIA stapler, followed by a Heineke-Mikulicz pyloroplasty and EGD. Frozen biopsy excluded malignancy and definitive diagnosis identified an  $8.5 \times 3 \times 2.8$  cm Brunner's gland hyperplasia with gastric pyloric type heterotopia and hyperplasia, consistent with Brunner's Gland Hamartoma. Its size of over 8 cm makes it one of the largest described in the literature (Fig. 6).

On postoperative day (POD) 1, the patient had one episode of emesis after premature self removal of nasogastric tube (NGT) and after reinsertion there were no other significant complications. The patient passed flatus on POD 3 and reported bowel movements on POD 4 coinciding with NGT removal. He tolerated diet advances until discharge on POD 6.

## DISCUSSION

Limitations to our workup include failing to test for *H. pylori* or excessive gastric acid secretion, which has been linked to over

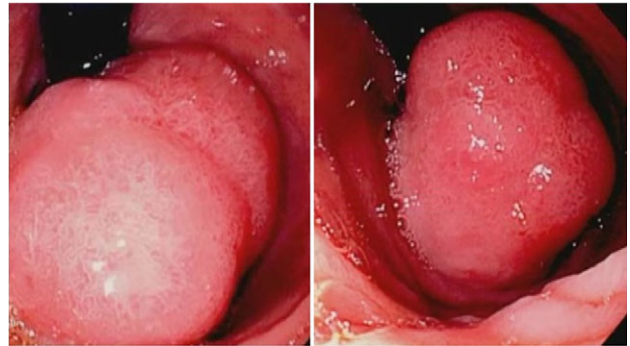


Figure 3: Retroflexed endoscopic view of hamartoma.

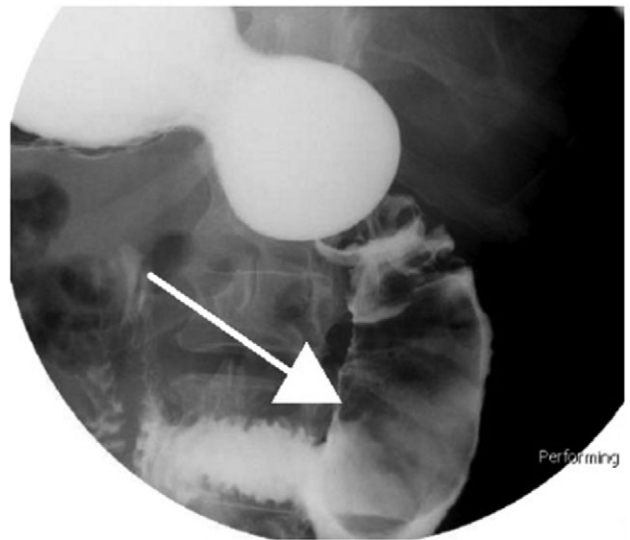


Figure 4: Small bowel series showing duodenal filling defect (posterior view).

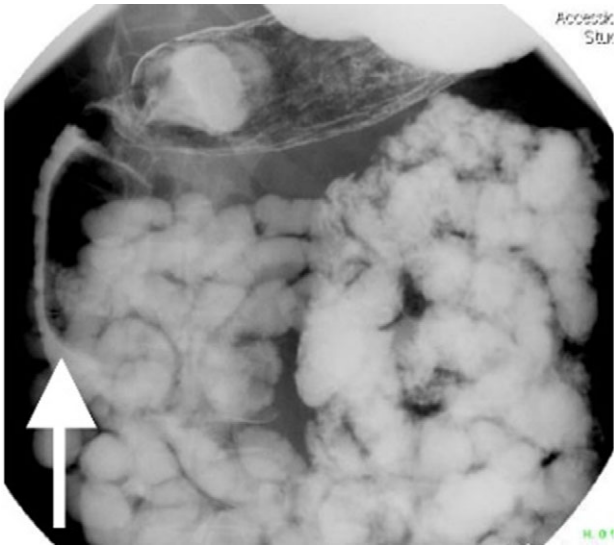


Figure 5: Small bowel series showing duodenal filling defect (anterior view).

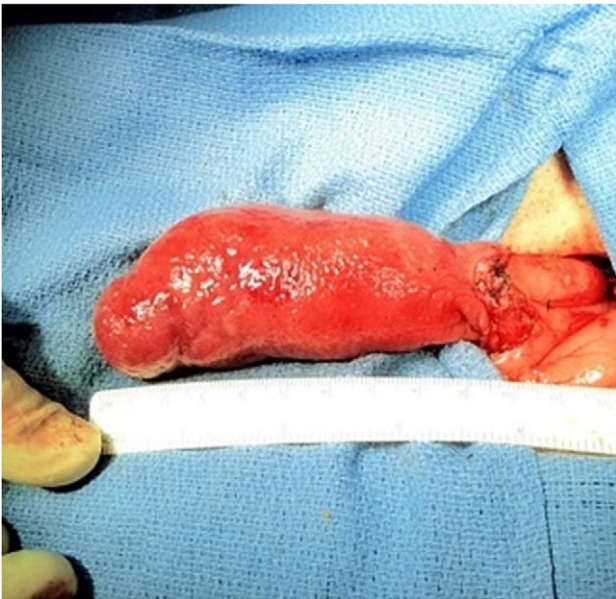

Figure 6: Resected hamartoma gross specimen.

70% of lesions [1, 9]. Although treating *H. pylori* has not demonstrated lesion regression or recurrence in the literature, anecdotal evidence points toward this logic [1]. In addition, although our patient's CT scan did indicate dilatation of the pancreatic duct as well as the CBD, we did not draw bilirubins, which could have pointed toward biliary obstruction, recurrent pancreatitis and/or biliary fistula that occasionally manifests [3, 7, 9].

With regard to diagnostic workup, the literature has described cases with similar results to ours. Small bowel contrast studies frequently show smooth-walled polypoid filling defects within the duodenal bulb, and CT imaging is useful for delineation of adjacent structures including the common duct

and pancreas [1]. Moreover, similar to the pathological results found in our patient, upper endoscopy biopsies are often equivocal as they are submucosal-based lesions [1]. The most useful diagnostic study, however, is endoscopic ultrasound, which may help distinguish the consistency and bowel layer of origin [2, 6], which unfortunately was not available at our institution.

Massive Brunner's gland hamartomas have rarely been described in the literature and even rarer are they diagnosed after only a single day of symptoms. Moreover, our case of a 'giant' hamartoma is significant as one of only a few larger than 5 cm ever described. Considering typical lesions tend to be smaller, endoscopic surgical excision is preferred for reduced morbidity and length of stay. In fact, recent literature has described successful snare cautery of lesions up to 5 cm, or via piecemeal if too difficult [1, 3, 4]. Laparotomy with duodenectomy, however, is preferred over endoscopic methods for massive lesions, those with refractory bleeding, complete obstruction or if there is concern for malignancy (9). This leads to the suggestion of possible future randomized studies featuring outcomes of endoscopic versus open surgical excision of these masses.

## CONFLICT OF INTEREST STATEMENT

None declared.

## REFERENCES

1. Abbass R, Al-Kawas FH. Brunner gland hamartoma. *Gastroenterol Hepatol* 2008;4:473-5.
2. de Nes LC, Ouwehand F, Peters SH, Boom MJ. A large Brunner's gland hamartoma causing gastrointestinal bleeding and obstruction. *Dig Surg* 2007;24:450-2.
3. Gokhale U, Pillai GR. Large Brunner's gland hamartoma: a case report. *Oman Med J* 2009;24:41-3.
4. Jung Y, Chung IK, Lee TH, Cho YS, Jo YG, Park SH, et al. Successful endoscopic resection of large pedunculated Brunner's gland hamartoma causing gastrointestinal bleeding arising from the pylorus. *Case Rep Gastroenterol* 2013;7:304-7.
5. Kurella RR, Ancha HR, Hussain S, Lightfoot SA, Harty R. Evolution of Brunner gland hamartoma associated with *Helicobacter pylori* infection. *South Med J* 2008;101:648-50.
6. Mumtaz R, Shah IA, Ramirez FC. Brunner's gland hamartoma simulating a pancreatic mass with duodenal obstruction. *Gastrointest Endosc* 2002;56:932-4.
7. Petersen JM, Felger TS, Goldstein JD. Gastroduodenal intussusception secondary to a giant brunner gland hamartoma. *Gastroenterol Hepatol* 2008;4:471-3.
8. Rocco A, Borriello P, Compare D, De Colibus P, Pica L, Iacono A, et al. Large Brunner's gland adenoma: case report and literature review. *World J Gastroenterol* 2006;12:1966-8.
9. Yadav D, Herten H, Pitchumoni CS. A giant Brunner's gland adenoma presenting as gastrointestinal hemorrhage. *J Clin Gastroenterol* 2001;32:448-50.
10. Zangara J, Kushner H, Drachenberg C, Daly B, Flowers J, Fantry G. Iron deficiency anemia due to a Brunner's gland hamartoma. *J Clin Gastroenterol* 1998;27:353-6.