



# Assessment of normal anal sphincter anatomy using transanal ultrasonography in healthy Korean volunteers: a retrospective observational study

Daeho Shon<sup>1</sup>, Sohyun Kim<sup>2</sup>, Sung Il Kang<sup>2</sup>

<sup>1</sup>Hwanggeumbit Surgery Clinic, Daegu, Korea

<sup>2</sup>Department of Surgery, Yeungnam University College of Medicine, Daegu, Korea

**Background:** To date, there have been no studies on the normal anatomic values of the anal sphincter in healthy Koreans. Therefore, this study aimed to determine the normal anatomic values of transanal ultrasonography (TAUS).

**Methods:** The thickness of the external anal sphincter (EAS) and internal anal sphincter (IAS) was measured by TAUS from healthy Korean volunteers between September 2019 and August 2021.

**Results:** Thirty-six volunteers with a median age of 37 years (range, 20–77 years) and a median body mass index (BMI) of 23.5 kg/m<sup>2</sup> (range, 17.2–31.2 kg/m<sup>2</sup>) were examined. The median thickness of the EAS at 4 cm and 2 cm from the anal verge was 7.4 mm (range, 5.8–8.8 mm) and 6.5 mm (range, 5.6–8.0 mm), respectively. The median thickness of the IAS at 2 cm from the anal verge was 1.8 mm (range, 0.8–4.3 mm). There were no differences in sphincter muscle thickness between the sexes. However, the EAS tended to thicken as the BMI increased (EAS at 2 cm and 4 cm from the anal verge, Spearman rho = 0.433, 0.363;  $p=0.008$  and  $p=0.029$ , respectively).

**Conclusion:** In healthy Korean, the median thickness of the IAS at 2 cm from the anal verge was 1.8 mm and the median thickness of the EAS at 2 cm and 4 cm from the anal verge was 6.5 mm and 7.4 mm respectively. There were no differences in anal sphincter thickness between sexes, but BMI was related to EAS thickness.

**Keywords:** Anal canal; Anal sphincter; Anus; Ultrasonography

## Introduction

According to data from the Korean Statistical Information Service, 183,908 patients underwent hemorrhoidectomy in Korea in 2019, ranking it the third most frequent surgery [1]. As such, a representative and essential test for diagnosing anal disease, which is one of the most frequent diseases, is transanal ultrasonography (TAUS). TAUS is a useful test for examining the anatomical structure of the anus [2,3]. The advantage of TAUS is that it has no risk of radiation exposure and is less expensive than magnetic resonance imag-

ing (MRI). In addition, TAUS can be easily performed in outpatient clinics.

Anatomical deterioration, such as anal fistulas, abscesses, and sphincter defects, can be easily detected on TAUS by ultrasound-skilled clinicians [4]. In contrast, most diseases, such as fecal incontinence, constipation, or simple hemorrhoids, show no anatomical deterioration on TAUS. However, the absence of anatomical deterioration on TAUS does not indicate a normal finding. This is because the thickness of the sphincter and the degree of ultrasound shadowing may appear differently depending on the pa-

Received: September 27, 2021 • Revised: November 2, 2021 • Accepted: November 4, 2021

Corresponding author: Sung Il Kang, MD

Department of Surgery, Yeungnam University College of Medicine, 170 Hyeonchung-ro, Nam-gu, Daegu 42415, Korea

Tel: +82-53-620-3580 • Fax: +82-53-624-1214 • E-mail: [sungiry@naver.com](mailto:sungiry@naver.com)

Copyright © 2022 Yeungnam University College of Medicine, Yeungnam University Institute of Medical Science

This is an Open Access article distributed under the terms of the Creative Commons Attribution Non-Commercial License (<http://creativecommons.org/licenses/by-nc/4.0/>) which permits unrestricted non-commercial use, distribution, and reproduction in any medium, provided the original work is properly cited.

tient's age, sex, past history, or degree of symptoms.

Indeed, according to previous studies conducted in Western countries, the thickness of the internal sphincter is measured differently according to age, and there is a difference in the length of the anal canal and thickness of the external sphincter according to sex [4-6]. In addition, the results may vary depending on the observer [5-7].

However, until now, there have been no studies on the normal anatomic value of the anal sphincter on TAUS in Koreans with no anal disease or symptoms. Therefore, research is needed to establish normal anatomic values for TAUS in healthy Koreans. The purpose of this study was to determine those normal values.

## Methods

**Ethical statements:** This study was approved by the Institutional Review Board (IRB) of Yeungnam University Hospital (IRB No: 2019-09-062-008) and all the subjects included in this study provided written informed consent.

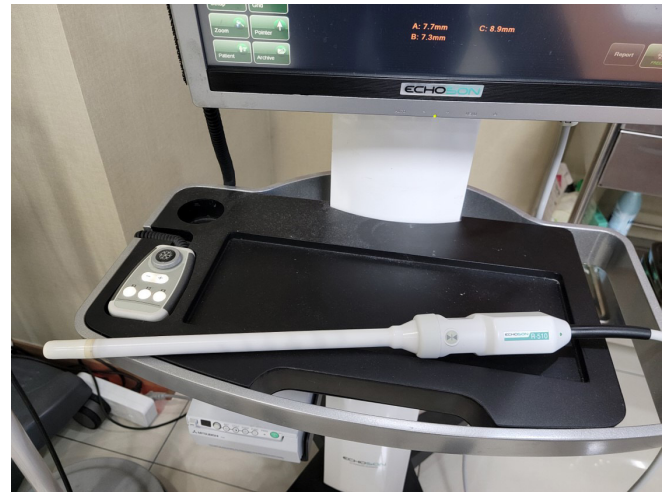This prospective study was conducted in a tertiary medical center and local colorectal clinic in Daegu, Korea between September 2019 and August 2021.

Healthy Korean adult volunteers who had no anal disease and symptoms were recruited through research subject recruitment notices on bulletin boards in hospitals, subways, and buses. The inclusion criteria were as follows: (1) age of  $\geq 20$  years, (2) no anorectal symptoms, (3) Wexner score of  $\leq 2$ , and (4) no anorectal surgical history. The applicant's participation in the study was finally decided through an interview and physical examination with the researcher. If asymptomatic anatomical deterioration was found

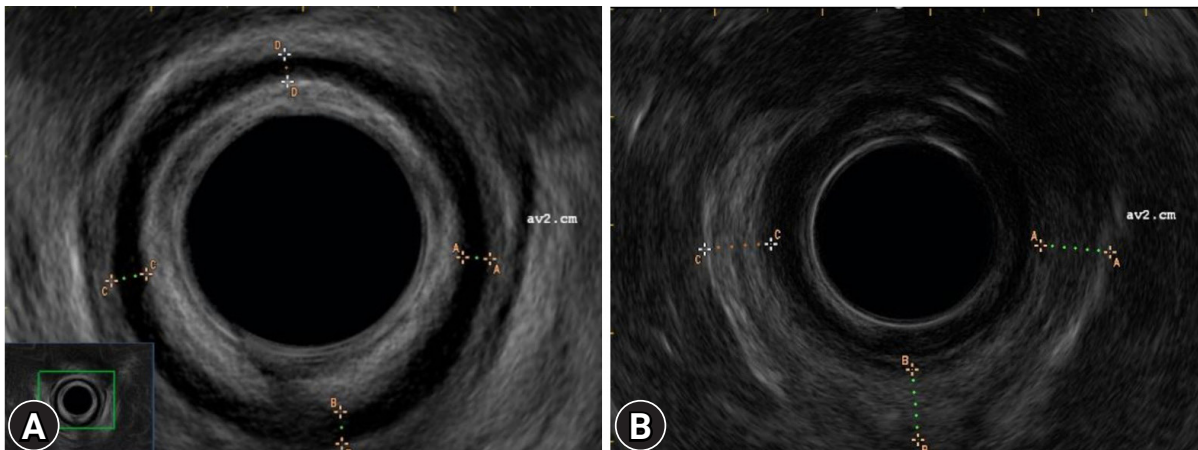
during TAUS, the subject was excluded from the study.

TAUS was performed using an endorectal probe (ALBIT ultrasound scanner, anorectal rotating 360, R510; ECHO-SON, Ltd., Pulawy, Poland) at a frequency of 7.5 and 12 MHz by an experienced colorectal surgeon (DS) (Fig. 1). An enema or bowel preparation drug was not administered prior to TAUS. The subject lay in the left lateral position, and serial radial images were acquired throughout the anal canal. The thickness of the internal anal sphincter (IAS) was measured in the direction of 12 o'clock (anterior), 3 o'clock (left lateral), 6 o'clock (posterior), and 9 o'clock (right lateral) at 2 cm from the anal verge (Fig. 2A). The thickness of the external anal sphincter (EAS) was measured in the direction of 3 o'clock (left lateral), 6 o'clock (posterior), and 9 o'clock (right lateral) at 2 cm and 4 cm from the anal verge (Fig. 2B).

Non-normally distributed data, presented as median (range),



**Fig. 1.** Endorectal probe (ALBIT ultrasound scanner, anorectal rotating 360, R510; ECHO-SON, Ltd., Pulawy, Poland).



**Fig. 2.** (A) Internal anal sphincter and (B) external anal sphincter on transanal ultrasonography imaging.

were analyzed using the Mann-Whitney *U*-test. Correlations between variables were analyzed using Spearman rank correlation test. Statistical significance was set at *p*-value of < 0.05. Statistical analyses were performed using IBM SPSS ver. 22.0 (IBM Corp., Armonk, NY, USA).

## Results

Thirty-six volunteers were examined for anal anatomy using TAUS. The median age of the subjects was 37 years (range, 20–77 years) and the median body mass index (BMI) was 23.5 kg/m<sup>2</sup> (range, 17.2–31.2 kg/m<sup>2</sup>). Nineteen patients (52.8%) were male. The age distribution was 21 to 30 years (7 individuals, 19.4%), 31 to 40 years (14 individuals, 38.9%), 41 to 50 years (5 individuals, 13.9%), 51 to 60 years (5 individuals, 13.9%), 61 to 70 years (4 individuals, 11.1%), and 71 to 80 years (1 individual, 2.8%). The de-

mographic characteristics of the study participants are presented in Table 1.

The median thickness of the EAS at 4 cm and 2 cm from the anal verge was 7.4 mm (range, 5.8–8.8 mm) and 6.5 mm (range, 5.6–8.0 mm), respectively. The median thickness of the IAS at 2 cm from the anal verge was 1.8 mm (range, 0.8–4.3 mm).

There were no differences in sphincter muscle thicknesses between male and female patients (Table 2, Fig. 3). However, the EAS tended to thicken as the BMI increased (EAS at 2 cm and 4 cm from the anal verge, Spearman rho = 0.433 and 0.363; *p* = 0.008 and 0.029, respectively) (Fig. 4).

## Discussion

In this study, we report a normal value of anal sphincter thickness in healthy Koreans as measured by TAUS. TAUS is the most frequently used examination for detecting anorectal anatomical variants because it can easily be performed in outpatient clinics without radiation exposure. Only a few studies have described the normal value of anal sphincter thickness in healthy adults [5,6,8,9]. However, all these studies were conducted in Western countries, and there have been no studies on healthy Asian or Korean volunteers.

In our study, the median IAS thickness at 2 cm from the anal verge was 1.8 mm. This is consistent with the results of previous studies conducted in Western countries (2 mm; range, 1–3 mm) [9]. Although the median value in our study was thinner than that in the cited study, this difference was not considered meaningful because of the measurement error and range.

The median EAS thickness in our study was 6.5 mm (range,

**Table 1.** Demographics of the study sample

Characteristic	Data
Age (yr)	37 (20–77)
20–30	7 (19.4)
31–40	14 (38.9)
41–50	5 (13.9)
51–60	5 (13.9)
61–70	4 (11.1)
71–80	1 (2.8)
Sex, male:female	19:17
Body mass index (kg/m <sup>2</sup> )	23.5 (17.2–31.2)
Wexner score	0 (0–2)

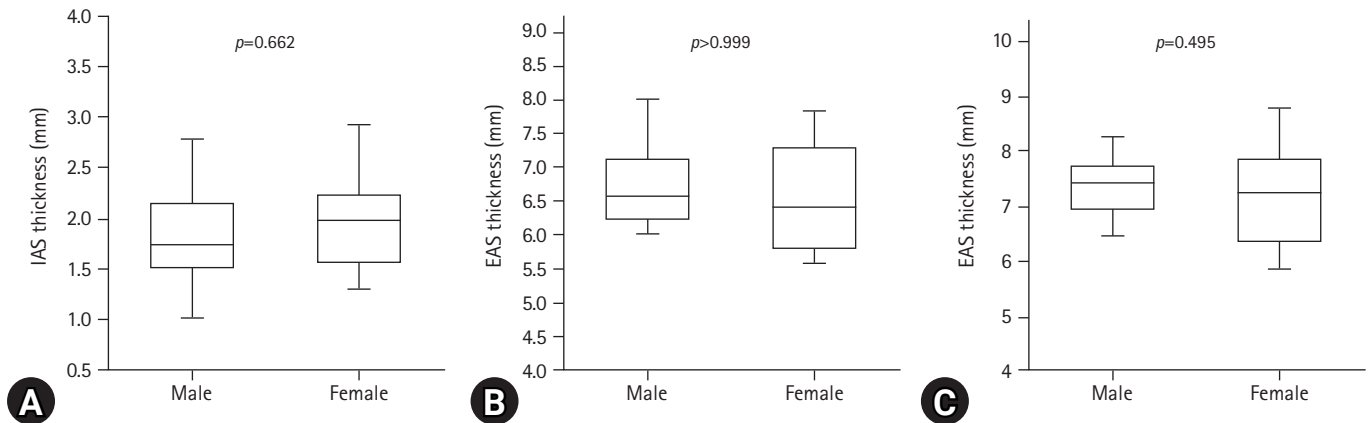
Values are presented as median (range), number (%), or number only.

**Table 2.** Transanal ultrasonographic findings between males and females

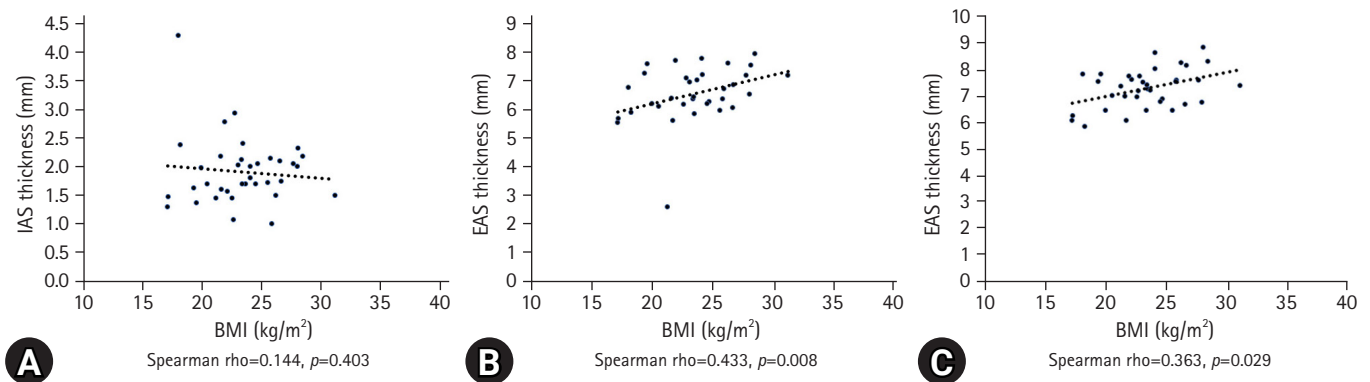
Variable	Male	Female	<i>p</i> -value
IAS thickness, 2 cm from anal verge (mm)	1.7 (0.8–4.3)	2.0 (1.0–3.4)	0.622
Anterior	2.8 (0.7–4.3)	2.1 (1.3–3.4)	0.131
Left lateral	1.9 (1.2–3.2)	1.9 (1.1–2.9)	0.645
Posterior	1.7 (0.8–3.8)	1.6 (1.0–2.6)	0.726
Right lateral	1.9 (0.8–4.3)	1.9 (1.2–2.8)	0.849
EAS thickness, 2 cm from anal verge (mm)	6.5 (5.9–8.0)	6.4 (5.6–7.8)	>0.999
Left lateral	6.7 (5.9–8.4)	6.4 (5.7–7.7)	0.459
Posterior	6.6 (6.0–7.7)	6.5 (5.6–7.8)	0.822
Right lateral	6.8 (5.9–8.0)	6.4 (5.8–7.6)	0.388
EAS thickness, 4 cm from anal verge (mm)	7.4 (6.2–8.4)	7.2 (5.8–8.8)	0.495
Left lateral	7.5 (6.2–8.4)	7.2 (5.8–8.6)	0.469
Posterior	7.1 (6.3–8.2)	7.2 (5.8–8.8)	0.822
Right lateral	7.5 (6.4–8.4)	7.4 (6.0–8.8)	0.388

Values are presented as median (range).

EAS, external anal sphincter; IAS, internal anal sphincter.



**Fig. 3.** Distribution plot by sex. (A) Internal anal sphincter (IAS) 2 cm from anal verge. (B) External anal sphincter (EAS) 2 cm from anal verge. (C) EAS 4 cm from anal verge.



**Fig. 4.** Scatter plots by body mass index (BMI). (A) Internal anal sphincter (IAS) 2 cm from anal verge. (B) External anal sphincter (EAS) 2 cm from anal verge. (C) EAS 4 cm from anal verge.

5.9–8.0 mm) at 2 cm from the anal verge. This is also consistent with the results of a previous study (6 mm; range, 5–8 mm) [9]. Unlike in the cited study, we also described the thickness of the EAS at the upper part of the anal canal (4 cm from the anal verge). The median EAS thickness of the upper anal canal was greater than that of the mid-anal cannula, although the difference was not statistically significant.

In the present study, no relationship was found between sex and sphincter thickness. This result is also consistent with that of a previous study [5]. However, interestingly, BMI correlated with EAS thickness in our study. The higher the BMI, the thicker the EAS was; however, IAS thickness was not correlated with BMI. A previous report revealed that BMI was not correlated with IAS thickness on MRI [10]. However, the investigators did not examine EAS thickness in that study. Another study revealed that BMI was correlated with IAS and EAS thickness [11]. However, the BMI correlation differed according to the measuring level of the anal canal. Interestingly, the investigators revealed that BMI was negative-

ly correlated with EAS thickness, which was the opposite of our result. However, as the previous study was conducted with only females and our study was conducted with a small sample size, further studies are needed to clarify the correlation between BMI and anal sphincter thickness.

Our study has some limitations. First, the sample size was small. More than 80 participants were recruited at the beginning of the study. However, it was challenging to recruit healthy volunteers due to the outbreak of coronavirus disease 2019 at the beginning of the study. Therefore, the final sample size for this study was smaller than originally intended. Second, due to the small number of samples, we could not investigate the relationship between age and sphincter thickness. Third, we did not describe sphincter tone, which is possibly related to the thickness of the anal sphincter muscle. However, previous studies have reported no correlation between sphincter thickness and anal canal pressure [7]. Fourth, we could not measure the length of the anal sphincter muscle because of the limitations of the two-dimensional scope. Nevertheless, we



believe that this study is meaningful as the first study to elucidate normal TAUS values in healthy Koreans.

In this study, in healthy Korean volunteers, the median thickness of the IAS 2 cm from the anal verge was 1.8 mm, and the median thickness of the EAS at 2 cm and 4 cm from the anal verge was 6.5 mm and 7.4 mm, respectively, as measured by TAUS. There were no differences in anal sphincter thickness between sexes, but BMI was related to anal sphincter thickness. Further large-scale studies are required to confirm the results.

## Notes

### Conflicts of interest

No potential conflict of interest relevant to this article was reported.

### Funding

This work was supported by a National Research Foundation of Korea (NRF) grant funded by the Korean government (MSIT) (No. 2019R1G1A1097554).

### Author contributions

Conceptualization, Investigation, Data curation, Formal analysis, Funding acquisition, Methodology, Visualization, Supervision: all authors; Project administration, Resources, Software: SIK; Writing-original draft: DS, SIK; Writing-review & editing: all authors.

### ORCID

Daeho Shon, <https://orcid.org/0000-0003-0514-2537>

Sohyun Kim, <https://orcid.org/0000-0002-8625-329X>

Sung Il Kang, <https://orcid.org/0000-0002-4751-5779>

## References

1. National Health Insurance Service (NHIS). Main surgery statistical yearbook for 2019 [Internet]. Wonju: NHIS; 2020 [cited 2021 Sep 14]. <https://www.nhis.or.kr/nhis/together/wbhaec06800m01.do?mode=view&articleNo=10803657&article.offset=0&articleLimit=10>.
2. Volløyhaug I, Taithongchai A, Arendsen L, van Gruting I, Sultan AH, Thakar R. Is endoanal, introital or transperineal ultrasound diagnosis of sphincter defects more strongly associated with anal incontinence? *Int Urogynecol J* 2020;31:1471–8.
3. Walsh KA, Grivell RM. Use of endoanal ultrasound for reducing the risk of complications related to anal sphincter injury after vaginal birth. *Cochrane Database Syst Rev* 2015;2015:CD010826.
4. Visscher AP, Felt-Bersma RJ. Endoanal ultrasound in perianal fistulae and abscesses. *Ultrasound Q* 2015;31:130–7.
5. Burnett SJ, Bartram CI. Endosonographic variations in the normal internal anal sphincter. *Int J Colorectal Dis* 1991;6:2–4.
6. Nielsen MB, Hauge C, Rasmussen OO, Sørensen M, Pedersen JF, Christiansen J. Anal sphincter size measured by endosonography in healthy volunteers. Effect of age, sex, and parity. *Acta Radiol* 1992;33:453–6.
7. Enck P, Heyer T, Gantke B, Schmidt WU, Schäfer R, Frieling T, et al. How reproducible are measures of the anal sphincter muscle diameter by endoanal ultrasound? *Am J Gastroenterol* 1997;92:293–6.
8. Law PJ, Bartram CI. Anal endosonography: technique and normal anatomy. *Gastrointest Radiol* 1989;14:349–53.
9. Nielsen MB, Pedersen JF, Hauge C, Rasmussen OO, Christiansen J. Endosonography of the anal sphincter: findings in healthy volunteers. *AJR Am J Roentgenol* 1991;157:1199–202.
10. Huebner M, Margulies RU, Fenner DE, Ashton-Miller JA, Bitar KN, DeLancey JO. Age effects on internal anal sphincter thickness and diameter in nulliparous females. *Dis Colon Rectum* 2007;50:1405–11.
11. Frudinger A, Halligan S, Bartram CI, Price AB, Kamm MA, Winter R. Female anal sphincter: age-related differences in asymptomatic volunteers with high-frequency endoanal US. *Radiology* 2002;224:417–23.