

# Complete response of skull base inverted papilloma to chemotherapy: Case report

Edward C. Kuan, M.D., M.B.A.,<sup>1</sup> John W. Frederick, M.D.,<sup>1</sup> Miguel F. Palma Diaz, M.D.,<sup>2</sup> Dean W. Lim, M.D.,<sup>3</sup> and Jeffrey D. Suh, M.D.<sup>1</sup>

## ABSTRACT

**Background:** *Inverted papilloma (IP) is the most common benign sinonasal neoplasm. Endoscopic techniques, improved understanding of pathophysiology, and novel surgical approaches have allowed rhinologists to treat IPs more effectively, with surgery being the mainstay of therapy. Frontal sinus IP poses a challenge for surgical therapy due to complex anatomy and potentially difficult surgical access.*

**Objectives:** *We reported a unique case of a massive frontal sinus IP that presented with intracranial and orbital extension, with near resolution after chemotherapy.*

**Methods:** *A retrospective case review of a patient with a frontal sinus IP treated at a tertiary academic medical center.*

**Results:** *A 75-year-old male patient presented with nasal obstruction, purulent nasal discharge, and a growing left supraorbital mass. Endoscopy demonstrated a mass that filled both frontal and ethmoid sinuses, with orbital invasion. There also was substantial erosion of the posterior table, which measured 1.73 × 1.40 cm. A biopsy specimen demonstrated IP with carcinoma in situ. The patient was deemed unresectable on initial evaluation and, subsequently, underwent chemotherapy (carboplatin and paclitaxel). The tumor had a dramatic response to chemotherapy, and the patient elected for definitive surgery to remove any residual disease. During surgery, only a small focus of IP was found along the superior wall of the frontal sinus. No tumor was found elsewhere, including at the site of skull base erosion. The final pathology was IP without carcinoma in situ or dysplasia.*

**Conclusion:** *This was the first reported case of chemotherapeutic “debulking” of IP, which facilitated surgical resection, despite substantial intracranial and orbital involvement. Although nearly all IPs can be treated surgically, rare cases, such as unresectable tumors, may benefit from systemic chemotherapy.*

(Allergy Rhinol 8:e105–e108, 2017; doi: 10.2500/ar.2017.8.0201)

**I**nverted papilloma (IP) is the most common benign neoplasm of the sinonasal tract. With novel endoscopic techniques and an improved understanding of its pathophysiology, IP is now effectively managed through surgery, with recurrence rates as low as 5–10%.<sup>1</sup> Standard surgical therapy entails debulking disease until the site of attachment and obtaining an adequate deep margin (including overlying bone, if any).<sup>2</sup> Although histologically benign,

if left alone, IPs have a propensity to undergo malignant transformation, the rate of which is estimated to be between 5 and 15%.<sup>3</sup>

Adjunctive therapies, such as radiation and chemotherapy, have traditionally played a limited role in the management of IP and are generally not considered first-line therapy. Indications to consider these therapies generally include multiple recurrences, locally advanced and/or unresectable disease, positive margins, IP with malignant transformation, and poor surgical candidates. Of these tumor characteristics, chemotherapy is truly only considered when there is a suspicion for malignant transformation and, overall, is uncommonly used as a treatment option. We reported a case of a patient with a massive frontal sinus IP with intracranial and orbital extension, initially thought to have malignant disease, with a dramatic response to chemotherapy. This report was approved by the institutional review board of the University of California, Los Angeles, California.

## CASE PRESENTATION

A 75-year-old healthy male patient presented to the clinic at a tertiary cancer center with nasal obstruction, purulent nasal discharge, and a growing left supra-

---

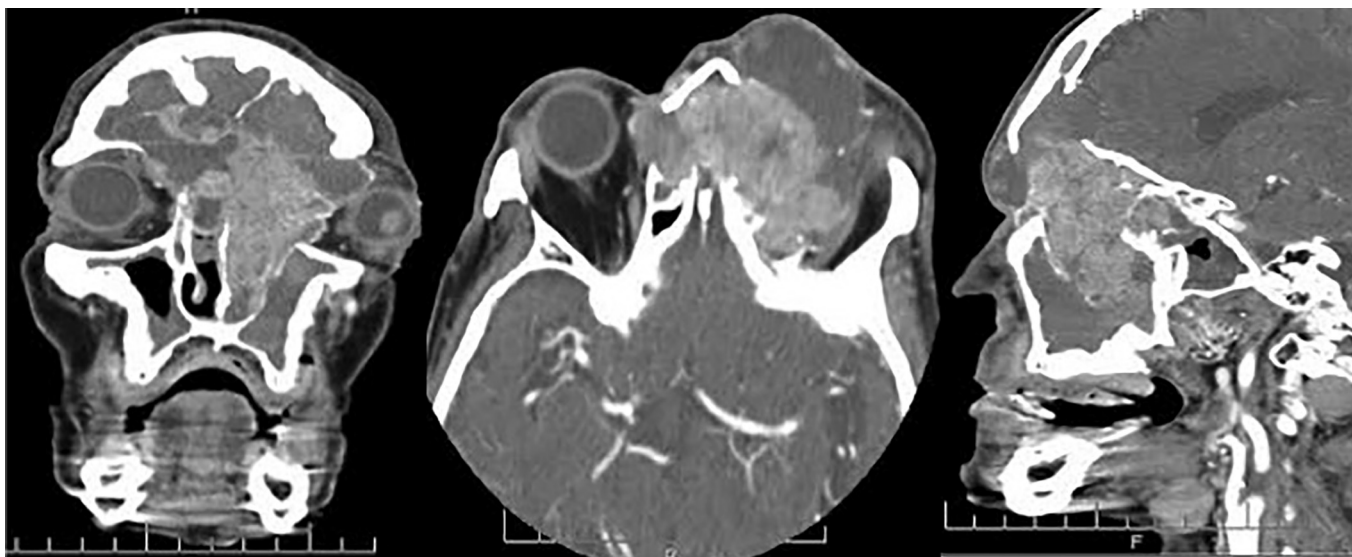
From the <sup>1</sup>Department of Head and Neck Surgery, University of California, Los Angeles, Los Angeles, California, <sup>2</sup>Pathology and Laboratory Medicine, University of California, Los Angeles, Los Angeles, California, and <sup>3</sup>Department of Medical Oncology and Therapeutics Research, City of Hope Cancer Center, Duarte, California  
No external funding sources reported

The authors have no conflicts of interest to declare pertaining to this article  
Address correspondence to Jeffrey D. Suh, M.D., Department of Head and Neck Surgery, University of California, Los Angeles, 10833 Le Conte Avenue, 62–132 CHS, Los Angeles, CA 90095

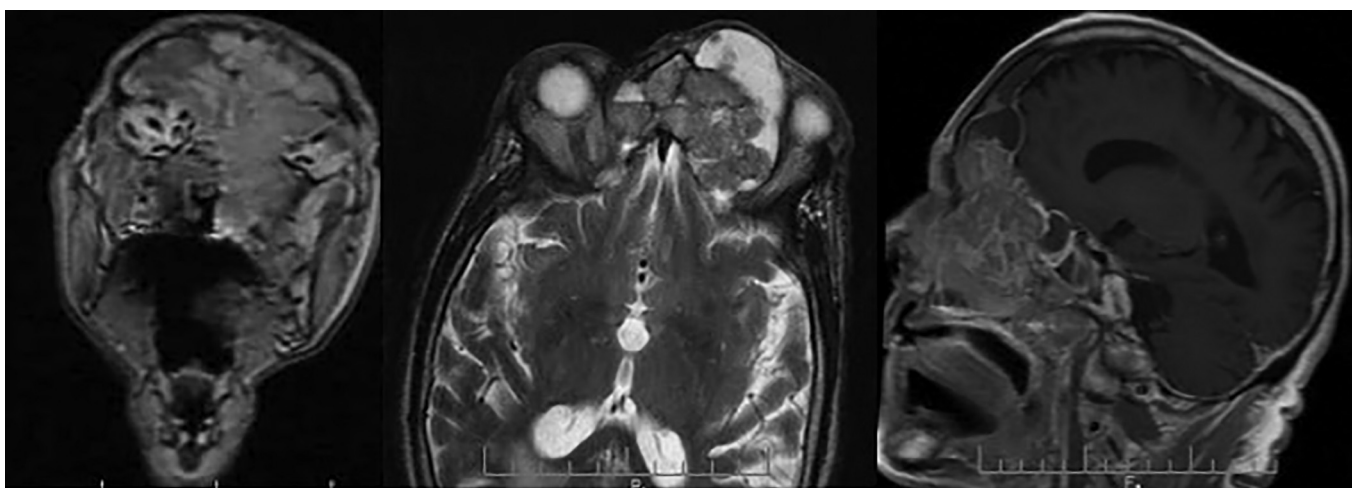
E-mail address: jeffsuh@mednet.ucla.edu

This work is published and licensed by OceanSide Publications, Inc. The full terms of this license are available at <https://www.allergyandrhinology.com/terms> and incorporate the Creative Commons License Deed: Attribution – Non-Commercial – NoDerivs 4.0 Unported (CC BY-NC-ND 4.0). By accessing the work you hereby accept the terms. Non-commercial uses of the work are permitted without any further permission from OceanSide Publications, Inc., provided the work is properly attributed. Any use of the work other than as authorized under this license or copyright law is prohibited.  
Copyright © 2017, OceanSide Publications, Inc., U.S.A.

---



**Figure 1.** Pretreatment computed tomography of the sinuses demonstrates extensive disease filling the frontal and ethmoid sinuses, with mucocele formation, leading to left intraorbital extension and erosion of the posterior table of the frontal sinus.



**Figure 2.** Pretreatment magnetic resonance imaging of the sinuses once again demonstrates the extensive left-sided disease with associated mucocele.

and intraorbital mass over the past 7 months. There was an associated 15-lb (6.8-kg) weight loss. He had a nasal biopsy performed outside of the hospital, which was read as IP with squamous cell carcinoma *in situ*. Nasal endoscopy revealed a large polypoid nasal mass that filled both the frontal and ethmoid sinuses, with apparent left orbital invasion. Computed tomography (Fig. 1) and magnetic resonance imaging (Fig. 2) of the sinuses was obtained and showed the mass extending posteriorly within the frontal sinus, with associated mucocele formation, which eroded the posterior table over an area of  $1.73 \times 1.40$  cm. Of note, the patient had a 60 pack-year smoking history and consumed six alcoholic drinks per week over the past 30 years.

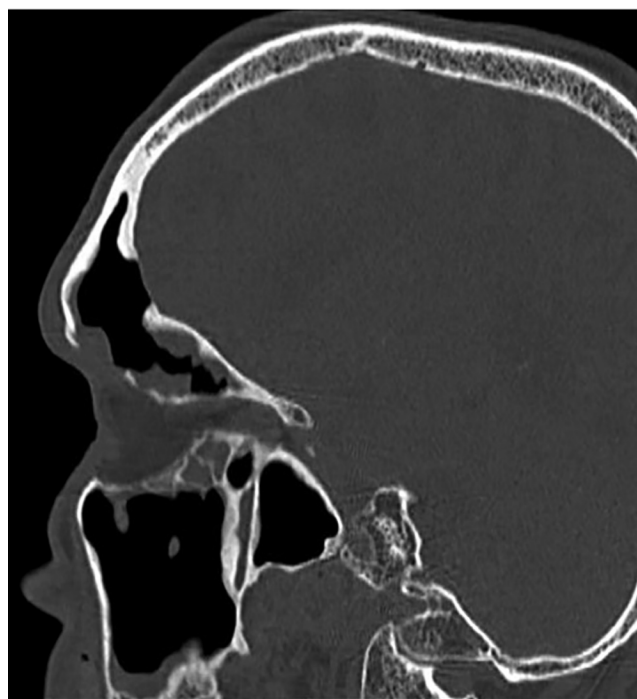
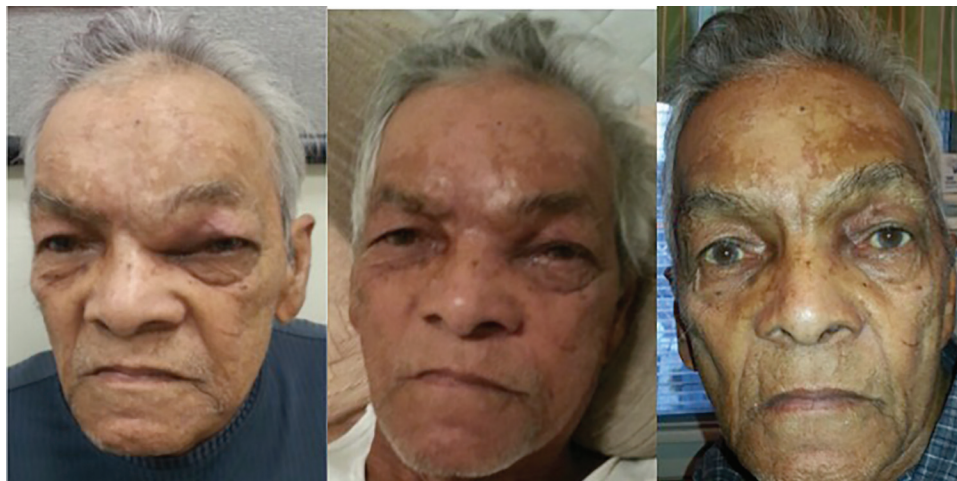He was initially deemed by the treating team to have unresectable disease, with the large mass being unable

to be selectively encompassed by radiation therapy. As such, he elected chemotherapy with carboplatin (306.3 mg per cycle) and paclitaxel (542.4 mg per cycle), which he completed over 6 weeks (four cycles). As treatment progressed, although he had adverse effects from the chemotherapy, his sinonasal symptoms improved and his left supraorbital swelling began to regress (Fig. 3).

He was then referred to a tertiary rhinology clinic, where he elected for definitive surgical management to remove any residual disease. A repeated preoperative computed tomography demonstrated marked shrinkage of the mass (Fig. 4). An endoscopic modified Lothrop procedure (Draf III) was performed, during which only a small focus of IP was found along the superior wall of the left frontal sinus (Fig. 5). Of note,



**Figure 3.** Before (left), during (6 weeks after initiation of therapy) (center), and after (2 months after completion of therapy) (right) chemotherapy pictures of the patient (used with written permission), with near-complete resolution of the left supraorbital swelling.

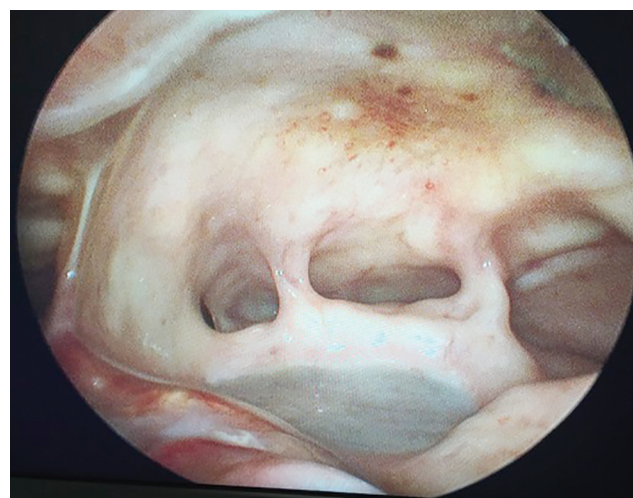

**Figure 4.** Postchemotherapy computed tomography of the sinuses demonstrates near resolution of the left frontal sinus mass; areas of supraorbital and posterior table dehiscence are evident.

there was a large area of posterior table erosion, with dural pulsations visible through the mucosa and no intervening bony layer, although there was no frank intracranial connection. The final pathology results showed only IP without squamous cell carcinoma *in situ* or dysplasia. The patient had been followed up every 1–2 months as an outpatient and remained recurrence free at 1 year after surgery, with good overall functional status after recovery from chemotherapy.

## DISCUSSION

Most IP cases can be effectively treated, even cured, by endoscopic sinus surgery alone. In contrast, previ-



**Figure 5.** Postoperative endoscopy of the Draf III cavity demonstrated mucosal healing but no evidence of recurrent disease, with a visible dehiscence of the posterior table of the frontal sinus.

ous reports indicate that squamous cell carcinoma that arises from IP has a guarded prognosis, of 63% survival at 3 years.<sup>4</sup> This particular patient was treated with chemotherapy because the initial biopsy result was suggestive of malignant transformation. Incidentally, it achieved a “medical debulking” phenomenon, which facilitated his subsequent surgery (*e.g.*, decreased disease burden, decreased blood loss, improved access). Although extremely rare for patients with IP in difficult-to-access areas (*e.g.*, lateral frontal sinus), extensive disease, or malignant transformation, neoadjuvant systemic chemotherapy may improve surgical access, which allowed for a chance of a cure. There is at least some interest in identifying novel chemotherapeutic agents for the management of IP, with photodynamic therapy showing some efficacy.<sup>5</sup> Adriaensen *et al.*<sup>6</sup> suggested efficacy in topical application of 5-fluorouracil, a nucleoside synthesis inhibitor, over sites where complete mucoperiosteum and

bone removal may not be possible. It is critical to weigh the risks and benefits of chemotherapy with the patient before deciding on treatment. In this case, carboplatin, an alkylating agent, is associated with myelosuppression and thus an elevated risk of opportunistic infections, whereas paclitaxel, a tubulin-targeting drug, is frequently associated with peripheral neuropathy. Both drugs may also cause systemic toxicity, such as nausea and vomiting, hair loss, and diarrhea.

As we begin to understand more about the pathophysiology of IP, surgical strategies have evolved to address this disease process. Specifically, once the tumor has been debulked and the site of attachment is identified, removal of this site, followed by drilling, cauterization, or excision of the underlying bone is now considered standard of care.<sup>2</sup> Primary cases have a higher rate of cure because revision cases are often associated with distorted anatomic landmarks, multiple sites of attachments, and tumor seeding.<sup>7</sup> IPs with sites of attachments in the frontal and sphenoid sinuses pose special challenges due to the proximity of the skull base. For frontal sinus IPs, medial and posterior wall IPs may often be completely removed *via* a standard unilateral endoscopic frontal sinusotomy, whereas those with broader attachments or multifocal involvement may be best accessed *via* a modified endoscopic Lothrop procedure. For extremely extensive frontal sinus IPs, a frontal sinus trephination or osteoplastic flap procedure may be indicated for complete removal of disease. However, the posterolateral wall of the sphenoid sinus houses the optic nerve and carotid arteries, and complete bone removal overlying these structures is infeasible. For this reason, sphenoid sinus IP has a high rate of recurrence (14.6%),<sup>8</sup> and, often-times, the decision is made to perform a subtotal resection with judicious follow up and surveillance as opposed to risk injury to the underlying neurovascular structures.

Similar to but more spatially selective than chemotherapy is the potential value of radiation therapy in treating IPs. In contrast to chemotherapy, radiation allows for selective targeting of primary tumor sites, although local toxicity to surrounding normal structures must be taken into consideration before treatment. This is especially true with the advent of newer technologies, such as intensity modulation or stereotactic guidance, in which concentrated radiation doses may be delivered to a targeted area with precision and spatial selectivity. For instance, Hug *et al.*<sup>9</sup> reported

that 7 of 7 patients (100%) with IP and 15 of 18 of patients with IP and with associated invasive carcinoma (83%) achieved long-term recurrence-free survival after primary or adjuvant radiation therapy. There are other reports with similar results, with good local control rates.<sup>10</sup> However, the unifying theme of advocating for the use of radiation therapy is only in the context of failed surgical management, especially in patients with unresectable, multiply recurrent, or malignant disease.

## CONCLUSION

Although not without its comorbidities and medical and functional sequelae, chemotherapy may be considered in rare cases of unresectable IP. We reported, to our knowledge, the first case in the literature of a patient who, after receiving treatment, has performed remarkably well and remained free of recurrent disease today.

## REFERENCES

1. Healy DY Jr, Chhabra N, Metson R, et al. Surgical risk factors for recurrence of inverted papilloma. *Laryngoscope* 126:796–801, 2016.
2. Pagella F, Pusateri A, Giourgos G, et al. Evolution in the treatment of sinonasal inverted papilloma: Pedicle-oriented endoscopic surgery. *Am J Rhinol Allergy* 28:75–81, 2014.
3. Vorasubin N, Vira D, Suh JD, et al. Schneiderian papillomas: Comparative review of exophytic, oncocytic, and inverted types. *Am J Rhinol Allergy* 27:287–292, 2013.
4. Tanvetyanon T, Qin D, Padhya T, et al. Survival outcomes of squamous cell carcinoma arising from sinonasal inverted papilloma: Report of 6 cases with systematic review and pooled analysis. *Am J Otolaryngol* 30:38–43, 2009.
5. Zhang Y, Yang Y, and Zou X. Efficacy of 5-aminolevulinic acid photodynamic therapy in treatment of nasal inverted papilloma. *Photodiagnosis Photodyn Ther* 10:549–551, 2013.
6. Adriaensen GF, van der Hout MW, Reinartz SM, et al. Endoscopic treatment of inverted papilloma attached in the frontal sinus/recess. *Rhinology* 53:317–324, 2015.
7. Adriaensen GF, Lim KH, Georgalas C, et al. Challenges in the management of inverted papilloma: A review of 72 revision cases. *Laryngoscope* 126:322–328, 2016.
8. Suh JD, Ramakrishnan VR, Thompson CF, et al. Inverted papilloma of the sphenoid sinus: Risk factors for disease recurrence. *Laryngoscope* 125:544–548, 2015.
9. Hug EB, Wang CC, Montgomery WW, and Goodman ML. Management of inverted papilloma of the nasal cavity and paranasal sinuses: Importance of radiation therapy. *Int J Radiat Oncol Biol Phys* 26:67–72, 1993.
10. Guedea F, Mendenhall WM, Parsons JT, and Million RR. The role of radiation therapy in inverted papilloma of the nasal cavity and paranasal sinuses. *Int J Radiat Oncol Biol Phys* 20:777–780, 1991. □