



Removal of MIRAgel scleral buckle implants using Yankauer suction catheter with adjusted diameter

Shintaro Nakao^{a,b,c,*}, Takashi Nishida^c, Koh-Hei Sonoda^c

^a Department of Ophthalmology, National Hospital Organization, Kyushu Medical Center, Fukuoka, Japan

^b Clinical Research Institute, National Hospital Organization, Kyushu Medical Center, Fukuoka, Japan

^c Department of Ophthalmology, Graduate School of Medical Sciences, Kyushu University, Fukuoka, Japan

ARTICLE INFO

Keywords:

Rhegmatogenous retinal detachment
Complication
Polyvinyl chloride
Eye movement

ABSTRACT

Purpose: A variety of removal methods have been reported for cases wherein MIRAgel-associated complications have occurred. Recently, Santorum et al. reported an aspiration method using a metal microcannula. Herein, we report a novel alternative approach using Yankauer suction catheter based on Santorum et al.'s method.

Observations: This retrospective case involved a 40-year-old Caucasian man with MIRAgel implant-associated swelling-related complications (strabismus and disfiguring mass effect), who underwent suction-assisted implant removal in January 2020 at Kyushu University Hospital. Surgery was conducted under general anesthesia with an incision made in the superior quadrant, and the degraded MIRAgel implant was aspirated using a Yankauer suction catheter instrument with its diameter adjusted to the space. At the one-month follow-up, there were no early postsurgical complications, and the retina remained completely attached.

Conclusions: Yankauer suction catheter is a useful instrument for removal of MIRAgel scleral buckle implants. It is made up of polyvinyl chloride, which is safer and cheaper, and can be cut to adjust the instrument's diameter according to the surgical field.

1. Introduction

In 1985, Tolentino et al. reported an episcleral hydrogel explant (MIRAgel, MIRA Inc., Waltham, MA) as an alternative to silicone buckles for the treatment of rhegmatogenous retinal detachment.¹ The hydrophilic sponge-like material could store an anti-infective agent if soaked in the anti-infective solution before implantation. This was believed to help reduce the incidence of scleral buckle infections. The buckle would swell slightly after surgery, and thus increase the buckling effect, which was believed to be desirable because theoretically, it helped keep the retina reattached. Despite these potential advantages, long-term follow-up of cases for over 10 years revealed that the hydrolysis of the synthetic hydrophilic material leads to marked expansion of the substance, causing complications such as buckle extrusion and intrusion, eye motility disorder, and periocular infections, as well as significant cosmetic problems.²⁻⁴

In 1992, the first adverse events related to hydrogel scleral buckles were reported.⁵ Although MIRAgel implants were removed from the market in 1995, patients continue to present with implant-related complications decades after surgery. When symptomatic swelling

occurs, implant removal is the treatment of choice in cases with complications, but is technically difficult due to the friability of the implant, severe scleral ectasia, and relatively high rate of redetachment after removal.² Degraded hydrogel buckles pose additional challenges owing to their friable nature. The main challenge arises from the fact that degraded hydrogel material crumbles when manipulated, and any attempt to grasp or pull the buckle with forceps (as with silicone buckles) simply causes it to further separate. Currently, the most popular removal technique includes opening the conjunctiva and capsule over the entire length of the implant with subsequent pushing of the implant out of its capsule by means of squint hooks or similar instruments. However, residual fragments are often left behind with this approach, leading to the need for repeated removal procedures. Several alternative techniques and devices have been proposed, such as pulling on the implant with a cryoprobe or an aspiration device^{6,7} to assist in the pushing maneuvers, floating the implant out of the capsule with a balanced salt solution,⁸ or consolidating the implant with boric acid to facilitate its removal in one piece.⁹ However, the consistency also transformed from a soft, spongy, whitish, and compact material to a translucent, gel-like, cream-colored, friable material, making it

* Corresponding author. National Hospital Organization, Kyushu Medical Center, 1-8-1 Jigyohama, Chuo-Ku, Fukuoka, 810-8563, Japan.

E-mail address: shintaro.nakao18@gmail.com (S. Nakao).

<https://doi.org/10.1016/j.ajoc.2022.101470>

Received 19 January 2022; Received in revised form 1 March 2022; Accepted 3 March 2022

Available online 7 March 2022

2451-9936/© 2022 The Author(s).

Published by Elsevier Inc.

This is an open access article under the CC BY-NC-ND license

(<http://creativecommons.org/licenses/by-nc-nd/4.0/>).

extremely difficult to remove. Recently, Santorum et al. reported a method using a metal micro cannula.⁷ However, because of the cannula's uniform diameter, the suction efficiency may be insufficient, and the surrounding tissue may be damaged. Herein, we introduce a simple and safe method to remove extruded MIRAgel explants based on Santorum et al.'s method, reducing the risk of fragmentation and damage to surrounding tissues.

1.1. Case presentation

A 40-year-old Caucasian man presented with slowly progressive swelling of the upper eyelid and movement disorders in his left eye (Fig. 1A). Thirty years earlier, he had undergone a segmental episcleral buckle procedure to repair his retinal detachment. At the time of presentation, his best-correlated visual acuity was 20/50, and his intraocular pressure was 10 mmHg in the left eye. Slit lamp examination revealed a swollen MIRAgel implant extruding through the conjunctiva in the supranasal quadrant of the left eye (Fig. 1B). Fundus examination revealed buckle elevation in the superior part of the left retina. Orbital

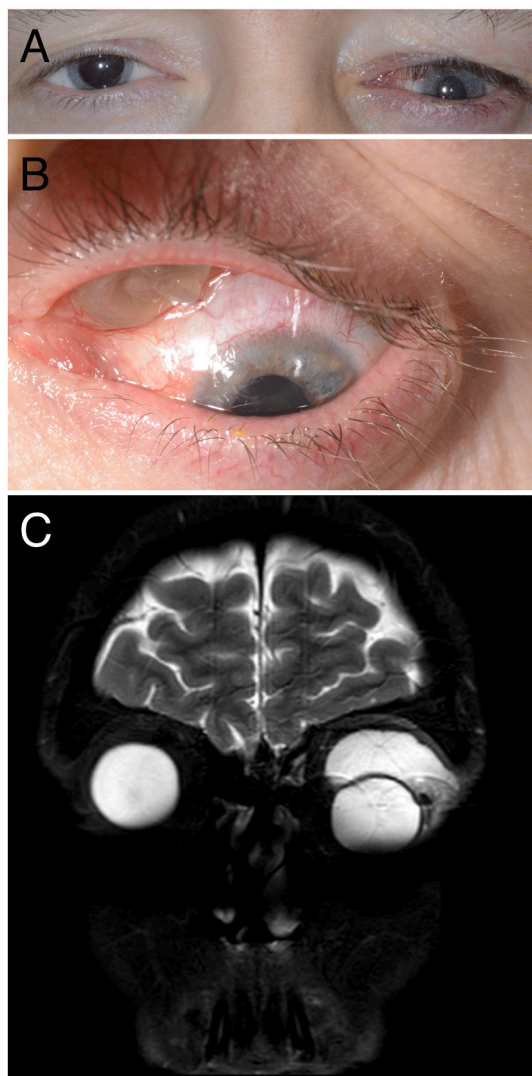


Fig. 1. Clinical photographs and magnetic resonance imaging. (A) An external ocular photograph shows a swelling of the upper eyelid and the downward deviation of the left eye. (B) A clinical photograph shows a swollen MIRAgel implant extruding through the conjunctiva in the supranasal quadrant of the left eye. (C) Magnetic resonance imaging T2 coronal section shows a swelling MIRAgel compressing the eyeball downward.

magnetic resonance imaging showed a 31 × 12 mm supranasal mass pressing his left eyeball (Fig. 1C). Surgery was conducted under general anesthesia. A part of the buckle that had already extruded from the conjunctiva was removed through the existing wound. The conjunctiva and capsule around the implant were incised with scissors at the site of the maximal conjunctival bulge. Any non-absorbable scleral suture was cut and removed. The incision was made to expose the buckle. A 20-mm incision across the superior rectus muscle was made in the superior segment, and the degraded MIRAgel implant was aspirated using a Yankauer suction catheter instrument (Catalog No. 5040; COVDIEN, Tokyo, Japan (0.87USD)) with the tip cut off and the diameter adjusted to the space (Fig. 2). A Yankauer suction catheter instrument was then used to aspirate the degraded hydrogel material directly without creating smaller pieces (Video). The vacuum pressure was set to -500 mBar on the collection canister, as previously reported.⁷ The wound was sutured with 8-0 PGA absorbable violet braided (MANI, Tochigi, Japan) after confirming the absence of scleral thinning or perforation. The capsule was irrigated with cefuroxime antibiotic solution. At the one-month follow-up, there were no early postsurgical complications, and the retina remained completely attached.

Supplementary video related to this article can be found at <https://doi.org/10.1016/j.ajoc.2022.101470>.

2. Discussion

MIRAgel implant removal is difficult because of their material, and often requires surgery. We present a novel use of the Yankauer suction catheter in MIRAgel removal surgery. The Yankauer suction catheter is a suction device used for clearing operative sites during various surgical procedures, including orthopedic surgery, and oropharyngeal secretions.^{10,11} They are usually constructed from flexible polyvinyl chloride suction tubes, which are sterile and inexpensive.

This device has proven to be useful for the minimally invasive fixation of the capsule surrounding the implant. Unlike other techniques, vacuuming efficiently separates the mobile from immobile parts detaching the implant without touching the eye wall. Recently, another suction device has been reported as a new method for removing MIRAgel.⁷ This suction device has a long metal shaft with a diameter of 3 mm. The diameter of the Yankauer suction catheter suction tube is 4 mm as it is composed of polyvinyl chloride and can be cut and adjusted to any diameter. Moreover, the suction tube is less likely to damage the surrounding tissue.

In conclusion, we have found that direct aspiration through a Yankauer suction catheter facilitates the removal of MIRAgel scleral buckle explants. Instead of trying to grasp or luxate the friable material, it is removed in place via a vacuum. This instrument seems to be safer, faster, and easier to administer than other previously described methods.

Although MIRAgel has been off-market, we still encounter patients previously treated with hydrogel buckles. These patients require MIRAgel-removal surgery. However, further studies with more cases and longer follow-up periods are needed to explore the advantages and limitations of this technique.




Fig. 2. A sterile, single use cuttable Yankauer suction catheter instrument. (A) This instrument is made of polyvinyl chloride with the diameter of 4 mm. (B) The tip is cut off and the diameter adjusted to the space.

Patient consent

Written informed consent for the research and publication of this study and any accompanying images was obtained from the patients.

Authorship

All authors attest that they meet the current ICMJE criteria for authorship.

Declaration of competing interest

Shintaro Nakao: consulting fee by Kowa; travel reimbursements and speaker fees by Novartis, Bayer Pharma, Canon Inc., Santen Pharmaceutical, Kowa, Senju Pharmaceutical, Ono Pharmaceutical, MSD. Koh-Hei Sonoda: consulting fees from Kowa, JT, Abbvie; travel reimbursements and speaker fees from Novartis, Bayer Pharma, Canon Inc., Santen Pharmaceutical, Kowa, Senju Pharmaceutical, Ono Pharmaceutical, MSD, HOYA, Wakamoto, AMO, Alcon, Otsuka Pharmaceutical, AbbVie Eisai, Nidek, Topcon, Novo Nordisk, Mitsubishi Tanabe Pharma, Sumitomo Dainippon Pharma, Astellas. Takashi Nishida has no financial disclosure.

Acknowledgement

Funding: This study was supported by grants from JSPS KAKENHI,

Grant-in-Aid for Scientific Research (C) No. 20K09829 (SN), and the Foundation for the Advancement of Clinical Medicine, Fukuoka, Japan (SN).

References

1. Tolentino FI, Roldan M, Nassif J, Refojo MF. Hydrogel implant for scleral buckling. Long-term observations. *Retina*. 1985;5:38–41.
2. Crama N, Klevering BJ. The removal of hydrogel explants: an analysis of 467 consecutive cases. *Ophthalmology*. 2016;123:32–38.
3. Roh M, Lee NG, Miller JB. Complications associated with MIRAgel for treatment of retinal detachment. *Semin Ophthalmol*. 2018;33:89–94.
4. Hatori T, Imai M, Iijima H. Intravitreal intrusion of an intrascleral MIRAgel buckling implant. *Jpn J Ophthalmol*. 2011;55:310–311.
5. Marin JF, Tolentino FI, Refojo MF, Schepens CL. Long-term complications of the MAI hydrogel intrascleral buckling implant. *Arch Ophthalmol*. 1992;110:86–88.
6. Richards AL, Meyer DR. Late complications of hydrogel scleral buckle implants and a technique for effective removal. *Ophthalmic Plast Reconstr Surg*. 2012;28:455–458.
7. Santorum P, De Vitto AML, Bertelli E. Removal of MIRAgel scleral buckle implants: the direct aspiration technique. *Retina*. 2019.
8. Chalioulias K, Nachiketa A, Scott R. A simple way to remove miragel explants after long-term inflammation and extrusion. *Retin Cases Brief Rep*. 2009;3:74–76.
9. Roldan-Pallares M, Avila MI, Refojo MF. The use of boric acid solution to help in the removal of biodegraded Miragel episcleral buckles. *Retina*. 2005;25:90–93.
10. Asmar O, Jeevan R, Iqbal A. Minimal access tendon harvesting without a harvester: a cheap and effective alternative technique using a plastic yankauer suction tip. *J Hand Surg Asian Pac*. 2020;25:515–517.
11. Allom R, Saad A, Kunasingam K, Amr R. The novel use of the Yankauer sucker as a radiolucent drill guide in orthopaedic surgery. *Ann R Coll Surg Engl*. 2015;97:402.