



REVIEW

# Current concepts and dilemmas in idiopathic interstitial pneumonias [version 1; referees: 4 approved]

Jay H. Ryu <sup>1</sup>, Teng Moua<sup>1</sup>, Natalya Azadeh<sup>1</sup>, Misbah Baqir<sup>1</sup>, Eunhee S. Yi<sup>2</sup>

<sup>1</sup>Division of Pulmonary and Critical Care Medicine, Mayo Clinic, Rochester, MN, USA


<sup>2</sup>Division of Anatomic Pathology, Mayo Clinic, Rochester, MN, USA





**v1** **First published:** 10 Nov 2016, 5(F1000 Faculty Rev):2661 (doi: 10.12688/f1000research.9601.1)  
**Latest published:** 10 Nov 2016, 5(F1000 Faculty Rev):2661 (doi: 10.12688/f1000research.9601.1)

**Abstract**

Idiopathic interstitial pneumonias comprise approximately one-third of interstitial lung diseases (also called diffuse parenchymal infiltrative lung diseases). The classification of idiopathic interstitial pneumonias has undergone several revisions since the initial description of 40 years ago, and the most recent version was published in 2013. Although some aspects have been clarified, this group of heterogeneous disorders continues to be a source of confusion and misunderstanding in clinical applications. In this article, we explore several topical themes in the evaluation and management of patients with idiopathic interstitial pneumonias.

**Open Peer Review**

**Referee Status:** 

	Invited Referees			
	1	2	3	4
<b>version 1</b> published 10 Nov 2016				

F1000 Faculty Reviews are commissioned from members of the prestigious F1000 Faculty. In order to make these reviews as comprehensive and accessible as possible, peer review takes place before publication; the referees are listed below, but their reports are not formally published.

- 1 **Yasuhiro Kondoh**, Tosei General Hospital  
Japan
- 2 **Sergio Harari**, Ospedale San Giuseppe  
Italy
- 3 **Dominique Valeyre**, Université Paris 13,  
Sorbonne Paris Cité France, Avicenne  
University Hospital France
- 4 **Kevin Flaherty**, University of Michigan  
USA

**Discuss this article**

Comments (0)

**Corresponding author:** Jay H. Ryu ([ryu.jay@mayo.edu](mailto:ryu.jay@mayo.edu))

**How to cite this article:** Ryu JH, Moua T, Azadeh N *et al.* **Current concepts and dilemmas in idiopathic interstitial pneumonias [version 1; referees: 4 approved]** *F1000Research* 2016, 5(F1000 Faculty Rev):2661 (doi: [10.12688/f1000research.9601.1](https://doi.org/10.12688/f1000research.9601.1))

**Copyright:** © 2016 Ryu JH *et al.* This is an open access article distributed under the terms of the [Creative Commons Attribution Licence](https://creativecommons.org/licenses/by/4.0/), which permits unrestricted use, distribution, and reproduction in any medium, provided the original work is properly cited.

**Grant information:** The author(s) declared that no grants were involved in supporting this work.

**Competing interests:** All authors declare that they have no competing interests.

**First published:** 10 Nov 2016, 5(F1000 Faculty Rev):2661 (doi: [10.12688/f1000research.9601.1](https://doi.org/10.12688/f1000research.9601.1))

## Introduction

Idiopathic interstitial pneumonias (IIPs) comprise approximately one-third of interstitial lung diseases (ILDs) but remain a difficult concept to grasp for clinicians and scientists. These disorders represent a heterogeneous group of diffuse parenchymal lung diseases that are defined on the basis of histopathologic pattern combined with clinical and radiologic features. There continue to be misunderstanding and misapplication of concepts pertaining to IIPs, which may lead to suboptimal management and patient outcomes. Revisions in definitions and classification of IIPs have likely contributed to this problem. Some patients with IIPs remain unclassifiable owing to discordant or overlapping clinical, imaging, and histopathologic features or lack of inter-observer agreement<sup>1,2</sup>. In this article, we will explore the current concepts and dilemmas regarding this group of diffuse parenchymal lung diseases.

## Historical background

Averill A. Liebow, a pathologist, provided the initial definition and classification of interstitial pneumonias in 1974<sup>3</sup>. He described “interstitial pneumonia” as “a type of response to injury in the lung that takes place predominantly in the supporting structures rather than within the alveoli”<sup>3</sup>. He noted that although interstitial fibrosis may be a possible consequence of this injury, there is diversity in the initial morphology of these disorders and associated clinical correlates. This early concept classified interstitial pneumonias based on morphologic (histologic) criteria into five types: “usual” interstitial pneumonia (most commonly encountered), bronchiolitis obliterans with classical interstitial pneumonia, desquamative interstitial pneumonia, lymphoid interstitial pneumonia, and giant cell interstitial pneumonia.

Over the subsequent 40 years, the classification of interstitial pneumonias has undergone several revisions<sup>4-6</sup>. Similarly, the concept of idiopathic pulmonary fibrosis (IPF) has also been modified; the initial definition of IPF (also called cryptogenic fibrosing alveolitis) included several distinct types of interstitial pneumonias as well as those with identifiable underlying diseases (i.e. not idiopathic), e.g. connective tissue diseases<sup>7,8</sup>. Thus, the definition of IPF became narrowed to that of usual interstitial pneumonia of unknown cause, i.e. no identifiable cause or underlying disease responsible for the fibrotic lung disease. During the process of these conceptual changes, the term “idiopathic” became attached to the classification of interstitial pneumonias, i.e. IIPs<sup>4-6</sup>. The most recent version of the IIPs lists three major categories: major, rare, and unclassifiable. The first group includes IPF, idiopathic nonspecific interstitial pneumonia, respiratory bronchiolitis–ILD, desquamative interstitial pneumonia, cryptogenic organizing pneumonia, and acute interstitial pneumonia. The second comprises idiopathic lymphoid interstitial pneumonia and idiopathic pleuroparenchymal fibroelastosis. IPF, i.e. usual interstitial pneumonia of unidentifiable cause, remains the most commonly encountered form of IIP<sup>8,9</sup>.

## Are idiopathic interstitial pneumonias truly idiopathic?

Disease classifications provide a framework for conceptualization and communication but inevitably change over time as additional insight and knowledge are gained. Although the current IIP classification inserts the term “idiopathic” for several types of

interstitial pneumonias in an attempt to distinguish IIP from interstitial pneumonia with identifiable causes or underlying disease, several dilemmas remain.

Most experts acknowledge that respiratory bronchiolitis-associated ILD and desquamative interstitial pneumonia in the majority of patients represent smoking-related lung diseases<sup>10-13</sup>. Indeed, smoking has been associated with an expanding spectrum of ILDs including pulmonary Langerhans cell histiocytosis, acute eosinophilic pneumonia, combined pulmonary fibrosis and emphysema syndrome, and smoking-related interstitial fibrosis. The main mode of treatment for subjects with smoking-related ILDs is smoking cessation rather than the use of immunosuppressive or antifibrotic agents employed in other forms of IIPs. Thus, continued inclusion of respiratory bronchiolitis-associated ILD and desquamative interstitial pneumonia under the umbrella of IIPs seems difficult to justify other than for historical reasons.

Nonspecific interstitial pneumonia refers to a pattern of lung injury characterized by chronic interstitial inflammation and fibrosis that lacks the typical features of usual interstitial pneumonia such as temporal heterogeneity with fibroblast foci and honeycomb fibrosis<sup>4,5,14</sup>. Nonspecific interstitial pneumonia is known to be associated with connective tissue diseases such as scleroderma and polymyositis. In recent years, it has become apparent that many patients with “idiopathic” nonspecific interstitial pneumonia develop features of definable connective tissue diseases such as inflammatory arthritis, rash, and sclerodactyly. Demographic features such as female gender and younger age at presentation support a greater likelihood of underlying connective tissue disease. In this regard, a recently proposed concept of “interstitial pneumonia with autoimmune features” (IPAF) is relevant<sup>15</sup>. This term recognizes the observation that many patients with IIPs, particularly nonspecific interstitial pneumonia, have features suggestive of an underlying autoimmune process but do not meet criteria for definable connective tissue disease and attempts to bring together what has previously been called “undifferentiated connective tissue disease-associated ILD” and “lung-dominant connective tissue disease”<sup>15</sup>. The proposed criteria for the diagnosis of IPAF include evidence of an interstitial pneumonia (radiologic or morphologic) of unknown cause and at least one feature from two of three domains: clinical domain (clinical features suggestive of autoimmune disease), serologic domain (circulating autoantibodies), and morphologic domain (high-resolution computed tomography [HRCT] or histopathologic features). It is hoped that this consensus in nomenclature and classification criteria will bring about a more informed path to gaining insight into this group of patients. However, some patients with nonspecific interstitial pneumonia will not have an identifiable cause or underlying disease despite a comprehensive evaluation, i.e. remain idiopathic.

Other forms of IIPs such as organizing pneumonia and lymphocytic interstitial pneumonia are rarely idiopathic. Unfortunately, this is not widely appreciated by clinicians, who may neglect to reassess such patients for identifiable causes and underlying diseases. Furthermore, although patients with usual interstitial pneumonia commonly have IPF, other diagnostic possibilities remain, even for those with a surgical lung biopsy confirmation. Several

studies have demonstrated that the histologic pattern of usual interstitial pneumonia can be seen in patients with chronic hypersensitivity pneumonitis as well as connective tissue diseases<sup>16–19</sup>. Thus, we wonder whether the continued use of the original term “interstitial pneumonias” coined by Liebow may have prevented some of the confusion associated with the current term “IIPs” in referring to this group of ILDs.

### What is the role of lung biopsy?

As discussed, the initial concept and classification of interstitial pneumonias were defined by histopathologic features. The advent of HRCT has allowed noninvasive diagnosis of IIPs to be possible in many cases. Decreasing need for lung biopsy, particularly surgical lung biopsy, has evolved through a better understanding of radiologic correlates of interstitial pneumonias. For example, a HRCT pattern characterized by lower lobe and peripherally predominant reticular and honeycomb changes in the absence of other features such as micronodules, cysts, or ground glass is highly predictive of usual interstitial pneumonia and does not require biopsy confirmation of the underlying histopathologic pattern<sup>8</sup>. However, the absence of typical HRCT features such as peripheral honeycombing does not exclude the possibility of usual interstitial pneumonia<sup>20</sup>. Respiratory bronchiolitis-associated ILD can generally be diagnosed without a biopsy in smokers who manifest patchy ground-glass opacities and centrilobular nodules<sup>6</sup>.

The “definitive” method of obtaining tissue in patients with suspected ILD is surgical lung biopsy, usually performed as a video-assisted thoracoscopic procedure. Surgical lung biopsy clearly has a role in defining the underlying histopathologic pattern in patients with nondiagnostic HRCT findings. For example, nonspecific interstitial pneumonia, desquamative interstitial pneumonia, and hypersensitivity pneumonia may all be characterized by diffuse ground-glass opacities in the lung but entail different treatment strategies. However, surgical lung biopsy is associated with significant risks, particularly for those patients with advanced age, comorbid conditions, IPF, and connective tissue-related ILDs<sup>21–23</sup>. Thus, the benefits and risks of a surgical lung biopsy need to be individualized according to the clinical context with consideration of diagnostic possibilities, anticipated biopsy results, and potential implications on management decisions.

Bronchoscopic biopsy usually performed with forceps is generally not diagnostic in patients with IIPs. However, the recent advent of cryobiopsy may increase the role of bronchoscopic biopsy in this clinical setting. Several studies have demonstrated increased diagnostic rate with bronchoscopic cryobiopsy even for patients with suspected IPF<sup>24–27</sup>. For example, Tomassetti and colleagues<sup>24</sup> recently demonstrated bronchoscopic cryobiopsy findings to have an impact similar to surgical lung biopsy in a multidisciplinary diagnostic process for patients with ILDs. Although bronchoscopic cryobiopsy yields larger specimens with fewer crush artifacts, the optimal technique remains to be determined since cryobiopsy may be associated with increased rates of bleeding and pneumothorax.

### Multidisciplinary discussion or clinical reasoning?

Multidisciplinary discussion (MDD) has been touted as the “gold standard” process by which a diagnosis is achieved in cases

of IIPs<sup>6,8,28,29</sup>. This conclusion has been primarily based on the observation of improved inter-observer agreement and diagnostic confidence resulting from dynamic interactions among clinicians, radiologists, and pathologists. However, the costs of multidisciplinary team meetings are high and the impact on clinical outcomes is unclear<sup>30–32</sup>. MDD for the diagnosis of IIPs is likely not a realistic option outside of academic medical centers.

The emphasis on the role of MDD in the diagnosis of IIPs has come about, in part, because of unrealistic expectations of clinicians as to the role of histopathologic patterns in the diagnosis of IIPs. Histopathologic patterns have varying morphologic specificities in identifying diseases and associated etiologies. Histologic pattern should not be confused with a diagnosis and the importance of clinical evaluation underestimated. For example, organizing pneumonia pattern is very nonspecific and can be seen in many diseases including infections, connective tissue disease-related ILD, aspiration, drug-induced lung injury, and many others. Thus, the diagnoses of IIPs, as well as ILDs in general, require judicious integration of relevant clinical, radiologic, and histopathologic (when available) data, i.e. clinical reasoning<sup>33–35</sup>. There are situations where a face-to-face interaction or verbal communication among the clinician, radiologist, and pathologist can be invaluable, but it is unrealistic to expect MDDs to occur routinely in the diagnostic evaluation of patients with suspected IIPs in most clinical practice settings. Ultimately, it is the essential role of the clinician to identify and integrate pivotal information derived from relevant disciplines in defining a diagnosis and implications thereof for the individual patient. Those patients with problematic and unresolved issues can be referred to an ILD center with appropriate expertise, MDD capability, and access to relevant clinical trials.

### What is the cause of acute exacerbations?

“Acute exacerbation” is a term that has been used to describe acute unexplained deterioration in respiratory status occurring during the clinical course of patients with IPF<sup>36</sup>. Over the past several years, this phenomenon has been recognized to occur in patients with other forms of fibrotic lung diseases, including chronic hypersensitivity pneumonitis, desquamative interstitial pneumonia, and connective tissue-related ILD<sup>37,38</sup>. Although the initial consensus definition of acute exacerbation required the exclusion of infections, pulmonary embolism, and other identifiable etiologies, a recent report from an international working group suggests that the definition be broadened to include any respiratory event characterized by new bilateral infiltrates not explained by heart failure or fluid overload<sup>39</sup>. This revised definition for acute exacerbation is meant to be more inclusive and more applicable in clinical practice.

Acute exacerbation occurring in patients with ILDs is associated with an alarmingly high short-term mortality rate of at least 50%<sup>36,40</sup>. Histopathologic pattern associated with this acute lung injury is diffuse alveolar damage in most cases, sometimes organizing pneumonia<sup>36,40–42</sup>. However, the underlying cause for this phenomenon remains unclear as to whether it represents an accelerated phase of the progressive fibrotic lung process or superimposed injury induced by an external trigger such as viral infection, micro-aspiration, or some other form of inhalational injury. Although systemic glucocorticoid therapy is commonly used in the treatment

of acute exacerbation in these patients, there is no clear evidence that such a strategy or other forms of treatment are effective.

## Conclusions

Although recent revisions in the concept of IIPs have clarified some issues, the current classification scheme of IIPs can be confusing for clinicians as well as radiologists and pathologists. Some forms of IIPs included in the current classification are not idiopathic, e.g. respiratory bronchiolitis-associated ILD and desquamative interstitial pneumonia, and some patients with IIPs may eventually manifest signs of a definable connective tissue disease. The role and the risks of surgical lung biopsy in the diagnosis of IIPs are becoming better defined. Although identification of the underlying histopathologic pattern can be important, it should be clinical reasoning that integrates all relevant data which is crucial in achieving a diagnosis. It is hoped that the recently revised definition of acute exacerbation

will lead to a better understanding and ultimately management of this deadly phenomenon.

## Abbreviations

HRCT, high-resolution computed tomography; IIP, idiopathic interstitial pneumonia; ILD, interstitial lung disease; IPAF, interstitial pneumonia with autoimmune features; IPF, idiopathic pulmonary fibrosis.

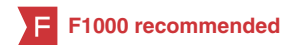## Competing interests

All authors declare that they have no competing interests.

## Grant information

The author(s) declared that no grants were involved in supporting this work.

## References




- Troy L, Glaspole I, Goh N, *et al.*: **Prevalence and prognosis of unclassifiable interstitial lung disease.** *Eur Respir J.* 2014; **43**(5): 1529–30.  
[PubMed Abstract](#) | [Publisher Full Text](#)
- Skolnik K, Ryerson CJ: **Unclassifiable interstitial lung disease: A review.** *Respirology.* 2016; **21**(1): 51–6.  
[PubMed Abstract](#) | [Publisher Full Text](#) | [F1000 Recommendation](#)
- Liebow A: **Definition and classification of interstitial pneumonias in human pathology.** *Prog Respir Res.* 1975; **8**: 1–32.  
[Publisher Full Text](#)
- Katzenstein AL, Myers JL: **Idiopathic pulmonary fibrosis: clinical relevance of pathologic classification.** *Am J Respir Crit Care Med.* 1998; **157**(4 Pt 1): 1301–15.  
[PubMed Abstract](#) | [Publisher Full Text](#)
- American Thoracic Society; European Respiratory Society: **American Thoracic Society/European Respiratory Society International Multidisciplinary Consensus Classification of the Idiopathic Interstitial Pneumonias. This joint statement of the American Thoracic Society (ATS), and the European Respiratory Society (ERS) was adopted by the ATS board of directors, June 2001 and by the ERS Executive Committee, June 2001.** *Am J Respir Crit Care Med.* 2002; **165**(2): 277–304.  
[PubMed Abstract](#) | [Publisher Full Text](#) | [F1000 Recommendation](#)
- Travis WD, Costabel U, Hansell DM, *et al.*: **An official American Thoracic Society/European Respiratory Society statement: Update of the international multidisciplinary classification of the idiopathic interstitial pneumonias.** *Am J Respir Crit Care Med.* 2013; **188**(6): 733–48.  
[PubMed Abstract](#) | [Publisher Full Text](#)
- Ryu JH, Colby TV, Hartman TE: **Idiopathic pulmonary fibrosis: current concepts.** *Mayo Clin Proc.* 1998; **73**(11): 1085–101.  
[PubMed Abstract](#) | [Publisher Full Text](#)
- Raghu G, Collard HR, Egan JJ, *et al.*: **An official ATS/ERS/JRS/ALAT statement: idiopathic pulmonary fibrosis: evidence-based guidelines for diagnosis and management.** *Am J Respir Crit Care Med.* 2011; **183**(6): 788–824.  
[PubMed Abstract](#) | [Publisher Full Text](#)
- Ryu JH, Moua T, Daniels CE, *et al.*: **Idiopathic pulmonary fibrosis: evolving concepts.** *Mayo Clin Proc.* 2014; **89**(8): 1130–42.  
[PubMed Abstract](#) | [Publisher Full Text](#)
- Vassallo R, Ryu JH: **Smoking-related interstitial lung diseases.** *Clin Chest Med.* 2012; **33**(1): 165–78.  
[PubMed Abstract](#) | [Publisher Full Text](#)
- Clinical Assembly contribution to the celebration of 20 years of the ERS, Balbi B, Cottin V, *et al.*: **Smoking-related lung diseases: a clinical perspective.** *Eur Respir J.* 2010; **35**(2): 231–3.  
[PubMed Abstract](#) | [Publisher Full Text](#)
- Wells AU, Nicholson AG, Hansell DM: **Challenges in pulmonary fibrosis - 4: smoking-induced diffuse interstitial lung diseases.** *Thorax.* 2007; **62**(10): 904–10.  
[PubMed Abstract](#) | [Publisher Full Text](#) | [Free Full Text](#)
- Caminati A, Harari S: **Smoking-related interstitial pneumonias and pulmonary Langerhans cell histiocytosis.** *Proc Am Thorac Soc.* 2006; **3**(4): 299–306.  
[PubMed Abstract](#) | [Publisher Full Text](#)
- Katzenstein AL, Fiorelli RF: **Nonspecific interstitial pneumonia/fibrosis. Histologic features and clinical significance.** *Am J Surg Pathol.* 1994; **18**(2): 136–47.  
[PubMed Abstract](#) | [Publisher Full Text](#)
- Fischer A, Antoniou KM, Brown KK, *et al.*: **An official European Respiratory Society/American Thoracic Society research statement: interstitial pneumonia with autoimmune features.** *Eur Respir J.* 2015; **46**(4): 976–87.  
[PubMed Abstract](#) | [Publisher Full Text](#) | [F1000 Recommendation](#)
- Chiba S, Tsuchiya K, Akashi T, *et al.*: **Chronic Hypersensitivity Pneumonitis With a Usual Interstitial Pneumonia-Like Pattern: Correlation Between Histopathologic and Clinical Findings.** *Chest.* 2016; **149**(6): 1473–81.  
[PubMed Abstract](#) | [Publisher Full Text](#) | [F1000 Recommendation](#)
- Morell F, Villar A, Montero MÁ, *et al.*: **Chronic hypersensitivity pneumonitis in patients diagnosed with idiopathic pulmonary fibrosis: a prospective case-cohort study.** *Lancet Respir Med.* 2013; **1**(9): 685–94.  
[PubMed Abstract](#) | [Publisher Full Text](#)
- Trahan S, Hanak V, Ryu JH, *et al.*: **Role of surgical lung biopsy in separating chronic hypersensitivity pneumonia from usual interstitial pneumonia/idiopathic pulmonary fibrosis: analysis of 31 biopsies from 15 patients.** *Chest.* 2008; **134**(1): 126–32.  
[PubMed Abstract](#) | [Publisher Full Text](#)
- Wells AU, Denton CP: **Interstitial lung disease in connective tissue disease --mechanisms and management.** *Nat Rev Rheumatol.* 2014; **10**(12): 728–39.  
[PubMed Abstract](#) | [Publisher Full Text](#) | [F1000 Recommendation](#)
- Yagihashi K, Huckleberry J, Colby TV, *et al.*: **Radiologic-pathologic discordance in biopsy-proven usual interstitial pneumonia.** *Eur Respir J.* 2016; **47**(4): 1189–97.  
[PubMed Abstract](#) | [Publisher Full Text](#) | [F1000 Recommendation](#)
- Hutchinson JP, Fogarty AW, McKeever TM, *et al.*: **In-Hospital Mortality after Surgical Lung Biopsy for Interstitial Lung Disease in the United States. 2000 to 2011.** *Am J Respir Crit Care Med.* 2016; **193**(10): 1161–7.  
[PubMed Abstract](#) | [Publisher Full Text](#) | [F1000 Recommendation](#)
- Maldonado F, Ryu JH: **Surgical biopsy for diffuse parenchymal lung diseases: are we causing more harm than good?** *J Bronchology Interv Pulmonol.* 2009; **16**(4): 227–8.  
[PubMed Abstract](#) | [Publisher Full Text](#)

23. **F** Kreider ME, Hansen-Flaschen J, Ahmad NN, *et al.*: **Complications of video-assisted thoracoscopic lung biopsy in patients with interstitial lung disease.** *Ann Thorac Surg.* 2007; **83**(3): 1140–4.  
[PubMed Abstract](#) | [Publisher Full Text](#) | [F1000 Recommendation](#)
24. **F** Tomassetti S, Wells AU, Costabel U, *et al.*: **Bronchoscopic Lung Cryobiopsy Increases Diagnostic Confidence in the Multidisciplinary Diagnosis of Idiopathic Pulmonary Fibrosis.** *Am J Respir Crit Care Med.* 2016; **193**(7): 745–52.  
[PubMed Abstract](#) | [Publisher Full Text](#) | [F1000 Recommendation](#)
25. **F** Fruchter O, Fridel L, El Raouf BA, *et al.*: **Histological diagnosis of interstitial lung diseases by cryo-transbronchial biopsy.** *Respirology.* 2014; **19**(5): 683–8.  
[PubMed Abstract](#) | [Publisher Full Text](#) | [F1000 Recommendation](#)
26. **F** Kropski JA, Pritchett JM, Mason WR, *et al.*: **Bronchoscopic cryobiopsy for the diagnosis of diffuse parenchymal lung disease.** *PLoS One.* 2013; **8**(11): e78674.  
[PubMed Abstract](#) | [Publisher Full Text](#) | [Free Full Text](#) | [F1000 Recommendation](#)
27. Hetzel J, Eberhardt R, Herth FJ, *et al.*: **Cryobiopsy increases the diagnostic yield of endobronchial biopsy: a multicentre trial.** *Eur Respir J.* 2012; **39**(3): 685–90.  
[PubMed Abstract](#) | [Publisher Full Text](#)
28. **F** Walsh SL, Wells AU, Desai SR, *et al.*: **Multicentre evaluation of multidisciplinary team meeting agreement on diagnosis in diffuse parenchymal lung disease: a case-cohort study.** *Lancet Respir Med.* 2016; **4**(7): 557–65.  
[PubMed Abstract](#) | [Publisher Full Text](#) | [F1000 Recommendation](#)
29. Flaherty KR, King TE Jr, Raghu G, *et al.*: **Idiopathic interstitial pneumonia: what is the effect of a multidisciplinary approach to diagnosis?** *Am J Respir Crit Care Med.* 2004; **170**(8): 904–10.  
[PubMed Abstract](#) | [Publisher Full Text](#)
30. Chinai N, Bintcliffe F, Armstrong EM, *et al.*: **Does every patient need to be discussed at a multidisciplinary team meeting?** *Clin Radiol.* 2013; **68**(8): 780–4.  
[PubMed Abstract](#) | [Publisher Full Text](#)
31. Kane B, Luz S, O'Briain DS, *et al.*: **Multidisciplinary team meetings and their impact on workflow in radiology and pathology departments.** *BMC Med.* 2007; **5**: 15.  
[PubMed Abstract](#) | [Publisher Full Text](#) | [Free Full Text](#)
32. Tattersall MH: **Multidisciplinary team meetings: where is the value?** *Lancet Oncol.* 2006; **7**(11): 886–8.  
[PubMed Abstract](#) | [Publisher Full Text](#)
33. Kassirer JP: **Teaching clinical reasoning: case-based and coached.** *Acad Med.* 2010; **85**(7): 1118–24.  
[PubMed Abstract](#) | [Publisher Full Text](#)
34. Norman G: **Building on experience—the development of clinical reasoning.** *N Engl J Med.* 2006; **355**(21): 2251–2.  
[PubMed Abstract](#) | [Publisher Full Text](#)
35. Scadding JG: **Diffuse pulmonary alveolar fibrosis.** *Thorax.* 1974; **29**(3): 271–81.  
[PubMed Abstract](#) | [Publisher Full Text](#) | [Free Full Text](#)
36. Collard HR, Moore BB, Flaherty KR, *et al.*: **Acute exacerbations of idiopathic pulmonary fibrosis.** *Am J Respir Crit Care Med.* 2007; **176**(7): 636–43.  
[PubMed Abstract](#) | [Publisher Full Text](#) | [Free Full Text](#)
37. **F** Chung A, Wright JL, Tazelaar HD: **Acute exacerbations of fibrotic interstitial lung disease.** *Histopathology.* 2011; **58**(4): 525–30.  
[PubMed Abstract](#) | [Publisher Full Text](#) | [F1000 Recommendation](#)
38. Parambil JG, Myers JL, Ryu JH: **Diffuse alveolar damage: uncommon manifestation of pulmonary involvement in patients with connective tissue diseases.** *Chest.* 2006; **130**(2): 553–8.  
[PubMed Abstract](#) | [Publisher Full Text](#)
39. **F** Collard HR, Ryerson CJ, Corte TJ, *et al.*: **Acute Exacerbation of Idiopathic Pulmonary Fibrosis. An International Working Group Report.** *Am J Respir Crit Care Med.* 2016; **194**(3): 265–75.  
[PubMed Abstract](#) | [Publisher Full Text](#) | [F1000 Recommendation](#)
40. **F** Ryerson CJ, Collard HR: **Acute exacerbations complicating interstitial lung disease.** *Curr Opin Pulm Med.* 2014; **20**(5): 436–41.  
[PubMed Abstract](#) | [Publisher Full Text](#) | [F1000 Recommendation](#)
41. Chung A, Muller NL, Silva CI, *et al.*: **Acute exacerbation (acute lung injury of unknown cause) in UIP and other forms of fibrotic interstitial pneumonias.** *Am J Surg Pathol.* 2007; **31**(2): 277–84.  
[PubMed Abstract](#) | [Publisher Full Text](#)
42. Parambil JG, Myers JL, Ryu JH: **Histopathologic features and outcome of patients with acute exacerbation of idiopathic pulmonary fibrosis undergoing surgical lung biopsy.** *Chest.* 2005; **128**(5): 3310–5.  
[PubMed Abstract](#) | [Publisher Full Text](#)

# Open Peer Review

Current Referee Status:



---

## Editorial Note on the Review Process

F1000 Faculty Reviews are commissioned from members of the prestigious F1000 Faculty and are edited as a service to readers. In order to make these reviews as comprehensive and accessible as possible, the referees provide input before publication and only the final, revised version is published. The referees who approved the final version are listed with their names and affiliations but without their reports on earlier versions (any comments will already have been addressed in the published version).

---

## The referees who approved this article are:

### Version 1

- Kevin Flaherty**, Division of Pulmonary and Critical Care Medicine, Department of Medicine, University of Michigan, Ann Arbor, MI, USA  
**Competing Interests:** No competing interests were disclosed.
- Dominique Valeyre**, <sup>1,2</sup> <sup>1</sup> Université Paris 13, Sorbonne Paris Cité, Bobigny, France  
<sup>2</sup> AP-HP, Pulmonary Department, Avicenne University Hospital, Bobigny, France  
**Competing Interests:** No competing interests were disclosed.
- Sergio Harari**, Unità Operativa di Pneumologia e Terapia Semi-Intensiva Respiratoria, Servizio di Fisiopatologia Respiratoria ed Emodinamica Polmonare, Ospedale San Giuseppe, Milan, Italy  
**Competing Interests:** No competing interests were disclosed.
- Yasuhiro Kondoh**, Department of Respiratory Medicine and Allergy, Tosei General Hospital, Aichi, Japan  
**Competing Interests:** No competing interests were disclosed.