

# Comparison of intraarticular injection of platelet-rich plasma following arthrocentesis, with sodium hyaluronate and conventional arthrocentesis for management of internal derangement of temporomandibular joint

## ABSTRACT

**Aim:** The aim of the study is to compare the efficacy of platelet-rich plasma (PRP) for the management of internal derangement of temporomandibular joint (TMJ).

**Settings and Design:** Thirty-three patients were selected from the pool of patients visiting the department of oral and maxillofacial surgery. Simple randomization was done.

**Subjects and Methods:** Patients with anterior disc displacement without reduction (DDWOR) were indicated for arthrocentesis. Group A patients are treated with PRP, Group B patients with sodium hyaluronate following arthrocentesis, and Group C patients were treated with arthrocentesis alone. Postoperative pain and maximal incisal opening are the primary outcomes evaluated.

**Statistical Analysis Used:** The collected data were analyzed with IBM. SPSS statistics software 23.0 version and the one-way ANOVA with Tukey's *post hoc* test were used.

**Results:** The mean age is 33 years, with female predominance. The statistical significant differences ( $P < 0.05$ ) in pain and MIO between the 3 groups at the end of 3<sup>rd</sup> week, 4<sup>th</sup> week, and 3<sup>rd</sup> month postoperatively are seen in PRP group comparative to other groups.

**Conclusions:** Our study has concluded that the intraarticular injection of PRP is an effective management for anterior DDWOR of TMJ than intraarticular injection of sodium hyaluronate and arthrocentesis in, reducing the pain and improving the interincisal distance in patients with DDWOR, thus providing a rapid recovery and improved quality of life.

**Keywords:** Arthrocentesis, internal derangement, platelet-rich plasma, TMJ

## INTRODUCTION

Internal derangement of the temporomandibular joint (TMJ) is an abnormal relationship of the articular disc to the glenoid fossa, mandibular condyle, and articular eminence and may include a deformation, perforation, or displacement of the disc and/or posterior attachment of the disc.<sup>[1] Heyl<sup>[2]</sup> in 1814 had previously used the term “internal derangement” to describe a localized mechanical fault interfering with smooth articular function. Internal derangements of the TMJ include disc displacements with reduction (DDWR) or disc displacement without reduction (DDWOR), often responsible for joint sounds, pain, and discomfort in the TMJ</sup>

**DIVYA SANJEEVI RAMAKRISHNAN,  
JANANI KANDAMANI, K. P. SENTHIL NATHAN**

Department of Oral and Maxillofacial Surgery, Saveetha Dental College, Chennai, Tamil Nadu, India

**Address for correspondence:** Dr. Divya Sanjeevi Ramakrishnan, 102, Tower 4 Coconut Groove Apartments, Vellalore Main Road, Singanallur, Coimbatore - 641 005, Tamil Nadu, India.  
E-mail: divyaramakrishnan55@gmail.com


**Received:** 21 May 2020, **Revised:** 02 September 2020,  
**Accepted:** 18 May 2021, **Published:** 15 June 2022

This is an open access journal, and articles are distributed under the terms of the Creative Commons Attribution-NonCommercial-ShareAlike 4.0 License, which allows others to remix, tweak, and build upon the work non-commercially, as long as appropriate credit is given and the new creations are licensed under the identical terms.

**For reprints contact:** WKHLRPMedknow\_reprints@wolterskluwer.com

**How to cite this article:** Ramakrishnan DS, Kandamani J, Nathan KP. Comparison of intraarticular injection of platelet-rich plasma following arthrocentesis, with sodium hyaluronate and conventional arthrocentesis for management of internal derangement of temporomandibular joint. *Natl J Maxillofac Surg* 2022;13:254-61.

### Access this article online

<b>Website:</b> www.njms.in	<b>Quick Response Code</b> 
<b>DOI:</b> 10.4103/njms.NJMS_94_20	

area. Displacement of the disc can present displacements in any direction, but anterior disc displacement is most common. In nonreducing displacement, the posterior band was positioned anteriorly to the condyle both with the mouth closed and opened.<sup>[3]</sup> This is important to maintain the stomatognathic system healthy; any alterations may lead to temporomandibular disorders (TMD).<sup>[4]</sup>

Disc displacement is the most frequent type of TMDs, including 41.1% of patients with TMD.<sup>[5,6]</sup> The common causes for TMJ ID are trauma and parafunctional habits which lead to degenerative changes in the articular structures, increased friction, and gradual disc displacement.<sup>[5,6]</sup> Chronic pain is the overwhelming reason for seeking TMD treatment, while TMD may also be associated with impaired general health, depression, or other psychological disabilities that affect the patient's general well-being,<sup>[7]</sup> which is the leading cause for the poor quality of life and functional disability in developing world. The common symptoms are pain in the preauricular area, limitations in jaw movements and clicking sound from TMJ.<sup>[8]</sup> Psychogenic factors have been implicated but, like trauma, malocclusion, joint laxity, after mandibular hyperextension resulting from yawning, overextension during dental treatment, third molar removal, intubation anesthesia, these are often considered as exacerbating factors rather than the primary cause of TMDs.<sup>[9]</sup>

The management of internal derangement includes conservative approaches and surgical approaches if the former fails. The conservative treatment indicated is occlusal appliance therapy,<sup>[10]</sup> and minimally invasive treatment such as arthrocentesis of the upper joint space with or without intraarticular medications such as corticosteroids,<sup>[11]</sup> sodium hyaluronate,<sup>[12]</sup> platelet-rich plasma (PRP)<sup>[3]</sup> which has shown promising results. This study was designed to assess the clinical outcomes of intraarticular injection of PRP and sodium hyaluronate following arthrocentesis with arthrocentesis alone for internal derangement of TMJ.

## SUBJECTS AND METHODS

Approval for the prospective randomized controlled clinical trial and clearance was obtained from the Institutional Ethical committee board. The Institutional Human Ethics Committee (IHEC) certificate number is as follows: [IHEC/SDC/MDS/003/02].

### Inclusion criteria

Clinical diagnosis of anterior DDWOR of TMJ according to diagnostic criteria for TMDs for clinical and research application. Radiological diagnosis by magnetic resonance

imaging, mandibular opening with assistance increased by 3 mm from unassisted opening, with a prior history of click. Contralateral movements <7 mm and/or uncorrected deviation to the ipsilateral side on opening, TMJ pain.

### Exclusion criteria

The presence of other disorders involving the TMJ (e.g. degenerative joint disease, or collagen vascular disease), history of major jaw trauma, dentofacial deformity, psychiatric illness, chronic headache.

### Setting and design

Thirty-three volunteer patients fitting the inclusion criteria described above were included in the study. The study participants were from the pool of patients in the department of oral and maxillofacial surgery. Simple block randomization was done to generate the sequence. Sequentially numbered, opaque, sealed envelope method was implemented for allocation concealment which conceals the sequence until interventions were assigned.

### Study groups

- Group A – Arthrocentesis with intraarticular injection of PRP
- Group B – Arthrocentesis with intraarticular injection of sodium hyaluronate
- Group C – Arthrocentesis.

### Procedure

The patient should be evaluated for tenderness in those areas in the head and neck accessible to palpation. Areas of tenderness trigger points and pain referral patterns are noted. If the splint therapy for 4 weeks failed to alleviate the symptoms, we proceeded for the minimally invasive treatment such as arthrocentesis of the TM joint cavity.

Intraarticular injection of PRP was preceded by collection of 10 ml peripheral blood added with anticoagulant. Centrifugation parameters were set to Remi 4c operator instructions. After separation of the erythrocyte mass and the platelet-poor and PRP layered directly above the erythrocytes, the PRP was aspirated with caution into a separate syringe. Calcium chloride as activator is added. Thus, prepared concentrate was ready for injection into the TMJ.

The patient was seated at a 45° angle, with the head turned towards the opposite side. The preauricular area was prepared with 5% povidone–iodine and draped following strict aseptic measures. Auriculotemporal nerve block was given through an insertion through the skin just anterior to the junction of the tragus and the ear lobe. The needle was advanced behind the posterior aspect of the condyle in

an anteromedial direction to a depth of 1 cm, and 2 ml of local anesthetic (2% Lignocaine with 1:200,000 Adrenaline, Xylocaine) was deposited after aspiration. The external auditory meatus on the side of the procedure was blocked with a cotton plug, and markings for needle insertion were placed using skin marking ink. A canthotragal line was drawn from the middle of the tragus to the lateral canthus. The posterior entrance point was located along the canthotragal line, 10 mm from the middle of the tragus and 2 mm below the line, and the anterior point of entry was placed 10 mm farther along the line and 5 mm below, i.e. 21 gauge needle syringe was inserted into the superior compartment of the joint using the posterior point as a guide. A second needle (21 gauge, Dispovan, India) was inserted with the anteriorly marked point as a guide (in the area of the articular eminence) to establish a free flow of the irrigating solution through the upper joint compartment. Then, the joint was irrigated with 100 ml of Ringer's lactate solution. Finally, before the anterior needle was removed depending on the group either 1 ml of sodium hyaluronate or 1 ml of autologous PRP, or no intervention was given in the joint space, following which the needle was withdrawn. The entry ports were covered with a sterile dressing for 2 h, and the patient was prescribed analgesics [Figures 1-5].

Patients were asked to rate their pain on a 10 numbered visual analog scale (VAS), 0 indicating no pain and 10 severe pain.

Maximal mouth opening was measured between the edges of the upper and lower central incisors by a millimeter ruler. Repeat measurements were performed on the 1<sup>st</sup> week, 2<sup>nd</sup> week, 3<sup>rd</sup> week, 4<sup>th</sup> week, and 3<sup>rd</sup> month postoperatively.

The collected data were analyzed with IBM SPSS (Statistical Product and Service Solutions), India 23.0 version. To describe the data, descriptive statistics, frequency analysis, and percentage analysis were used for categorical variables, and the mean and standard deviation was used for continuous variables. To find the significant difference in the multivariate analysis, the one-way ANOVA with Tukey's *post hoc* test was used. To find the significance in categorical data, Chi-square test was used. In all the above statistical tools, the probability value 0.005 is considered as a significant level.

## RESULTS

Patients experienced transient facial nerve weakness, temporary swelling over the TMJ for the few hours to the 1<sup>st</sup> day following procedures which were 0.66% and 0.99%, respectively.

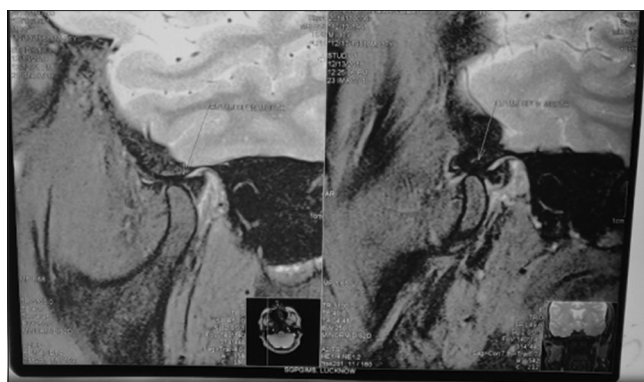


Figure 1: Magnetic resonance imaging showing disc displacement without reduction




Figure 2: Platelet-rich plasma sample after activation

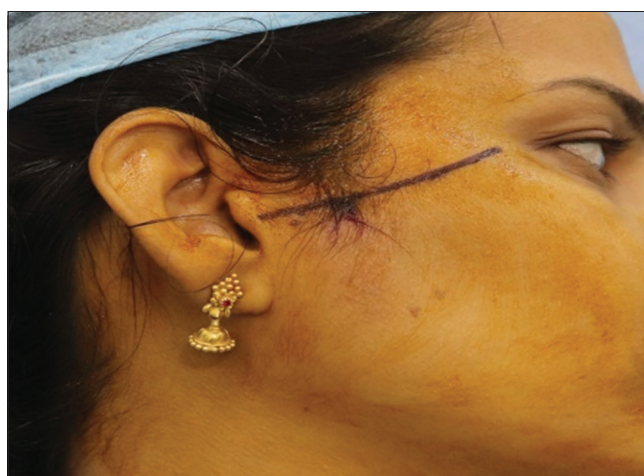

Figure 3: Canthotragal line marking

Graph 1 depicts the distribution of gender among study participants in Groups A, B, and C. About 36% of study participants were male and 64% were female.

Graph 2 depicts the mean age group among Groups A, B, and C. The mean age of Group A (PRP) is 30.3 years,

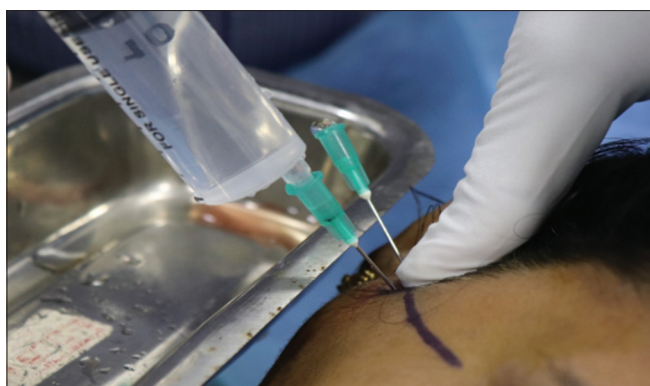
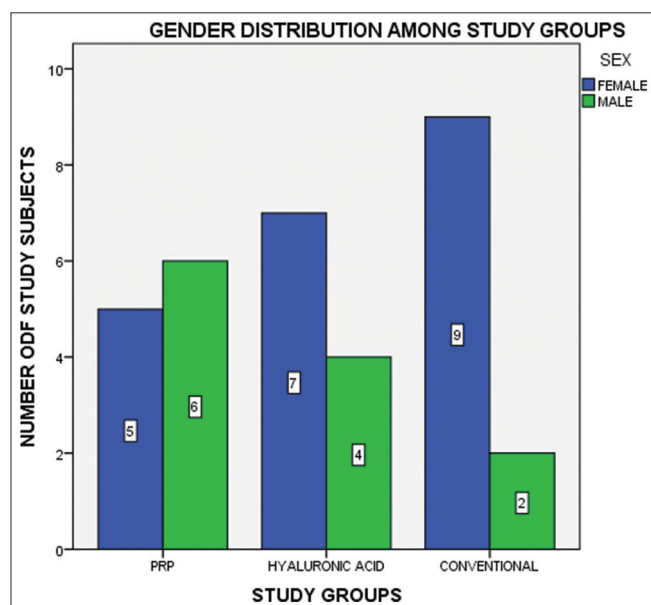


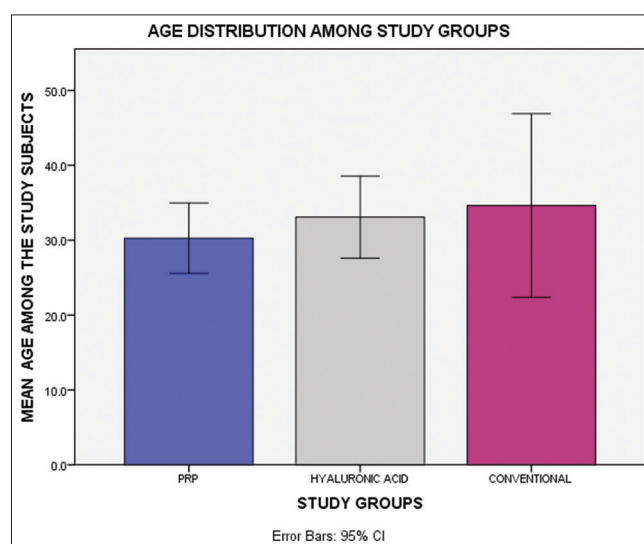
Figure 4: Arthrocentesis of joint cavity

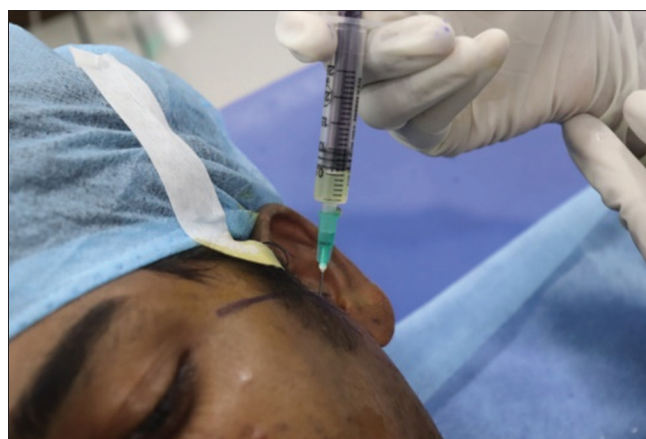

Figure 5: Injection of 1 ml of platelet-rich plasma



Graph 1: Distribution of gender among Groups A, B, and C - Graph caption



Graph 2: Comparison of mean age between Groups A, B, and C - Graph caption

Group B (HA) is 33.1 years, and Group C (control) is 34.6 years.

### Intergroup comparisons of various parameters at baseline and at different time points after intervention

#### Visual analog scale score

The differences in pain scores (VAS) between pre and postinjection were statistically significant ( $P < 0.005$ ) at 3<sup>rd</sup> week, 4<sup>th</sup> week, and 3<sup>rd</sup> month postoperative day (POD) between Group A (PRP), Group B (HA), and Group C (arthrocentesis). The most intense distinction was between preinjection ( $6.73 \pm 1.01$ ) and 4<sup>th</sup> week after injection ( $0.27 \pm 0.467$ ), and 3<sup>rd</sup> month after injection (0.00) was seen in Group A.

Table 1 depicts that mean preinjection and 4<sup>th</sup> week postinjection VAS values were statistically significant ( $P < 0.005$ ) at postoperative 3<sup>rd</sup> week, 4<sup>th</sup> week, and 3<sup>rd</sup> month between Group A (PRP), Group B (HA), and Group C (arthrocentesis).

Graph 3 depicts the comparison of mean VAS score between Groups A, B, and C at POD 1<sup>st</sup> week, 2<sup>nd</sup> week, 3<sup>rd</sup> week, 4<sup>th</sup> week, and 3<sup>rd</sup> month. The mean pain scores (VAS) between pre and postinjection were statistically significant ( $P < 0.005$ ) using multivariate analysis the one-way ANOVA with Tukey's *post hoc* test at 3<sup>rd</sup> week, 4<sup>th</sup> week, and 3<sup>rd</sup> month postoperative day between Group A (PRP), Group B (HA), and Group C (arthrocentesis). The most intense distinction was between preinjection ( $6.73 \pm 1.01$ ) and 4<sup>th</sup> week after injection ( $0.27 \pm 0.467$ ), at 3<sup>rd</sup> month (0.00) was seen in Group A.

MIO: Mean preinjection and 1-month postinjection MIO values were statistically significant ( $P < 0.005$ ) at 3<sup>rd</sup> week, 4<sup>th</sup> week, and 3<sup>rd</sup> month postoperative day between Group A (PRP), Group B (HA), and Group C (arthrocentesis). The most intense distinction was between preinjection ( $27.91 \pm 3.14$  mm), and 3<sup>rd</sup> month after injection ( $44.27 \pm 0.64$  mm) was seen in Group A.

**Table 1: Depicting the visual analog scale comparison by repeated measures of ANOVA**

Groups	Mean	P
Preoperative		
Group A	6.73	0.906#
Group B	6.55	
Group C	6.64	
POD 1 <sup>st</sup> week		
Group A	4.91	0.752#
Group B	5.09	
Group C	5.27	
POD 2 <sup>nd</sup> week		
Group A	3.36	0.703#
Group B	3.45	
Group C	3.64	
POD 3 <sup>rd</sup> week		
Group A	1.27	0.0005**
Group B	3.09	
Group C	3.45	
POD 4 <sup>th</sup> week		
Group A	0.27	0.0005**
Group B	2.18	
Group C	2.36	
POD 3 <sup>rd</sup> month		
Group A	0	0.0005**
Group B	0.27	
Group C	0.55	

POD: Postoperative day. \*\*Highly statistical significance, #Not statistically significant

**Table 2: Depicting maximal interincisal opening comparison by repeated measures of ANOVA**

Groups	Mean	P
Preoperative		
Group A	27.91	0.910#
Group B	27.82	
Group C	27.45	
POD 1 <sup>st</sup> week		
Group A	32.27	0.529#
Group B	31.36	
Group C	31.27	
POD 2 <sup>nd</sup> week		
Group A	36.45	0.238#
Group B	35.64	
Group C	34.64	
POD 3 <sup>rd</sup> week		
Group A	40.55	0.001**
Group B	38.00	
Group C	37.36	
POD 4 <sup>th</sup> week		
Group A	43.36	0.0005**
Group B	39.82	
Group C	39.27	
POD 3 <sup>rd</sup> month		
Group A	44.27	0.0005**
Group B	40.55	
Group C	39.55	

POD: Postoperative day. \*\*Highly statistical significance, #Not statistically significant

Table 2 depicts that mean preinjection and 4<sup>th</sup> week postinjection MIO values were statistically significant ( $P < 0.005$ ) at postoperative 3<sup>rd</sup> week and 4<sup>th</sup> week between Group A (PRP), Group B (HA), and Group C (arthrocentesis).

Graph 4 depicts the comparison of MIO score between Groups A, B, and C at POD 1<sup>st</sup> week, 2<sup>nd</sup> week, 3<sup>rd</sup> week, and 4<sup>th</sup> week. Mean preinjection and 1-month postinjection MIO values were statistically significant ( $P < 0.005$ ) using multivariate analysis the one-way ANOVA with Tukey's *post hoc* test at 3<sup>rd</sup> week, 4<sup>th</sup> week, and 3<sup>rd</sup> month postoperative day between Group A (PRP), Group B (HA), and Group C (arthrocentesis). The most intense distinction was between preinjection ( $27.91 \pm 3.14$  mm), and 3<sup>rd</sup> month after injection ( $44.27 \pm 0.64$  mm) was seen in Group A.

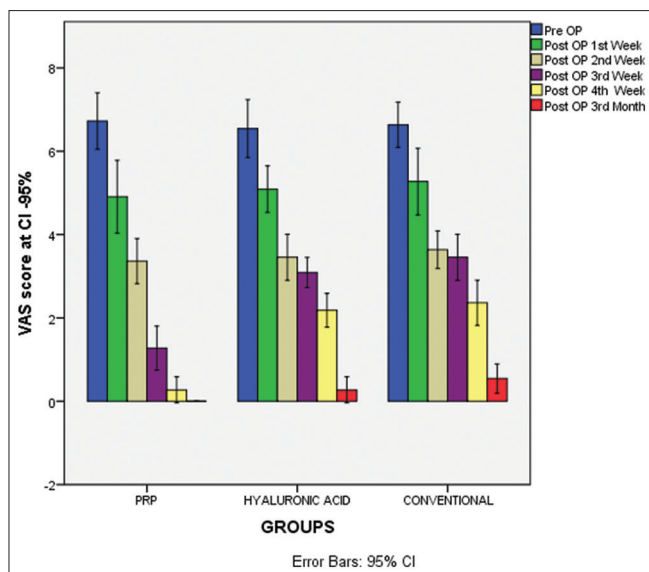
### DISCUSSION

In symptomatic DDWOR, patients can experience pain and reduced jaw mobility,<sup>[13]</sup> being the arthrocentesis an effective treatment option for DDWOR when conservative methods are no longer efficient.<sup>[14]</sup> The results of the present study showed that DDWOR patients who underwent arthrocentesis had reduction un pain intensity, MIO increased which was statistically significant at the 3<sup>rd</sup>, 4<sup>th</sup> week, and 3<sup>rd</sup> month postoperatively ( $P < 0.0005$ ), which rejected the null hypothesis.

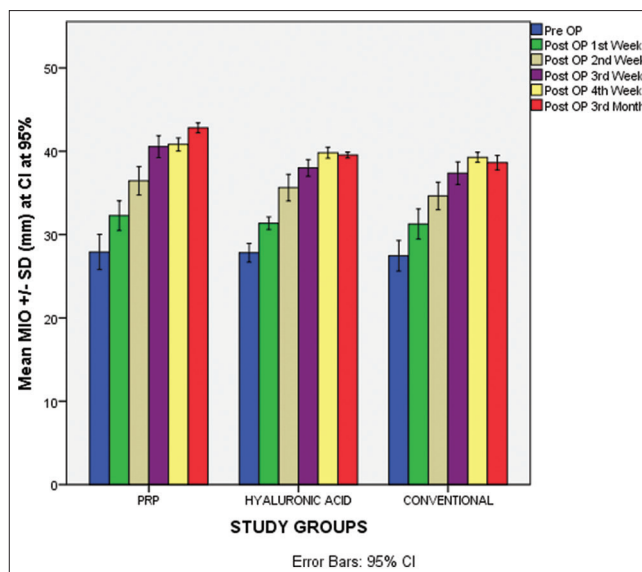
The reduction of the pain is expected as the irrigation process, conducted with biocompatible substances, allows the removal of debris of the joint tissues in degeneration and eliminates allogeneic substances, mainly inflammatory mediators.<sup>[14-16]</sup> The arthrocentesis is considered to be effective as the reduction of the levels of these mediators is achieved with the lavage.<sup>[17]</sup> the proper use of this technique is highly important to achieve good results.

Despite reducing pain, the arthrocentesis performed under pressure may also present other benefits to the patient, as it removes adhesences,<sup>[18]</sup> eliminates the negative pressure in the joint,<sup>[19]</sup> distends the joint space, recovering the space of the joint disc and fossa, changes the viscosity of the synovial liquid, helps in the translation of the joint disc and condyle,<sup>[20]</sup> and consequently, enlarges mouth opening.<sup>[21]</sup>

After arthrocentesis, our PRP group patients experienced an increase in the maximum mouth opening, from  $27.91 \pm 3.14$  mm to  $44.27 \pm 0.64$  mm ( $P < 0.0005$ ) at 3<sup>rd</sup> month postoperative, similar to what has been found in other studies (from  $23.7 \pm 2.91$  mm to  $41.05 \pm 2.91$  mm)<sup>[22]</sup> and (from  $32.13 \pm 9.86$  mm to  $46.6 \pm 2.56$ ).<sup>[23]</sup>



Graph 3: Comparison of visual analog scale score between Groups A, B, and C



Graph 4: Comparison of MIO Score between Groups A, B, and C

Within time, the displaced joint disc becomes significantly deformed, and the retrodiscal tissue becomes less flexible and more fibrous, which does not allow it to reposition itself along the condyle, both in open and closed mouth.<sup>[13]</sup> The change in the position of the disc in DDWOR after arthrocentesis can be observed in the techniques where one or two needles were used.<sup>[24]</sup> However, this is not necessary to relieve the pain and restore the proper function of the joint in patients with DDWOR<sup>[25]</sup> being the normalization of the functionality more important than the re-establishment of the joint anatomy. It was proposed that lavage and lysis of the upper joint space would eliminate the vacuum effect and alter the viscosity of the synovial fluid, thereby aiding translation of the disc and the condyle.<sup>[26]</sup>

Intraarticular injection of drugs is an effective way to treat DDWOR.<sup>[27]</sup> Studies of TMJ injections have focused on decreased pain after injection in patients with both pain and limited mouth opening secondary to inflammatory disorders of the joint, such as arthritis and capsulitis.<sup>[28,16]</sup>

PRP is also known as platelet-rich growth factors (GFs), platelet-rich fibrin (PRF) matrix, PRF, and platelet concentrate. PRP is a biological product defined as a portion of the plasma fraction of autologous blood with a platelet concentration above the baseline (before centrifugation).<sup>[29]</sup>

PRP is a natural source of signaling molecules, and upon activation of platelets in PRP, the P-granules are degranulated and release the GFs and cytokines that will modify the pericellular microenvironment. Some of the most important GFs released by platelets in PRP include vascular

endothelial GF, fibroblast GF, platelet-derived GF, epidermal GF, hepatocyte GF, insulin-like GF 1, 2 (insulin-like growth factor [IGF]-1, IGF-2), matrix metalloproteinases 2, 9, and interleukin 8.<sup>[30]</sup>

PRP has recently been used successfully for the treatment of knee degenerative pathologic disorders because it is safe and has the potential to reduce pain and improve function.<sup>[31]</sup> PRP has recently been considered as an ortho biological adjuvant treatment. It also restores intraarticular hyaluronic acid, increases glycosaminoglycan chondrocyte synthesis, balances joint angiogenesis, and provides a scaffold for stem cell migration. Basic scientific studies have indicated that PRP stimulates cell proliferation and the production of cartilage matrix by chondrocytes and bone marrow-derived mesenchymal stromal cells and increases the production of hyaluronic acid by synovioocytes.<sup>[32]</sup>

It has shown that intraarticular injection of PRP has a statistically significant reduction in pain intensity and joint sound and an increase in mouth opening in the study group when compared with the control group in DDWR patients.<sup>[33]</sup>

The data of our study revealed that intraarticular injection PRP shows improvement rates in a short time at the 1<sup>st</sup> postoperative month and was followed by a more gradual increase in terms of postoperative pain from  $6.73 \pm 1.01$  to  $0.27 \pm 0.467$  at 4<sup>th</sup> week and 0.00 at 3<sup>rd</sup> month. Therefore, the optimal duration of this therapy is considered to up to 6–12 months. Thus, reinforcing our result, it can relieve the clinical symptoms in the short term and possibly prevent TMJ disease progression, especially for DDWOR. Due to the

fact that PRP is a natural source of autologous GFs, it also improves cartilage repair in degenerative knee pathologic disorder.<sup>[34]</sup>

HA is a high-molecular-weight glycosaminoglycan naturally present in synovial fluid and participates in joint lubrication. Injections of HA have been widely used in the treatment of TMDs in single-dose or repeated or associated with other procedures, such as arthrocentesis or arthroscopy, and several published studies show positive and encouraging results in improvement of mouth opening and pain relief.<sup>[12]</sup>

The data of our study revealed that improvement rates increased in intraarticular injection of sodium hyaluronate in the 1<sup>st</sup> postoperative month in terms of postoperative pain from  $6.55 \pm 1.04$  to  $0.27 \pm 0.4$  at 3<sup>rd</sup>. Even though these results show that HA has superior results than arthrocentesis alone, although not significant when compared to intraarticular injection of PRP.

The male: female ratio (3.63%:6.93%) of the present study shows a strong female predominance. This relationship is expected since it has been shown to be more common in women than men. The higher occurrence of DDWOR in women can be explained by gender features such as greater joint laxity, increased intra-articular pressure, and periodical hormonal changes.<sup>[35]</sup>

In the present study, transient facial nerve weakness was encountered in 0.66% and swelling in 0.99% of patients in the immediate postoperative period. The minimally invasive character of the arthrocentesis produces less postoperative morbidity if compared with other surgical techniques for the TMJ. Transient facial nerve paralysis caused by local anesthesia and swelling of the preauricular area due to fluid extravasation may result from arthrocentesis. The literature has reported some risks, such as: extravasation of liquid to the surrounding tissue, lesion of the facial nerve, optical lesion, preauricular hematoma, arteriovenous fistula, trans articular perforation, intracranial perforation, extradural hematoma, and intra-articular problems.<sup>[36]</sup>

After the procedure, the patients were not recommended to use the occlusal splints or any other treatment during the follow-up period, so that there would be no interference in the interpretation of the results.

The limitations of the present study would be lack of long-term follow-up and larger sample size in patients with anterior DDWOR.

## CONCLUSIONS

Management of internal derangement of TMJs has generated worldwide controversies having arrived with no consensus. PRP has been used in various fields of modern medicine for its invaluable regenerative properties, and only a very few studies have been conducted to assess its role in internal derangement of TMJ.

Our study has concluded that the intraarticular injection of PRP is an effective management for anterior DDWOR of TMJ than intraarticular injection of sodium hyaluronate and arthrocentesis in, reducing the pain, increasing interincisal distance, in patients with DDWOR. Thus, these benefits provide a rapid recovery and improved quality of life.

Within the limitations of our study, the use of PRP in anterior DDWOR should be evaluated in a larger population with long-term follow-up for potential benefits considering the scientific lacunae for the use of PRP in the management of anterior DDWOR.

## Declaration of patient consent

The authors certify that they have obtained all appropriate patient consent forms. In the form, the patient has given her consent for her images and other clinical information to be reported in the journal. The patient understands that his name and initials will not be published and due efforts will be made to conceal identity, but anonymity cannot be guaranteed.

## Financial support and sponsorship

Nil.

## Conflicts of interest

There are no conflicts of interest.

## REFERENCES

1. Laskin DM, Greene CS, Hylander WL, editors. Temporomandibular disorders: an evidence-based approach to diagnosis and treatment. Quintessence Publishing Company; 2006.
2. Hey W. Practical Observations in Surgery, Illustrated by Cases. James Humphreys; 1805.
3. Al-Delayme RM, Alnuamy SH, Hamid FT, Azzamily TJ, Ismaeel SA, Sammir R, *et al.* The efficacy of platelets rich plasma injection in the superior joint space of the temporomandibular joint guided by ultra sound in patients with non-reducing disk displacement. *J Maxillofac Oral Surg* 2017;16:43-7.
4. Comisso MS, Martínez-Reina J, Ojeda J, Mayo J. Finite element analysis of the human mastication cycle. *J Mech Behav Biomed Mater* 2015;41:23-35.
5. Dijkgraaf LC, de Bont LG, Boering G, Liem RS. Structure of the normal synovial membrane of the temporomandibular joint: A review of the literature. *J Oral Maxillofac Surg* 1996;54:332-8.

6. Dijkgraaf LC, De Bont LG, Boering G, Liem RS. Function, biochemistry, and metabolism of the normal synovial membrane of the temporomandibular joint: A review of the literature. *J Oral Maxillofac Surg* 1996;54:95-100.
7. Dworkin SF, LeResche L. Research diagnostic criteria for temporomandibular disorders: Review, criteria, examinations and specifications, critique. *J Craniomandib Disord* 1992;6:301-55.
8. LeResche L. Epidemiology of temporomandibular disorders: Implications for the investigation of etiologic factors. *Crit Rev Oral Biol Med* 1997;8:291-305.
9. Ahmad M, Schiffman EL. Temporomandibular joint disorders and orofacial pain. *Dent Clin North Am* 2016;60:105-24.
10. Lundh H, Westesson PL, Eriksson L, Brooks SL. Temporomandibular joint disk displacement without reduction. Treatment with flat occlusal splint versus no treatment. *Oral Surg Oral Med Oral Pathol* 1992;73:655-8.
11. Fouda AA. Association between intra-articular corticosteroid injection and temporo-mandibular joint structure changes. *Int Arch Oral Maxillofac Surg* 2018;2:015.
12. Alpaslan GH, Alpaslan C. Efficacy of temporomandibular joint arthrocentesis with and without injection of sodium hyaluronate in treatment of internal derangements. *J Oral Maxillofac Surg* 2001;59:613-8.
13. Kurita K, Westesson PL, Yuasa H, Toyama M, Machida J, Ogi N. Natural course of untreated symptomatic temporomandibular joint disc displacement without reduction. *J Dent Res* 1998;77:361-5.
14. Tatli U, Benlidayi ME, Ekren O, Salimov F. Comparison of the effectiveness of three different treatment methods for temporomandibular joint disc displacement without reduction. *Int J Oral Maxillofac Surg* 2017;46:603-9.
15. Song YL, Yap AU. Outcomes of therapeutic TMD interventions on oral health related quality of life: A qualitative systematic review. *Quintessence Int* 2018;49:487-96.
16. Grossmann E, Poluha RL, Iwaki LCV, Santana RG, Filho LI. Predictors of arthrocentesis outcome on joint effusion in patients with disk displacement without reduction. *Oral Surg Oral Med Oral Pathol Oral Radiol* 2018;125:382-8.
17. Tvrdy P, Heinz P, Pink R. Arthrocentesis of the temporomandibular joint: A review. *Biomed Papers* 2015;159:031-4.
18. Yura S, Totsuka Y, Yoshikawa T, Inoue N. Can arthrocentesis release intracapsular adhesions? Arthroscopic findings before and after irrigation under sufficient hydraulic pressure. *J Oral Maxillofac Surg* 2003;61:1253-6.
19. Yura S, Totsuka Y. Relationship between effectiveness of arthrocentesis under sufficient pressure and conditions of the temporomandibular joint. *J Oral Maxillofac Surg* 2005;63:225-8.
20. Sembronio S, Albiero AM, Toro C, Robiony M, Politi M. Is there a role for arthrocentesis in recapturing the displaced disc in patients with closed lock of the temporomandibular joint? *Oral Surg Oral Med Oral Pathol Oral Radiol Endod* 2008;105:274-80.
21. Nitzan DW. Arthrocentesis – Incentives for using this minimally invasive approach for temporomandibular disorders. *Oral Maxillofac Surg Clin North Am* 2006;18:311-28, vi.
22. Malik AH, Shah AA. Efficacy of temporomandibular joint arthrocentesis on mouth opening and pain in the treatment of internal derangement of TMJ – A clinical study. *J Maxillofac Oral Surg* 2014;13:244-8.
23. Chandrashekhkar VK, Kenchappa U, Chinnannavar SN, Singh S. Arthrocentesis A minimally invasive method for TMJ disc disorders – A prospective study. *J Clin Diagn Res* 2015;9:C59-62.
24. Pasqual PG, Poluha RL, Setogutti ET, Grossmann E. Evaluation of effusion and articular disc positioning after two different arthrocentesis techniques in patients with temporomandibular joint disc displacement without reduction. *Cranio* 2020;38:256-63.
25. Moses JJ, Sartoris D, Glass R, Tanaka T, Poker I. The effect of arthroscopic surgical lysis and lavage of the superior joint space on TMJ disc position and mobility. *J Oral Maxillofac Surg* 1989;47:674-8.
26. Ohnuki T, Fukuda M, Nakata A, Nagai H, Takahashi T, Sasano T, *et al.* Evaluation of the position, mobility, and morphology of the disc by MRI before and after four different treatments for temporomandibular joint disorders. *Dentomaxillofac Radiol* 2006;35:103-9.
27. Li C, Zhang Y, Lv J, Shi Z. Inferior or double joint spaces injection versus superior joint space injection for temporomandibular disorders: A systematic review and meta-analysis. *J Oral Maxillofac Surg* 2012;70:37-44.
28. Møystad A, Mork-Knutsen BB, Bjørnland T. Injection of sodium hyaluronate compared to a corticosteroid in the treatment of patients with temporomandibular joint osteoarthritis: A CT evaluation. *Oral Surg Oral Med Oral Pathol Oral Radiol Endod* 2008;105:e53-60.
29. Alves R, Grimalt R. Randomized placebo-controlled, double-blind, half-head study to assess the efficacy of platelet-rich plasma on the treatment of androgenetic alopecia. *Dermatol Surg* 2016;42:491-7.
30. Andia I, Abate M. Platelet-rich plasma: Underlying biology and clinical correlates. *Regen Med* 2013;8:645-58.
31. Sampson S, Reed M, Silvers H, Meng M, Mandelbaum B. Injection of platelet-rich plasma in patients with primary and secondary knee osteoarthritis: A pilot study. *Am J Phys Med Rehabil* 2010;89:961-9.
32. Hegab AF, Ali HE, Elmasry M, Khallaf MG. Platelet-rich plasma injection as an effective treatment for temporomandibular joint osteoarthritis. *J Oral Maxillofac Surg* 2015;73:1706-13.
33. Hancı M, Karamese M, Tosun Z, Aktan TM, Duman S, Savacı N. Intra-articular platelet-rich plasma injection for the treatment of temporomandibular disorders and a comparison with arthrocentesis. *J Craniomaxillofac Surg* 2015;43:162-6.
34. Kon E, Buda R, Filardo G, Di Martino A, Timoncini A, Cenacchi A, *et al.* Platelet-rich plasma: Intra-articular knee injections produced favorable results on degenerative cartilage lesions. *Knee Surg Sports Traumatol Arthrosc* 2010;18:472-9.
35. Lazarin Rd, Previdelli IT, Silva Rd, Iwaki LC, Grossmann E, Filho LI. Correlation of gender and age with magnetic resonance imaging findings in patients with arthrogenic temporomandibular disorders: A cross-sectional study. *Int J Oral Maxillofac Surg* 2016;45:1222-8.
36. Vaira LA, Raho MT, Soma D, Salzano G, Dell'aversana Orabona G, Piombino P, *et al.* Complications and post-operative sequelae of temporomandibular joint arthrocentesis. *Cranio* 2018;36:264-7.