



OPEN

## Investigation of a connection between abdominal wall defects and severity of the herniation in fetuses with gastroschisis and omphalocele

Natasha T. Logsdon, Carla M. Gallo, Luciano Alves Favorito<sup>✉</sup> & Francisco J. Sampaio

Analyze the biometric parameters and the size (area) of abdominal wall defect (AWD) in fetuses with gastroschisis and omphaloceles and correlate them with the herniated internal organs. We studied 22 fetuses (11 with AWDs and 11 without anomalies). In all fetuses we evaluated the xiphopubic distance (XPD) and iliac crest distance (ICD). In fetuses with AWDs we dissected the abdominal wall and measured the width and length of the defect for calculating its area and studying the correlation between the size of the defect with the organs that were herniated. For statistical analysis, the Anova and Tukey post-test were used ( $p < 0.05$ ). The XPD in the control group had mean of 4.2 mm (2.3–5.9;  $SD \pm 1.11$ ), while in the AWDs it was 4.2 mm (2.9–5.5;  $SD \pm 0.98$ ) ( $p = 0.4366$ ). The ICD had mean values of 2.5 mm (1.6–3.4;  $SD \pm 0.58$ ) in the control group, and 2.3 mm (1.2–3.0;  $SD \pm 0.56$ ) in AWDs fetuses ( $p = 0.6963$ ). The number of herniate organs do not have significant correlation with the area of the defect ( $r^2 = 0.2504$ ,  $p = 0.5068$ ). There is no correlation between the size (area) of abdominal wall defects and the number of the internal organs that herniated. Therefore, the hole size is not a predictor of the severity of the gastroschisis or omphalocele.

### Abbreviations

ADA	Abdominal defect area
AWD	Abdominal wall defect
AWDs	Abdominal wall defects
CAAE	Certificate of ethical appreciation presentation
CEP	Ethical Committee on Human Research
CNPQ	National Council for Scientific and Technological Development
CONEP	National Research Ethics Commission
CRL	Crown-rump length
FAPERJ	Rio de Janeiro State Research Foundation
HUPE	Pedro Ernesto University Hospital
ICD	Iliac crest distance
IRB	Institutional Review Board
mm	Millimeters
mm <sup>2</sup>	Square millimeters
p	P-value
r <sup>2</sup>	Pearson correlation coefficient
SD	Standard deviation
Vs.	Versus
WPC	Weeks post conception
XPD	Xiphopubic distance

Urogenital Research Unit, State University of Rio de Janeiro, Rua Professor Gabizo, 104/201, Tijuca, Rio de Janeiro, RJ CEP 20271-320, Brazil. ✉email: lufavorito@Yahoo.com.br

Abdominal wall defects (AWDs) are common human birth anomalies with incidence of about 1 in 2000 newborns<sup>1</sup>. The AWDs that occur most commonly are gastroschisis and omphalocele<sup>2</sup>. Gastroschisis is a paraumbilical AWD associated with protrusion of the abdominal content through a defect, usually in the right side, without a covering membrane. Omphalocele is a AWD at the umbilicus, and the viscera outside the belly are covered by a membrane<sup>2–4</sup>. Patients with AWDs have an increased incidence of intrauterine growth restriction, and, therefore, the estimation of weight in fetuses with AWDs during gestational ultrasonography is more difficult than for normal fetuses<sup>5–7</sup>.

The abdominal wall develops from somitic and lateral plate mesoderm. Ventral body wall defects are originated from lateral plate mesoderm malformations<sup>8</sup>. The rectus abdominal muscle and rectus sheath are very important to physiological umbilical hernia closure during the abdominal wall development<sup>9,10</sup>. In omphalocele and gastroschisis, the rectus muscle was intact but inserted more laterally on the costal margins and xiphoid process<sup>8</sup>.

To our knowledge, there are no reports about the abdominal wall biometric parameters in human fetuses with AWDs. The objective of this study was to analyze the biometric parameters of the abdominal wall in AWDs fetuses and to compare them with the parameters of fetuses without anomalies. Also, we aimed to analyze the size (area) of abdominal wall defect in fetuses with AWDs and correlate it with the herniated organs.

## Methods

The fetuses used in this study (both Controls and with AWDs) were obtained from the Department of Pathology of the Fernandes Figueira Institute, Oswaldo Cruz Foundation, Ministry of Health, in partnership with our University, via an official Cooperation Term.

The study was approved by the Ethical Committee on Human Research—University Hospital of the State University of Rio de Janeiro (CEP / HUPE), with the number IRB: 2.770.641, CAAE: 89602318.4.0000.5259).

The study has also been registered in the Brazil Platform, Ministry of Health, National Health Council, National Research Ethics Commission (CONEP) for studies with human beings. We confirm that all methods used in this paper were carried out in accordance with relevant guidelines and regulation.

We studied 11 human fetuses with AWDs, aged 15.3 to 27.4 weeks post conception (WPC), and 11 fetuses without anomalies (Controls) aged 13.2 to 18.8 WPC, during the period from March 2017 to February 2020. All fetuses were well preserved and have been demised due to spontaneous or induced abortion. The gestational age of the fetuses was determined in weeks post conception (WPC) according to the foot-length criterion, which is currently considered the most acceptable parameter to estimate the fetal gestational age<sup>11–13</sup>.

The fetuses were biometrically evaluated considering their total length, the crown-rump length (CRL) and the body weight.

After these measurements, the fetuses were photographed and carefully dissected with the aid of a stereoscopic lens with 16–25× magnification. Two abdominal wall measures were recorded with a digital pachymeter in all 22 fetuses: xiphopubic distance (XPD) and the iliac crest distance (ICD) (Fig. 1A,B).

In the AWDs fetuses, we dissected and analyzed the abdominal wall defect as well as the number and kind of abdominal organs that were herniated. Figure 1C shows a typical aspect of an AWD fetus with omphalocele. The length and width of the abdominal wall defect were measured with a digital pachymeter (Fig. 1D), for calculating the area of the defect (Length × Width × 3.1416). The same observer performed all measurements.

**Statistical analysis.** All parameters were statistically processed and graphically presented. Descriptive statistics were calculated and the values of age, weight, CRL, XPD and ICD are presented as means, followed by standard deviations (SD). The data were analyzed by the use of ANOVA and the Tukey post-test to compare variances among the groups. Differences were considered statistically significant when p-values were below 0.05. For the correlation of abdominal distances (XPD and ICD) and other variables, Pearson's correlation coefficient was used considering  $r^2$  greater than 0.7 as strong correlation, while  $r^2$  between 0.4 and 0.7 reflected moderate correlation and  $r^2$  less than 0.4 reflected weak or very weak correlation. The statistical analysis was performed with the GraphPad Prism program (Version 8.0.1).

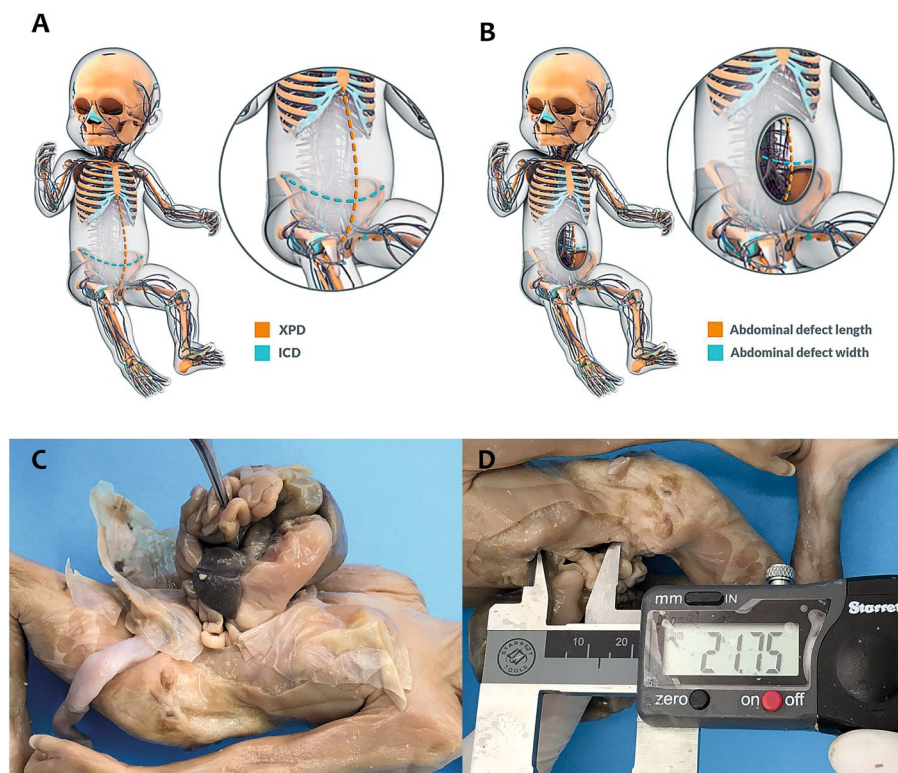
## Results

The statistical analysis of all fetal and abdominal biometric parameters is reported in Table 1.

The mean xiphopubic distance was 4.2 mm (2.3–5.9; SD ± 1.11) in the control group and 4.2 mm (2.9–5.5; SD ± 0.98) in the AWD fetuses, without significant differences between the groups ( $p = 0.4366$ ). The mean distance between the iliac crests was 2.5 mm (1.6–3.4; SD ± 0.58) in the control group and 2.3 mm (1.2–3.0; SD ± 0.56) in AWD fetuses, without significant differences between the groups ( $p = 0.6963$ ).

The size (length and width) as well as, the area of the hole in fetuses with AWDs, and the description of the abdominal organs that were herniated in these 11 cases are shown in Table 2. The hole in AWD had a mean length of 23.52 mm (13.46–35.14) and a mean width of 14.05 mm (7.33–25.83). The mean area of the hole was 1124.03 mm<sup>2</sup> (379.30–2603.13).

The linear regression analysis indicated that the XPD in the Control group ( $r^2 = 0.6837$ ;  $p = 0.0017$ ) and in the AWD group ( $r^2 = 0.6106$ ;  $p = 0.0045$ ) increased significantly and positively with fetal age ( $p < 0.0001$ ) (Table 3). The ICD also increased significantly and positively with fetal age in the Control group ( $r^2 = 0.466$ ;  $p = 0.0255$ ) and in the AWD group ( $r^2 = 0.6742$ ;  $p < 0.0019$ ) (Table 3). The XPD in the Control group ( $r^2 = 0.8161$ ;  $p = 0.0001$ ) and in AWD group ( $r^2 = 0.4919$ ;  $p = 0.0162$ ) increased significantly and positively with fetal weight (Table 3). The ICD also increased significantly and positively with fetal weight in the AWD group ( $r^2 = 0.5453$ ;  $p = 0.0094$ ), but only the Control group had strong correlation with fetal weight (control group:  $r^2 = 0.8161$ ;  $p = 0.0001$ ) (Table 3).



**Figure 1.** Morphometric evaluation of abdominal wall in controls and fetuses with abdominal wall defects (AWDs). (A) Schematic drawing showing the measurements of xiphopubic distance (XPD) and iliac crest distance (ICD); (B) schematic drawing showing the measurements of the length and the width of the defect in the abdominal wall in a fetus with AWD; (C) male fetus with 15 weeks post conception (WPC) with omphalocele, showing the dissected membrane and the defect in the anterior abdominal wall, with herniated abdominal organs; (D) male fetus with 15 WPC with a dissected omphalocele, showing the measurements of the abdominal wall defect with a digital pachymeter.

Parameter	Controls	AWDs	p Value
Age (WPC)	13.2–18.8 (mean = 15.7/SD ± 1.83)	15.3–27.4 (mean = 19.5/SD ± 4.76)	0.0049
Weight (g)	58.0–344.0 (mean = 172.3/SD ± 94.67)	90.02728.0 (mean = 786.6/SD ± 1056.1)	0.0227
CRL (cm)	9.0–19.0 (mean = 14.8/SD ± 3.12)	7.0–25.0 (mean = 15.9/SD ± 6.28)	0.0349
XPD (mm)	2.3–5.9 (mean = 4.2/SD ± 1.11)	2.9–5.5 (mean = 4.2/SD ± 0.98)	0.4366
ICD (mm)	1.6–3.4 (mean = 2.5/SD ± 0.58)	1.2–3.0 (mean = 2.3/SD ± 0.56)	0.6963

**Table 1.** Statistical analysis of fetal and abdominal wall biometric parameters. AWDs abdominal wall defects, CRL crown-rump length, XPD xiphopubic distance, ICD iliac crest distance.

The linear regression analysis indicated that the XPD in the Control group ( $r^2 = 0.7394$ ;  $p < 0.0007$ ) and in the AWD group ( $r^2 = 0.4823$ ;  $p < 0.0177$ ) increased significantly and positively with fetal CRL. Also, the ICD in the Control group ( $r^2 = 0.5501$ ;  $p = 0.0090$ ) and in the AWD group ( $r^2 = 0.6560$ ;  $p = 0.0025$ ) increased significantly and positively with CRL (Table 3).

The linear regression analysis indicated that the abdominal defect width increased significantly and positively with fetal weight ( $r^2 = 0.3883$ ;  $p = 0.0406$ ) and with the fetal age ( $r^2 = 0.3999$ ;  $p = 0.0368$ ), nevertheless, the abdominal defect length do not have significant correlation with the fetal weight ( $r^2 = 0.1998$ ;  $p = 0.1681$ ) and fetal age ( $r^2 = 0.2201$ ;  $p = 0.1454$ ) (Table 3).

The number of herniate organs through the abdominal wall defect do not have significant correlation with the length ( $r^2 = 0.1348$ ;  $p = 0.2668$ ) and width ( $r^2 = 0.01768$ ;  $p = 0.6967$ ) of the defect, nor with the area of the defect (Table 3).

Figure 2 shows the graphics of the following linear correlations: Abdominal Defect Area (ADA) vs. Fetal Age, Abdominal Defect Area vs. Xiphopubic Distance, Abdominal Defect Area vs. Iliac Crest Distance and Abdominal Defect Area vs. Herniated Organs.

Fetus	Anomaly	Sex	Age (WPC)	Weight (g)	CRL (cm)	Abdominal defect length (mm)	Abdominal defect width (mm)	Abdominal defect area (mm <sup>2</sup> )	Herniated organs	Associated anomalies
1	O	M	15.3	96	10	13.46	8.97	379.30	Liver, small intestine, colon, appendix	Left pelvic kidney, bilateral hydro-nephrosis (UPJ stenosis)
2	G	F	15.4	90	7	17.00	7.5	400.55	Small intestine, L-lung, heart, spleen, liver, stomach, pancreas, large intestine (except sigmoid)	Facial malformation
3	G	F	16.1	154	11	22.85	10.17	730.06	Liver, spleen, stomach, small intestine, large intestine, R-adrenal gland	Encephalocele
4	G	F	16.3	142	14	26.22	12.66	1042.84	Liver, small intestine, stomach, spleen, ascending colon, transverse	None
5	G	M	16.3	178	14	20.49	11.98	771.17	Small intestine, L-colon, descending sigmoid	Cleft lip and malformation of upper limbs and face
6	G	F	16.7	210	15	21.01	7.33	483.82	Liver, spleen, small intestine, large intestine (except cecum), R-adrenal gland	None
7	O	M	18.4	306	16	21.17	13.33	886.55	Liver, spleen, caecum with appendix, small intestine, stomach, ascending colon, common hepatic flexure, esophageal-gastric junction	Left lower limb agenesis
8	G	F	19.8	256	13	35.14	23.58	2603.13	Liver, small intestine, large intestine, stomach, spleen, L-lung	Facial malformation and upper limbs
9	O	M	26.1	1988	25	22.12	16.06	1116.04	Liver, small intestine, stomach, spleen	Bilateral renal agenesis
10	G	F	26.2	2728	24.5	31.46	17.15	1695.02	Liver, heart, L-lung, spleen, intestinal loops, ovaries, stomach, kidneys, adrenals, uterus, uterine tubes	None
11	G	F	27.4	2504	25	27.80	25.83	2255.90	Liver, stomach, small intestine, large, spleen, L-kidney	Discoid kidney

**Table 2.** The table shows the description of herniated abdominal organs in the 11 fetuses with abdominal wall defects (AWD). Age in weeks post-conception (WPC); weight in grams (g), crown-rump length in centimeters (cm); abdominal wall defects (length and width) in millimeters (mm), area of abdominal defect (hole) in square millimeters (mm<sup>2</sup>). G gastroschisis, CRL crown-rump length, O omphalocele, UPJ ureteropelvic junction.

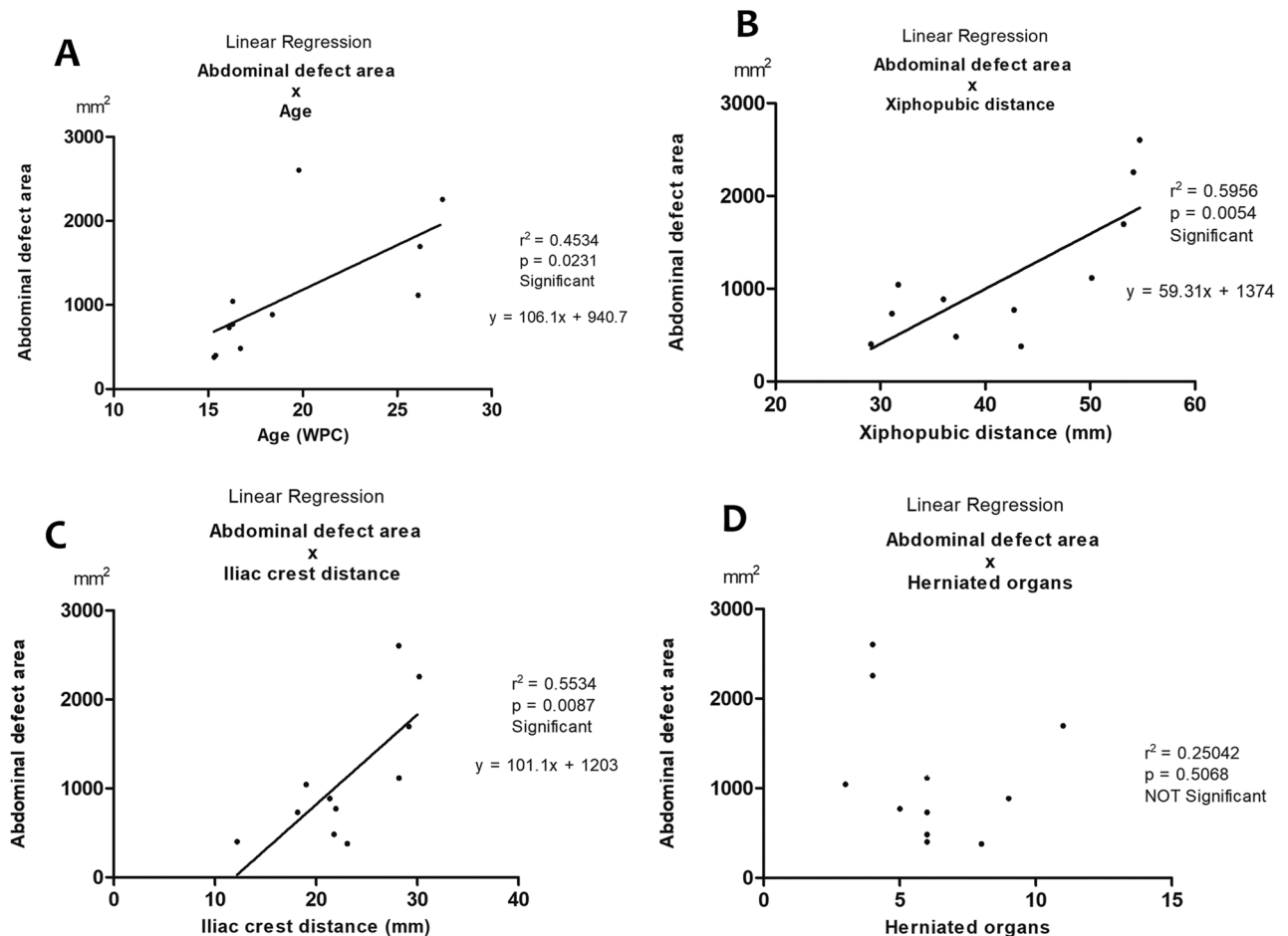
## Discussion

During the 4th WPC, the abdominal wall is formed in the craniocaudal and mediolateral directions<sup>14</sup>. From the 6th WPC, there is physiological herniation of the liver and midgut due to inadequate space in the abdominal cavity for the rapidly growing of the medium intestine<sup>15,16</sup>. The midgut completed its rotation and returns to the abdominal cavity at the 10th WPC. Omphalocele is characterized by the failure of the physiological hernia to return to the abdominal cavity<sup>17</sup>. On the other hand, the cause of gastroschisis is not completely elucidated, but there is evidence of an abnormality in the formation and development of the ventral body wall during embryogenesis, resulting mainly in bowel herniation<sup>18</sup>. Thus, the origin of this defect is different from that of omphalocele<sup>19,20</sup>.

Patients with omphalocele have a high prevalence of associated anomalies, while gastroschisis is associated with malformations outside the gastrointestinal tract in around 10% of the cases, and with abnormalities related to the gastrointestinal tract in up to 25% of cases<sup>21-23</sup>. Although our AWDs sample was small, from 8 cases of gastroschisis studied, we found 5 cases (62.5%) with anomalies not associated with the gastrointestinal tract, such as craniofacial malformations, limb agenesis and kidney anomalies.

Linear regression	r value	p value	Correlation strength
XPD × Age – Controls	$r^2 = 0.6837$	$p = 0.0017$	Moderate
XPD × Age – AWDs	$r^2 = 0.6106$	$p = 0.0045$	Moderate
ICD × Age – Controls	$r^2 = 0.4666$	$p = 0.0295$	Moderate
ICD × Age – AWDs	$r^2 = 0.6742$	$p < 0.0019$	Moderate
XPD × Weight – Controls	$r^2 = 0.8161$	$p = 0.0001$	Strong
XPD × Weight – AWDs	$r^2 = 0.4919$	$p = 0.0162$	Moderate
ICD × Weight – Controls	$r^2 = 0.8161$	$p = 0.0001$	Strong
ICD × Weight – AWDs	$r^2 = 0.5453$	$p = 0.0094$	Moderate
XPD × ADA	$r^2 = 0.5956$	$p = 0.0054$	Moderate
Age × ADA	$r^2 = 0.4534$	$p = 0.0231$	Moderate
ICD × ADA	$r^2 = 0.5534$	$p = 0.0087$	Moderate
Herniated Organs × ADA	$r^2 = 0.2504$	$p = 0.5068$	Weak

**Table 3.** The table shows the linear regression analysis (correlation strength: strong, moderate and weak) in the 22 fetuses: 11 with abdominal wall defects (gastroschisis and omphalocele); and 11 without anomalies (controls). Age fetal age in weeks postconception, XPD xiphopubic distance, AWD abdominal wall defects, ICD iliac crest distance, ADA abdominal defect area.



**Figure 2.** (A) Linear regression analysis of Abdominal Defect Area (ADA) versus Fetal Age showing that the ADA increased significantly and positively with fetal age ( $r^2 = 0.4534$ ;  $p = 0.0231$ ); (B) linear regression analysis of ADA versus Xiphopubic Distance (XPD) showing that the ADA increased significantly and positively with the XPD ( $r^2 = 0.5956$ ;  $p = 0.0054$ ); (C) linear regression analysis of ADA versus Iliac Crist Distance (ICD) showing that the ADA increased significantly and positively with the ICD ( $r^2 = 0.5534$ ;  $p = 0.0087$ ); (D) linear regression analysis of ADA versus Number of Herniated Organs showing that the area of abdominal defect (hole) did not have significant correlation with the number of herniated organs ( $r^2 = 0.25042$ ;  $p = 0.5068$ ).



The AWDs diagnosis can be easily performed by ultrasound around the 11th to 12th WPC<sup>6,7</sup>. Growth restriction is an important predictor of perinatal morbidity and mortality in gastroschisis and omphalocele, so the accurate estimation of fetal weight is important to guide the management of fetuses with AWDs<sup>24,25</sup>. Estimation of weight in fetuses with AWD was very difficult and no formula used in ultrasonography during the gestational period has yet shown good accuracy<sup>6,7</sup>. In AWDs fetuses, the abdominal circumference measurements by ultrasonography may overestimate the weight<sup>6,7</sup>.

The AWDs fetuses in our sample had higher weight and CRL when compared to controls, but in this group we had 3 fetuses with more than 26 WPC, explaining the significant differences in weight and CRL compared with the control group. The analysis of the linear regressions indicated interesting findings when comparing the abdominal wall parameters with fetal weight and crown-rump length. The biometric parameters of the abdominal wall had strong correlation with fetal weight and crown-rump length only in the fetuses of the control group. These findings support the association of AWDs with intrauterine growth restriction during the gestational period.

In fetuses with defects in the abdominal wall, the organs tend to protrude out through the abdominal hole<sup>26</sup>. In most cases, two or more organs (e.g., liver, intestines and stomach) are herniated<sup>27,28</sup>. As expected, we have observed this condition in most of our fetuses. However, despite being rarely found in these cases, we found a herniated spleen in 9 of 11 fetuses. In our sample, the organs most often herniated were liver and small intestine (91%), large intestine (82%), followed by stomach and spleen (73%). The evisceration only of the intestine classifies gastroschisis as simple, while the evisceration of other organs classifies it as complex<sup>23–26</sup>. Studies have shown that this complex condition is correlated with an increase in the mortality rate<sup>27–30</sup>.

Our findings suggest that the area of the abdominal wall defect (hole) in gastroschisis and omphalocele was not a predictor of the number of herniated abdominal organs. The linear regression analysis (Table 3 and Fig. 2) confirmed this information, showing that the number of herniate organs through the abdominal wall defect do not have significant correlation with the area of the abdominal wall defect.

Steven et al. (2019), in a recent multicentric study with 274 omphaloceles patients shows that the defect size is an independent predictor of neonatal morbidity and mortality, nevertheless, they do not performed the abdominal wall defect measurements; they only classified the defect as small, medium, large, giant and unknown<sup>31</sup>.

Our paper is the first to report correlations of the abdominal wall measurements with fetal age, weight and CRL in AWD fetuses. For the first time we also analyzed the measurements of the abdominal wall defects in human fetuses with gastroschisis and omphalocele, and correlated it with the xiphopubic and iliac distances, as well as with the herniated organs.

An important limitation of our study should be mentioned: the sample size was small, however, fetuses with gastroschisis and omphalocele are very rare and observations of a small sample are still relevant.

## Conclusion

There is moderate correlation between the xiphopubic distance and the area of abdominal defect, as well as between the iliac crest distance and the area of the abdominal defect.

There is no correlation between the size (area) of abdominal wall defect and the number of the internal organs that herniated. Therefore, the size of the hole is not a predictor of the severity of the gastroschisis or the omphalocele.

## Ethical approval

This study was carried out in accordance with the ethical standards of the hospital's institutional committee on human experimentation. (IRB: 2.770.641, CAAE: 89602318.4.0000.5259).

Received: 30 September 2020; Accepted: 9 December 2020

Published online: 08 January 2021

## References

- Christison-Lagay, E. R., Kelleher, C. M. & Langer, J. C. Neonatal abdominal wall defects. *Semin. Fetal Neonatal Med.* **16**, 164–172 (2011).
- Slater, B. J. & Pimpalwar, A. Abdominal wall defects. *Neoreviews* **21**, e383–e391 (2020).
- Forrester, M. B. & Merz, R. D. Structural birth defects associated with omphalocele and gastroschisis, Hawaii, 1986–2001. *Congenit. Anom. (Kyoto)* **48**, 87–91 (2008).
- Lakshminarayanan, B. & Lakhoo, K. Abdominal wall defects. *Early Hum. Dev.* **90**, 917–920 (2014).
- Spaulding, P., Edwards, A., Coombs, P., Davies-Tuck, M. & Robinson, A. Accuracy of sonographic estimation of weight in fetuses with abdominal wall defects. *Aust. N. Z. J. Obstet. Gynaecol.* **60**, 762–772 (2020).
- Nicholas, S. et al. Estimation of fetal weight in fetuses with abdominal wall defects. *J. Ultrasound Med.* **29**, 1069–1074 (2010).
- Chabra, S., Sienas, L., Hippe, D. S., Paulsene, W. & Dighe, M. Utility of formulas using fetal thigh soft tissue thickness in estimating weight in gastroschisis. *J. Ultrasound Med.* **39**, 1977–1983 (2020).
- Mekonen, H. K. et al. Development of the ventral body wall in the human embryo. *J. Anat.* **227**, 673–685 (2015).
- Xu, D. et al. Umbilicus and the rectus sheath: A study using human fetuses. *Surg. Radiol. Anat.* **42**, 461–471 (2020).
- Yang, J. D. et al. Development of the rectus abdominis and its sheath in the human fetus. *Yonsei Med. J.* **53**, 1028–1035 (2012).
- Hern, W. M. Correlation of fetal age and measurements between 10 and 26 weeks of gestation. *Obstet. Gynecol.* **63**, 26–32 (1984).
- Mercer, B. M., Sklar, S., Shariatmadar, A., Gillieson, M. S. & D'Alton, M. E. Fetal foot length as a predictor of gestational age. *Am. J. Obstet. Gynecol.* **156**, 350–355 (1987).
- Platt, L. D. et al. Fetal foot length: Relationship to menstrual age and fetal measurements in the second trimester. *Obstet. Gynecol.* **71**, 526–531 (1988).
- Sadler, T. W. The embryologic origin of ventral body wall defects. *Semin. Pediatr. Surg.* **19**, 209–214 (2010).
- Torres, U. S. et al. When closure fails: What the radiologist needs to know about the embryology, anatomy, and prenatal imaging of ventral body wall defects. *Semin. Ultrasound CT MRI* **36**, 522–536 (2015).

16. Cho, B. H. *et al.* Topographical anatomy of the intestines during in utero physiological herniation. *Clin. Anat.* **3**, 583–592 (2018).
17. Khan, F. A., Hashmi, A. & Islam, S. Insights into embryology and development of omphalocele. *Semin. Pediatr. Surg.* **28**, 80–83 (2019).
18. Opitz, J. M., Feldkamp, M. L. & Botto, L. D. An evolutionary and developmental biology approach to gastroschisis. *Birth Defects Res.* **111**, 294–311 (2019).
19. Beaudoin, S. Insights into the etiology and embryology of gastroschisis. *Semin. Pediatr. Surg.* **27**, 283–288 (2018).
20. Prefumo, F. & Izzì, C. Fetal abdominal wall defects. *Best Pract. Res. Clin. Obstet. Gynaecol.* **28**, 391–402 (2014).
21. Mastroiacovo, P. *et al.* Gastroschisis and associated defects: An international study. *Am. J. Med. Genet. Part A* **143**, 660–671 (2007).
22. Kumar, H. R., Jester, A. L. & Ladd, A. P. Impact of omphalocele size on associated conditions. *J. Pediatr. Surg.* **43**, 2216–2219 (2008).
23. Logsdon, N. T., Sampaio, F. J. B. & Favorito, L. A. The role of intra-abdominal pressure in human testicular migration. *Int. Braz. J. Urol.* **47**, 36–44 (2021).
24. Revels, J. W. *et al.* An algorithmic approach to complex fetal abdominal wall defects. *Am. J. Roentgenol.* **214**, 218–231 (2020).
25. Lurie, S., Sherman, D. & Bukovsky, I. Omphalocele delivery enigma: The best mode of delivery still remains dubious. *Eur. J. Obstet. Gynecol. Reprod. Biol.* **82**, 19–22 (1999).
26. Koehler, S. M. *et al.* The significance of organ prolapse in gastroschisis. *J. Pediatr. Surg.* **52**, 1972–1976 (2017).
27. Hidaka, N. *et al.* Correlation between the presence of liver herniation and perinatal outcome in prenatally diagnosed fetal omphalocele. *J. Perinat. Med.* **37**, 66–71 (2009).
28. Malkawi, H. Y., Qublan, H. S. & Al-Ghweri, A. S. Omphalocele containing bowel, liver and spleen: A case report and spleen. A case report. *J. Res. Med. Sci.* **12**, 35–37 (2005).
29. Calcagnotto, H. *et al.* Associated factors for perinatal mortality in gastroschisis. *Rev. Bras. Ginecol. e Obstet.* **35**, 549–553 (2013).
30. Raymond, S. L. *et al.* Predicting morbidity and mortality in neonates born with gastroschisis. *J. Surg. Res.* **245**, 217–224 (2020).
31. Raymond, S. L. *et al.* Outcomes in omphalocele correlate with size of defect. *J. Pediatr. Surg.* **54**, 1546–1550 (2019).

### Author contributions

N.L.: project development, data collection, manuscript writing. C.M.G.: statistics, manuscript writing, data collection. L.A.F.: project development, data collection, manuscript writing. F.J.B.S.: project development, data collection, manuscript writing.

### Funding

This study was supported by the National Council for Scientific and Technological Development (CNPQ—Brazil) (Grant number: 301522/2017) and The Rio de Janeiro State Research Foundation (FAPERJ) (Grant number: E26/202.873/2017).

### Competing interests

The authors declare no competing interests.

### Additional information

**Correspondence** and requests for materials should be addressed to L.A.F.

**Reprints and permissions information** is available at [www.nature.com/reprints](http://www.nature.com/reprints).

**Publisher's note** Springer Nature remains neutral with regard to jurisdictional claims in published maps and institutional affiliations.



**Open Access** This article is licensed under a Creative Commons Attribution 4.0 International License, which permits use, sharing, adaptation, distribution and reproduction in any medium or format, as long as you give appropriate credit to the original author(s) and the source, provide a link to the Creative Commons licence, and indicate if changes were made. The images or other third party material in this article are included in the article's Creative Commons licence, unless indicated otherwise in a credit line to the material. If material is not included in the article's Creative Commons licence and your intended use is not permitted by statutory regulation or exceeds the permitted use, you will need to obtain permission directly from the copyright holder. To view a copy of this licence, visit <http://creativecommons.org/licenses/by/4.0/>.

© The Author(s) 2021