

## Case Report

# Juvenile Hemochromatosis due to a Homozygous Variant in the *HJV* Gene

**María-Belén Moreno-Risco,<sup>1</sup> Manuel Méndez ,<sup>2</sup> María-Isabel Moreno-Carralero,<sup>2</sup> Ana-María López-Moreno,<sup>3</sup> José-Manuel Vagace-Valero,<sup>1</sup> and María-José Morán-Jiménez <sup>2</sup>**

<sup>1</sup>*Servicio de Hematología y Hemoterapia, Hospital Materno Infantil de Badajoz, Badajoz, Spain*

<sup>2</sup>*Instituto de Investigación Sanitaria Hospital 12 de Octubre (imas12), Madrid, Spain*

<sup>3</sup>*Servicio de Radiología, Hospital Universitario de Badajoz, Badajoz, Spain*

Correspondence should be addressed to María-José Morán-Jiménez; [moranjimenez@h12o.es](mailto:moranjimenez@h12o.es)

Received 24 November 2021; Revised 16 March 2022; Accepted 22 March 2022; Published 11 April 2022

Academic Editor: Vjekoslav Krzelj

Copyright © 2022 María-Belén Moreno-Risco et al. This is an open access article distributed under the Creative Commons Attribution License, which permits unrestricted use, distribution, and reproduction in any medium, provided the original work is properly cited.

Hemochromatosis type 2 or juvenile hemochromatosis has an early onset of severe iron overload resulting in organ manifestation such as liver fibrosis, cirrhosis, cardiomyopathy, arthropathy, hypogonadism, diabetes, osteopathic medicine, and thyroid abnormality, before age of 30. Juvenile hemochromatosis type 2a and 2b is an autosomal recessive disease caused by pathogenic variants in *HJV* and *HAMP* genes, respectively. We report a child with hepatic iron overload and family history of hemochromatosis. We aim to raise awareness of juvenile hemochromatosis, especially in families with a positive family history, as early diagnosis and treatment may prevent organ involvement and end-stage disease. The purpose of this study was to identify the gene variant that causes the disease. The genetic study was performed with a targeted gene panel: *HFE*, *HJV*, *HAMP*, *TFR2*, *SLC40A1*, *FTL*, and *FTH1*. We identified the variant c.309C > G (p.Phe103Leu) in the *HJV* gene in the homozygous state in the patient.

## 1. Introduction

Hereditary hemochromatosis (HH) is a disorder that causes excess iron absorption and its deposition in many organs. Progressive iron accumulation during decades result in illnesses such as liver fibrosis and cirrhosis, cardiomyopathy, diabetes, hypogonadism, hypothyroidism, arthropathy, and skin pigmentation [1]. Iron depletion by therapeutic phlebotomy or chelation therapy reduce morbidity and mortality [2].

The *HFE*, *HJV*, *HAMP*, *TFR2*, and *SLC40A1* genes have been identified as causative of HH types 1, 2a, 2b, 3, and 4, respectively. All of them have an autosomal recessive inheritance, except for type 4 with autosomal dominant inheritance [3, 4].

HH type 2a or juvenile hemochromatosis (OMIM 602390) is a severe type with an early onset, hypogonadism and cardiomyopathy being the most common symptoms at presentation and organ failure before age 30 [5, 6]. To date, more than one hundred cases of juvenile hemochromatosis

have been reported with a prevalence of 1 in 5-6 million people worldwide [7, 8]. The hemojuvelin (*HJV*) gene is located in the chromosome 1q21.1, which encodes a protein involved in the iron metabolism. Hemojuvelin is a bone morphogenic protein coreceptor and acts as a modulator of hepcidin expression, a peptide that regulates the entry of iron into plasma [9]. Seventy-nine variants have been reported so far in the *HJV* gene (<https://www.hgmd.cf.ac.uk/ac/index.php>).

## 2. Case Report

A child of Spanish origin with a familial history of iron overload and consanguineous parents was checked for ferritin, and he presented with hyperferritinemia since 3 years of age. Aged 8, he was diagnosed with hemochromatosis, presenting hyperferritinemia (777 ng/ml; normal range 30–400), high serum iron concentration (380 µg/dl; normal range 50–120), and high saturation of transferrin

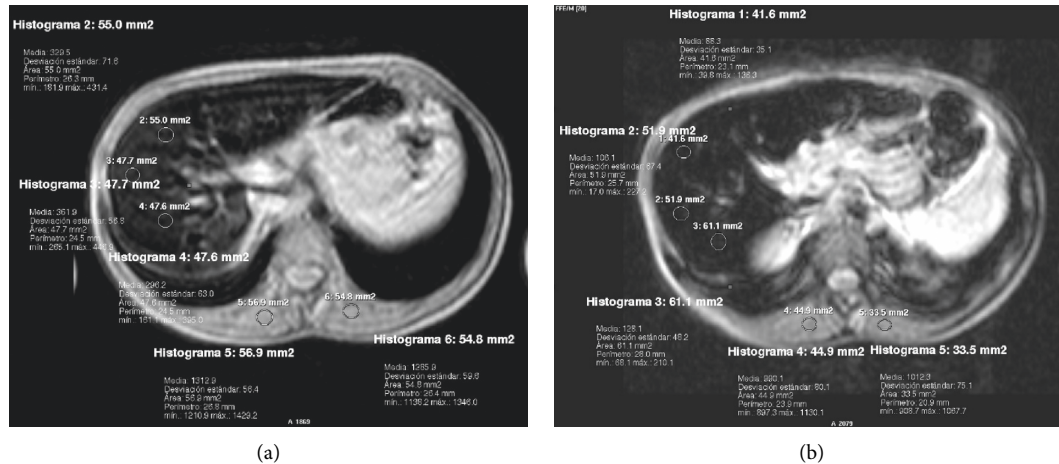


FIGURE 1: Abdominal MRI of patient. (a) Proton density fast field echo (PD FFE) sequence and (b) relaxation time T2 FFE sequence in the same axial section, with 3 regions of interest (ROI) in the liver and 2 ROIs in the paravertebral musculature to perform.

(94%; normal range 20–50). Magnetic resonance imaging (MRI) of the abdomen was performed (Figure 1), and liver iron was quantified as indicated in <https://www.sedia.es/calculadora-fe/>, [10]. If the value is greater than  $79 \mu\text{mol/g}$ , it is compatible with high overload, and if it is greater than  $85 \mu\text{mol/g}$ , it is confirmatory of high overload. The patient showed a severe hepatic iron overload,  $99.10 \mu\text{mol/g}$  equivalent to  $5.56 \text{ mg/g}$ . Other liver tests were normal except for two punctual determinations of ALT/SGPT: abdominal ultrasound, no significant findings observed; ALT/SGPT, 26–46 U/l (normal range 9–39); AST/SGOT, 29–39 U/l (normal range 10–50); AF, 195–333 U/l (normal range 141–460); and GGT, 10–16 U/l (normal range 8–61). A study of Gilbert's disease due to intermittent hyperbilirubinemia (values 0.5–1.7 mg/dl; normal range 0.2–1.2 mg/dl) was recently requested, and the homozygous presence of the (TA) 7/(TA) 7 polymorphism compatible with Gilbert's syndrome has been detected in the patient.

Genomic DNA was extracted from a peripheral blood sample. The analytical method for genetic study was the Ion AmpliSeq™ Technology (Life Technologies, Carlsbad, CA, USA). A targeted gene panel was used to sequence coding, splice site regions, and 5' and 3' untranslated regions of genes *HFE*, *HJV*, *HAMP*, *TFR2*, *SLC40A1*, *FTL*, and *FTH1*, whose reference sequences are NM\_000410.3, NM\_213653.3, NM\_021175.3, NM\_003227.3, NM\_014585.5, NM\_000146.3y, and NM\_002032.2, respectively. Torrent Suite 4.4 and Ion Reporter 5.2 softwares (Life Technologies) were used to analyze sequences and germline variants. Sequences were visualized in the Integrative Genomics Viewer (IGV-Human hg19). Sequences were reviewed and compared with the reference sequence by ClustalW2 software (<https://www.ebi.ac.uk/Tools/msa/clustalw2/>).

### 3. Discussion

The patient had the variant c.309C>G (p.Phe103Leu) in exon 3 of the *HJV* gene in homozygous state. These variants were inherited from his consanguineous parents. Moreover,

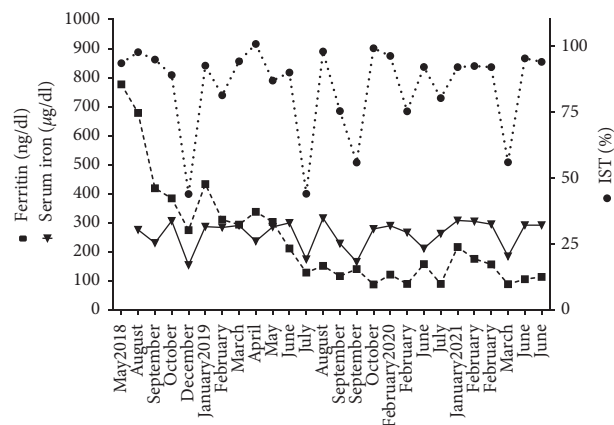


FIGURE 2: Serum ferritin and iron (left ordinate axis) and index saturation transferrin (right ordinate axis) of patient during phlebotomies treatment.

this patient has the variant c.187C>G (p.His63Asp) in exon 2 of the *HFE* gene in heterozygous state. The variant c.309C>G in the *HJV* gene has been reported in a female patient in her thirties with iron overload in the liver and spleen [11].

The hematologist prescribed phlebotomies of 7 ml blood/kg bodyweight weekly with the aim of achieving a serum ferritin concentration 50–100 ng/dl and a transferrin saturation index <50% [12]. The patient tolerated this therapy well though the process in such a small child was difficult, not only because of difficulty of venous access or peripheral catheterization dislodgement but also because the child was nervous and because the intercurrent infections altered the scheduled therapy. The therapy was suspended at the end of March and July 2019 due to infectious processes that required antibiotic treatment. From August 2018 to June 2021, the patient underwent thirty-four phlebotomies, and he achieved partial iron depletion (Figure 2). In the last MRI performed in May 2021, no hepatic iron overload was observed ( $19.4 \mu\text{mol/g}$  equivalent to  $1.1 \text{ mg/g}$ ). During this

period, the hemoglobin remained in the range of 13–15 g/dl, the serum iron in the range of 156–317  $\mu\text{g}/\text{dl}$ , the serum ferritin in the range of 89–777 ng/ml and, the transferrin saturation in the range of 56–96%. Currently, the patient continues undergoing phlebotomies therapy. Chelation therapy is not considered at present.

A cardiologist, endocrinologist, and gastroenterologist are attending the patient who has had no organ manifestations such as cardiomyopathy, arthropathy, hypogonadism, osteopathic medicine, thyroid abnormality, glucose intolerance, or abnormal liver function test, but has skin pigmentation.

Phlebotomy is the mainstay of therapy for hemochromatosis to prevent iron overload [12]. This is particularly critical during childhood in the heart, pancreas, and pituitary gland that would lead to multiorgan dysfunction. Iron chelation is a treatment to reduce iron overload; this therapy has also been reported to reverse end-stage heart failure and to improve hematological and clinical parameters in patients with juvenile hemochromatosis [13–15].

Juvenile hemochromatosis is typically diagnosed during childhood, but a milder phenotype and late onset has been reported in some patients; therefore, genetic testing for variants in the *HJV* gene should be proposed in all cases of clinical expression of iron overload [11, 16–20].

A genetic study for the currently proposed genes responsible for hemochromatosis is recommended in patients with a phenotype of iron overload and in those patients with a positive family history. The earlier the diagnosis is made, the sooner treatment can be started to prevent complications derived from the progressive iron deposit in the body.

## Ethical Approval

The Research Ethics Committee of the Hospital Universitario 12 de Octubre, Madrid, Spain, approved the genetic study.

## Consent

The patient's parents were informed and gave their consent for the genetic study on their son. Written informed consent to perform the genetic analysis was according to the local guidelines (Ley de Investigación Biomédica 14/2007, Ley Orgánica de Protección de Datos y Garantía de Derechos Digitales 3/2018) and to the General Data Protection Regulation of the European Parliament and of the Council 2016/679.

## Conflicts of Interest

The authors declare that they have no conflicts of interest.

## Authors' Contributions

MBMR and JMVV diagnosed and treated the patient, followed up the therapy, and revised the manuscript; MIMC performed the genetic study; AMLM performed the radiological analysis and revised the manuscript; MJMJ and

MM designed the genetic study, analyzed the genetic variants, and wrote the article.

## Acknowledgments

The genetic study was funded by a Spanish grant from "Fundación Investigación Biomédica Mutua Madrileña (2016–0084)."

## References

- [1] C. Pelusi, D. I. Gasparini, N. Bianchi, and R. Pasquali, "Endocrine dysfunction in hereditary hemochromatosis," *Journal of Endocrinological Investigation*, vol. 39, no. 8, pp. 837–847, 2016.
- [2] O. Loréal, T. Cavey, F. Robin, M. Kenawi, P. Guggenbuhl, and P. Brissot, "Iron as a therapeutic target in HFE-related hemochromatosis: usual and novel aspects," *Pharmaceuticals*, vol. 11, no. 4, 2018.
- [3] E. Bardou-Jacquet, Z. Ben Ali, M.-P. Beaumont-Epinette, O. Loreal, A.-M. Jouanolle, and P. Brissot, "Non-HFE hemochromatosis: pathophysiological and diagnostic aspects," *Clinics and Research in Hepatology and Gastroenterology*, vol. 38, no. 2, pp. 143–154, 2014.
- [4] A. Pietrangelo, "Hemochromatosis: an endocrine liver disease," *Hepatology*, vol. 46, no. 4, pp. 1291–1301, 2007.
- [5] C. Camaschella and E. Poggiali, "Rare types of genetic hemochromatosis," *Acta Haematologica*, vol. 122, pp. 140–145, 2009.
- [6] M. De Gobbi, A. Roetto, A. Piperno et al., "Natural history of juvenile haemochromatosis," *British Journal of Haematology*, vol. 117, no. 4, pp. 973–979, 2002.
- [7] X. Kong, L. Xie, H. Zhu et al., "Genotypic and phenotypic spectra of hemojuvelin mutations in primary hemochromatosis patients: a systematic review," *Orphanet Journal of Rare Diseases*, vol. 14, no. 1, pp. 171–194, 2019.
- [8] D. F. Wallace and V. N. Subramaniam, "The global prevalence of HFE and non-HFE hemochromatosis estimated from analysis of next-generation sequencing data," *Genetics in Medicine*, vol. 18, no. 6, pp. 618–626, 2016.
- [9] A. Piperno, R. Mariani, P. Trombini, and D. Girelli, "Hepcidin modulation in human diseases: from research to clinic," *World Journal of Gastroenterology*, vol. 15, no. 5, pp. 538–551, 2009.
- [10] B. Henninger, J. Alustiza, M. Garbowski, and Y. Gandon, "Practical guide to quantification of hepatic iron with MRI," *European Radiology*, vol. 30, no. 1, pp. 383–393, 2020.
- [11] T. Lv, W. Zhang, A. Xu et al., "Non-HFE mutations in haemochromatosis in China: combination of heterozygous mutations involving *HJV* signal peptide variants," *Journal of Medical Genetics*, vol. 55, no. 10, pp. 650–660, 2018.
- [12] K. V. Kowdley, K. E. Brown, J. Ahn, and V. Sundaram, "ACG clinical guideline: hereditary hemochromatosis," *American Journal of Gastroenterology*, vol. 114, no. 8, pp. 1202–1218, 2019.
- [13] J. Alqanatish, B. Alsowailmi, H. Alfarhan, A. Alhamzah, and T. Alharbi, "Juvenile hemochromatosis: rheumatic manifestations of 2 sisters responding to deferasirox treatment. A case series and literature review," *Open Access Rheumatology Research and Reviews*, vol. 13, pp. 15–21, 2021.
- [14] S. D. Cooray, N. M. Heerasing, L. A. Selkrig et al., "Reversal of end-stage heart failure in juvenile hemochromatosis with iron chelation therapy: a case report," *Journal of Medical Case Reports*, vol. 12, no. 1, p. 18, 2018.

- [15] T. Maeda, T. Nakamaki, B. Saito et al., “Hemojuvelin hemochromatosis receiving iron chelation therapy with deferasirox: improvement of liver disease activity, cardiac and hematological function,” *European Journal of Haematology*, vol. 87, no. 5, pp. 467–469, 2011.
- [16] B. K. Dhillon, G. Chopra, M. Jamwal et al., “Adult onset hereditary hemochromatosis is associated with a novel recurrent Hemojuvelin (HJV) gene mutation in north Indians,” *Blood Cells, Molecules, and Diseases*, vol. 73, pp. 14–21, 2018.
- [17] H. Hamdi-Rozé, Z. Ben Ali, M. Ropert et al., “Variable expressivity of HJV related hemochromatosis: “Juvenile” hemochromatosis?” *Blood Cells, Molecules, and Diseases*, vol. 74, pp. 30–33, 2019.
- [18] C. Koyama, H. Hayashi, S. Wakusawa et al., “Three patients with middle-age-onset hemochromatosis caused by novel mutations in the hemojuvelin gene,” *Journal of Hepatology*, vol. 43, no. 4, pp. 740–742, 2005.
- [19] A. Takami, Y. Tatsumi, K. Sakai et al., “Juvenile hemochromatosis: a case report and review of the literature,” *Pharmaceuticals*, vol. 13, no. 8, 2020.
- [20] L. Wu, W. Zhang, Y. Li et al., “Correlation of genotype and phenotype in 32 patients with hereditary hemochromatosis in China,” *Orphanet Journal of Rare Diseases*, vol. 16, no. 1, p. 398, 2021.