

Aortic Root and Ascending Aortic Aneurysm in an Adult with a Repaired Tetralogy of Fallot

Tae Sik Kim, M.D.*, Chan-Young Na, M.D.*, Jong Hyun Baek, M.D.*, Jin Sung Yang, M.D.*

Surgical repair of the tetralogy of Fallot is one of the most successful operations in the treatment of congenital heart diseases. We report the case of a 65-year-old man who had an aortic valve replacement at the time of complete repair of the tetralogy of Fallot at the age of forty-three. He subsequently had progressive aortic root and ascending aorta dilation to 9 cm. The aortic root and ascending aorta replacement was done using a composite valve-graft and was performed along with other procedures. Thus, meticulous follow-up of aortic root and ascending aorta after corrective surgery for tetralogy of Fallot is recommended following initial curative surgery.

Key words: 1. Aneurysm
2. Aorta, ascending
3. Tetralogy of Fallot
4. Adult

CASE REPORT

A 65-year-old man without any symptoms was referred for an operation on the aortic root and ascending aortic aneurysm. He had undergone a total correction of tetralogy of Fallot (TOF) and aortic valve replacement with mechanical valvular prosthesis 22 years earlier (in 1987, at the age of forty-three).

In August 2009, a huge aneurysmal dilatation (9 cm) of aortic root and proximal ascending aorta, severe tricuspid regurgitation, and good left ventricular ejection fraction were found on echocardiography. Atrial fibrillation was found on electrocardiography. Computed tomography showed a huge saccular aneurysm of the aortic root and proximal ascending thoracic aorta (Fig. 1).

The patient underwent a Bentall procedure involving a

composite conduit with a mechanical valvular prosthesis. The operation also included pulmonary valve replacement using a bioprosthesis, tricuspid annuloplasty, subaortic pannus resection, maze procedure, and coronary artery bypass surgery (saphenous vein to proximal right coronary artery). Because the right coronary artery orifice was deviated to the left side and was close to the aortic annulus, coronary artery bypass surgery was chosen despite availability of the button technique.

After the operation, there was the microscopic finding of cystic medial degeneration in the ascending aortic wall (Fig. 2). The postoperative period was uneventful apart from the wound disruption of femoral cannulation site. He was discharged on his 37th postoperative day. At follow-up, he remains well 17 months after this latest procedure.

*Department of Thoracic and Cardiovascular Surgery, Sejong General Hospital

†This manuscript was presented at the 224th Seoul-Gyeonggi Local Academic Meeting of the Korean Thoracic and Cardiovascular Society. Received: February 18, 2011, Revised: April 13, 2011, Accepted: May 31, 2011

Corresponding author: Chan-Young Na, Department of Thoracic and Cardiovascular Surgery, Sejong General Hospital, 91-121, Sosabon 2-dong, Sosa-gu, Bucheon 422-711, Korea

(Tel) 82-32-340-1732 (Fax) 82-32-340-1236 (E-mail) koreaheartsurgeon@hotmail.com

© The Korean Society for Thoracic and Cardiovascular Surgery. 2011. All rights reserved.

© This is an open access article distributed under the terms of the Creative Commons Attribution Non-Commercial License (<http://creativecommons.org/licenses/by-nc/3.0>) which permits unrestricted non-commercial use, distribution, and reproduction in any medium, provided the original work is properly cited.

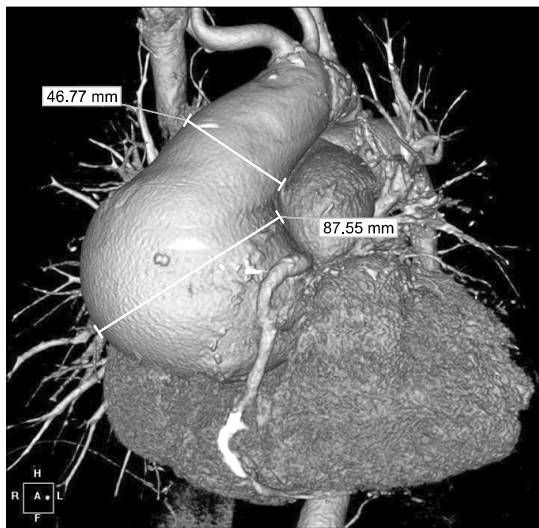


Fig. 1. The huge saccular aneurysm (9 cm) of aortic root and proximal ascending aorta in computed tomography.

DISCUSSION

In 1997, Dodds and colleagues described the first series report about progressive aortic regurgitation and aortic root dilatation after complete, uncomplicated repair of TOF [1].

A long-standing volume overload of the aortic root may cause aortic root dilatation in adults with a repaired TOF [2]. The right to left shunt through the ventricular septal defect in unrepaired TOF increases the volume overload effect on the aortic root.

Another causative mechanism for progressive aortic root dilatation is marked histological abnormalities in the aortic root and ascending aortic wall [3]. Intrinsic histological changes were found in TOF patients; including medionecrosis, fibrosis, cystic medial necrosis, elastic fragmentation and elastic lamellae disruption.

Our patient had initial reparative surgery at the age of forty-three in 1987. The phrase of the enlarged aorta was described in the record of the first operation. We could not obtain any data about the size of the ascending aorta. Also, we did not know why correction was not performed in the initial operation. In 2002, ascending aortic aneurysm (7 cm) was found on echocardiography. An operation for ascending aortic aneurysm was recommended, but he refused any surgery at

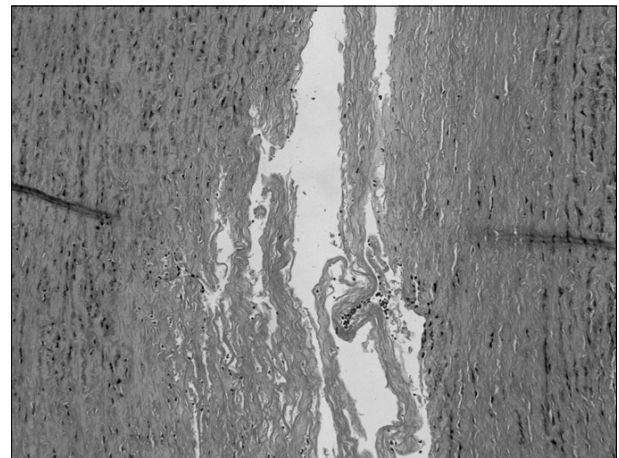


Fig. 2. Microscopic finding of cystic medial degeneration in the ascending aortic wall (H&E stain, $\times 100$).

that time.

The pathologic conditions of aortic root and ascending aorta in repaired TOF are no longer a benign problem. In recent reports, cases of aortic root dissection in repaired TOF are described [4,5]. These are the first reports of aortic dissection in tetralogy of Fallot. After an initial curative operation for TOF, meticulous monitoring of aortic root and ascending aorta is mandatory.

REFERENCES

1. Dodds GA 3rd, Warnes CA, Danielson GK. *Aortic valve replacement after repair of pulmonary atresia and ventricular septal defect or tetralogy of Fallot.* J Thorac Cardiovasc Surg 1997;113:736-41.
2. Niwa K, Siu SC, Webb GD, Gatzoulis MA. *Progressive aortic root dilatation in adults late after repair of tetralogy of Fallot.* Circulation 2002;106:1374-8.
3. Tan JL, Davlouros PA, McCarthy KP, Gatzoulis MA, Ho SY. *Intrinsic histological abnormalities of aortic root and ascending aorta in tetralogy of Fallot: evidence of causative mechanism for aortic dilatation and aortopathy.* Circulation 2005;112:961-8.
4. Rathi VK, Doyle M, Williams RB, Yamrozik J, Shannon RP, Biederman RW. *Massive aortic aneurysm and dissection in repaired tetralogy of Fallot; diagnosis by cardiovascular magnetic resonance imaging.* Int J Cardiol 2005;101:169-70.
5. Kim WH, Seo JW, Kim SJ, Song J, Lee J, Na CY. *Aortic dissection late after repair of tetralogy of Fallot.* Int J Cardiol 2005;101:515-6.