



Case Study

Case report of meningiomatosis with aspiration of a dental bridge improved by comprehensive rehabilitation therapy

MIN JI SUH, MD¹⁾, EUN YOUNG HAN, MD, PhD^{1)*}, BO RYUN KIM, MD, PhD¹⁾,
JONG HOO LEE, MD, PhD²⁾

¹⁾ Department of Rehabilitation Medicine, Jeju National University School of Medicine: Aran 13 gil 15, Jeju 63241, Republic of Korea

²⁾ Department of Internal Medicine, Division of pulmonology, Jeju National University School of Medicine, Republic of Korea

Abstract. [Purpose] The aim of this study was to ascertain the effect of comprehensive rehabilitation therapy on a quadriplegic patient with meningiomatosis and severe dysphagia. [Subject and Methods] Meningiomatosis is defined as multiple meningiomas involved in several intracranial regions, which occurs more frequently in elderly patients. The prognosis of meningiomatosis is mostly reported as benign, but the prognosis for some malignant cases can be poor. Furthermore, dysphagia in elderly patients with brain lesions may lead to foreign body aspiration, which can be fatal. The removable type of dental prosthesis is a common cause of aspiration, but aspiration is rare with the fixed type. [Results] This report presents a rare case of bronchial aspiration involving a fixed dental prosthesis in an elderly meningiomatosis patient that was improved following comprehensive rehabilitation therapy. [Conclusion] Thorough evaluation and individualized assessment of rehabilitation goals is recommended for the care of severe comorbid elderly patients.

Key words: Dysphagia, Meningiomatosis, Rehabilitation therapy

(This article was submitted May 8, 2016, and was accepted Aug. 2, 2016)

INTRODUCTION

Meningiomatosis is defined as multiple meningiomas involved in several intracranial regions, which occurs more frequently in elderly patients¹⁾. The prognosis of meningiomatosis is mostly reported as benign, because it is completely resolved after multiple surgical resection and radiation therapy²⁾. However, it is often associated with a poor prognosis, because tumor recurrence frequently appears after surgical resection, increasing the morbidity and mortality for some patients²⁾, and the effect of comprehensive rehabilitation therapy has not been reported. In addition, dysphagia is a common disorder in elderly patients³⁾. These patients exhibit changes in oropharyngeal sensory discrimination and a higher threshold to trigger the pharyngeal phase, which may increase the risk of dental origin foreign body aspiration³⁾. The increasing use of dental prostheses in elderly patients could raise the risk of aspiration leading to severe complications, even death⁴⁾. There are few case reports^{5, 6)} regarding the aspiration of dentures, however, most involve removable dentures, and aspiration of the fixed type is rarely reported.

Therefore, we report a case of bronchial aspiration of a 5 unit fixed dental bridge that occurred in a quadriplegic elderly patient with meningiomatosis and was improved following bronchoscopic removal and comprehensive rehabilitation therapy. The patient provided a written informed consent and agreed to participate in the treatment. This case report was approved by the Ethics Committee of the OO National University Hospital.

*Corresponding author. Eun Young Han (E-mail: clearblue10@naver.com)

©2016 The Society of Physical Therapy Science. Published by IPEC Inc.

This is an open-access article distributed under the terms of the Creative Commons Attribution Non-Commercial No Derivatives (by-nc-nd) License <<http://creativecommons.org/licenses/by-nc-nd/4.0/>>.

SUBJECT AND METHODS

Five years ago, an 80-year-old male, who had undergone tumor resections on three occasions and radiation therapy, was diagnosed with meningiomatosis. He became quadriplegic, and all the muscles of the bilateral upper and lower extremities showed grade 2/5 in Manual Muscle Testing (MMT). He could not walk independently, and most activities of daily living (ADL) required maximal assistance. He also presented with moderate to severe cognitive impairment, with a Korean Mini-Mental State Examination (K-MMSE) score of 16 and a Clinical Dementia Rating (CDR) of 1.

On September 18, 2012, he abruptly demonstrated impulsive violent behaviors and a confused mentality. Thus he was admitted to the Department of Neuropsychiatry with the clinician's impression of depression and received selective serotonin reuptake inhibitor (SSRI) therapy and psychiatric counseling. However, on hospital day (HD) 1, his confused mentality was not improved, and his body temperature rose above 38.5 °C. Contrast-enhanced T1-weighted magnetic resonance (MR) imaging showed an increased extent of meningiomatosis along the right sigmoid, transverse sinus, petrous ridge, cavernous sinus, and Meckel's cave, and dura of the clivus and dorsum sella, with a nodular enhancing lesion in the right side of the cerebellopontine angle (CPA), which was greater than on a previous MR image (Fig. 1). The volume of purulent sputum increased, and a chest X-ray revealed pneumonic infiltration in both lower lung zones, which was suggestive of aspiration pneumonia. Thus, antibiotics were prescribed. A nasogastric tube was inserted, and oral feeding was stopped.

On HD 44, his medical condition improved, and he was transferred to the Department of Physical and Rehabilitation Medicine. His mental status was still drowsy, and his K-MMSE score was 0/30 points. His initial Berg Balance Scale (BBS) score was 2/56, and his Korean Modified Barthel Index (K-MBI) score was 0/100, indicating totally dependent ADL. On HD 52, a video-fluoroscopic swallowing study (VFSS) showed no chewing or tongue movement. When 2 ml of diluted barium (barium/water, 35/65% weight/volume ratio) was administered to the posterior tongue, severe grade residues in the valleculae and pyriform sinuses and massive aspiration were observed. His total score for the functional dysphagia scale (FDS) was 88/100. Then, indirect dysphagia therapy was conducted including oromotor facilitation and neuromuscular electrical stimulation⁷⁾ (Vital Stim, Model 5900, Chattanooga Group, CA, USA). On HD 64, a follow-up VFSS was performed, but his FDS score was still 88/100. Thus, we recommended percutaneous endoscopic gastrostomy (PEG). However, the caregivers wanted to delay the procedure and the indirect dysphagia therapy was maintained.

On HD 94, an occupational therapist and a care assistant found a loose fixed dental bridge, and its removal was planned. However, on the next morning, his mental status deteriorated, and he experienced shortness of breath with low oxygen saturation.

RESULTS

Careful physical examination revealed that the dental bridge was missing and that breathing sounds were diminished in the left lung. Chest radiography showed a nontransparent shadow of metal intensity of approximately 45 × 10 mm in size, impacted in the left main bronchus (Fig. 2A). The first attempt at emergency bronchoscopy failed, but the 5-unit dental bridge was removed on the second attempt (Fig. 2B). On HD 105, comprehensive rehabilitation therapy was restarted (twice a day,

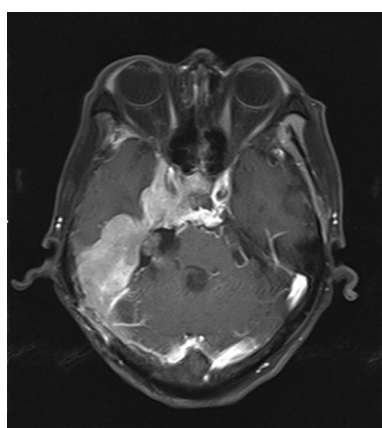


Fig. 1. Axial T1-weighted MR image showing an increased extent of meningiomatosis along the right sigmoid, transverse sinus, petrous ridge, cavernous sinus, and Meckel's cave, and dura of the clivus and dorsum sella, with a nodular enhancing lesion in the right side of the cerebellopontine angle.

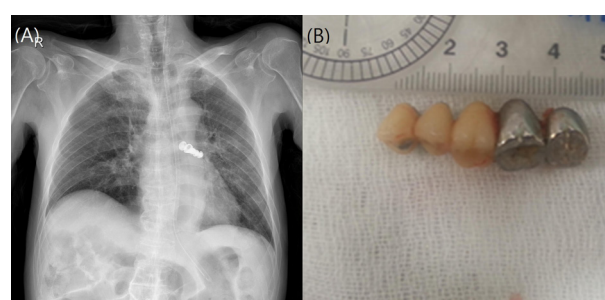


Fig. 2. (A) Chest radiography of the impacted fixed bridge in left main bronchus. (B) Extracted 5-unit dental bridge of approximately 45 × 10 mm in size.

5 days per week), and on HD 122, a PEG tube was inserted. On HD 141, there was improvement in orientation and memory, and his K-MMSE score was 8/30. Although his K-MBI score improved from 0 to 6, it still indicated a dependent state. His BBS score improved from 0/5 to 15/56, and he could ambulate using a rolling walker for about 5 meters at discharge.

DISCUSSION

This was a case of bronchial aspiration of a 5-unit fixed dental bridge that occurred in a quadriplegic elderly patient with meningiomatosis. The elderly patient with recurrent meningiomatosis and severe dysphagia was totally dependent in ADL and had severe cognitive impairment. Commonly, comprehensive rehabilitation therapy is not performed in a severe case like this, and dysphagia is a critical problem that may lead to dehydration, malnutrition, and potential life-threatening complications such as aspiration pneumonia³). About 500–2,000 people per year die as a result of the complications of aspiration in the United States, and 20% of the reported cases of foreign body aspiration are seen in elderly patients³). In addition, swallowing difficulty develops frequently in patients with comorbid brain lesions such as stroke, dementia, and Parkinson's disease³).

In these patients, chewing function and tongue movement is decreased, pharyngeal peristalsis is delayed, and oropharyngeal sensory and swallowing reflexes are reduced. All of these factors increase the risk of airway aspiration, which is an important cause of morbidity and mortality in elderly patients. Moreover, dysphagia could be missed in geriatric patients who exhibit cognitive impairment and communication disorders⁸), as in our case. Comprehensive history taking and physical examinations should be performed for these patients to prevent potentially dangerous situations. Elderly patients usually use dental prostheses and according to Limper and Prakash⁹), detachment of dental appliances from the oral cavity is the second most common cause of foreign body aspiration. If a patient is using a dental prosthesis, regular dental checkups and careful dental inspections must be performed for the safety of the patient. In our case of a swallowing problem that was confirmed by VFSS, the loosening of the dislodged dental bridge was detected through indirect oromotor facilitation therapy. When aspiration symptoms developed, we assessed the patient for aspiration of the dental bridge, and a prompt bronchoscopy and removal of the foreign body were performed. These processes might minimize the complications of tracheobronchial aspiration and enable continuation of comprehensive rehabilitation therapy.

Usually, aspirated dental prostheses tend to lodge in the right main stem bronchus, which has a more vertical and larger diameter for ease of entry⁴). Furthermore, aspiration of a fixed dental bridge is very rare; most aspirated dental prostheses are removable dentures¹⁰). However, in our case, the missing dental prosthesis was a fixed denture, which was dislodged without trauma, impacted in the left main stem bronchus. It was assumed that this was due to the patient lying in a left lateral recumbent position to prevent bedsores.

In conclusion, despite the poor prognosis, careful evaluation and rapid management of dental aspiration and 79 days of multidisciplinary rehabilitation therapy enabled our patient to improve from a bedridden status to a maximally assisted ambulatory status. The present case suggests that comprehensive evaluation and individualized assessment of rehabilitation goals should be considered for the care of severely comorbid elderly patients.

ACKNOWLEDGEMENT

This research was supported by the 2016 scientific promotion program funded by Jeju National University.

REFERENCES

- 1) Ohla V, Scheiwe C: Meningiomatosis restricted to the left cerebral hemisphere with acute clinical deterioration: case presentation and discussion of treatment options. *Surg Neurol Int*, 2015, 6: 64. [[Medline](#)] [[CrossRef](#)]
- 2) Wang J, Wang L, Luo B, et al.: Recurrent meningioma with malignant transformation: a case report and literature review. *Int J Clin Exp Med*, 2015, 8: 16845–16849. [[Medline](#)]
- 3) Forster A, Samaras N, Gold G, et al.: Oropharyngeal dysphagia in older adults: a review. *J Eurger*, 2011; 2: 356–62.
- 4) Mahmoud M, Imam S, Patel H, et al.: Foreign body aspiration of a dental bridge in the left main stem bronchus. *Case Rep Med*, 2012, 2012: 798163. [[Medline](#)]
- 5) Başoğlu OK, Buduneli N, Cagirci U, et al.: Pulmonary aspiration of a two-unit bridge during a deep sleep. *J Oral Rehabil*, 2005, 32: 461–463. [[Medline](#)] [[CrossRef](#)]
- 6) Peters TE, Racey GL, Nahman BJ: Dental prosthesis as an unsuspected foreign body. *Ann Emerg Med*, 1984, 13: 60–62. [[Medline](#)] [[CrossRef](#)]
- 7) Won YS: Influence of manual facilitation technique on swallowing disorder and aspiration pneumonia caused by severe dysphagia with stroke. *J Phys Ther Sci*, 2012, 24: 909–913. [[CrossRef](#)]
- 8) Higashijima M: Relationship between swallowing dysfunction and decreased respiratory function in dementia patients. *J Phys Ther Sci*, 2013, 25: 941–942. [[Medline](#)] [[CrossRef](#)]
- 9) Limper AH, Prakash UB: Tracheobronchial foreign bodies in adults. *Ann Intern Med*, 1990, 112: 604–609. [[Medline](#)] [[CrossRef](#)]
- 10) Gachabayov M, Isaev M, Orujova L, et al.: Swallowed dentures: two cases and a review. *Ann Med Surg (Lond)*, 2015, 4: 407–413. [[Medline](#)] [[CrossRef](#)]