



Case Report

Postoperative intracranial migration of a C2 odontoid screw: A case report and literature review

Ankush Chandra^{1,2}, Seong-Jin Moon^{1,3}, Blake Walker^{1,3}, Emre Yilmaz^{4,5}, Marc Moisi^{1,3,4}, Robert Johnson^{1,3}

¹Department of Neurological Surgery, Detroit Medical Center, Wayne State University, ²Department of Neurological Surgery, School of Medicine, Wayne State University, ³Department of Neurological Surgery, Sinai Grace Hospital, Detroit, Michigan, ⁴Seattle Science Foundation, ⁵Department of Neurosurgery, Swedish Neuroscience Institute, Seattle, Washington, United States.

E-mail: *Ankush Chandra - achandra@med.wayne.edu; Seong-Jin Moon - smoon@med.wayne.edu; Blake Walker - bwalker@med.wayne.edu; Emre Yilmaz - emre.yilmaz@gmx.de; Marc Moisi - mmoisi@dmc.org; Robert Johnson - robjohnson@med.wayne.edu

***Corresponding author:**

Ankush Chandra,
Department of Neurological
Surgery, Wayne State University
School of Medicine, 4201 St.
Antoine Street, Suite 6E,
Detroit, Michigan 48201,
United States.

achandra@med.wayne.edu

Received : 09 April 19
Accepted : 20 August 19
Published : 10 September 19

DOI
10.25259/SNI_245_2019

Quick Response Code:



ABSTRACT

Background: Intracranial migration of odontoid screws is a rare but serious complication of anterior odontoid screw fixation not often reported in literature by neurosurgeons. Here, we describe the second case in literature of intracranial migration of an odontoid screw.

Case Description: A 64-year-old neurologically intact patient with a type II odontoid fracture secondary to trauma underwent anterior odontoid screw fixation without any intraoperative complications. He tolerated the procedure well, and postoperative imaging demonstrated near anatomic correction of the fracture with satisfactory placement of the lag screw. Unfortunately, the patient was subsequently lost to follow up and he presented 7 months later for a routine outpatient computed tomography (CT) of the cervical spine, which demonstrated upward migration of the screw into the intracranial cavity abutting the medulla, with CT angiography of the neck also confirming the screw lying between the two vertebral arteries. Magnetic resonance imaging of the cervical spine also demonstrated the odontoid screw lying within close proximity to the ventral cervicomedullary junction, marginating the left vertebral artery. Subsequently, the patient was managed with removal of the odontoid screw and posterior cervical arthrodesis and instrumented fusion.

Conclusion: Our case demonstrates the rare but serious complication of intracranial odontoid screw migration, which we bring to the attention of the neurosurgical community. The recognition of risk factors for this complication and optimized management of this rare occurrence is important for surgeons to recognize.

Keywords: Anterior odontoid screw fixation, C2 odontoid screw, Postoperative intracranial migration

INTRODUCTION

Odontoid fractures are the most common cervical spine fractures with an occurrence of approximately 20% of all cervical fractures.^[5,11] Broadly speaking, odontoid fractures are divided into three categories, based on Anderson and d'Alonso classification: (1) type I: oblique fracture through the tip of the dens; (2) type II: fracture at the base of the dens, in the junction with the axis body; and (3) type III: fracture extending into the body of the axis, with or without the involvement of atlantoaxial joint.^[1,13] Of the three classes of odontoid fracture, type II is the most common, occurring approximately 65%–74% among elderly population.^[4,16]

Treatment options for type II odontoid fractures can be conservative or surgical. Due to the patient discomfort and high risk of nonunion and mortality with conservative approaches in a subpopulation of patients, surgical stabilization is typically favored and is becoming the norm for this subpopulation.^[8,19] Among surgical techniques, the two widely practiced procedures are anterior odontoid screw fixation (AOSF) and posterior cervical instrumented fusion (PCIF). While each of these procedures has unique indications and contraindications, AOSF is preferred by some spine surgeons due to its minimally invasive nature, minimal blood loss, high fusion rate from 89% to 100%, quicker postoperative recovery with preservation of normal atlantoaxial rotation, and maximum postoperative cervical spine motion.^[10,19] However, this procedure is technically quite challenging with screw breakage, malposition, and loss of fixation as some of the many possible complications – hardware failure occurs generally in a delayed fashion and is often associated with pseudoarthrosis.

We present a rare case of a 64-year-old male who presented with a posttraumatic type II odontoid fracture which was managed through AOSF. A routine computed tomography (CT) scan of the cervical spine 7 months later demonstrated intracranial migration of the screw, with the patient undergoing subsequent removal of the screw and PCIF. To the best of our knowledge, intracranial migration of odontoid screws has only been described in literature once, making our case, the second reported case of upward migration of an odontoid screw. We provide a comprehensive review of literature demonstrating postoperative migration of anterior odontoid screws and discuss the current management that spine surgeons must face when dealing with this rare, yet critical, complication.

CASE DESCRIPTION

A 64-year-old male presented as an intoxicated pedestrian who was involved in a hit-and-run incident. Initial trauma workup demonstrated that the patient had sustained a type II odontoid fracture [Figure 1]. He subsequently underwent AOSF for this fracture, without any intraoperative complications. He tolerated the procedure well and postoperative imaging demonstrated near anatomic correction of the fracture with satisfactory placement of the lag screw [Figures 2 and 3]. Postoperatively, the patient was to attend physical therapy. Unfortunately, the patient was subsequently lost to follow up and he presented 7 months later for a routine outpatient CT of the cervical spine, which demonstrated upward migration of the screw into the intracranial cavity abutting the medulla [Figure 4], with CT angiography of the neck also demonstrating the screw lying between the two vertebral arteries [Figure 5]. The patient had also obtained a magnetic resonance imaging of the cervical

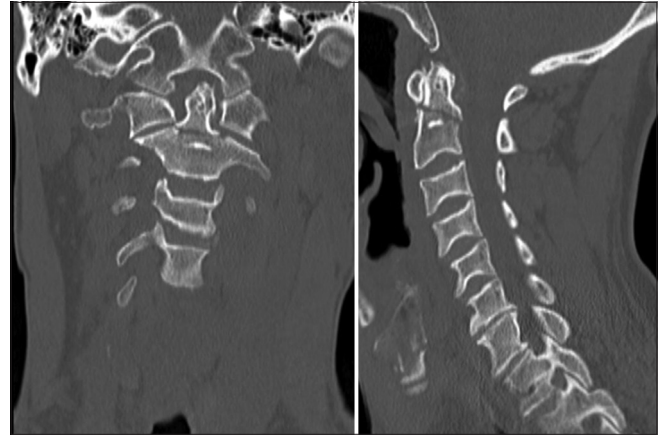


Figure 1: Coronal and sagittal computed tomography images of the cervical spine, demonstrating type II odontoid fracture.

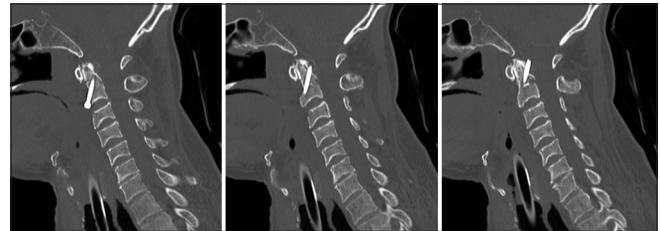

Figure 2: Sagittal immediate post-anterior odontoid screw fixation computed tomography images of the cervical spine, demonstrating near anatomic correction of the patient's type II odontoid fracture with a lag screw.

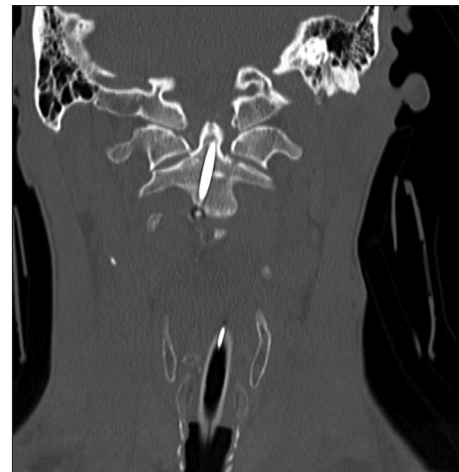

Figure 3: Coronal immediate post-anterior odontoid screw fixation computed tomography images of the cervical spine, demonstrating near anatomic correction of the patient's type II odontoid fracture with a lag screw.

spine which demonstrated the odontoid screw lying within close proximity to the ventral cervicomedullary junction, marginating the left vertebral artery [Figures 6 and 7]. Although he did not exhibit any neurological symptoms at this

time, given the migration of the screw, there was nonunion of the patient's fracture with increased risk of poor recovery and neurological deterioration. He was subsequently taken for an anterior removal of the odontoid screw with posterior open treatment and reduction, C1-4 posterolateral arthrodesis and instrumented fusion, and Brooks sublaminar wire placement of C1-2 posterior instrumentation [Figure 8]. He tolerated the procedure well and remained intact neurologically postoperatively.

DISCUSSION

Fractures of the C2 odontoid process are the most common cervical injury.^[1,4] These fractures lead to instability of the atlantoaxial joint which may result in cervical myelopathy and cervical spine compression. Management of these fractures can be done either conservatively by immobilizing the joint using a rigid or halo brace or surgically by AOSF

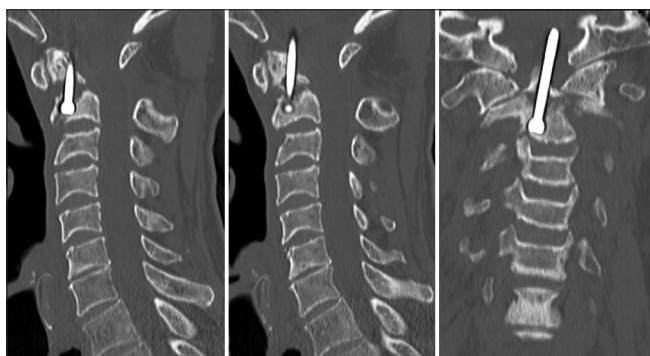


Figure 4: Sagittal and coronal computed tomography images of the cervical spine 7 months after anterior odontoid screw fixation demonstrating upward migration of the patient's odontoid screw.

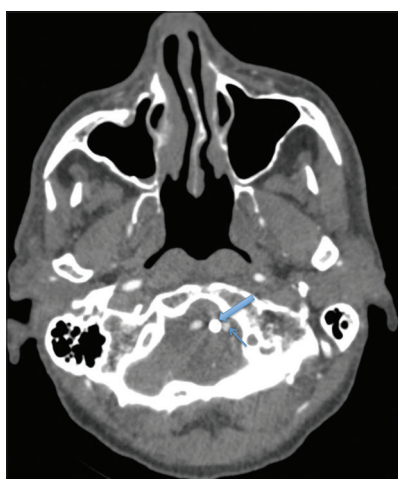


Figure 5: Axial computed tomography angiography sequence of the neck 7 months after anterior odontoid screw fixation demonstrating the odontoid screw (thick arrow) marginating the left vertebral artery (thin arrow).

or PCIF.^[2,12] However, nonsurgical management of these fractures is generally associated with poor outcomes and morbidity.^[2] While there is no current consensus on the best surgical treatment of type II odontoid fractures, AOSF has become popular among spine surgeons due to its minimal

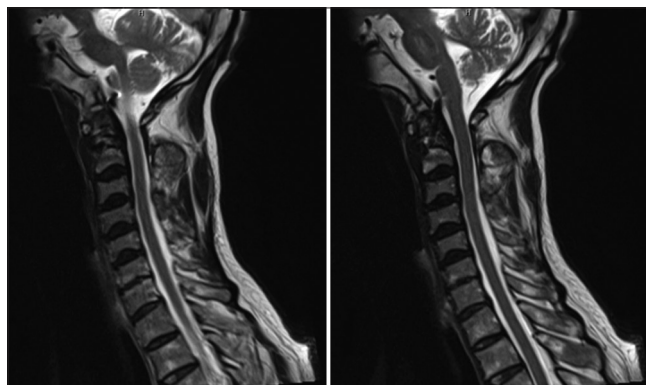


Figure 6: Sagittal magnetic resonance imaging sequences of the cervical spine demonstrating the odontoid screw lying within the ventral cervicomedullary junction.

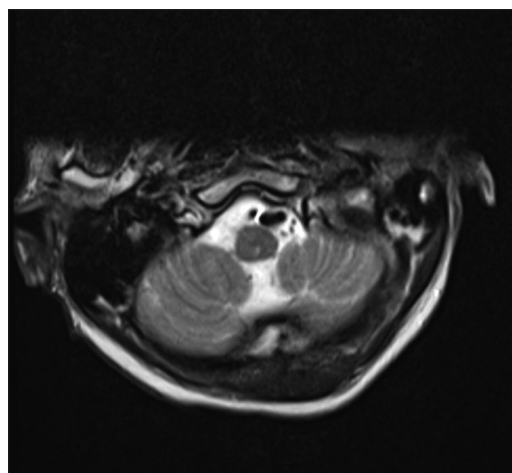


Figure 7: Axial magnetic resonance imaging sequences of the cervical spine demonstrating the odontoid screw lying within the ventral cervicomedullary junction.

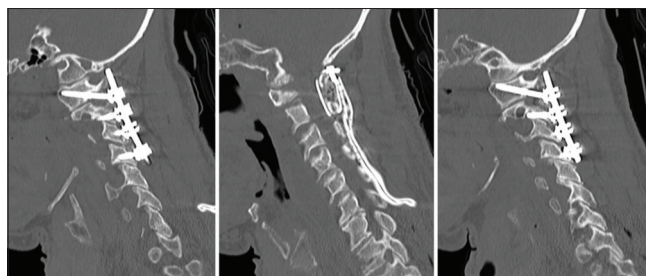


Figure 8: Sagittal computed tomography images of the cervical spine demonstrating subsequent removal of the odontoid screw with C1-4 posterior cervical instrumented fusion.

Table 1: Cases of odontoid screw migration in type II odontoid fractures.

Authors and year	Age* (years)	Cause of migration	Time to screw migration**	Presenting symptoms	Site of migration	Complications	Outcome
Lee <i>et al.</i> , 2012	27, F	Malposition of screw and local infection	3 years	Dysphagia	Pharyngeal soft tissue	None	Surgical screw removal without complications
Simonin <i>et al.</i> , 2016	70, M	Pseudoarthrosis of fracture and erosion of C1-C2 facet joints	10 years	Neck pain and quadriparesis	Medulla oblongata	None	Surgical screw removal and posterior C1-C2 fusion without complications
Leitner <i>et al.</i> , 2017	78, M	Suboptimal fixation of screw	8 years	Neck tension and dysphagia	Gastrointestinal tract	Esophageal perforation	Excreted through gastrointestinal tract

invasive nature, immediate stabilization, preservation of the atlantoaxial joint movement, and high fusion rates.^[6] Since our patient was elderly and deemed healthy to undergo surgery, we chose to manage his type II odontoid fracture by performing an AOSF due to higher success rates of fusion with AOSF as compared to a stabilization by a cervical collar^[7] and for immediate and robust stability of the fracture without compromising the normal atlantoaxial rotation.^[8]

Screw loosening and migration are well-recognized complications of several spine procedures. There are some rare occurrences reported in literature.^[9,10,12,14,15,20] Moreover, in a review of multiple series of AOSF by Subach *et al.*, the authors reported only 2 of 252 cases with screw migration, of which only one patient exhibited neurological symptoms and required screw removal.^[18] Among the cases reporting odontoid screw migration, most have described delayed esophageal or pharyngeal perforation which are summarized in Table 1.^[3,10,12] Lee *et al.* reported migration of a lag screw through the pharynx 3 years after AOSF.^[10] Leitner *et al.* reported a 78-year-old man who safely excreted a screw 8 years after implantation due to esophageal perforation and migration to the gastrointestinal tract.^[12] In an interesting case reported by Simonin *et al.*, an odontoid screw migrated upward over a decade after AOSF and caused progressive quadriparesis in a patient with rheumatoid arthritis.^[17] Radiographical evidence revealed compression of the medulla oblongata without intracranial migration of the screw, which was caused by pseudoarthrosis of the fracture and partly due to erosion of the C1-2 facet joints with vertical translation.^[17] Reports of screw and plate loosening postcervical spine fusion found local infection and inadequate perioperative positioning of the patient as contributing factors that may potentially influence screw loosening and migration post-AOSF.^[3,10] Other common factors causing screw loosening and migration post-AOSF are abnormal anatomy (subaxial cervical spondylosis, barrel chest, short neck, and severe thoracic kyphosis), pathologic fracture, rheumatoid arthritis, and incompetent transverse atlantal ligament.^[13]

There has been some consideration in literature evaluating two-screw fixation versus single screw fixation. Jenkins *et al.* demonstrated that in a series of 42 consecutive patients with odontoid screw placement, there was no significant difference in the successful union rates between one and two-screw fixation techniques (fusion was found to be 81% and 85%, respectively).^[20] Moreover, Sasso *et al.* showed that the two-screw fixation technique did provide an increased stiffness in extension loading, with no significant difference in the biomechanical fixation rate between one- and two-screw fixation methods. Thus, we did not find it necessary to perform a two-screw fixation in our patient.

Postoperative anterior or posterior migration of odontoid screws is rarely reported in literature, being reported in literature only three times [Table 1]. Our patient sustained a posttraumatic type II odontoid fracture which was initially managed with AOSF with near anatomic correction of the fracture. Follow-up imaging nearly 7 months later demonstrated upward migration of the odontoid screw, which necessitated screw removal with PCIF and instrumented fusion.

To rectify the fixation and nonfusion of the fracture, we performed a PCIF and C1-C4 posterolateral arthrodesis and instrumented fusion following anterior screw removal. While PCIF is typically done to fuse C1-C2, we extended the fusion from C1-C4 to provide additional robustness to the fusion given that our patient was elderly and that his fracture still showed significant nonfusion in spite of 7-month post-AOSF.

CONCLUSION

Intracranial migration of odontoid screws is a rare but serious complication of AOSF. Here, we report the second case in literature of intracranial migration of an odontoid screw in a neurologically intact patient, managed with subsequent removal and PCIF. Our case demonstrates the rare but serious complication of intracranial odontoid screw migration, which we bring to the attention of the neurosurgical community.

Acknowledgments

Ankush Chandra is a Howard Hughes Medical Institute Med Research Fellow.

Declaration of patient consent

The authors certify that they have obtained all appropriate patient consent forms. In the form, the patient(s) has/have given his/her/their consent for his/her/their images and other clinical information to be reported in the journal. The patients understand that their names and initials will not be published and due efforts will be made to conceal their identity, but anonymity cannot be guaranteed.

Financial support and sponsorship

Nil.

Conflicts of interest

There are no conflicts of interest.

REFERENCES

- Anderson LD, D'Alonzo RT. Fractures of the odontoid process of the axis. *J Bone Joint Surg Am* 1974;56:1663-74.
- Andersson S, Rodrigues M, Olerud C. Odontoid fractures: High complication rate associated with anterior screw fixation in the elderly. *Eur Spine J* 2000;9:56-9.
- Cagli S, Isik HS, Zileli M. Cervical screw missing secondary to delayed esophageal fistula: Case report. *Turk Neurosurg* 2009;19:437-40.
- Clark CR, White AA 3rd. Fractures of the dens. A multicenter study. *J Bone Joint Surg Am* 1985;67:1340-8.
- Dunn ME, Seljeskog EL. Experience in the management of odontoid process injuries: An analysis of 128 cases. *Neurosurgery* 1986;18:306-10.
- Geisler FH, Cheng C, Poka A, Brumback RJ. Anterior screw fixation of posteriorly displaced type II odontoid fractures. *Neurosurgery* 1989;25:30-7.
- Hsu WK, Anderson PA. Odontoid fractures: Update on management. *J Am Acad Orthop Surg* 2010;18:383-94.
- Joaquim AF, Patel AA. Surgical treatment of Type II odontoid fractures: Anterior odontoid screw fixation or posterior cervical instrumented fusion? *Neurosurg Focus* 2015;38:E11.
- Kim SJ, Ju CI, Kim DM, Kim SW. Delayed esophageal perforation after cervical spine plating. *Korean J Spine* 2013;10:174-6.
- Lee EJ, Jang JW, Choi SH, Rhim SC. Delayed pharyngeal extrusion of an anterior odontoid screw. *Korean J Spine* 2012;9:289-92.
- Lee PC, Chun SY, Leong JC. Experience of posterior surgery in atlanto-axial instability. *Spine (Phila Pa 1976)* 1984;9:231-9.
- Leitner L, Brückmann CI, Gilg MM, Bratschitsch G, Sadoghi P, Leithner A, *et al.* Passage of an anterior odontoid screw through gastrointestinal tract. *Case Rep Med* 2017;2017:2923696.
- Mazur MD, Mumert ML, Bisson EF, Schmidt MH. Avoiding pitfalls in anterior screw fixation for Type II odontoid fractures. *Neurosurg Focus* 2011;31:E7.
- Nourbakhsh A, Garges KJ. Esophageal perforation with a locking screw: A case report and review of the literature. *Spine (Phila Pa 1976)* 2007;32:E428-35.
- Pompili A, Canitano S, Caroli F, Caterino M, Crecco M, Raus L, *et al.* Asymptomatic esophageal perforation caused by late screw migration after anterior cervical plating: Report of a case and review of relevant literature. *Spine (Phila Pa 1976)* 2002;27:E499-502.
- Scheyerer MJ, Zimmermann SM, Simmen HP, Wanner GA, Werner CM. Treatment modality in Type II odontoid fractures defines the outcome in elderly patients. *BMC Surg* 2013;13:54.
- Simonin A, Borsotti F, Chittur-Viswanathan G, Duff JM. Progressive quadriparesis caused by anterior odontoid screw upward migration in rheumatoid arthritis. *Spine J* 2016;16:e309-10.
- Subach BR, Morone MA, Haid RW Jr., McLaughlin MR, Rodts GR, Comey CH, *et al.* Management of acute odontoid fractures with single-screw anterior fixation. *Neurosurgery* 1999;45:812-9.
- Wu AM, Jin HM, Lin ZK, Chi YL, Wang XY. Percutaneous anterior C1/2 transarticular screw fixation: Salvage of failed percutaneous odontoid screw fixation for odontoid fracture. *J Orthop Surg Res* 2017;12:141.
- Yee GK, Terry AF. Esophageal penetration by an anterior cervical fixation device. A case report. *Spine (Phila Pa 1976)* 1993;18:522-7.

How to cite this article: Chandra A, Moon S, Walker B, Yilmaz E, Moisi M, Johnson R. Postoperative intracranial migration of a C2 odontoid screw: A case report and literature review. *Surg Neurol Int* 2019;10:173.