

A review of echocardiograms in hypertensive patients greater than 60 years in a community based family medicine program

Shideh Doroudi, Michael D. DeLisi  and Vincent A. DeBari

New York Medical College, School of Medicine/St. Joseph's Family Medicine Department, Paterson, NJ, USA

ABSTRACT

Background: Heart disease as a result of Hypertension is known to occur. Anatomical and functional changes of the heart can easily be detected by echocardiography, which is a safe and readily available study.

Objectives: The aims of this study were to evaluate the prevalence of common echocardiographic changes in chronic hypertensive patients and to compare these changes in male and female populations.

Design/methods: The study was a community-based cross-sectional study, on 227 hypertensive patients, 60 years and older, seen in St. Joseph's Family Medicine at Clifton, with integrated clinical and echocardiographic data.

Results: Study population consisted of 227 hypertensive patients, over the age of 60 years who had echocardiography done. Overall 92.5% of the echocardiograms had abnormal findings including but not limited to TR, Diastolic dysfunction, MR, and LVH. There was significant difference between the rate of MR in male and female population.

Conclusion: A variety of echocardiographic abnormalities can be found in hypertensive patients. Drug selection in hypertension should be driven by the underlying cardiac pathology. Certain drugs have more effectiveness for diastolic dysfunction, LVH, systolic dysfunction and pulmonary hypertension and are superior choices when these conditions are present. Echocardiogram is a non-invasive and easily available tool in order to help us to select the best treatment strategy to optimize hypertensive control in the challenging group of elderly patients. The results of our study should influence us to liberally use echocardiography in these patients to guide treatment decision and drug selection.

Abbreviations: LVH: left ventricular hypertrophy; MR: mitral valve regurgitation; TR: tricuspid valve regurgitation; LVD: left ventricular dilation; LVEF: left ventricular ejection fraction

ARTICLE HISTORY

Received 4 October 2016
Accepted 10 January 2017

KEYWORDS

Echocardiography;
hypertension; elderly

1. Introduction

Hypertension is a chronic medical condition seen in a considerable proportion of patients in a primary care setting. Heart disease as a result of Hypertension is known to occur. Left Ventricular Hypertrophy (LVH) in hypertensive Patients is a marker of the burden on the heart of multiple modifiable and non-modifiable risk factors [1]. Prospective studies have consistently shown that effective long-term blood pressure (BP) lowering may prevent or reduce LVH [2]. Hypertension is also a substantial risk factor for heart failure, particularly via left ventricular diastolic dysfunction, characterized by thickening of the left ventricular wall. Anatomical changes and functional changes of the heart can easily be detected and imaged by echocardiography, which is a real-time, quick, safe, and easily available imaging study. Many of the studies reviewed, involved large proportions of Caucasian ethnicities which is not representative of many of the large metropolitan and urban centers in large cities throughout the world. With migration of different ethnicities to various parts of the world, health care

providers will be better equipped to understand their patient population's specific needs if they are provided with research and data that contains variable stratifications of varied ethnicity, ages, and comorbidities. While there have been a number of studies published within the past five years examining the relationship between hypertension, echocardiographic changes, and the variables associated, a significant proportion of the data was obtained from many years prior. The patient population seen at Clifton Family Practice offers a variance in terms of ethnicity, age, BMI, treatment regimen, stage of hypertension at initial presentation, compliance, and comorbidities. The aims of this study were to evaluate the prevalence of common echocardiographic changes in chronic hypertensive patients in a community based family medicine program and to compare these changes between male and female population.

2. Design/methods

2.1. Study design

A clinic-based cross-sectional study.

2.2. Data collection

A registry report was run on hypertensive patients. The family medicine's electronic database was used. This was done in December 2013. We used electronic data base.

2.3. Study population

Our target population was patients 60 years and older with diagnosis of hypertension in their problem list. We chose 60 years to increase the number of the study population and improve the power of the study. Hypertension was defined using GNC7 guideline. We found 548 patients, from whom, 227 had echocardiogram done in the last 8 years. We included the most recent echocardiograms available. None of the echocardiograms were interpreted by study investigators. It comprised 143 female and 84 male patients, seen in Clifton Family Practice, with integrated clinical and transthoracic echocardiographic data. All patients seen by family physicians. So in summary, all hypertensive patients who were 60 years and older, and had an echocardiogram in their medical record, were included in the study and all others excluded. Data was analyzed for age, gender, date of echocardiogram, reason for echocardiogram and common echocardiographic findings including: Left ventricular ejection fraction (LVEF), Left ventricular hypertrophy (LVH), Left atrium enlargement, Right atrium enlargement, right ventricular enlargement, valvular abnormalities, pulmonary hypertension and pericardial effusion.

2.4. Definitions and classifications

LVEF of 50% and higher considered normal. Pulmonary hypertension was defined as pulmonary artery pressure (systolic), above 25 [3]. Valvular abnormalities classified as stenosis or insufficiency meaning that other findings including thickened, sclerotic and calcified valves without evidence of stenosis or insufficiency classified as normal.

2.5. Statistical analysis

Interval data were tested for normality using the D'Agostino-Pearson omnibus normality test. Non-normally distributed interval data (age) are presented as medians and interquartile ranges (IQR). Analysis of categorical data, with gender as the exposure (female v. male) was carried out with Fisher's exact test. Because of the retrospective nature of the study, the odds ratio (OR) is used as a measure of effect size with the 95% confidence interval (95 CI) as a measure of dispersion.

The value of α was 0.05, thus $p < 0.05$ (two-sided) was required for statistical significance. Analyses were conducted with Prism® v. 6 software (GraphPad Corp. San Diego CA, USA).

3. Results

Study comprised 143 female (63%) and 84 male (37%) hypertensive patients 60 years and older with median age of 66 with interquartile range between 62 and 73 years, who had echocardiogram done during the last 8 years (average of 2.4 years). 60% of our study population were between 60 and 69 years old (Table 1).

Reasons for requesting echocardiogram including hypertension, cardiac murmur, heart failure, valve disease, chest pain, coronary artery disease, palpitation, Shortness of breath, CVA and arrhythmia but all patients were hypertensive. Overall 92.5% of the echocardiograms had abnormal findings. 57% had tricuspid regurgitation including mild (48%), moderate (7.5%), and severe (0.8%) (Figure 1).

49% of the patients had diastolic dysfunction with 47.6% Grade 1 and 1.4% Grade 2 diastolic dysfunction.

42% of the patients had mitral regurgitation, including mild (34%), mild to moderate (1.3%), moderate (5%), moderate to severe (1.3%), and severe (0.4%) (Figure 2).

57% of the patients had normal left ventricular dimensions, 37% had LVH, 5% had left ventricular dilation and 1% had combination of left ventricular dilation and LVH (Figure 3).

32% of the patients had left atrial enlargement of those 29% had mild and only 3% had moderate and severe left atrial enlargement. 5% of the population had right atrial dilation. 93% of the patients had normal and 7% had impaired left ventricular ejection fraction. (Less than 50%), including LVEF of 35–50% (3.5%) and less than 35% (3.5%) (Figure 4).

2.2%) of the patients had right ventricular dilation. Aortic valve abnormalities including 12% AI, 3.5%) AS. Only one patient was found to have a combination of AS and AI. 7% was found to have pulmonary valve insufficiency. 15% of the patients had pulmonary artery hypertension. In comparisons between male and female gender, there was one significant difference in the above mentioned echocardiographic changes was mitral regurgitation, with 36.4% in female and 52% in male popu-

Table 1. Age demographic of study population.

Age range (years)	Number of study population	Percentage (%)
60–69	137	60
70–79	64	28
≥80	26	12

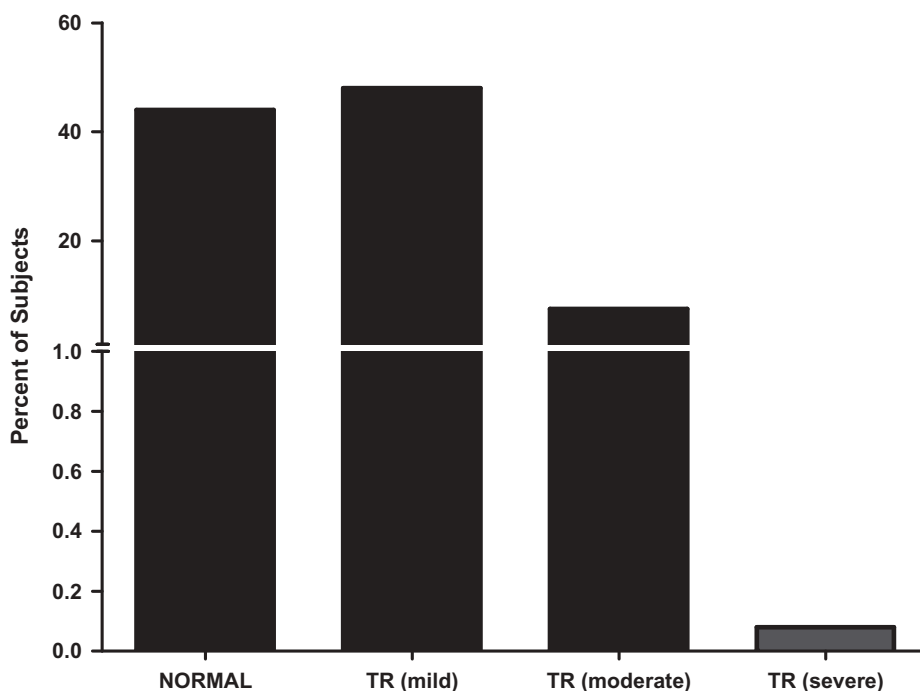


Figure 1. Percent of subjects with varying degrees of tricuspid valve insufficiency. Note that the graph is broken at 1% to show the 0.8 percent of subjects with severe tricuspid valve insufficiency.

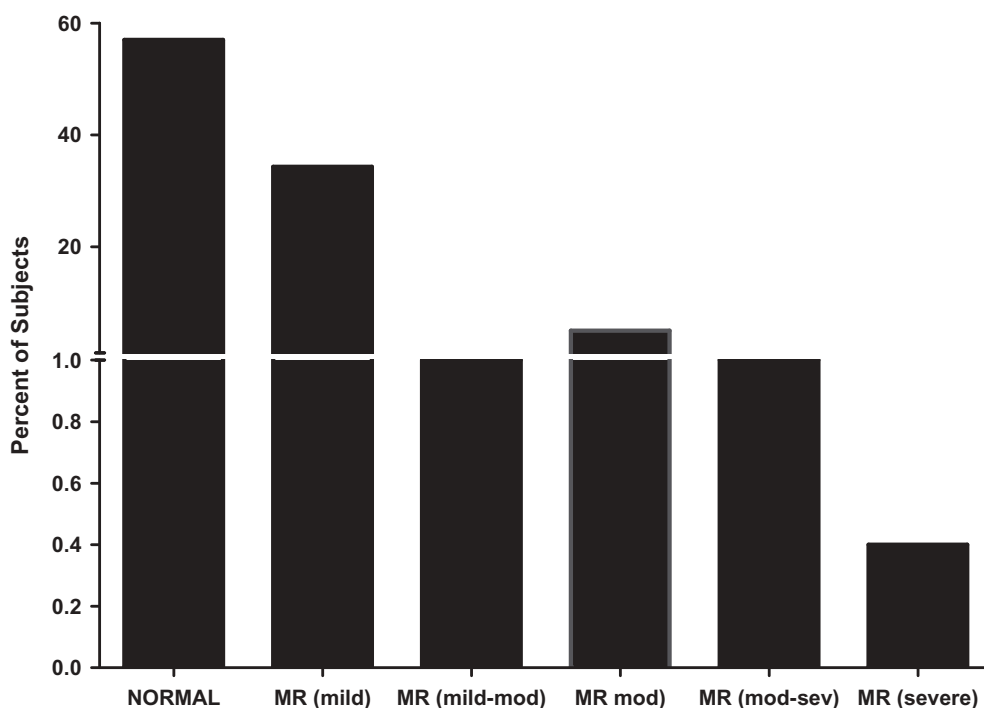


Figure 2. Percent of subjects with varying degrees of mitral valve insufficiency. Note that the graph is broken at 1% to show the 0.4 percent of subjects with severe mitral valve insufficiency.

lation [OR: 0.52, CI 95% (0.30–0.90)], and p-value of 0.026.

We have reviewed 16 different studies in our literature review. As a result we found Left ventricular hypertrophy to be a common echocardiographic finding in hypertensive patients [1,4–7] and found that Ace-Inhibitors like enalaprilat demonstrated promising myocardial remodeling effects in

experimental models of hypertensive heart disease [8]. Another finding in our literature review was the development of left ventricular diastolic dysfunction which may precede hypertrophy and may be one of the earliest changes associated with hypertensive heart disease. This finding can be assessed with echocardiogram and amlodipine, atenolol, as well as Lisinopril were found to improve this co-morbidity

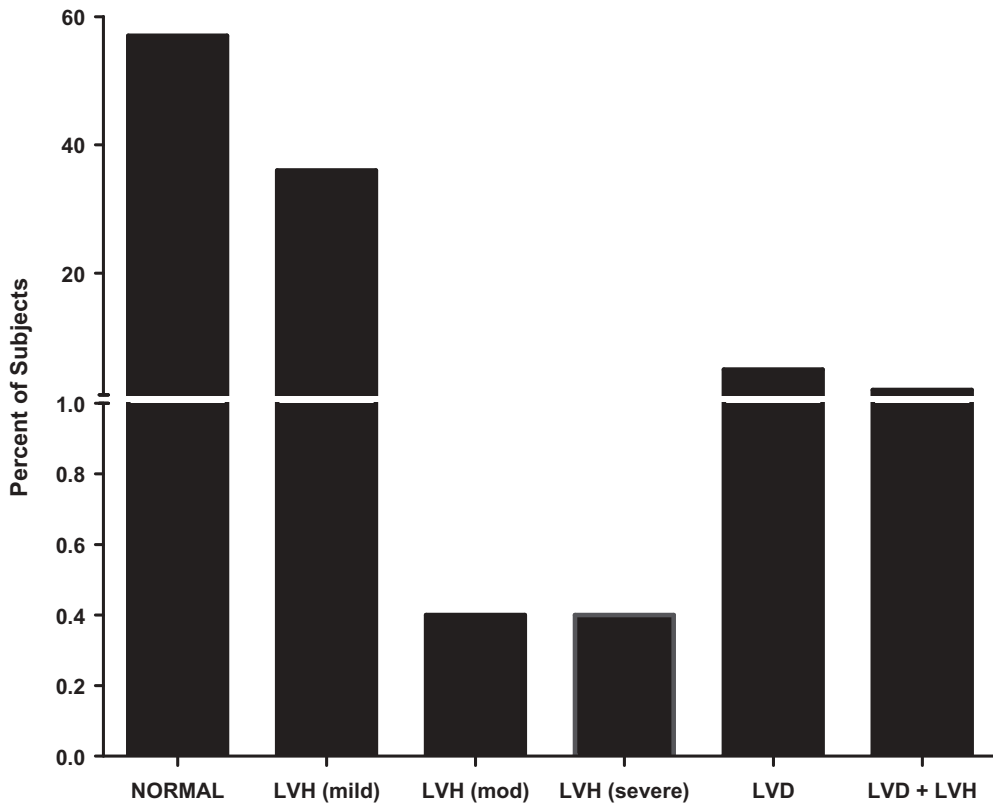


Figure 3. Percent of subjects with varying degrees of left ventricular hypertrophy/dilation. Note that the graph is broken at 1% to show the 0.4 percent of subjects with moderate and severe left ventricular hypertrophy.

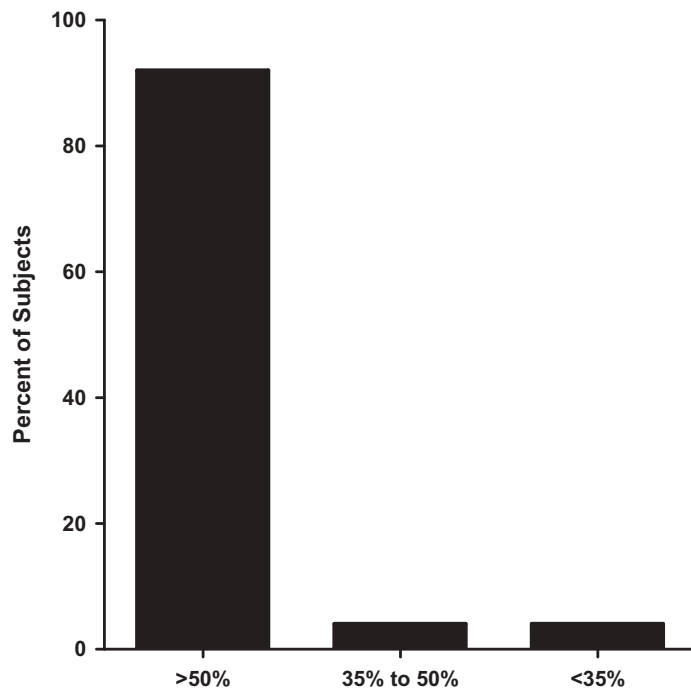


Figure 4. Percent of subjects with varying degrees of left ventricular ejection fraction.

as discussed further in our discussion [9–13]. Another study revealed that lowering blood pressure improves diastolic function irrespective of the type of antihypertensive agent used [14]. We also studied

other echocardiograms findings including left atrial enlargement and aortic valve stenosis in the existing literature and compared with those in our population.

4. Discussion

The present study assessed the prevalence of different echocardiographic changes in a cohort of hypertensive individuals 60 years and older who presented to a community based family medicine program. Reasons for echocardiogram in this population were different but they all had hypertension as one of the diagnoses in their problem list. Echocardiography is a mode of investigation that is noninvasive and assesses anatomical structure and function of the heart via a multitude of parameters. Left ventricular Hypertrophy is a preclinical organ damage frequently observed in human hypertension, reflecting the impact of chronic pressure overload on the heart [5]. In our literature review, a study done in Sweden showed sixteen percent of the healthy population versus 45% of the hypertensive patients demonstrated the presence of LVH [4]. In another study done in Italy, the prevalence of LVH in a total of 2249 hypertensive subjects with mean age of 62 was reported to be 65% [1].

Tovillas-Moran et al. reported the prevalence of LV hypertrophy to be 63.8% [7]. A Chinese study reported LVH to be a major complication of Hypertension with prevalence of 42.7% [6]. The above mentioned studies showed higher rates of LVH than what we found in our study (38%), but we can conclude that LVH is a common echocardiographic finding in hypertensive patients.

An article review done by Ferreira Fiho et al., concluded that anti-hypertensive drugs induced various degrees of hypertrophic regression for example Ace-inhibitors demonstrated promising myocardial remodeling effects in experimental models of hypertensive heart disease. Enalaprilat in particular increased the regression of hypertrophy in the left ventricular, but not in the diaphragm or the gastrocnemius muscles [8].

The development of left ventricular diastolic dysfunction may precede hypertrophy and may be one of the earliest changes associated with hypertensive heart disease. Notably, diastolic dysfunction may not be accompanied by symptoms and is usually a chance finding during a Doppler echocardiographic examination.

Since left ventricular diastolic dysfunction as assessed by Doppler echocardiography can predict mortality in middle-aged and elderly adults, this tool has acquired an important clinical position [10]. Prevalence of Left ventricular diastolic dysfunction in a random sample of a general population was estimated to be as high as 27.3% which is lower than the rate we found in our study (48%) [9]. The population in our study was hypertensive with a higher mean age and many with other medical co morbidities like diabetes, hyperlipidemia, and coronary artery disease, etc.

Setaro et al. reported verapamil to improve exercise capacity and diastolic function [11].

A long-term study, the EL VERA trial proves that amlodipine and lisinopril reduce left ventricular mass and improve diastolic function to a similar extent in elderly newly diagnosed hypertensive patients [12]. In a prospective, randomized study of 1006 patients with hypertension treated for a year, Tapp et al. found that patients receiving treatment with an amlodipine-based regimen had better diastolic function than patients treated with the atenolol-based regimen. Treatment-related differences in diastolic function were independent of BP reduction and other factors that are known to affect diastolic function [13].

In the study done by Muller-Brunotte et al., Irbesartan and Atenolol improved diastolic dysfunction [15] and in Solomon SD's study, Valsartan was no different from other hypertension medication (matched placebo) in improving diastolic function [14].

Left atrial size has been shown to be a predictor, not only of atrial fibrillation, stroke, and congestive heart failure, but also of overall cardiovascular risk. Cuspidi et al. [16] found left atrial enlargement to be a frequent finding in hypertensive patients. This abnormality was found to be strongly related to left ventricular hypertrophy and to diastolic dysfunction. For these reasons, in the European Society of Cardiology's latest guidelines for the management of arterial hypertension the measurement of left atrial size is strongly recommended [10]. We found 32% of our sample population to have Left Atrial Enlargement. The prevalence of critical Aortic valve stenosis in 552 persons of a randomly selected men and women in the age group of 55–86 was found to be 2.2% [17] which was higher than what we found in our review (0.9%).

Overall, Given that hypertension is usually detected and controlled in Primary Health Care, this implies that Primary Health Care patients could be more representative of the general hypertensive population [7].

5. Conclusion

A variety of echocardiographic abnormalities can be found in hypertensive patients, rates vary in different studies. Review of the literature concludes that drug selection in hypertension should be driven by the underlying cardiac pathology. It also suggests that certain drugs have more effectiveness for diastolic dysfunction, LVH, systolic dysfunction and pulmonary hypertension and are superior choices when these conditions are present. Echocardiogram is a non-invasive, easily available and valuable tool in elderly hypertensive patients in order to identify common underlying cardiac abnormalities which should help us to select the best treatment strategy to optimize hypertensive control in this challenging and

varied group of patients. The high prevalence of Diastolic dysfunction and LVH in elderly hypertensive patients, found in our study, should influence us to liberally use echocardiography in these patients to guide treatment decision and drug selection.

5.1. Limitations

At the time of study complete demographic data was not available. Also other co-morbid conditions might have affected the echocardiogram results.

5.2. Strengths

This study is one of the largest reviews in the literature. We reviewed a true real world and diverse population in our study.

Acknowledgment

A special thanks to MS. Barbara Spoust (RN) for running the registry report and continuous support in data collection. Also we would like to thank Ms. Avanthi Tudor (MS-IV) for helping us in a comprehensive literature review.

Disclosure statement

No potential conflict of interest was reported by the authors.

ORCID

Michael D. DeLisi  <http://orcid.org/0000-0003-4111-9131>

References

- [1] Cuspidi C, Negri F, Muiesan ML, et al. Prevalence and severity of echocardiographic left ventricular hypertrophy in hypertensive patients in clinical practice. *Blood Press*. 2011;20:3–9.
- [2] Fagard RH, Celis H, Thijs L, et al. Regression of left ventricular mass by antihypertensive treatment: a meta-analysis of randomized comparative studies. *Hypertension*. 2009;54:1084–1091.
- [3] Badesch DB, Champion HC, Gomez Sanchez MA, et al. Diagnosis and assessment of pulmonary arterial hypertension. *J Am Coll Cardiol*. 2009;54(1 Suppl):S55–S66. PMID 19555859. DOI:10.1016/j.jacc.2009.04.011
- [4] Andrén B, Lind L, Hedenstierna G, et al. Left ventricular hypertrophy and geometry in a population sample of elderly males. *Eur Heart J*. 1996;17:1800–1807.
- [5] Messerli FH, Williams B, Ritz E. Essential hypertension. *Lancet*. 2007;370:591–603.
- [6] Wang S-X, Xue H, Zou Y-B. Prevalence and risk factors for left ventricular hypertrophy and left ventricular geometric abnormality in the patients with hypertension among Han Chinese. *Chin Med J (Engl)*. 2012 Jan;125(1):21–26.
- [7] Tovillas-Morán FJ, Zabaleta-del-Olmo E, Dalfó-Baqué A. Cardiovascular morbidity and mortality and left ventricular geometric patterns in hypertensive patients treated in primary care. *Rev Esp Cardiol*. 2009;62(3):246–254.
- [8] Ferreira Filho C, De Abreu L, Ferreira M, et al. Antihypertensive drugs have different effects on ventricular hypertrophy regression. *Clinics*. 2010;65(7):723–728.
- [9] Kuznetsova T, Herbots L, López B, et al. Prevalence of left ventricular diastolic dysfunction in a general population. *Circ Heart Fail*. 2009;2:105–112.
- [10] Karabinos I, Charalampos G, Kostaki P, et al. Echocardiography in the evaluation of a hypertensive patient: an invaluable tool or simply following the routine? *Hellenic J Cardiol*. 2013;54:47–57.
- [11] Setaro JF, Zaret BL, Schulman DS, et al. Usefulness of verapamil for congestive heart failure associated with abnormal left ventricular diastolic filling and normal left ventricular systolic performance. *Am J Cardiol*. 1990 Oct 15;66(12):981–986.
- [12] Terpstra WF, May JF, Smit AJ, et al. Long-term effects of amlodipine and Lisinopril on left ventricular mass and diastolic function in elderly, previously untreated hypertensive patients: the EL VERA trial. *J Hypertens*. 2001 Feb;19(2):303e9.
- [13] Tapp RJ, Sharp A, Stanton AV, et al. Differential effects of antihypertensive treatment on left ventricular diastolic function: an ASCOT (anglo-scandinavian cardiac outcomes trial) substudy. *J Am Coll Cardiol*. 2010 Apr 27;55(17):1875–1881.
- [14] Solomon SD, Janardhanan R, Verma A, et al. Effect of angiotensin receptor blockade and antihypertensive drugs on diastolic function in patients with hypertension and diastolic dysfunction: a randomized trial. *Lancet*. 2007 Jun 23;369(9579):2079–2087.
- [15] Muller-Brunotte R, Kahan T, Malmqvist K, et al. Tissue velocity echocardiography shows early improvement in diastolic function with irbesartan and atenolol therapy in patients with hypertensive left ventricular hypertrophy. Results from the Swedish irbesartan left ventricular hypertrophy investigation vs atenolol (SILVHIA). *Am J Hypertens*. 2006 Sep;19(9):927e36.
- [16] Cuspidi C, Negri F, Sala C, et al. Association of left atrial enlargement with left ventricular hypertrophy and diastolic dysfunction: a tissue Doppler study in echocardiographic practice. *Blood Press*. 2012;21:24–30.
- [17] Lindroos M, Kupari M, Heikkilä J, et al. Prevalence of aortic valve abnormalities in the elderly: an echocardiographic study of a random population sample. *J Am Coll Cardiol*. 1993;21:1220–1225.